Ophthalmic Research

Journal for Research in Experimental and Clinical Ophthalmology

Founded 1970 by O. Hockwin, Bonn, G. Naumann, Hamburg and D.F. Cole, London
Continued by O. Hockwin, Bonn, 1981–1994, G.F.J.M. Vrensen, Zeist, 1994–2003

Editor-in-Chief

Uwe Pleyer, Berlin

Section Editors

Anatomy, Pathology and Cell Biology
A. Prescott, Dundee

Biochemistry, Molecular Biology and Molecular Genetics
J. Graw, Neuherberg

Clinical and Epidemiological Research
M. Kojima, Ishikawa-ken

Cornea and Ocular Surface
C. Marfurt, Gary, Ind.

Glaucoma
S. Tsukahara, Yamanashi

Immunology and Microbiology
U. Pleyer, Berlin

Lens and Cataract
S. Varma, Baltimore, Md.

Miscellaneous
U. Pleyer, Berlin

Neuro-Ophthalmology and Vision Sciences
T. van den Berg, Amsterdam

Ocular Oncology
M. Jager, Leiden

Physiology, Pharmacology and Toxicology
A. Wegener, Bonn

Retina and Retinal Cell Biology
N. Osborne, Oxford

Editorial Board

D. Balasubramanian, Hyderabad
A. Bialasiewicz, Muscat
D. Borchman, Louisville, Ky.
M. Boulton, Manchester
F.J. Giblin, Rochester, Mich.
D. Goldblum, Bern
S.K. Gupta, New Delhi
Chr. Hartmann, Berlin
N. Ibaraki, Chiba
J. Jonas, Mannheim
K. Kawasaki, Kanazawa
J.F. Koretz, Troy, N.Y.
Y. de Kozak, Paris
N.H. Lubsen, Nijmegen
B.R. Masters, Bethesda, Md.
H. Mayer, München
H. Nishigori, Kanagawa
C.I. Phillips, Edinburgh
M. Rao, Hyderabad
K. Sasaki, Ishikawa-Ken
J. Sparrow, Bristol
P. Söderberg, Stockholm
J. Tiffany, Oxford
J. Trevithick, London, Ont.
R. Truscott, Wollongong
S. Uga, Kanagawa
P. Wiedemann, Leipzig
B. Worgul, New York, N.Y.

KARGER

Printed in Switzerland on acid-free paper by Reinhardt Druck, Basel

Appears bimonthly: 1 volume per year (6 issues)

Guidelines for Authors

Ophthalmic Research

Submission

Only original papers written in English are considered and should be sent together with a word processing disk to:

Prof. Dr. med. U. Pleyer
Universitäts-Augenklinik
Charité Berlin
Augustenburger Platz 1
D–13353 Berlin
Tel. +49 30 4505 54131
Fax +49 30 4505 54952
E-Mail uwe.pleyer@charite.de

Manuscripts should be submitted in triplicate (with three sets of illustrations of which one is an original; final high-resolution pictures need only be sent after acceptance of the paper) together with a soft copy on disc. **The manuscript should match the electronic file exactly.** For details please refer to: www.karger.com/electronic_submission. Editorial work and copy-editing will be executed from the electronic version of your manuscript.

Types of Papers

(1) The main body of papers to be published will be *'Original Papers'* on experimental research. (2) *'Review Papers'* of up to 30 manuscript pages will be published from invited authors and by direct submission. In both cases the manuscripts will be subject to peer reviewing. Review papers will be published free of charge. (3) *'Short Communications'* of up to 3–4 pages dealing with new original concepts or technical approaches will be published at short notice. (4) 'Ophthalmic Research' has a tradition in publishing *'Supplements'* which can be published under the responsibility of guest editors. Requests for such supplements should be addressed to the managing editor.

Conditions

All manuscripts are subject to editorial review. Manuscripts are received with the explicit understanding that they are not under simultaneous consideration by any other publication except in abstract form. Submission of an article for publication implies transfer of the copyright from the author to the publisher upon acceptance. Accepted papers become the permanent property of 'Ophthalmic Research' and may not be reproduced by any means, in whole or in part, without the written consent of the publisher. It is the author's responsibility to obtain permission to reproduce illustrations, tables, etc. from other publications. Research involving live human and animal subjects must have been approved by the author's institutional review board. Ophthalmic Research requires that in the Methods section of their manuscript the authors state that they adhered to the tenets of the Declaration of Helsinki or the NIH statement for the use of Animals in Research.

Arrangement

Title page: The first page of each paper should indicate the title, the authors' names, the institute where the work was conducted, and a short title for use as running head.
NB: Authors wishing to preserve the phonetic meaning of diacritics (PubMed reduces diacritics to their root characters) must spell their names accordingly when submitting manuscripts (e.g. Müller should be Mueller).

Full address: The exact postal address of the corresponding author complete with postal code must be given at the bottom of the title page. Please also supply phone and fax numbers, as well as e-mail address.

Key words: For indexing purposes, a list of 3–10 key words in English is essential.

Abstract: Each paper needs an abstract of up to 10 lines.

Footnotes: Avoid footnotes.

Tables and illustrations: Tables and illustrations (both numbered in Arabic numerals) should be prepared on separate pages. Tables require a heading and figures a legend, also prepared on a separate page. For the reproduction of illustrations, only good drawings and original photographs can be accepted; negatives or photocopies cannot be used. Due to technical reasons, figures with a screen background should not be submitted. When possible, group several illustrations in one block for reproduction (max. size 180 × 223 mm) or provide crop marks. On the back of each illustration, indicate its number, the author's name, and 'top' with a soft pencil. Electronically submitted b/w half-tone and color illustrations must have a final resolution of 300 dpi after scaling, line drawings one of 800–1,200 dpi. Photographs of microscopic preparations should be labeled with the magnification scale, e.g. 1 mm.

Color illustrations: Up to 6 color illustrations per page can be integrated within the text at the special price of CHF 660.–/USD 545.00 per page. Color illustrations are reproduced at the author's expense.

References: In the text identify references by Arabic numerals [in square brackets]. Material submitted for publication but not yet accepted should be noted as 'unpublished data' and not be included in the reference list. The list of references should include only those publications which are cited in the text. Do not alphabetize; number references in the order in which they are first mentioned in the text. The surnames of the authors followed by initials should be given. There should be no punctuation other than a comma to separate the authors. Preferably, please cite all authors. Abbreviate journal names according to the Index Medicus system. (Also see International Committee of Medical Journal Editors: Uniform requirements for manuscripts submitted to biomedical journals. N Engl J Med 1997;336:309–315. www.icmje.org)

Digital Object Identifier (DOI)
S. Karger Publishers supports DOIs as unique identifiers for articles. A DOI number will be printed on the title page of each article. DOIs can be useful in the future for identifying and citing articles published online without volume or issue information. More information can be found at www.doi.org.

Examples
(a) Papers published in periodicals: Chatel J-M, Bernard H, Orson FM: Isolation and characterization of two complete Ara h 2 isoforms cDNA. Int Arch Allergy Immunol 2003;131:14–18.
(b) Papers published only with DOI numbers:
Theoharides TC, Boucher W, Spear K: Serum interleukin-6 reflects disease severity and osteoporosis in mastocytosis patients. Int Arch Allergy Immunol DOI: 10.1159/000063858.
(c) Monographs: Matthews DE, Farewell VT: Using and Understanding Medical Statistics, ed 3, revised. Basel, Karger, 1996.
(d) Edited books: DuBois RN: Cyclooxygenase-2 and colorectal cancer; in Dannenberg AJ, Dubois RN (eds): COX-2. Prog Exp Tum Res. Basel, Karger, 2003, vol 37, pp 124–137.

Page Charges

There are no page charges for papers of 3 or fewer printed pages (including tables, illustrations and references). Each additional complete or partial page is charged to the author at CHF 650.–/USD 540.00. The allotted size of a paper is equal to approx. 8 manuscript pages (including tables, illustrations and references). Authors of manuscripts that will exceed this allotted size are requested to submit, together with the manuscript, a written statement of their willingness to accept page charges.

Proofs

Unless indicated otherwise, proofs are sent to the first-named author and should be returned with the least possible delay. Alterations made in proofs, other than the correction of printer's errors, are charged to the author. No page proofs are supplied.

Reprints

Order forms and a price list are sent with the proofs. Orders submitted after the issue is printed are subject to considerably higher prices.

KARGER

Fax +41 61 306 12 34
E-Mail karger@karger.ch
www.karger.com

© 2004 S. Karger AG, Basel

The Guidelines for Authors are available at:
www.karger.com/ore_Guidelines

General Information

Ophthalmic Research

Publication data: 'Ophthalmic Research' is published 6 times a year. Volume 36 with 6 issues appears in 2004.

Subscription rates: Subscriptions run for a full calendar year. Prices are given per year.
Personal subscription:

Print or Online	**Print/Online combined**
CHF 514.–	CHF 555.–
EUR 380.50	EUR 410.50
USD 411.00	USD 444.00
postage and handling	(added to print and print/online)
CHF 31.80 Europe,	CHF 47.10 Overseas
EUR 22.80	
USD 31.80	

Institutional subscription:

Print or Online	**Print/Online combined**
CHF 1028.–	CHF 1110.–
EUR 761.–	EUR 822.–
USD 822.00	USD 888.00
postage and handling	(added to print and print/online)
CHF 39.60 Europe,	CHF 58.80 Overseas
EUR 28.50	
USD 39.60	

Airmail surcharge: CHF 39.60 / USD 33.00
Discount subscription prices:
Association for Eye Research;
Association for Research and Vision in Ophthalmology.

Microforms: Please direct all enquiries and orders to:
University Microfilms Inc.
300 North Zeeb Road, P.O. Box 1346
Ann Arbor, MI 48106-1346 (USA)

Subscription orders: Orders can be placed at agencies, bookstores, directly with the Publisher
S. Karger AG, P.O. Box
CH–4009 Basel (Switzerland)
or with any of the following distributors:
Deutschland: S. Karger GmbH, Postfach
D–79095 Freiburg
France: Librairie Luginbühl
36, bd de Latour-Maubourg
F–75007 Paris
Great Britain, Ireland: S. Karger AG
4 Rickett Street
London SW6 1RU, UK
USA: S. Karger Publishers, Inc.
26 West Avon Road, P.O. Box 529
Farmington, CT 06085, USA
India, Bangladesh, Sri Lanka:
Panther Publishers Private Ltd.
33, First Main
Koramangala First Block
Bangalore 560 034, India
Japan: Karger Japan, Inc.
Yushima S Bld. 3F
4-2-3, Yushima, Bunkyo-ku
Tokyo 113-0034, Japan

Change of address: Both old and new address should be sent to the subscription source.

Single issues and back volumes: Information can be obtained through the Publisher.

Advertising: Correspondence and rate requests should be addressed to the Publisher.

Bibliographic indices: This journal is regularly listed in bibliographic services, including *Current Contents®* and Index Medicus/MEDLINE.

Copying: This journal has been registered with the Copyright Clearance Center (CCC), as indicated by the code appearing on the first page of each article. For readers in the US, this code signals consent for copying of articles for personal or internal use, or for the personal or internal use of specific clients, provided that the stated fee is paid per copy directly to
Copyright Clearance Center Inc.
222 Rosewood Drive
Danvers, MA 01923 (USA)
A copy of the first page of the article must accompany payment. Consent does not extend to copying for general distribution, for promotion, for creating new works, or for resale. In these cases, specific written permission must be obtained from the copyright owner,
S. Karger AG,
P.O. Box, CH–4009 Basel (Switzerland).

Disk Submission

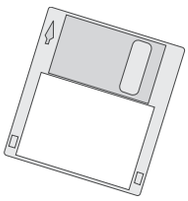

A **comprehensive version** of these guidelines for the **submission of manuscripts and illustrations on disk** can be accessed online under **www.karger.com/disksubmission** or requested as a leaflet from the editorial department.

Please follow the general rules on style and arrangement in the **'Guidelines for Authors'** of the journal. Submit a **double-spaced printout** of your manuscript matching the file on disk exactly.

Technical Information
Store only data pertinent to this manuscript. Include your fonts (screen and printer fonts for Macintosh). For a **text only** manuscript, use a 3.5-inch disk. For **text and illustrations,** use 3.5 or 5.25 Magneto Optical Disc; CD-ROM (DOS or hybrid); iomega Zip/DOS (100 MB), or 44 MB, 88 MB or 200 MB SyQuest. Compress extensive data using ZIP format.

Data Description
Label your disk with the **title of the journal or book** for which it is submitted; a **short version** of the paper's title; your **name,** postal and e-mail address, fax and phone number; **hard- and software** used, including the version; and the **complete list of the file names.** File names consist of eight characters before the dot identifying the file and three characters after the dot identifying the application.

Text and Format
The **preferred word-processing package is MS-Word.** Other commonly used PC text programs and ASCII formats are accepted.
Update your data when you revise subsequent to the reviewer's or editor's decision and mark revisions clearly. Manuscripts accepted for publication are subject to **copy editing:** changes and/or questions will be marked in the manuscript, which will be returned to you with your disk and the galley proofs for checking.
Enter your text continuously flush left. Do not use any layout functions. Do not split words at the end of a line. **Do not use indentations.** Use a blank line before and a hard return at the end of paragraphs. **Arrange headings flush left.** Insert only **one space after punctuation marks.** Insert Greek letters, mathematical symbols etc. with your word-processing program. Use **boldface and italics** as well as sub- and superscript where appropriate.
Tables are part of the text and should be placed at the end of the text file. Separate the individual parts of a table by lines. Use the tabulator instead of spaces. Format operation data on one line in the same column.

Legends to illustrations are part of the text and should also be listed at the end of the text file.

Illustrations
Store illustrations as separate files: do not integrate them in your text. Export **line drawings/vector graphics** as TIF, EPS or WMF format. Use Photoshop for processing and retouching **scanned half-tone images.** Save the original scan and the processed version. Export **black and white or color images** as TIF or EPS format in their anticipated size in print. **For detailed information** on how to submit illustration data on disk please consult the leaflet or **www.karger.com/disksubmission.**

KI 02 DISK

KARGER

Fax +41 61 306 12 34
E-Mail karger@karger.ch
www.karger.com

© 2004 S. Karger AG, Basel

The Journal Home Page is available at:
www.karger.com/ore

S. Karger
Medical and Scientific Publishers
Basel • Freiburg • Paris • London
New York • Bangalore • Bangkok
Singapore • Tokyo • Sydney

Drug Dosage
The authors and the publisher have exerted every effort to ensure that drug selection and dosage set forth in this text are in accord with current recommendations and practice at the time of publication. However, in view of ongoing research, changes in government regulations, and the constant flow of information relating to drug therapy and drug reactions, the reader is urged to check the package insert for each drug for any change in indications and dosage and for added warnings and precautions. This is particularly important when the recommended agent is a new and/or infrequently employed drug.

All rights reserved.
No part of this publication may be translated into other languages, reproduced or utilized in any form or by any means, electronic or mechanical, including photocopying, recording, microcopying, or by any information storage and retrieval system, without permission in writing from the publisher or, in the case of photocopying, direct payment of a specified fee to the Copyright Clearance Center (see 'General Information').

© Copyright 2004 by S. Karger AG,
P.O. Box, CH–4009 Basel (Switzerland)
Printed in Belgium by
Drukkerij Artoos n.v., Kampenhout
ISBN 3–8055–7823–7

KARGER

Fax +41 61 306 12 34
E-Mail karger@karger.ch
www.karger.com

Ophthalmic Research

EVER 2004

European Association for Vision and Eye Research
September 24–27, 2004, Vilamoura, Portugal

Abstracts

Guest Editor
J. Jost, Heidelberg, Germany

KARGER
Basel · Freiburg · Paris · London · New York ·
Bangalore · Bangkok · Singapore · Tokyo · Sydney

EVER-2004-abstractbook.indd 5 8/19/04 12:25:38 PM

In memory of Gordon RUSKELL

Professor Emeritus - Department of Optometry and Visual Science, City University, London.

Faculty and staff of the Department of Optometry and Visual Science, City University London, and hundreds of research colleagues, friends and other professional associates, are mourning the loss of Gordon Ruskell, O.D., Ph.D., who died after a short illness, in the first week of March 2004. He was a brilliant researcher who made numerous important contributions to our knowledge of the anatomy of the eye and it's adnexae. His knowledge and experience of eye research had a major impact on his students, many of whom became prominent researchers in their own right, engaged in unravelling the anatomical secrets of the eye. In Norway he built up successfully the eye research programme of the Department of Optometry and Visual Science of the Buskered University and the Netherlands was not only visited for the Mondrian landscape of tulip fields during Spring, but absorbing also alternatives for the pulley theory and the concomitant oculomotor control of extraocular muscles.

Gordon played an important role in the development of eye research in Europe, particularly initially, through his involvement with the Association for Eye Research (AER), on whose Board he sat, acting as treasurer for many years. He was a regular source of sage and unbiased advice on any subject that touched on the running of the association and he helped to ensure its subsequent evolution, which led to the founding of EVER. He was, until recently, chairman of the section of Anatomy of EVER and later served as a Vice President, who displayed a disarming mixture of wisdom and courtesy which was characteristic for him. Gordon Ruskell was a founding member of the European Club for Ophthalmic Fine Structure and served as its Secretary and later, as President.

We will miss Gordon's contributions to our meetings at so many levels, but in particular, we will remember him as a good friend and a fine contributor to ophthalmic science who was a model for us all.

We offer our condolences to wife and daughter and to all his family.

Per Söderberg
President of EVER
Professor of Ophthalmology at Karolinska Instiutet
Stockholm, Sweden

EVER-2004-abstractbook.indd 6 8/19/04 12:25:39 PM

TABLE OF CONTENTS

EVER 2004

September 24-27, 2004
Vilamoura, Portugal

About EVER 8

KEYNOTE LECTURES

- DRECOLL L 10
- BRON AJ 11
- PFLUGFELDER S 12
- WEST SK 13
- ZRENNER E 14
- DELAMERE NA 15
- CUNHA-VAZ J 16

POSTERS

- Posters 101-199, exhibited on Saturday 18-42
- Posters 201-274, exhibited on Sunday 43-61
- Posters 301-386, exhibited on Monday 62-83

ORAL PRESENTATIONS

- Sessions on Saturday 86-131
- Sessions on Sunday 132-175
- Sessions on Monday 176-219

All Authors Index 221

EVER-2004-abstractbook.indd 7 8/19/04 12:25:40 PM

ABOUT EVER

EVER 2004

September 24-27, 2004
Vilamoura, Portugal

EVER is a non-profit organisation. The aims of the association are to encourage research and the dissemination of knowledge concerning the eye and vision by means of meetings, publications and exchange activities.

Membership is open to individuals of any nationality engaging in or having an interest in ophthalmic and vision research who meet the requirements established by the EVER board. To become a member, a candidate shall apply to the general secretary on the membership form. The application must be endorsed by one member and the applicant shall pay an application fee. If the candidate does not know any member who can endorse his/her application, he/she should attach a letter explaining the situation. The candidate becomes a member upon recommendation by the EVER board and upon payment of the dues.

The meetings of EVER are open to members and non-members; however, only members and candidate members can submit material for a presentation.

The scientific programme is available at www.ever.be

The abstracts are arranged in order of their numbers in the programmebook. Abstracts of posters have three-digit numbers. They are grouped according to subject. Abstracts of oral presentations have four-digit numbers and are arranged per session. The authors are sole responsable for their contents.

EVER-2004-abstractbook.indd 8 8/19/04 12:25:42 PM

KEYNOTE LECTURES

EVER 2004

September 24-27, 2004
Vilamoura, Portugal

EVER-2004-abstractbook.indd 9 8/19/04 12:25:43 PM

1001

Morphological changes in glaucomatous eyes and the role of TGFß2 in the pathogenesis of the diseasein the pathogenesis of the disease

DRECOLL EL
Anatomisches Institut LS II, Erlangen

Purpose In most cases of primary open angle glaucoma (POAG) and of pseudoexfoliation glaucoma (PEX) the main risk factor for the progressive optic nerve neuropathy is age and elevated IOP. Elevated IOP is mainly caused by increase in extracellular material (ECM) in the juxtacanalicular or cribriform region of the trabecular meshwork [TM]. In eyes with POAG the so called "plaque material" is significantly increased compared to age matched controls. In eyes with PEX the specific PEX fibres are deposited in this region.Both areas of plaques and the area of the PEX-material underneath the inner wall of SC are correlated with axon loss in the optic nerve. On the other hand, only the amount of PEX-material correlated with IOP. As the extracellular material (ECM) in the TM presumably cannot influence optic nerve deneration directly, we assume that either a sequence of events (PEX-material elevated IOP axon loss) or common factors influencing TM and nerve changes could be causative.For the pathogenesis of POAG we followed the second assumption. As TGFß2 is increased in the aqueous humor of 50 % of eyes with POAG, the influence of TGFß2 on human TM cells in culture and on perfused anterior eye segments was investigated. Our results indicate, that elevated TGFß2-levels could induce increase in ECM in the TM in different ways and increase outflow resistance. In the postlaminar region of the optic nerve of eyes with POAG there was significantly more fibrosis and decrease in capillary density than in eyes with PEX-glaucoma. Treatment of optic nerve astrocytes with TGFß2 show that the increased fibrosis could also be caused by elevation of this growth factor. In summary our findings indicate that increase in TGFß2 could play a role in the pathogenesis of a proportion of eyes with POAG. Supported by SFB 539 of the DFG

EVER-2004-abstractbook.indd 10 8/19/04 12:25:43 PM

1002

Of Puzzles and Paradoxes

BRON AJ
Nuffield Laboratory of Ophthalmology, University of Oxford, Oxford

Purpose To address some puzzling corneal conditions.

Methods Deductive reasoning.

Results Unravelling of some mysteries, leaving some unsolved.

Conclusion Ignorance is the first step in discovery

1003

Mechanisms of corneal epithelial diseases in dry eye

PFLUGFELDER S, LI DQ, LUO L, DEPAIVA CS, ZHUO CHEN L, FARLEY W
Ophthalmology, Baylor College of Medicine, Houston, TX

Purpose To review evidence supporting the concept that hyperosmotic stress activates signaling pathways in the corneal epithelium that leads to altered barrier function.

Methods Dry eye was induced by systemic scopolamine administration and exposure to desiccating environment. Levels of total and activated (phosphorylated) mitogen/stress activated protein kinases (MAPK) were evaluated by western blot. Inflammatory cytokines were measured by ELISA and RT-PCR. Matrix metalloproteinases (MMPs) were measured by zymography, ELISA and RT-PCR. Apoptosis was evaluated with an ISOL assay, Hoechst nuclear staining and activated caspase 3 immunostaining.

Results Dry eye promoted activation of the MAPKs ERK, JNK and p38 in the corneal epithelium. Activation of these MAPK was also observed in corneal epithelial cultures that were exposed to hyperosmolar stress. Hyperosmolar stress stimulated synthesis of the inflammatory cytokines IL-1 β and TNF α as well as MMPs 1,3, 7, 9, 10 and 13. Stimulated synthesis of these factors was inhibited by MAPK inhibitors and doxycycline. A significant increase in apoptosis was observed in cultured corneal epithelial cells exposed to hyperosmolar stress. MMP-9 knock mice showed significantly less disruption of corneal epithelial barrier function, less proteolytic degradation of the tight junction protein occludin and less desquamation of the apical corneal epithelium than wild type mice.

Conclusion The hyperosmolar stress of dry eye activates MAPK signaling pathways and stimulates production of inflammatory cytokines and MMPS. The later appear to play a key role in the perturbation of corneal epithelial barrier function in dry eye.

EVER-2004-abstractbook.indd 12 8/19/04 12:25:43 PM

1004

Cataract at the Cross Roads: Increasing Blindness and Challenges for Research

WEST SK
Dana Center for Preventive Ophthalmology, Baltimore

Purpose Cataract is the leading cause of blindness world-wide, an estimated 25 million persons or 50% of all blindness. The numbers will grow in the future as life expectancy increases, and overwhelms the ability of most health care delivery systems to keep up with surgical intervention. Perceptions persist that cataract surgery has solved the problem of cataractous blindness, despite evidence for persistent barriers to cataract surgical services and increasingly poor outcomes, possibly including endophthalmitis. Research leading to cataract prevention should remain top priority

Methods A review of what has been learned from past research into risk factors for cataract, and new avenues for both population and laboratory research into mechanisms of cataractogenesis will be presented and discussed in terms of translation to practice. Especially relevant is research from other disciplines, which should view the lens as a window into aspects of the aging process

Results Current strategies for prevention of cataract- avoidance of ocular exposure to sunlight, cessation (or not starting) smoking, and avoidance of some medications may have modest impacts. Ongoing research is demonstrating the key role of calcium in the pathogenesis of cataract. The role of genetics, and genetic/environmental interaction is also a key area of research, although translating such discoveries into practical preventive programs will be a complex challenge.

Conclusion While operations research is urgently needed to determine optimal management of the growing population of current and future cataract cases, feasible preventive strategies will be based on the intersection of basic and clinical research efforts.

1005

From gene to therapy: the long way to understand and cure retinal diseases

ZRENNER E

Purpose The vulnerability of the retina to a wide range of pathogenic mechanisms has its origin in the complexity of the visual process. The high sophistication of the retinal circuitry, the many different types of neurotransmitter and neuromodulatory systems involved in its function, the contribution of growth factors and astrocytes and many more, reflect the multitude of of potential targets for pathogenic mechanisms. The visual cycle and the regeneration of photoreceptors by the retinal pigment epithelium (RPE) have an enormous metabolic demand and it is clear that small shifts in function can result in a catastrophic deterioration in function.There are numerous examples, some of which will be presented, how the elucidation of these mechanisms has led to the development of novel therapeutic strategies that are already applied in animal models.Over the past 15 years a massive accumulation of knowledge has led to the recognition that more than 160 genes may be involved in monogenic retinal dystrophies. From work in retinal biology the discoveries include genes coding for proteins of the transduction cascade, for maintaining the delicate structure of photoreceptor outer segments, lipid metabolism, transcription, splicing and for controlling major steps of retinal cell commitment and differentiation. Strikingly, mutations in all these genes have been found in the various inherited retinal disorders.

Conclusion Of course there are numerous problems still to be solved concerning the delivering system, compounds, long-term efficacy, safety. Nevertheless, it is obvious that the retina is an ideal model for detecting, characterising and potentially rectifying anomalous biological mechanisms as well as to develop novel strategies for prevention and repair.

EVER-2004-abstractbook.indd 14 8/19/04 12:25:44 PM

1006

Astrocyte form and function: implications for glaucoma

DELAMERE N.A. (1, 2)
(1) Ophthalmology and Visual Science, University of Louisville, Louisville, KY USA
(2) Pharmacology and Toxicology, University of Louisville, Louisville, KY USA

Results Astrocytes are multifunctional cells that have a major impact on neuronal activity, metabolism and survival. They are abundant, contributing a significant fraction to the bulk of neuronal tissues such as the optic nerve head. Astrocytes control the ion composition in the extracellular environment and also regulate extracellular pH and the extracellular concentration of glutamate. Several of these functions are made possible by the direct or indirect involvement of the sodium-potassium pump, Na,K-ATPase. Astrocytes express two distinct Na,K-ATPase isoforms, alpha-1 and alpha-2, and recent studies lead us to believe that the two isoforms serve different purposes. The Na,K-ATPase alpha-1 isoform appears to have a housekeeping role, maintaining cell-wide cytoplasmic ion composition. There is evidence from this and other laboratories to suggest that the alpha-2 isoform may be linked to calcium regulation and glutamate uptake. Alteration in the amount of calcium stored in the endoplasmic reticulum occurs as a consequence of selective Na,K-ATPase alpha-2 inhibition in rat optic nerve astrocytes. Potentially, this change in calcium storage has far-reaching consequences for astrocyte function and gene expression. Consideration of such changes in astrocyte function could be important in light of evidence that suggests a significant role for astrocytes in the remodeling of the optic nerve head that occurs with the progression of glaucoma.

1007

Characterization of diabetic retinopathy phenotypes

CUNHA-VAZ J (1, 2, 3)
(1) Department of Ophthalmology, University Coimbra Hospital, Coimbra
(2) IBILI, Faculty of Medicine, University of Coimbra, Coimbra
(3) AIBILI, Coimbra

Purpose The natural history of the initial lesions occurring in the diabetic retina has particular relevance for our understanding and management of diabetic retinal disease, one of the major causes of vision loss in the western world. Diabetic retinal lesions are still reversible at this stage opening entirely new opportunities for effective intervention.Four main alterations characterize these early stages of diabetic retinopathy: microaneurysms/hemorrhages, alteration of the Blood-Retinal Barrier, capillary closure and alterations in the neuronal and glial cells of the retina.By combining different imaging techniques, multimodal imaging of the macula made apparent three major evolving patterns: Pattern A including eyes with reversible and relatively little abnormal fluorescein leakage, a slow rate of microaneurysm formation and a normal foveal avascular zone (FAZ); Pattern B including eyes with persistently high leakage values, high rates of microaneurysm accumulation and a normal FAZ. This group may identify a "wet" form of diabetic retinopathy, and; Pattern C including eyes with variable and reversible leakage and an abnormal FAZ. The identification of different retinopathy phenotypes characterized by different rates of progression and different dominant retinal alterations, may indicate that different disease processes predominate in specific retinopathy phenotypes, probably determined by specific gene mutations.Identification of well-defined retinopathy phenotypes may be an essential step in the quest for a successful treatment of diabetic retinopathy. The characterization of specific retinopathy phenotypes and predominant disease mechanisms involved is expected to contribute to improve targeted drug therapy.

EVER-2004-abstractbook.indd 16 8/19/04 12:25:44 PM

POSTERS

EVER 2004

September 24-27, 2004
Vilamoura, Portugal

EVER-2004-abstractbook.indd 17 8/19/04 12:25:45 PM

101

Trypan blue staining of epirretinal membranes in proliferative vitreoretinopathy

ESPINOZA-NAVARRO J, MILDRED FROMOW-GUERRA MDMILDRED FROMOW-GUERRA MILDRED FROMOW-GUERRA, ARTHUR LEVINE-BEREBICHEZ, RENATA GARCIA-FRANCO
Glaucoma Department, Fundacion Hospital Nuestra Señora de la Luz, Mexico

Purpose To evaluate the utility of trypan blue staining of epirretinal membranes in proliferative vitreorretinopathy surgery and to recognize clinical signs of toxicity to intraocular tissues.

Methods We performed standard three port vitrectomy, in patients with Proliferative Vitreorretinopathy stage C2 or more. After a partial fluid-air interchange, 0.5 ml of trypan blue 0.15% was introduced into the vitreous cavity for 1 minute. The dye was removed and peeling of epirretinal membranes was performed.

Results Seven patients underwent trypan blue staining. Five patients showed staining of epirretinal membranes, two patients showed no staining of the epirretinal tissue. None showed staining of the underlying retina or residual intraocular staining in the postoperative period.

Conclusion No clinical signs of toxicity was detected. Trypan blue staining of epirretinal membranes can be useful in some cases of Proliferative Vitreorretinopathy depending on maturity of membranes as well as on the technique used for trypan blue staining.

102 / 1155

Effects of vitamin C on hyperoxia-induced reduction of retinal blood flow

LUKSCH A (1, 2), WEIGERT G (1), MAÁR N (2), RESCH H (1), SCHMETTERER L (3, 1)
(1) Department of Clinical Pharmacology, Vienna
(2) Department of Ophthalmology, Vienna
(3) Department of Medical Physics and Biomedical Engineering, Vienna

Purpose The purpose of the present study was to investigate whether ascorbic acid alters retinal blood flow and/or modifies the retinal vasoconstrictor response to systemic hyperoxia.

Methods We performed a randomized, double-masked, placebo-controlled study in 12 healthy male volunteers. Subjects received vitamin C (3g i.v.) or placebo on two different study days. 100% oxygen was inhaled over a period of 12 minutes two times, before and after drug administration, per study day. Retinal vessel diameter (Zeiss retinal vessel analyzer) and retinal blood flow velocity (bi-directional Doppler velocimetry) were assessed continuously. Blood gas analysis was done from arterialized capillary blood from the earlobe. Intraocular pressure and systemic hemodynamics were measured in regular intervals.

Results Systemic hemodynamics and intraocular pressure were comparable on both study days and remained unchanged throughout the study. The values of the blood gas analysis were within the expected range. Administration of vitamin C did not alter retinal blood flow parameters at baseline. Breathing of 100% oxygen for 12 minutes reduced retinal venous diameter ($p<0.0001$ versus baseline) and retinal blood velocity ($p<0.0001$ versus baseline). The reduction of retinal hemodynamic parameters in response to systemic hyperoxia was not altered by administration of vitamin C (venous diameter: $p=0.51$, blood flow velocity: $p=1.0$).

Conclusion In healthy humans vasoconstriction of retinal vessels and decreased retinal blood flow velocity in response to systemic hyperoxia is not altered by a dose of vitamin C. In addition, vitamin C did not influence retinal blood flow at baseline. Accordingly, vitamin C does not influence retinal blood flow to a substantial degree.

103 / 1156

Preterm Birth and Retinovascular Development

FIELDER AR, COCKER KD
Visual Neuroscience, Imperial College London, London

Purpose To study retinovascular development in babies born prematurely, without and with retinopathy of prematurity.

Methods Images were acquired using wide-field non-contact digital imaging (RetCam 120, Massie Labs, Dublin, CA) obtained during routine screening for retinopathy of prematurity (ROP). The following 4 studies were performed: i) measurement of the distance from optic disc to first bifurcation of arterioles and venules; ii) assessment of emergent angle of temporal vessels; iii) quantifying tortuosity of the retinal arterioles, and iv) measurement of venule diameter. Results were categorised by the infant's gestational age (GA): 24-27 weeks, 28-31 weeks and ≥32 weeks (GA), and ROP status.

Results The temporal vessel angles were similar between the 2 eyes of each infant, but the temporal vessel angle increased with time in utero. The superior and inferior retinal vessels differ in their distance from the fovea. There was a trend of increasing distance to the first bifurcation of the inferior temporal arteriole with increasing prematurity, but venous bifurcation was not affected by the degree of prematurity. Arteriolar tortuosity and venous diameter both increased with increasing ROP stage.

Conclusion Recently developed methods of retinal imaging present new opportunites to study in a quantitive manner, retinal development. These preliminary studies demonstrate that shortening the gestational period affects the development of the major retinal vessels, which in turn reflects underlying microvasculature and neural development. In many instances, the influences of prematurity per se and ROP cannot be differentiated. These studies show promise for the quantification of plus disease in ROP.

104 / 1357

Diode laser (diopexyâ) transmission trough sclera

PLAZAS A, RUIZ-LAPUENTE C
HH UU VIRGEN DEL ROCIO, Sevilla

Purpose The transscleral application of the diode laser can be useful in the treatment of retinopathy of prematurity, intraocular tumors, retinal breaks, retinal detachment and glaucoma. The presence of subretinal blood or high neurosensorial detachment does not allow for Photodynamic Therapy or Transpupillary Termotherapy as demonstrated by several authors.Purpose: to quantify the ex vivo Diode laser (Diopexyâ) transmission trough sclera

Methods Transscleral laser diode transmission was measured by placing human sclera in contact with laser light from Diopexyâ probe. A power sensor behind took the measurements. The mean of five readings was then calculated.

Results

POWER					
100	6.3	2.2	2.0	3.4	4.2
250	3.8	4.3	4.2	9.1	5.7
500	8.5	6.3	8.4	8.1	8.3
1000	24	16.7	25	31.6	27

Conclusion As seen in the table, most part of the energy of the LASER is blocked by the sclera, but in vivo enhanced absorption by choroid could be reached by infusion of ev indocyanine green.

EVER-2004-abstractbook.indd 18 8/19/04 12:25:45 PM

105 / 1157

Expression of apoptosis markers in retinas of human subjects with diabetes

ABU EL ASRAR AM (1), DRALANDS L (2), MISSOTTEN L (2), AL-JADAAN IA (3), GEBOES K (4)
(1) Department of Ophthalmology, Riyadh
(2) Department of Ophthalmology, Leuven
(3) King Khaled Eye Specialist Hospital, Riyadh
(4) Laboratory of Histochemistry and Cytochemistry, Leuven

Purpose To investigate the expression of the apoptotic mediators in the retinas from human subjects with diabetes mellitus.

Methods Ten postmortem eyes from five subjects with diabetes mellitus, and 8 control eyes were examined. We used antibodies directed GFAP, caspase-3, Fas, Fas ligand (FasL), Bax, Bcl-2, survivin, p53, extracellular signal-regulated kinases (ERK1/2), and p38.

Results In retinas from all subjects without diabetes, weak Bcl-2 immunoreactivity was confined to GFAP+ glial cells in the nerve fiber layer. Weak immunoreactivity for ERK1/2 was noted in a few nuclei in the inner nuclear layer and in a few Müller cell processes. Cytoplasmic immunostaining for survivin was noted in the retinal pigment epithelial cells. All diabetic retinas showed cytoplasmic immunoreactivity for caspase-3, Fas, and Bax in ganglion cells. FasL immunoreactivity was detected in GFAP-positive cells. Up-regulation of Bcl-2 immunoreactivity was noted in GFAP+ cells in nerve fiber and ganglion cell layers, and Bcl-2 induction was noted in Müller cell processes. Strong immunoreactivity for ERK1/2 was observed in many nuclei in inner nuclear layer, GFAP+ cells in nerve fiber and ganglion cell layers, and numerous Müller cell processes. Survivin immunoreactivity was not altered in the diabetic retinas.

Conclusion Ganglion cells in diabetic retinas express several proapoptosis molecules suggesting that these cells are the most vulnerable population. Glial cells in diabetic retinas are activated and express several antiapoptosis molecules in addition to the cytotoxic effector molecule FasL suggesting a possible role of glial cells in induction of apoptosis in ganglion cells.

106

Investigation of the effects of phototoxicity on photoreceptor function and visual outcome following arteriovenous sheathotomy surgery

MUQIT MMK (1), PARKS S (2), KEATING D (2), MURDOCH JR (1)
(1) Tennent Institute of Ophthalmology, Glasgow
(2) Electrodiagnostic Imaging Unit, Glasgow

Purpose Arteriovenous sheathotomy (AVS) surgery for branch retinal vein occlusion (BRVO) has produced variable clinical outcomes in the literature with uncertainty over the reasons for functional improvement. We evaluate the effects of AVS surgery on retinal function, and assess the potential role of retinal phototoxicity under these surgical conditions and the relationships with clinical visual outcomes.

Methods 6 patients underwent pars plana vitrectomy (PPV) and AVS for BRVO. The fibre-optic endoillumination (FOE) system was used under standard conditions. Patients were examined by fluorescein angiography (FA), and wide field multifocal electroretinography (wfmERG) using a custom built system. Follow-up period was 4 months to 1 year.

Results Standard FOE exposure times for the AVS stages were three times that used for a PPV procedure. A higher power output was used with close proximity of the light-pipe to the retinal surface. FA demonstrated reperfusion beyond the arteriovenous blockage site and resolution of macular oedema in most patients. Visual recovery ranged from 0 to greater than 0.8 logMAR units. WfmERG showed a significant delay in the implicit timing of responses after surgery. The delay slowly returned to preoperative levels by 3 months. This was seen across central and peripheral retinal photoreceptor function and is typical of phototoxicity. Amplitude of waveform responses increased after AVS surgery.

Conclusion This study reports how retinal AVS surgery may cause significant retinal photoreceptor phototoxicity, and lead to variations in subjective visual recovery despite angiographic improvement. We suggest techniques to reduce the intraoperative retinal photic exposure.

107

Commotio retinae determined by optical coherence tomography

PIERRE-KAHN VPK, MICHOUD NM, CEDDAH AC, BOURGES JLB, RENARD GR, CHAUVAUD DC
Ophthalmology, Hôpital Hôtel Dieu, Paris

Purpose To describe the OCT appearance in human acute commotio retinae.Optical coherence tomography (OCT) may be helpful to assess the in vivo retinal lesions of this maculopathy.

Methods Nine patients with unilateral acute commotion retinae were studied. Bilateral visual acuity, fundoscopy, cross-sectional and macular OCT mapping (Stratus OCT) were performed at presentation and one month later.

Results All traumatized eyes showed an initial whitening in the macular area. On OCT examinations, macular retinal thickness and foveal pit were preserved. The signal enhancement in the hyperreflective inner retinal band was constantly observed when compared to the fellow eye. In 3 cases, some subretinal fluid was observed. In 6 eyes, the fundus and the OCT abnormalities normalized in the first month. Three eyes, that initially showed subretinal fluid, developped macular pigmented scars and retinal atrophy.

Conclusion As a rule, the macular whitening normalizes in the mild form of commotio retinae (retinal concussion), whereas it usually precedes a pigmented scar in more sever conditions (retinal contusion). A fragmentation of the photoreceptor outer segments could explain the retinal whitening in animal models. This photoreceptors disruption could correspond to the transient signal enhancement of the hyperreflectivity in the inner retinal layer. The subretinal fluid may be an early sign of retinal contusion and could be considered as a bad prognostic factor since it led to retinal atrophic states. Conclusion: The OCT examination is an additional tool to enhance the understanding of this traumatic maculopathy and could help to provide some new prognostic factors.

108

Function of the visual system of patients treated with interferon alfa and ribavirin - The prospective study

POJDA-WILCZEK D (1), HERBA E (1), POJDA SM (1), PLECH AR (1), MAKOWIECKA-OBIDZINSKA K (1), ZATORSKA B (1), JEDRZEJEWSKI W (1), DZIAMBOR AP (2), STOLARZ W (2)
(1) Department of Ophthalmology and Eye Clinic Division Medical University of Silesia, Bytom
(2) Departament of Pulmonology and Tuberculosis, Clinic Division of Infectious Diseases Medical University of Silesia, Bytom

Purpose The aim of this study was to estimate the influence of interferon therapy on function of the visual system because some cases of retinopathy during this therapy were reported.

Methods 38 patients treated with interferon alfa and ribavirin because of chronic viral hepatitis C were examined. 17 of them have completed 12-months follow-up with second examination after first 3 months and the last one 1-2 months after the therapy was finished. We have examined: visual acuity, contrast sensitivity, mesoptometry, anterior segment and fundus of the eye, static central and peripheral visual field, intraocular pressure, pattern ERG, pattern VEP, EOG, flash ERG (ISCEV standards).

Results No change in visual acuity the anterior segment, fundus and IOP were observed, no patient complained of visual disturbances. All patients had normal scotopic vision in mesoptometry and better readaptation time in the last study. Increasing of the contrast sensitivity were noticed. MD in central visual field deepened in the second and third examination while MS was increased. In PERG P50 amplitude was lower in second as well as in third than in the first exam. In the last PVEP exam P100 amplitude was lower after stimulation of 14'. Photopic b-wave amplitude after flicker 30 Hz was lower in third than in the first examination. Arden ratio was significantly higher in second compared with first EOG.

Conclusion Interferon therapy may cause ganglion cells ischaemia and irreversible subclinical deterioration of their activity as well as cones' function especially in the macular region. Retinal pigment epithelium function may be temporary changed during interferon therapy.

EVER-2004-abstractbook.indd 19 8/19/04 12:25:46 PM

■ 109

Pulsatile Ocular Blood Flow in Asymmetric Age Related Related Macular Degeneration.

SANDHU R (1), CHONG V (2)
(1) Retinal Research Unit, King's College Hospital, London
(2) Retinal Research Unit, King's College Hospital; University of London, London

Purpose Ocular perfusion abnormalities have been proposed in the pathogenesis of age related macular degeneration (AMD). Various authors have found differences in pulsatile ocular blood flow (POBF) in eyes with asymmetric AMD. These studies were carried out in a Japanese population and the purpose of our study was to observe the differences in a Caucasian population.

Methods 48 patients with asymmetric AMD were included in this observational case series study. Patients with co-existent glaucoma, diabetic retinopathy, high myopia and veno-occlusive disease were excluded from the study. Axial length and POBF (µl/min) was measured in both eyes of subjects with asymmetric AMD in a sitting position using the Blood Flow Analyser. Statiscical analysis was carried out by the student T-test.

Results A total of 48 patients were subdivided into three groups with asymmetric AMD in each of the fellow eyes: POBF in Group 1 (21) with Drusen (1148.6 (SD 369.0) µl/min) and fellow eye with CNV (1153.2 (402.8) µl/min), p=0.437; Group 2 (19) with Drusen (988.1 (SD 333.7) µl/min) and fellow eye with disciform scar (1031.3 (436.7) µl/min), p=0.420; Group 3 (8) with CNV (933.4 (317.8) µl/min) and disciform scar (830.6 (333.5) µl/min), p=0.071. There was no statistically significant difference between the fellow eyes with asymmetric AMD in any of the groups in the Caucasian sample population.

Conclusion Previous studies suggested relevance of haemodynamic differences between fellow eyes in the development of CNV and formation of disciform scar. However, this was not confirmed by our study based on Caucasians. Patient demographics may play an important role in understanding the pathogenesis of AMD in relation to ocular perfusion abnormalities.

■ 110

Age-specific visual loss in eyes with early Age-Related Maculopathy

SJÖSTRAND JB (1), BERGMAN B (1), POPOVIC Z (2)
(1) Ophthalmology, Molndal
(2) Ophthalmolgy, Molndal

Purpose To investigate the change in visual acuity in eyes with early Age-Related Maculopathy (ARM) compared to eyes without clinical signs of any disease at 82 to 88 years.

Methods We used recently published population data of visual acuity (VA) in eyes with early AMR and no clinical signs of cataract (n=112) and in healthy eyes of subjects (n=40) at 82 and 88 years of age. Early ARM was diagnosed in eyes with the presence of any drusen type except hard and indistinct, and with pigmentary abnormalities (areas of increased retinal pigmentation or hypopigmentation), but no signs of late age-related maculopathy. An eye was defined as healthy when there were no clinical signs of disease. Loss of retinal ganglion cells or functional channels was predicted from changes of VA,assuming normal optical media, by using previously established relationships between cell separations in the retina and spatial resolution.

Results The percentage of eyes with visual impairment at 82 and 88 years of age (VA≤ 0.5) is increased in early ARM, 34% and 26% respectively, compared to a percentage of approximately 2% in healthy eyes. Correspondingly, our calculation indicates an additional loss of foveal cones in the early phase of ARM in addition to the cell loss occurring in ageing healthy eyes.

Conclusion Our study indicates that more focus should be given to the evaluation of age specific visual losses in eye diseases during ageing.

■ 111

Pulsatile Ocular Blood Flow Changes after Pan-retinal Photocoagulation and Macular Laser for Diabetic Retinopathy

SANDHU R (1), CHONG V (2)
(1) Retinal Research Unit, King's College Hospital, London
(2) Retinal Research Unit, King's College Hospital; University of London, London

Purpose To evaluate the change in pulsatile ocular blood flow (POBF) following laser therapy for proliferative diabetic retinopathy and clinically significant macular edema. The relationship of ocular blood flow and diabetic retinopathy has been studied in the past. Geyer and colleagues suggested that the POBF is initially decreased with the onset of diabetes when there is no diabetic retinopathy. Subsequently, the POBF increases with the severity of retinopathy. Recently, Krepler and colleagues found a reduction in ocular blood flow following vitrectomy for diabetic complications. It was not certain whether laser therapy had any influence on POBF.

Methods 28 eyes with proliferative diabetic retinopathy and 22 eyes with clinically significant macular edema receiving pan-retinal photocoagulation (PRP) and macular laser therapy respectively were included in the study. POBF was measured using Blood Flow Analyser at baseline, one month and three months following the respective laser treatment. Statistical analysis was carried out by student T-test.

Results In proliferative diabetic retinopathy, there was a statistically significant reduction of pulsatile ocular blood flow at 1 month (p=0.0005) and at 3 months (p=0.0000009) after laser treatment. In diabetic maculopathy, the reduction in pulsatile ocular blood flow at 4 months after macular laser was not statistically significant (p=0.3).

Conclusion The treatment benefit of PRP in patients with proliferative diabetic retinopathy may be related to the reduction in ocular blood flow.

■ 112

Cellular membrane content of occludin in an experimental model of diabetes

CARVALHO M, PROENÇA R
Ophthalmology Center-IBILI-University of Coimbra, Coimbra

Purpose To determine the vascular content of the tight junction protein occludin and to establish a correlation with the alterations of retinal vascular permeability in an experimental model of diabetes

Methods Experimental diabetes was induced in the Wistar rat by intraperitoneal injection of streptozotocin. Blood glycose and hemoglobin A1c levels were determined to assess the diabetic state (7 days and 1 month). Quantitative fluorescence microscopy was used to confirm the alteration of the retinal vascular permeability.The content of the tight junction protein occludin in the total cellular fraction and membranar cellular fraction was determined by immunoblotting of retinal lysates using a specific polyclonal antibody. The quantitative analysis of the overall cellular occludin content and of the cellular membrane occludin content was made and the values correlationated.

Results The overall occludin content decreased in the diabetic versus the control animals. This decreased is strongly accentuated after 7 days of diabetes.The cellular membrane content of occludin was significantly reduced after 7 days and 1 month of diabetes. The results point to a reduction of occludin in the cellular membrane and also an accentuated degradation of this protein in the cell after 7 days of diabetes. After 1 month of diabetes the low content of occludin in the cellular membrane remained but the overall cellular content reached the normal values problably due to an occludin synthesis in the cytoplasm to reestablish the cellular content of this protein.

Conclusion These results represent the important role of the transmenbrane protein occludin and of the tight junction structure in the disruption of the integrity of retinal vascular permeability.

EVER-2004-abstractbook.indd 20 8/19/04 12:25:46 PM

■ 113

Combined phacovitrectomy and intraocular lens implantation: Pertinent steps in maintaining optimal per-operative visualisation of the anterior retina and posterior pole.

MUGHAL S, HERO M
Paybody Eye Unit, Department of Ophthalmology, Coventry

Purpose There is limited detail on the operative principles in safe transition to phacovitrectomy. Intraoperative complications can be avoided if attention is paid to the following; maintenance of the anterior chamber depth, avoiding intraocular lens displacement, and maintaining optimal visualisation.

Methods A clear corneal incision was made with a 2.8 mm keratome and a 1.5 to 2.0 mm three-step corneal section was created. A small continuous circular capsulorrhexis (CCC) of 4.0 to 4.5 mm diameter was followed by a "divide and conquer" phacoemulsification technique and bimanual irrigation and aspiration of soft lens matter. The capsular bag was deepened with Viscoelastic (Viscoat) and a 6.5 mm 3-piece AcrySof foldable intraocular lens implant (IOL) (MA60BM, Alcon) was manipulated into the bag. The corneal section was sutured with a single 10-0 nylon suture prior to vitrectomy and Viscoat retained.

Results AC depth was maintained. Direct pressure on the globe during vitrectomy was avoided using a lid speculum and a non-contact visualisation system.IOL displacement was minimised by placing a large optic in the bag through a smaller capsulorrhexis that allowed better visualisation of the anterior retina and reduced optical prismatic effects from the IOL edge. Visualisation was dependent upon maintaining the AC. Initially; one patient had a collapsed AC that was reformed with intracameral Viscoat.

Conclusion Macular hole can be treated safely by combining pars plana vitrectomy with phacoemulsification and IOL implantation. Pertinent initial steps are the construction of the corneal incision, a smaller capsulorrhexis and implantation of a large optic.

■ 114

High Speed Indocyanine Green Angiography Guided Laser Treatment For Idiopathic Polypoidal Choroidal Vasculopathy; An Interventional Case Series.

LAUDE A (1), DJATIKUSUMO A (2), LEE JJ (2), NAH GKM (2), LIM TH (2)
(1) The Eye Institue@Tan Tock Seng Hospital, Singapore
(2) The Eye Institute@Tan Tock Seng Hospital, Singapore

Purpose To report the clinical features and treatment outcome of idiopathic polypoidal choroidal vasculopathy (IPCV) using high speed indocyanine green angiography (ICGA) guided laser treatment.

Methods Clinical features of 11 eyes with IPCV were evaluated with high speed ICGA using a confocal scanning laser ophthalmoscope. All were treated using a green (532nm) dye laser. The laser treatment targets were either the polypoidal lesions (if located outside the foveal avascular zone), feeder vessels or both. Six patients had focal laser alone, 3 had feeder vessel treatment alone and 2 had both. Snellen visual acuity, optical coherence tomography, fundal photography and angiographic changes were evaluated.

Results Eight eyes (72.7%) obtained visual acuity improvement, 2 eyes (18.2%) showed no change and 1 eye (9.1%) had a reduction of 1 line on the Snellen chart. Ten eyes (90.9%) showed closure of the IPCV angiographically post laser. Seven eyes (63.6%) showed resolution of the presenting fundal features like haemorrhage, pigment epithelial detachment or oedema. The mean follow up after laser treatment was 3.8 months (2-7 months).

Conclusion In this small case series with short follow up, high speed ICGA guided laser treatment of IPCV appears to be safe and efficacious. Larger study with longer follow up is warranted.

■ 115

Didanosine induced retinopathy in adults: an observational case series

ANDERSON OA, FERNANDO FI, PURI P, DAVIES NP, MITCHELL SM
Chelsea and Westminster Hospital, London

Purpose Didanosine is a purine analogue used in the treatment of human immunodeficiency virus disease. Didanosine has been associated with pancreatitis, peripheral neuropathy and retinopathy. The retinopathy has been classically attributed to irreversible RPE loss accompanied by partial loss of choriocapillaris and neurosensory retina in the mid periphery. It has been reported before in children. There are very few reports in adults. We present six cases of didanosine induced retinopathy in adult patients on HAART therapy.

Methods An observational case series.

Results All patients had mid-peripheral pigmentary retinal changes of varying degrees of severity. Symptoms varied from asymptomatic to difficulty seeing at night. Markedly constricted visual fields were noted in those patients with affected night vision. Electrophysiology was performed in the severely affected patients. This showed generalized retinal dysfunction affecting the rods to a greater extent than the cones.

Conclusion DDI induced retinopathy which has been previously reported in children is also prevalent in adults.

■ 116

Secretory phospholipase A2-IB in the human retina

KOLKO M (1), PRAUSE JU (1), HEEGAARD S (1), BAZAN NG (2)
(1) Eye Pathology Institute, University of Copenhagen, Copenhagen
(2) Neuroscience Center and Department of Ophthalmology, Louisiana State University, New Orleans

Purpose Low-molecular-weight phospholipases A2 (sPLA2) are a subgroup of PLA2, which are secreted, bind to receptors, and may act as intracellular signalling modulators. At least ten different groups have been characterized in mammals and there is expanding evidence on the significance of sPLA2 in neuronal signalling and survival. sPLA2 activity has been measured in the retina, and we have resently cloned and characterized subgroups of sPLA2s in the rat retina. To date no sPLA2s have been cloned and/or characterized in the human retina. The purpose of the present study was to explore the presence and location of sPLA2-IB in the human retina.

Methods Primers were designed to identify sPLA2-IB in the human retina by PCR. The product were confirmed by sequencing and used for in situ hybridization. Antibodies against sPLA2-IB were designed and western blotting as well as immunohistochemical staining was performed.

Results The obtained results provide the first evidence of the existence of genes encoding sPLA2-IB as well as sPLA2-IB protein expression in the human retina. sPLA2-IB was most abundantly expressed in the retinal pigment epithelial cells, the photoreceptor inner segments and in the ganglion cells. We revealed co-localization of the neuronal specific marker NeuN and sPLA2-IB whereas no co-localization was found between sPLA2-IB and the glial specific marker, GFAP.

Conclusion This study reveals for the first time the presence of a specific sPLA2 in the human retina. We conclude that the widespread expression of sPLA2-IB in the human retina may indicate a role of this enzyme as an intercellular signaling modulator that could turn out to be significant both in retinal cell function and in retinal degeneration.

EVER-2004-abstractbook.indd 21 8/19/04 12:25:47 PM

117
Measuring macular pigment optical density with undilated pupil in one second

VAN NORREN D (1, 2), VAN DE KRAATS J (3), BERENDSCHOT TTJM (4)
(1) UMC Utrecht, Opthalmology, AZU 03.136, Utrecht
(2) TNO Human Factors, Soesterberg, the Netherlands
(3) UMC Utrecht, Ophtalmology, Utrecht
(4) UMC Utrecht, Ophthalmology, Utrecht

Purpose To built an apparatus that enables fast, objective assessment of the density of the macular pigment in the undilated eye. Macular pigment possibly protects against age related macular degeneration. Its density can be manipulated by nutritional factors.

Methods A beam of white light is send into the eye, and returned from a 1 degree retinal area to an exit pupil. The exit beam leads to a commercial fiber optic spectrometer. A crucial element in the design is sqeezing entrance and exit pupil, with a certain separation, through a 3 mm pupil. The subject fixates the middle of a bright white spot. Spectral fundus reflectance is analysed with a model of the pathways of light in the eye. This results in a parameter for the optical density of macular pigment.

Results Reproducible optical density of macular pigment was be obtained in subjects up to 78 years. The actual measurement takes one second; the total procedure takes less than 5 minutes.

Conclusion We succeeded in building an instrument for fast and reliable assessment of macular pigment. The apparatus holds great promises for epidemiological research.

118
Autofluorescence

GONZALVEZ BG, SARMENTO AS, MOUILLON MM

Purpose Our research work shows some selected aspects from fundus infra-red autofluorescence and compares them with some images from late fluorescein or indocyanine green angiography (30 minutes), thus it also compares them with some aspects of blue ligth autofluorescence.

Methods We use a digital TOPCON camera to obtain our images. The infra-red autofluorescence image is obtained through the use of exciter filters infra-red of 810 nm wavelength, the blue light autofluorescence images are obtained with the fluorescein exciters and barrier filters of 532 nm wavelength. All images are obtained from a prospective study that aims analyze and compare all the information based on exudation aspects, disease evolution and etiology from Age-related Macular Degeneration (AMD), inflammatory diseases and heredodegenetative diseases.

Results Autofluorescence would allow in vivo analyzes of lipofuscin and other fluorophores accumulation and degradation and would also become an interesting marker of oxydative activity, as a predictor in AMD. In the others degenerative and inflammatory diseases it could allow a noninvasive therapeutic and an evolutive complementary follow-up.

Conclusion Much of the aspects remains critical to analyze because a better knowledge of the fluorophores' dynamics, spatial distribution and expression still necessary. To confirm the new predictive and diagnostic prospects and the noninvasive follow up that it seems to bring, these images should become systematic on the same basis that the ones with green, blue and red filters.

119
Macular pigment shows ring like structures

BERENDSCHOT TTJM, VAN NORREN D
UMC Utrecht, Ophthalmology, AZU E03.136, Utrecht

Purpose To study spatial distribution of the macular pigment optical density.

Methods Fundus reflectance and autofluorescence maps at 488 and 514 nm Argon laser wavelengths were acquired in 53 healthy subjects with a custom-built Scanning Laser Ophthalmoscope. Since the lens and the macular pigment are the only absorbers in this wavelength region, digital subtraction of log reflectance and log autofluorescence provides density maps of the sum of both absorbers.

Results Mean optical density of the macular pigment in the central 0.5° was identical for the reflectance and for the autofluorescence method. Modeling a 4° field centered at the fovea with a Gaussian distribution we again found similar amplitudes and widths for both methods. Yet, in about half of the subjects a distinct ring pattern was observed at a mean distance of 0.9° of the fovea. Therefore, a better description was given by an exponential decaying density as a function of eccentricity and in addition a Gaussian distributed ring pattern. The prominence of this ring pattern seems not to depend on parameters like age, gender, smoking or diet.

Conclusion Both reflectance and autofluorescence maps show similar ring patterns in the distribution of the macular pigment.

120
Macular pigment optical density is independent of age

BERENDSCHOT TTJM, VAN NORREN D
UMC Utrecht, Ophthalmology, AZU E03.136, Utrecht

Purpose To study possible age dependency of the macular pigment optical density (MPOD).

Methods We used five different methods to arrive at MPOD estimates in 53 healthy subjects. Spectral fundus reflectance of the fovea was measured with a fundus reflectometer and analyzed with a detailed optical model. This reflectometer also allowed the determination of the amplitude of the directional component of the fundus reflectance. Spectral analysis of this amplitude provided a second MPOD estimate. Reflectance and autofluorescence maps were made with a Scanning Laser Ophthalmoscope. Digital subtraction of maps at 514 nm and 488 nm and comparison between the foveal area and 8 degree temporal site provided another two MPOD estimates. Psychophysical estimates were obtained with heterochromatic flicker photometry comparing foveal and 5 degree temporal sensitivity.

Results All objective techniques showed no age dependence. Only the psychophysical method showed a small, but significant decline with age. All methods correlated significantly with each other.

Conclusion MPOD appears to be independent of age.

EVER-2004-abstractbook.indd 22 8/19/04 12:25:47 PM

■ 121 / 1154

Qualitative and Quantitative Comparison Of Autofluorescence And Color Images of Eyes withDrusen And Age Related Macular Degeneration

SIVAGNANAVEL V (1), SMITH RT (2), CHAN J (2), FITZKE F (3), WEBSTER AR (4, 5), JENKINS SA (4), CHONG NV (1)
(1) Kings College Hospital, London
(2) Department of Ophthalmology, Columbia University, New York
(3) Institute of Ophthalmology, London
(4) Moorfields Eye Hospital, London
(5) Institute of Ophthalmology, London, England

Purpose To determine the degree of concordance between autofluorescence patterns and drusen distribution in eyes with drusen.

Methods Thirty consecutive patients with significant drusen were selected from those persons recruited to the UK-MRCage-related macular degeneration collection. Matlab and Adobe software was used to resize and overlay corresponding points between colour (Topcon) and autofluresecence SLO images (Zeiss). Independent graders from Columbia University and King's College Hospital used macular background levelling software to quantify the percentage of drusen in the middle Wisconsin subfields, using both color and autofluorescence images

Results There was considerable variability in the extent of autofluoresence between eyes. Direct visual comparison did not identify a pattern of autofluorescent foci which matched the drusen determined on color imaging. When subgroup analysis was performed according to disease phenotype (eyes with bilateral drusen, drusen in one eye and choroidal neovascularization or geographic atrophy in the fellow eye), a similar discordance in autofluorescence and color imaging was seen. Correlation measures were calculated for the quantity of color and autofluorescent variation for all images

Conclusion The exact relevance of drusen in AMD remains uncertain with regard to a role as a disease marker or causal relationship. Progression of disease is widely accepted to correlate to increase in drusen load. The distinct patterns of drusen and retinal autofluroescence at the macula suggest the preservation of function of those RPE cells overlying drusen in age-related macular disease.

■ 122

Mechanisms controlling permeability and junctional architecture of primary retinal endothelial cells in vitro

OCKRIM ZK (1, 2), HYKIN P (2), TUROWSKI P (3), GREENWOOD J (3)
(1) Institiute of Ophthalmology, London
(2) Moorfields Eye Hospital, London
(3) Institute of Ophthalmology, London

Purpose Elevated levels of vascular endothelial growth factor (VEGF) can be detected in the vitreous of patients with diabetic macular oedema. VEGF is an angiogenic growth factor and is thought to be central in the induction of diabetic macular oedema. Indeed, exposure of vascular endothelial cells in vitro to VEGF has been shown to increase their permeability. Inter-cellular adherens and tight junctions are key components controlling paracellular permeability of endothelial beds. In the present study we have investigated how VEGF treatment affected the temporal and spatial organisation of inter-cellular junctions.

Methods Primary microvascular endothelial cell cultures were established from rat retinae (RMEC) and subcellular localisation of junctional proteins determined using indirect immunofluorescence. Their subcellular localisation was also determined following treatment with VEGF alone and in combination with various drugs specifically interfering with intra-cellular signalling pathways.

Results Cadherin and catenins, components of adherens junctions, as well as the tight junctional proteins occludin, claudin-5 and ZO-1 were all found predominantly at the inter-cellular junctions. VEGF treatment affected the subcellular distribution of many junctional proteins: it induced either their disappearance or their redistribution to the cytoplasm. The effect of various inhibitors of cellular pathways was also determined.

Conclusion Our work suggests that VEGF might contribute to the pathogenesis of diabetic macular oedema by negatively regulating the intracellular junctions of the retinal endothelium. Understanding underlying signalling mechanisms may open novel therapeutic avenues.

■ 123

Absorption of diode 810 nm TTT laser by blood in vitro

MUNOZ MORALES AM
Ophtalmology, Seville

Purpose To quantify the in vitro energy attenuation by blood of the diode 810 nm TTT laser.

Methods The spot size of the laser was adjusted until a power sensor (0,5 microns). Pasteur pipettes were filled with different dissolutions of blood from the author (hematocrit 38,2%): 1, 1/2, 1/4, 1/8;and were placed in the path of a laser light from the slit lamp to the power sensor to approximate the location of an eye being treated.The absorption of laser light was measured in air,glass,distilled water and blood (each of the four dissolutions). All measurements were based on the mean of six readings and were made with six energies:100,200,300,400,500 and 1000 mW.

Results The power sensor reading for the pipettes filled with blood (mean+/- standard deviation) were:

	1	1/2	1/4	1/8
100	15,33+/-2,52	18,0+/-11,53	21,20+/-1,73	31,78+/-0,84
200	17,81+/-2,4	27,11+/-1,90	41,53+/-2,30	63,85+/-0,89
300	29,58+/-3,22	51,88+/-0,79	70,03+/-0,87	97,61+/-0,88
400	38,91+/-2,36	71,13+/-0,83	95,60+/-1,07	152,33+/-3,92
500	40,73+/-2,23	87,96+/-1,28	129,5+/-2,15	180,33+/-3
1000	64,66+/-3,05	240+/-2,88	265,33+/-2,23	381,83+/-2,12

The mean percent of transmission of the diode 810 nm TTT laser in each medium was:

	Air	Glass	Water	Blood 1	Blood 1/2	Blood 1/4	Blood 1/8
M % Transmission	95,57	74,85	79,08	9,73	18,03	23,60	34,75

The mean percent of absorption due only to blood was: 65,12 (1); 56,82 (1/2); 51,25 (1/4); 40,10 (1/8).

Conclusion The effect of the 810 nm diode laser diminishes when blood concentration and energy increase.Blood significantly reduce it.Avoiding subrretinal blood is a key factor for success in the treatment of subrretinal membranes.

■ 124

Heme oxygenase-1 response to diabetes, hyperglycemia and oxidative stress in retinas and endothelial cells

AVELEIRA CA, LEAL EC, CASTILHO A, SERRA A, AMBRÓSIO AF
Center of Ophthalmology of Coimbra, IBILI, Coimbra

Purpose Oxidative stress is believed to play a significant role in the development of diabetic retinopathy. Since the expression of heme oxygenase-1 (HO-1), a protective enzyme, may be induced by stress conditions, we investigated the effect of hyperglycemia and oxidative stress on the HO-1 immunoreactivity in retinal endothelial cells. We also studied the expression of HO-1 in retinas of diabetic rats.

Methods Rat retinal capillary endothelial cells (TR-iBRB2 cell line) were exposed to high concentrations of D-glucose (30 mM) or mannitol, the osmotic control, for 7 days. The cells were also exposed in a time-dependent manner (1, 3, 6, 12 and 24h) to D-glucose, H2O2 and NOC-18, a NO donor. Diabetes was induced in male Wistar rats with streptozotocin (60 mg/kg) and retinas were harvested after 1 week or 1 month. HO-1 immunoreactivity was evaluated by Western blot analysis.

Results Chronic hyperglycemia (7 days) did not alter HO-1 protein levels in endothelial cells, but its content increased with shorter periods (12 h). Also, H2O2 and NOC-18 significantly increased the protein immunoreactivity of HO-1 in a time-dependent manner. In whole retinas, the HO-1 protein levels did not change 7 days after inducing diabetes, but significantly decreased after 1 month.

Conclusion These results show that the protein levels of HO-1 increase in retinal endothelial cells exposed to hyperglycemia or oxidative stress, suggesting the existence of a protective response. However, in longer periods of hyperglycemia, or diabetes, the HO-1 levels do not change or even decrease, suggesting that the protective response may be only temporary or that the antioxidative defence may be compromised.

EVER-2004-abstractbook.indd 23 8/19/04 12:25:48 PM

■ 125

Visual prognosis in pseudovitelliform degeneration: A longitudinal study

FERNANDO A (1), PURI P (2), TALBOT JF (2)
(1) Chelsea & Westminster Hospital, London
(2) Royal Hallamshire Hospital, Sheffield

Purpose Pseudovitelliform degeneration a rare condition usually associated with a good visual prognosis can occasionally be associated with severe visual loss. A longitudinal study was therefore performed to determine the long-term visual prognosis in these patients.

Methods 37 eyes of 20 patients who were diagnosed as having pseudovitelliform degeneration were followed up for a period varying from 1 year to 11 years. A record of the best-corrected visual acuity was made on every visit. A colour fundus photograph, fundus fluorescein angiogram and OCT were performed at the out set and repeated if there was either a significant clinical or visual deterioration.

Results 20 patients 5 males and 15 females aged 46- 84 years who were followed for upto 11 years were included in the study. The best corrected Snellen acuity at presentation was 6/6 or better:6 eyes, between 6/6 and 6/12:20 eyes, between 6/12 and 6/24:10 eyes and worse than 6/24 in 2 eyes. Slit lamp biomicroscopy revealed a sub retinal deposit of yellowish material in the macular area , which was confirmed by colour fundus photography,fundus fluorescein angiography and OCT. Visual acuity remained stable in 33 eyes however deteriorated in 5 eyes.Analysis of various risk factors revealed that an earlier presentation and a longer duration of disease were associcated an increased visual loss. Poor visual acuity at presentation and a longer follow up were the other risk factors.

Conclusion Pseudovitelliform degeneration is a rare ocular presentation, which is usually associated with good visual prognosis, however is am important cause of slow but progressive visual loss with over half of the patients losing two or more lines of Snellen acuity over a mean follow-up of 4 years.

■ 126 / 1356

Photodynamic Therapy for Subfoveal Choroidal Neovascularization Secondary to Vogt-Koyanagi-Harada Syndrome

NOWILATY SR, BOUHAIMED M, ABBOUD EB, KAHTANI E, DHIBI H, AL-HARTHI E, JOHNSTON M, AL ROBAIE M, BANTAN I
Vitreoretinal Division, King Khaled Eye Specialist Hospital, Riyadh

Purpose To assess the effects of photodynamic therapy (PDT) with Verteporfin in the treatment of subfoveal choroidal neovascularization (CNV) secondary to Vogt-Koyanagi-Harada syndrome (VKH).

Methods Six eyes of 6 patients with VKH who developed subfoveal CNV underwent standard PDT. Repeated treatments were performed at 3-month intervals for persistent leakage. The charts and angiographic data were analysed retrospectively.

Results All patients were young (17 -27 years). Five CNV lesions were recent and classic (greatest lesion diameter 1100-3100 microns). One CNV was chronic and partially scarred. Mean visual acuity at presentation was 20/200. Five patients had more than one year follow-up.Five eyes had active inflammation. Of these, three required one PDT. The final CNV scar was smaller/stable with improvement of VA by one line in two eyes. The third developed a larger CNV scar with loss of 2 lines of VA. Submacular fibrosis developed in all three. In eye #4, mild CNV leakage persisted after one PDT, but hazy media precluded a second PDT. At 15 months the CNV scar and VA were stable. The fifth case, with mild inflammation, required three PDTs. The CNV leakage continued but was minimal. The lesion became smaller and VA improved. One eye without inflammation needed two PDT sessions to halt the CNV leakage. The final lesion was smaller and vision was stable. There were no PDT-related complications.

Conclusion Photodynamic therapy with Verteporfin appears to be a safe and viable treatment option for subfoveal CNV secondary to VKH, offering a chance for stabilization or even improvement of vision. Further study is warranted.

■ 127

Effects of Photodynamic Therapy in the use of microscopes in patients with choroidal neovascularization secondary to pathological myopia and classic age-related macular degeneration

SOBRADO-CALVO P (1, 2), GÓMEZ-RAMÍREZ AM (1, 2), VARGAS-MARTÍN F (3), VILLEGAS-PÉREZ MP (1, 2), MIRALLES DE IMPERIAL J (1, 2)
(1) Departamento de Oftalmología. Universidad de Murcia, Murcia
(2) Hospital General Universitario, Murcia
(3) Departamento de Física- área de Óptica. Universidad de Murcia, Murcia

Purpose To analyse the effects of photodynamic therapy (PDT) on vision through microscopes (MS) in patients with subfoveal choroidal neovascularization (CNV) secondary to pathological myopia and classic age-related macular degeneration.

Methods Sixteen eyes of 12 patients with pathological myopia and 9 eyes of 9 patients with classic CNV secondary to ARMD were selected for PDT with Verteporfin. The best corrected visual acuity (BCVA) and the visual acutiy with MS (MSVA) were assessed in all patients just before the treatment and 3 months after PDT, using a Keeler-A chart.

Results Group of pathological myopia: three months after PDT BCVA increased in 59% of the patients, and decreased in 6% of them. MS increased the near VA in almost all patients before PDT; after PDT MSVA was higher in 17,5% of the patients, while 65% of the patients maintained their MSVA. Group of classic ARMD: three months after PDT the BCVA increased in 37,5% of the patients, and decreased in 62,5%. MS increased the VA in almost all patients before PDT; after PDT, MSVA was higher in 25% of the patients, while 50% of them maintained their MSVA. These results are very similar to those obatined in these patients for far distance (our data not published), although the far VA with aids was better than the near VA with aids after PDT in the group of patients with CNV secondary to pathological myopia.

Conclusion Microscopes improve the near visual acuity of patients with subfoveal CNV secondary to pathological myopia and classic ARMD before and after PDT; PDT increase the near VA through MS in a percentage of patients.

■ 128

Photodynamic Therapy using Verteporfin for juxtafoveal choroidal neovascularisation in Angioid Streaks associated with Pseudoxanthoma elasticum

CHUNG AKK (1), GALIBA V (1), GHANCHI FD (2)
(1) Leeds General Infirmary, Leeds
(2) Bradford Royal Infirmary, Bradford

Purpose To report the 40 months follow up results of Angioid Streaks associated choroidal new vessels (CNV) treated with Photodynamic Therapy (PDT) using Verteporfin

Methods A 55 year-old Caucasian man with Pseudoxanthoma elasticum, previously diagnosed of having untreatable occult CNV secondary to Angioid streaks in his left eye, was found to have developed fovea splitting classic CNV in his right eye during routine ophthalmic examination. The presenting Sellen visual acuities were 6/24 (55 letters on ETDRS visual acuity chart & contrast sensitivity at 1.05) in his right eye and 6/60 in his left eye. Argon laser photocoagulation was carefully contemplated but was later ruled out in favour of PDT, in view of the location of the CNV. A standard PDT with Verteporfin was performed on his right eye per TAP criteria. A laser size of 2400um wa used. No adverse effect was noted during or after treatment. He was followed up every 3 months. His visual acuity (ETDRS chart) & contrast sensitivity was measured in each visit. In addition, Fundus fluorescein angiography was performed to detect the extent of leakage from CNV.

Results The patient has had 8 sessions of PDT over 40 months. The visual acuity in his right eye has remained stable at 58 letters and contrast sensitivity improved to 1.45. There was no leakage on his latest fundus fluorescein angiogram.

Conclusion Our case is the only case report with long-termed data (40 months) in a patient with Angioid streak associated CNV, treated with PDT using Verteporfin. PDT can be used to reduce severe visual loss in patients with sight-threatening CNV associated with Angioid streaks.

EVER-2004-abstractbook.indd 24 8/19/04 12:25:49 PM

■ 129

Peripapillar neovacularisation during Tamoxifen treatment

HERA R, TONINI M, MOUILLON M, ROMANET JP
Ophthalmology, Grenoble

Purpose Ocular side effects have already beeen described in tamoxifen therapy. We report for the first time the case of a patient who developped during tamoxifen treatment peripapillar neovascularisation associated with inner retinal crystalline deposition.

Methods A 72 years old woman receveing tamoxifen as an adjuvant postoperative treatment for breast cancer,report during the tratement a visual acuity loss in right eye. Fluorescein and ICG angiographic examination showed peripapillar neovascularisation associated with macular oedema and retinal crystalline deposition. Direct photocoagulation was performed and few months later the tamoxifen treatment was stopped.

Results Visual acuity improved , macular oedema and crystalline deposition decreased, while angiographic findings of neovascularisation desappeared.

Conclusion To our knowledge, this is the first case of neovascularisation reported during tamoxifen treatment. Is this a side effect of tamoxifen therapy, or is this an independant pathology such as age related macular degeneration?

■ 130

Evolution of retinal thickness in a two year follow up of nonproliferative retinopathy in type 2 Diabetes

DUARTE L (1), FIGUEIRA J (2), BERNARDES RC (1), NUNES S (1), LOBO C (1), CUNHA-VAZ JG (1)
(1) AIBILI, Coimbra
(2) Department of Ophthalmology of University's Hospital, Coimbra

Purpose To characterize retinal thickness progression in the initial stages of retinal disease in Diabetes type 2.

Methods Thirty seven eyes of 37 patients with mild nonproliferative retinopathy classified by 7 field stereoscopic fundus photography (levels 10, 20 and 35 of Wisconsin grading), were examined 5 times at six-months intervals using a retinal thickness analyzer (RTA – Talia) and vitreous fluorometry. Measurements of retinal thickness were performed in the foveal area or covering a large portion of the macula. Comparison with a normal reference population was made taking into account the value of maximal and area of retinal thickness increase.

Results The eyes were analyzed in to main groups taking into account the duration of their diabetes. There were 12 eyes of 12 patients with diabetes of more than 10 years of duration (mean 12,2 ± 2,4), where marked increases in retinal thickness were registered in 9 eyes. Of these, 8 (89%) showed stabilized increase in retinal thickness throughout the follow-up period. There were 25 eyes of 25 patients with diabetes of less than 10 years duration (mean 5,6 ± 2,5). Of these, 21 eyes showed marked increase in retinal thickness in at least one visit during the follow-up. The increases in retinal thickness were stable in only 9 eyes and reversible in 12 eyes. In this group, the isolated increases in retinal thickness were associated with increases in fluorescein leakage either in the same or previous visits.

Conclusion Stable increases in retinal thickness were seen mostly in eyes with longer duration of diabetes, whereas isolated and reversible increases were seen in eyes with shorter duration of diabetes.

■ 131

High TGF-β2 levels during primary retinal detachment may protect against proliferative vitreoretinopathy

DIEUDONNE SC (1), LA HEIJ EC (1), DIEDEREN R (1, 2), KESSELS A (3), LIEM A (1), KIJLSTRA A (1), HENDRIKSE F (1)
(1) Ophthalmology, Maastricht
(2) Basic Neuroscience, Maastricht
(3) Clinical Epidemiology and Medical Technology Assessment, Maastricht

Purpose Transforming growth factor-β2 (TGF-β2) and hepatocyte growth factor (HGF) have been implicated in the pathogenesis of proliferative vitreoretinopathy (PVR) after retinal detachment surgery. The exact role of these factors immediately following primary retinal detachment is not yet known and was therefore the purpose of this study.

Methods Subretinal fluids were collected prospectively during scleral buckling surgery from 144 patients. TGF-β2 and HGF were measured using commercially available ELISA kits. Thirty patients who developed postoperative PVR were compared with 114 patients with an uncomplicated retinal detachment. Controls included eighteen vitreous samples from patients with macular holes or puckers. Multivariate regression analysis was used to compare the relative roles of growth factors and clinical factors in the development of PVR.

Results The median amount of subretinal TGF-β2 was approximately two times lower in patients with postoperative PVR (1.9 ng/ml) than in the uncomplicated group (3.3 ng/ml) ($p = 0.002$). TGF-β2 levels in the PVR-positive group were similar to control vitreous levels (1.8 ng/ml). Subretinal HGF concentrations were not significantly different between the two patient groups (PVR positive: 8.8; PVR negative: 8.9 ng/ml), but were higher than control vitreous levels (4.6 ng/ml) ($p = 0.01$). Stepwise multivariate logistic regression analysis revealed that of all factors under study, decreased TGF-β2 was the exclusive predictor of postoperative PVR ($p = 0.01$).

Conclusion High TGF-β2 levels in subretinal fluid at the time of primary retinal detachment may protect a patient against subsequent development of PVR.

■ 132

Preventive effect of subretinal injections of hRPE on synaptic relay in RCS rats

PINILLA I (1, 2), SALIVÉ Y (1), CUENCA N (1, 3), WANG S (1), LU B (1), LUND RD (1)
(1) Department of Ophthalmology. Moran Eye Center, Salt Lake City
(2) Servicio de Oftalmologia. Hospital Universitario Miguel Servet, Zaragoza
(3) Departamento de Biotecnologia. Universidad de Alicante, Alicante

Purpose To evaluate the preventive effect of hRPE transplants on outer plexiform layer (OPL) synapses and to correlate the findings with retinal function.

Methods Six treated RCS rats were studied, together with unoperated and non-dystrophic controls. Treated rats received subretinal injections of a human RPE cell line (ARPE19) at P22; all animals were maintained on oral cyclosporine immunosuppression. ERG was recorded at P59 and rats were sacrificed at P90 or P120. The OPL was studied immunohystochemically.

Results In normal rats, bassoon stains rod terminals as single punctate spots, which are paired with rod bipolar receptor sites stained with mGluR6: cone terminals are paired with mGluR6-positive postsynaptic disks on on-cone bipolar cells. During the course of degeneration, the rod and paired bipolar puncti are quickly lost: the cone synaptic patterns stained with bassoon/mGluR6 become disorganised. In areas of retina preserved by the injected cells, the normal organisation was preserved with evident rod terminal/bipolar pairing and clear cone synaptic sites. The level of connectivity was related to the degree of photoreceptor survival and the number of synapses decreased with increasing distance from the injected cells area. Bipolar cells were well organized in the area of maximum rescue with relatively normal dendritic branching. ERG recordings showed at best both a-and b-waves being preserved, albeit of lower amplitude than normal. The magnitude of the ERG response was usually a good predictor of the level of anatomical preservation.

Conclusion ARPE19 transplants in RCS rats are able to maintain not only normal cell morphology, but also detailed substrates of connectivity in the OPL.

EVER-2004-abstractbook.indd 25 8/19/04 12:25:49 PM

■ 133

Userfriendly software for the automated mosaic reconstruction of fundus digital retinography

GAVET Y (1, 2), PEYROCHE C (1, 3), DEB-JOARDAR N (1), THURET G (1), DINET E (3), GAIN P (1)
(1) EA3063 Lab 'Cell survival and adherence', Faculty of Medicine, Saint-Etienne
(2) Ecole Nationale Supérieure des Mines de Saint-Etienne, Saint-Etienne
(3) Institut Supérieur des Technologies Avancées de Saint-Etienne, Saint-Etienne

Purpose To develop a registration software for fundus images taken by digital nonmydriatic retinograph to compute the fundus mosaic

Methods We developed a cross-platform software (for Linux and Windows) in C++, using the libraries Insight ToolKit to load and to analyse the images and Visualisation ToolKit to display them. The user interface has been designed with Fast Light ToolKit. The algorithm used was based on mathematical morphology operations to isolate the retinal vessels, extract the points common to the different images and compute the registration. It was designed to deal with a large number of image types and function independently from any particular retinograph trade mark

Results Our software was simple and user friendly. The fundus mosaic computation was reliable, timesaving and the operator rarely had to adjust the images position

Conclusion Our software generates in a few seconds a fundus mosaic. This should improve the assessment of screening parameters of retinal pathologies, especially diabetic retinopathy

■ 134

Erythropoiethyn plasma expression in diabetic retinopaty preliminary report

DE SOUZA RAMALHO P (1, 2), PEREIRA DA SILVA A (2), THIRAN C (2), FONTES G (2), BICHO MM (2)
(1) Ophtalmology, University Medical College, Lisbon
(2) Genetics Laboratory and Metabolic Centre, University Medical College, Lisbon

Purpose Erithropoiethin (EPO), stimulates the formation, proliferation and differenciation of erythrocytes. EPO also mediates neuroprotection by binding to its transmembrane receptors (EPOR) in the brain and in the eye (retina). EPO is up-regulated in the ischemic retina and in the vitreous. It also assists neuronal survival in the retinal cultures at low glucose concentrations with important implication of retinal cell apoptosis in diabetic retinopathy.Objectives: To study EPO plasma levels in type 2 diabetics with and without retinopathy.

Methods In 36 type 2 diabetics under medication, 14 with and 22 without retinopathy, with mean age of 66.44±7.59, 15 females and 21 males, EPO levels (mIU/ml) in the plasma were measured using ELISA and compared to 41 non diabetic controls age and sex matched. Student test was used.

Results Plasma EPO levels were varied in diabetics (1.462 to 44.979) with a tendency towards higher levels in diabetics compared to non diabetic controls (12.067±9.416 vs 9.47±6.574) p=0.151. It was also high (not significant) in diabetic patients having retinopathy (14,003±13,106 without (10,835±6,111) p=0.332.

Conclusion Erythropoietin appears up-regulated in diabetic population studied suggesting a possible ischemia induced erythropoietin expression which could indicate an attempt to attenuate or protect ischemic induced apotposis. This preconditioning mechanism may not be present equally in all the patients. Further studies are needed to understand the implication of erythropoietin in this complex process of diabetic retinopathy.

■ 135

Helicobacter pylori and retinal vein occlusion

VOIGT M, LE TIEN V, GLACET-BERNARD A, ZOURDANI A, COSCAS G, SOUBRANE G
CHI Créteil, Paris

Purpose Helicobacter pylori infection is very frequent. Its implication in gastric ulcers and cancer is well known. Recently Helicobacter pylori was shown to be implicated in other pathological conditions such as cardiovascular diseases and in ophthalmology in conditions like glaucoma. The study aim was to analyze a possible implication of Helicobacter pylori in the occurrence of retinal vein occlusion.

Methods 32 patients, who were hospitalized for a treatment by hemodilution for central retinal vein occlusion or retinal venous branch occlusion, were tested for serology with Helicobacter Pylori between January 2002 and April 2004. Other parameters were also noted: presence of factors of vascular risk, initial and final vision, angiographic monitoring for observation of the ischemic and oedematous components.

Results In this study we found a prevalence of Helicobacter pylori of 47%. This appeared to be statistically significantly higher than the average prevalence in the French population (25.4%, $p<0.01$). Analyzed by age periods (40-49, 50-59, >60) the prevalence of Helicobacter pylori was not any more significantly different to the control groups. Interestingly we could observe different clinical outcome between the positive and negative groups.

Conclusion Though not statistically significantly different in its prevalence it appears that a possible Helicobacter pylori infection could play a role in the outcome of the treatment retinal vein occlusion. We noticed a significant tendency towards an ischemic evolution in patients, which were Helicobacter pylori positive in comparison to patients that were Helicobacter pylori negative.

■ 136

Multiple retinal hemangioma-like lesions in retinitis pigmentosa

PENAS S (1), CARNEIRO A (1, 2), VALVERDE J (2), MARTINHO R (1, 2), FALCÃO-REIS F (1)
(1) Department of Ophthalmology, University of Porto School of Medicine, São João Hospital, Porto
(2) Department of Ophthalmology, Private Portuguese Hospitals-HPP, Porto

Purpose To report an unusual case of a patient with retinitis pigmentosa (RP) presenting unilateral multiple retinal hemangioma-like lesions.

Methods Complete ophthalmological examination, ultrasonography and fluorescein angiography.

Results A 37 year-old male with RP and no significant medical or family history presented a visual acuity of 6/10 in both eyes, pale optic discs, retinal vascular narrowing, depigmentation of the retinal pigment epithelium (RPE) and a bone-spicule pigment pattern in the mid-peripheral zone of both retinas. In a regular ophthalmology consultation a vascular mass with approximately 4DD, surrounded by lipid exudation, was detected in the infero-nasal periphery of his right eye. The ultrasonography revealed an acoustically solid retinal mass with a smooth anterior border but predominantly medium reflectivity suggesting a vascular pattern. The fluorescein angiogram showed a rapidly filling lesion, with dilated afferent and efferent retinal vessels and diffuse leakage in the middle and late frames, suggestive of retinal capillary hemangioma. No similar lesions were detected in the other eye. This lesion was successfully treated with laser photocoagulation but six months later a new similar lesion developed in the temporal periphery of the same eye.

Conclusion A bilateral exudative retinopathy has been associated with approximately 1–4% of cases of longstanding RP. The cause is still unknown but it may be the result of a vasodilatory response to toxic products of photoreceptor/RPE degeneration. Early detection and treatment can prevent severe visual loss. Our case is unusual in that lesions are multiple and unilateral unlike almost all previous reported cases refering to bilateral presentations.

EVER-2004-abstractbook.indd 26 8/19/04 12:25:50 PM

■ 137

Level of antibodies against retinal antigens in AMD patients

MISIUK HOJLO MH (1), JUROWSKA-LIPUT JJL (1), AGOPSOWICZ KA (1), BIALEK-SZYMANSKA ABS (1), GORCZYCA WG (2), KUROPATWA MK (2), WITKOWSKA DW (2)

(1) Ophthalmology Department, Medical University, Wroclaw

(2) L. Hirszfeld Institute of Immunology and Experimental Therapy, Polish Academy of Sciences, Wroclaw

Purpose The purpose of this researche was to estimate level of antibodies against retinal antigens in AMD patients.

Methods Serum samples were obtained from 46 AMD patients (35 females and 11 males, 53- 84 years old, average 72,6). In all patients examination of visual acuity, ophthalmoscopy and fluorescein angiography were performed. Sera in standard dilution (1:100) were evaluated for the presence of antibodies against soluble retinal antigens (retAgs) using immunoblot analysis. Serum samples obtained from 10 healthy volunteers were used as controls.

Results In the group of 46 examinated AMD serum samples, 30 were positive (65,2%). It means, that in 25 (54,3%) females and 5 (10,9%) males immunoblot analysis detected the presence of antibodies against soluble retinal antigens. The most intensive and frequent reaction (in more than half of cases) was observed with enolase and arrestin. The numbers of sera positively reacting with those antigens were significantly higher in the AMD patients than in the control sera. Moreover, the average intensity of the reaction with other retinal proteins (30 kD, 37 kD, 43 kD 50 kD, 51 kD, 52 kD, 54 kD, 56 kD, 58 kD, 64 kD, 72 kD, 96 kD protein) was also significantly higher in AMD sera.

Conclusion Enolase and arrestin were the most reactive retinal antigens in AMD patients. Reactivity was significantly higher in AMD group in comparsion with healthy control individuals. Detection of antibodies against soluble retinal antigens could be one of the risk factors for AMD.

■ 138

Verteporfin therapy for subfoveal choroidal neovascularization in pathologic myopia

GOMEZ-RAMIREZ AM, MARTÍNEZ-MORALES JA, SOBRADO-CALVO P, VILLEGAS-PÉREZ MP, MIRALLES DE IMPERIAL J

Hospital General Universitario, Dpto. Oftalmología, Universidad de Murcia, Murcia

Purpose To analyze the visual results of photodynamic therapy (PDT) with verteporfin in pathologic myopia with subfoveal choroidal neovascularization (CNV)

Methods Forty-seven eyes from 39 patients were treated with PDT and followed between 9 and 21 months. The pre-treatment best corrected visual acuity (BCVA) was 0.11+-0.15 (mean±SEM; range:0.005-0.5). Thus, all patients had a BCVA equal or inferior to 0.5 and complied with the other requirements of the VIP study. The patients were followed every three months and retreated when necessary

Results BCVA was 0.16±0.21 (range: 0.005-0.95) 3 months after the first treatment (n=47), 0.15±0.19 (range: 0.005-0.95) 6 months alter the first treatment, and 0.18±0.22 (range: 0.005-0.975) 9 months after the first treatment (n=47). At these three following periods, BCVA was significantly higher than the BCVA pre-treatment. BCVA was 0.15±0.21 (range:0.01-0.8), 0.13±0.18 (range:0.01-0.85) and 0.17±0.19 (range:0.01-0.5), at 12 (n=31), 15 (n=31) and 18 months (n=13) after the first treatment, respectively. There were no significant differences between the BCVA at these three following periods and the pre-treatment BCVA. Twenty one months after the first treatment, however, the BCVA increased significantly to 0.22±0.19 (range:0.01-0.5)(n=10). The mean number of treatments per patient during the first year was 2.5±0.6 (range:1-4; n=31). A trend was observed for the younger (<55 years) patients to show better results

Conclusion In patients with pathologic miopia and subfofeal CNV, PDT increases BCVA during 9 months and maintains it during at least the 21 months of the study.

■ 139

The management of retinal detachment in adult aphakes who have had congenital cataract surgery

MUGHAL S, HEGDE V, AL-HUSAINI S, HERO M

Paybody Eye Unit, Department of Ophthalmology, Coventry

Purpose To demonstrate the augmentative role of endotamponade with silicon oil (SO) in reducing the risk of re-detachment following primary retinal detachment repair.

Methods A retrospective review was performed on 3 patients aged 32-42 years with retinal detachment following congenital cataract surgery that was performed from the ages of 4 months to 2 years. One patient had a superior giant retinal tear with no macular involvement and 2 patients presented with bulluos retinal detachment with subretinal fluid (SRF) affecting the anatomical macula. All underwent pars plan vitrectomy, 3600 endolaser and encirclement. The two retinal detachment patients had inferior (1800) explant. SO endotamponade was used in the surgical procedure for the giant retinal tear case and for one of the retinal detachment cases. The other which was our first case of this case series had pneumatic endotamponade with C3F8 (perfluoropropane).

Results Supero-temporal horse-shoe tears were observed in the retinal detachment cases. The patient that had a partial gas fill with 10% C3F8 developed an infero-temporal retinal re-detachment 2-weeks following the primary repair. An identifiable break was not seen. This was successfully managed by internal drainage of sub-retinal fluid and endotamponade with SO. In all subsequent cases, we elected to use SO for endotamponade. Anatomical success was maintained in all 3 patients at the time of discharge.

Conclusion Retinal detachments can behave unpredictably in patients who have undergone congenital cataract surgery. We believe that SO provides more effective internal tamponade as opposed to gas.

■ 140 / 1256

Reinjection Rates of Intravitreal Triamcinolone

YILMAZ G, GEDIK S, AKKOYLIN I, AKOVA Y

Baskent University Faculty of Medicine, Department of Ophthalmology, Ankara

Purpose To determine the indications and reapplying rates of intravitreal 'triamcinolone acetonide' (TA) injections and to assess the causes of repeating the injection procedures.

Methods The records of 150 patients who were treated with intravitreal TA (4mg/0.1ml) injections were evaluated retrospectively. Pre- and post injection visual acuities, intraocular pressure (IOP) measurements and fundus fluorescein angiography (FFA) findings were recorded. The TA injection indications and number of reinjections per eye were analyzed.

Results Ninety women, 60 men total of 150 patients with a mean age and follow-up period of 65 years and nine months, respectively, were enrolled into the study. The distribution of TA injections were as follows: 121 eyes of 97 patients for refractory diabetic macular edema (Group I); 30 eyes of 30 patients for macular edema due to retinal vein occlusions (Group II); 11 eyes of 11 patients for pseudophakic cystoid macular edema (Group III), 14 eyes of 12 patients for uveitic macular edema (Group IV). A total of 145 injections have been carried out for 121 diabetic eyes; 33 injections for group II; 14 injections for group III and 16 injections for group IV. The reinjections rates were 19.8% in group I, 10% in group II, 27.2% in group III and 14.2% in group IV.

Conclusion Intravitreal TA may be effectively used in many ocular conditions like refractory diabetic macular edema, pseudophakic cystoid macular edema, retinal vein occlusions and chronic cystoid macular edema associated with uveitis. Pseudophakic cystoid macular edema is the most refractory disorder among these disorders.

EVER-2004-abstractbook.indd 27 8/19/04 12:25:50 PM

■ 141

Intravitreal triamcinolone acetonide for treatment of intraocular proliferative, exudative and angiogenic diseases.

JONAS JB, KREISSIG I, DEGENRING RF
Department of Ophthalmology, Faculty for Clinical Medicine Mannheim, Ruprecht-Karls-University, Heidelberg

Purpose Within the last three years, triamcinolone acetonide has increasingly been applied intravitreally as treatment option for various intraocular neovascular and edematous proliferative disorders. Purpose of this study is to report on the results obtained after more than 750 intravitreal injections (IVTA) for various reasons such as diabetic macular edema, uveitis and exudative age-related macular degeneration.

Methods Under topical anesthesia, 20 to 25 mg triamcinolone acetonide were injected transconjunctivally into the vitreous cavity.

Results The best response in terms of gain in visual acuity after theintravitreal injection of triamcinolone acetonide was found in eyes withintraretinal edematous diseases such as diffuse diabetic macular edema,branch retinal vein occlusion, central retinal vein occlusion, andpseudophakic cystoid macular edema. Visual acuity increased and degree ofintraocular inflammation decreased in eyes with various types ofnon-infectious uveitis including sympathetic ophthalmia. Intravitrealtriamcinolone was useful as angiostatic therapy in eyes with irisneovascularisation and proliferative ischemic retinopathies. In eyes withchronic, therapy resistant, ocular hypotony, intravitreal triamcinoloneinduced an increase in intraocular pressure. The complications ofintravitreal triamcinolone therapy included secondary ocular hypertension inabout 40% of the eyes injected, cataractogenesis, postoperative infectious and non-infectious endophthalmitis, and pseudo-endophthalmitis. Intravitreal triamcinolone injection was combined with other intraocular surgeries including cataract surgery. Cataract surgery performed some months after the injection did not show a markedly elevated rate of complications. If visionincreases and eventually decreases again after an intravitreal triamcinolone acetonide injection, the injection was repeated. The duration of the effect of a single intravitreal injection of triamcinolone ranged between 2 and 9 months.

Conclusion IVTA may be a therapeurtical option for some intraocular edematous and neovascular diseases.

■ 142

Retinal circulation in diabetic retinopathy before and after panretinal photocoagulation

OKANO T, MATSUNO K
Dept. of Ophthalmology, Tokyo Medical University Kasumigaura Hospital, Ibaraki, Japan

Purpose This study was performed to reveal the therapeutic effects of panretinal photocoagulation (PRP) to retardation of retinal circulation in advanced diabetic retinopathy. We investigated the effects of PRP on the velocity of retinal circulation in proliferative diabetic retinopathy.

Methods The velocity of retinal circulation in diabetic eyes was evaluated by means of rapid serial fluorescein angiopathy (FAG), employing scanning laser ophthalmoscope (SLO). FAG was conducted at the rate of 30 frames per seconds with a SLO (Rodenstok) in video-tape following injection of 5ml of 10% fluorescein sodium into the antecubital vein. Disc-to-macula transit time (DMTT) was defined as the time interval between the initial appearance of dye bolus in the central retinal artery and the moment of initial dye filling in the parafoveal capillaries.The DMTT in advanced diabetic retinopathy was measured before and after PRP. Normal 30 eyes were used as control and diabetic 12 eyes with proliferative diabetic retinopathy before photocoagulation were evaluated. These diabetic subjects progressed until the stage when the PRP was necessary. They were examined to measure the DMTT before and after PRP. Results: Mean DMTT decreased from 9.4±2.1 seconds before PRP to 6.5±1.6 seconds after PRP in 12 diabetic eyes ($p<0.05$). DMTT before and after PRP were significantly longer than mean DMTT in 30 normal eyes (3.7±0.7 seconds;$p<0.01$). The DMTT in diabetic eyes with improvement after PRP was significantly shorter than that before PRP.

Conclusion Retinal hemodynamics are retarded in diabetic eyes with retinopathy. The retardation of retinal circulation in diabetic retinopathy after effective PRP improves significantly. But the value after PRP can not recover until the control level.

■ 143

Ultrastructural retinal changes in an experimental model of hypercholesterolemia. Variations after normalization of cholesterol blood values induced by a normal diet.

SALAZAR JJ, RAMÍREZ AI, DE HOZ R, ROJAS B, TRIVIñO A, RAMÍREZ JM
Instituto Investigaciones Oftalmológicas Ramón Castroviejo. UCM, Madrid

Purpose To evaluate (a) ultrastructural changes in the retinal layers in an experimental model of hypercholesterolemia and (b) modifications induced by a period of normal cholesterol blood values induced by a normal diet.

Methods Rabbits were administered a cholesterol enriched diet for eleven months (Group-1: 10 n) and thereafter a normal diet for 6 months (Group-2: 10 n). A third group of 10 rabbits was used as control. The retinas were processed using transmission electron microscopy.

Results 1) Group-1: Degeneration of RPE cells through build-up of lipids. Disappearance of photoreceptors by necrosis and apoptosis. Disorganization of the internal nuclear layer by apoptosis. Apoptosis and necrosis in the ganglion cell layer. Degeneration in the optic nerve fiber layer (ONFL), leaving spaces empty of axonal tissue. Hyperactive astrocytes and Müller cells, with the nuclei of some Müller cells shifting to the ONFL. Müller cells filled some spaces left by dead retinal neurons. Epiretinal vessels presented thickening of the basement membrane, inclusions of electron-dense bodies, hypertrophy of the smooth muscle cells and increased collagen in the adventitia. 2) Group-2: Attenuation of RPE changes. Persistence of the alterations observed in the hypercholesterolemic phase in all retinal layers and on epiretinal vessels. The Müller glia filled up the gaps left by the disappearance of neurons in the various different layers of the retina.

Conclusion After normalization of the cholesterol blood values induced by a normal diet, retinal changes persisted as a consequence of chronic ischemia induced by vascular changes.

■ 144

Ultrastructural choroidal changes in an experimental model of hypercholesterolemia. Variations after normalization of cholesterol blood values induced by a normal diet.

RAMIREZ AI, SALAZAR JJ, ROJAS B, DE HOZ R, TRIVIñO A, RAMÍREZ JM
Instituto Investigaciones Oftalmológicas Ramón Castroviejo. UCM, Madrid

Purpose To evaluate (a) ultrastructural changes in the choroidal layers in an experimental model of hypercholesterolemia and (b) modifications induced by a period of normal cholesterol blood values induced by a normal diet.

Methods Rabbits were administered a cholesterol enriched diet for eleven months (group 1: 10 animals) and thereafter a normal diet for 6 months (group 2: 10 animals). A third group of 10 rabbits was used as control. The retinas were processed using transmission electron microscopy (TEM).

Results 1) Group 1: There were large accumulations of cholesterol in the suprachoroid, compressing the vascular layers including the choriocapillary layer. Foam-cells surrounded by fibroblasts, collagen and cholesterol crystals were observed in all layers. Overall, the basal membrane of the vessels was thickened, presenting vacuoles and electron-dense inclusions in their interior. The endothelial cells of the choriocapillary layer presented rarefactions in the cytoplasm. Bruch's membrane was thickened. 2) Group 2: Reduction of suprachoroid lipids with partial recovery of vascular lumen in the choroidal layers. General persistence of: a) thickening of the basal membrane; b) hypertrophy of the endothelial cells; c) increase of collagen fibres in the intervascular spaces. Reduced thickness of Bruch's membrane, basically at the expense of the internal collagen, where electron-lucent bodies tended to disappear.

Conclusion After normalization of the cholesterol blood values induced by a normal diet, chronic ischemia continued due to the persistence of choroidal changes affecting vessels and extracellular matrix.

EVER-2004-abstractbook.indd 28 8/19/04 12:25:51 PM

■ 145

Classification of Choroidal Neovascular Membrane Type in Age-Related Macular Degeneration using Optical Coherence Tomography - 3

KHAN AJ, HUGHES EH, PATEL N, KASHANI S, CHONG NV
Kings College Hospital, London

Purpose Choroidal neovascularisation (CNV) in age-related macular degeneration (AMD) results in severe visual loss. CNV are subdivided into classic and occult based on their appearance on fluorescein angiography (FFA). Although FFA remains the diagnostic method of choice, it is invasive and does not show the anatomical location of the CNV. Furthermore, in some cases, the distinction of the classic and occult component in a mixed lesion can be difficult. We have evaluated the potential of using non-invasive optical coherence tomography (Carl Zeiss Stratus OCT-3) to identify whether there are differences in appearances between classic and occult CNV.

Methods 23 patients with acute CNV underwent fluorescein angiography and optical coherence tomography (OCT), which were analysed by separate blinded observers.

Results In 87.5% of angiographically labelled 'classic' CNV a discreet sub-retinal lesion corresponding to the neovascular complex could be seen above and separate to the retinal pigment epithelium on OCT. This was found in only 12.5% of 'occult' CNV.

Conclusion The improved resolution of this latest OCT imaging system has allowed us to describe features that characterise certain differences between classic and occult CNV. OCT-3 imaging may be a useful adjunct to FFA in the diagnosis and classification of CNV type in AMD as well as confirming the previously held belief that classic CNV tends to occupy the sub-retinal space. The potential benefits also include a useful diagnostic tool in cases where FFA may be equivocal.

■ 146

Mitochondrial-DNA Control Region analysis in Diabetic Retinopathy

ABECIA E (1), PEIRÓ F (2), MARTÍNEZ-JARRETA B (2)
(1) Department of Ophthalmology. Hospital Miguel Servet, Zaragoza
(2) Department of Legal Medicine. University of Zaragoza, Zaragoza

Purpose Mitochondria have long been known to participate in the process of cell injury associated with metabolic failure. Only recently, however, have we come to appreciate the role of mitochondria as primary intracellular targets in the initiation of cell dysfunction. MtDNA quantitative and qualitative changes in blood samples from diabetic patients have been reported. These changes have been assocciated to the duration of the disease and to the presence of complications.Furthermore, mtDNA control region has shown to be very higly hypervariable and therefore very useful in human identification studies.The aim of this study is to assess a possible association between polymorphic sites of the mtDNA control region and diabetic retinopathy.

Methods Peripheral blood samples from 80 type I and type II diabetic patients were collected. MtDNA was obtained and isolated following international protocols.The Control Region was analysed by dividing it into four sub-regions (HVIa, HVIb, HVIIa y HVIIb), which were amplified directly. In other cases they were amplified by means of semi-nested PCR. They were subsequently sequenced in a MegaBACE 500 capillary sequencer with marked terminators. Mitosearch program was used to carried out the comparison between the individual sequences for the mtDNA control region.

Results No statistically significant differences were found comparing mtDNA control region from type I and type II diabetic patients to healthy Causasian individuals from the same geographic area (Aragon, Nort-East Spain).

Conclusion Better understanding of the molecular mechanisms and genetics of mitochondrial bioenergetics will help us to the prediction, prevention, diagnosis, and treatment of diabetic tissue injury.

■ 147

Retinitis pigmentosa with Coats-like exudative vasculopathy - a case report

FARKAS Á (1), VáMOS R (1), BESCH D (2), SALACZ G (1)
(1) 2nd Department of Ophthalmology, Budapest
(2) University Eye Hospital Dept. II., Tübingen

Purpose To present a retinitis pigmentosa case with advanced Coats-like exudative vasculopathy and to underline the importance of the early diagnosis and the difficulties of the differential diagnosis.

Methods A 27-year-old woman with known retinitis pigmentosa came to our department complaining of severe bilateral deterioration of vision. According to an ophthalmological report made 2 years earlier, her visual acuity was 0.9 in the right eye and 0.8 in the left eye. Visual acuity and visual fields were checked and biomicroscopy of the anterior and posterior segments, fluorescence angiography, electroretinography and ultrasonography were carried out. Complex internal and neurological examinations (including MRI of the brain) were also done.

Results Visual acuity: hand movements in the right eye and finger counting at a distance of 10 cm in the left eye. The anterior segments of both eyes were normal. On the fundi pale optic nerve head, pigment granules over the retina, big areas of retinal and subretinal exudates with overlying teleangiectasia and serous retinal detachment were seen in both eyes. Ultrasonography showed residual vitreous hemorrhage in the right eye. Neither internal nor neurological disorders were found.

Conclusion Retinitis pigmentosa in association with Coats-like vascular abnormalities is a severe condition and difficulties in the differential diagnosis may occure. Young patients with retinitis pigmentosa need regular follow-up for the early detection of any kind of vascular abnormalities.

■ 148

Retinal and pupillary function recovery in severe ocular siderosis

PENAS S, ROCHA-SOUSA A, CAPÃO-FILIPE JA, FALCÃO-REIS F
Department of Ophthalmology, University of Porto School of Medicine, São João Hospital, Porto

Purpose To analyse prospectively the retinal and pupillary function in a patient with ocular siderosis.

Methods Prospective evaluation of a patient with serial complete ophthalmological examinations including visual acuity (VA) determination, biomicroscopy of the anterior segment, tonometry, fundoscopy, pupillometry, pattern evoked visual potencials (PEVP) (60' check board), electroretinogram (ERG) and electroculogram (EOG) (ISCEV Standards), before and after the removal of an IOFB. The follow-up is of 6 months.

Results A 17 year-old male patient with an iron-containing IOFB in his right eye presented, 3 months after the injury, pupillary mydriasis, iron deposition on the corneal endothelium and anterior capsule, cataract, peripheral clumping of the retinal pigment epithelium and a peripheral inferior retinal detachment. The best-corrected VA in the affected eye was 7/10. The ERG showed a completely extinguished cone and rod responses and the pupillometry presented a mydriatic pupil (initial diameter ID- 6.9mm) slightly responsive to light stimulation (minimum diameter MD- 6.7mm; constriction velocity CV- 1.8mm/seg). Six months after the surgical removal of the IOFB the VA was 5/10, the ERG showed a partial recovery to within 20% of the normal limit in both cone and rod response and the PEVP recovered to 40 % of the fellow eye. An increase in pupillary function was detected by pupillometry (ID- 5.9mm, MD- 5.6mm, CV- 3.2mm/seg).

Conclusion Although it has been accepted that a b-wave amplitude reduction beyond 50-75% of the other eye strongly indicated an irreversible damage, in this case we show a partial functional recovery of the retinal and pupillary function.

EVER-2004-abstractbook.indd 29 8/19/04 12:25:52 PM

■ 149

Screening of diabetic retinopathy by digital retinograph: advantages of pharmacological dilatation

DEB N (1), THURET G (1), GAVET Y (2), MANOLI P (1), GARCIN A (1), GERMAIN N (3), MILLOT L (3), ESTOUR B (3), GAIN P (1)
(1) Ophthalmology dpt, University Hospital, Saint-Etienne
(2) Ecole Nationale Supérieure des Mines de Saint-Etienne, Saint-Etienne
(3) Endocrinology dpt, University Hospital, Saint-Etienne

Purpose The screening of diabetic retinopathy (DR) by digital retinograph is catching up in France. A hospital clinical research trial aims to compare the reliability of screening by specially trained endocrinologists (E) vs that of ophthalmologists (O). The screening without pharmacological pupillary dilatation met with several hurdles: 1/ the prolonged stay of patients in darkness for physiological mydriasis disturbed the day-hospitalization normal course; 2/ the quality of screening by E seemed affected by the poor image quality. Aim: To compare the feasibility and the quality of screening according to the dilatation mode

Methods Training of the E: 40 hours of theory and practice on DR and incidental findings. 150 diabetic patients had 5 field photography per eye and mosaic construction (Topcon TRC NRW6S), first after a 10 min obscuration, then after 1 drop of tropicamide. The 2x300 sets of images were graded independently by 2 E and 2 O

Results Patients aged 59±15 yrs had a 15±12 yrs evolution of diabetes. Pharmacological mydriasis showed definite improvement of the image quality with a/ an increased number of sets with 5 'good' images (159 vs 7/300, p<0.001) b/ an improved mosaic quality (good: 232 vs 99/300, p<0.001; uninterpretable: 4 vs 21/300, p<0.001) c/ suppression of the flash-induced miosis in the second eye. All these helped in better identification of DR, maculopathy and incidental findings (+20, +112, +29% of true positive respectively, p<0,001 each). It allowed a gain of 7-8 mins/patient, did not hinder hospital functioning nor create any side effect

Conclusion In view of the benefits, we decided to perform routine pharmacological mydriatic screening in our clinical research trial

■ 150

Intravitreal Triamcinolone Acetonide in eyes with macular edema associated with central retinal vein occlusion

GIRAUD JMG, RIGAL-SASTOURNÉ JCRS, OUBAAZ AO, RENARD JPR, MAURIN JFM
Hôpital d'Instruction des Armées du Val de Grâce, Paris

Purpose To evaluate the treatement of macular edema associated with central retinal vein occlusion (CRVO) with intravitreal injections of triamcinolone acetonide. Prospective case serie study.

Methods 3 eyes of 3 patients with long standing CRVO (3-6 month) and visual acuity <1/10 or worse.Following baseline evaluation were done : best corrected vision, slit lamp examination, intra ocular pressure, fluorescein angiography, OCT.Triamcinolone acetonide (15mg/0.1ml) was injected into the vitreous cavity under topical anesthesia.

Results After a mean duration of 7 month, all patients demonstrated a reduction of macular edema with corresponding improvement of OCT images.Mean best corrected visual acuity improved (# 2 lines) at follow up six month.

Conclusion Intravitreal triamcinolone acetonide is an effective treatment and reduce central macular edema after CRVO.

■ 151

Vitreal glutamate concentration in rabbits after intravitreous injection of air, balanced saline solution, sulfur hexafluoride gas and perfluorocarbon liquid

VIEIRA DE SOUZA N, VIEIRA DE SOUZA E, AIHARA T, COUTINHO NETO J
Faculdade de Medicina, Dept. of ophthalmology, Ribeirao Preto

Purpose The purpose of the present study was to determine glutamate vitreal concentration after intravitreous air, balanced saline solution (BSS), sulfur hexafluoride gas (SF6), and perfluorocarbon liquid (PFCL) injection to rabbit eyes

Methods Third seven eyes from twenty tree New Zealand albino rabbits were divided into five groups: Air (7 eyes), BSS (7 eyes), SF6 (4 eyes), PFCL (5 eyes), control (14 eyes). After the introduction of a needle into the sclera, 3 mm from the limbus, the vitreous was aspirated (0.3 ml). Air, BSS, SF6 gas 100% and PFCL (0.3 ml) were injected into rabbit vitreous cavity. Fourteen eyes were used as control, six without sclerotomy and 8 with sclerotomy without substance injection. After three weeks the vitreous was aspirated (1,0 ml) from all eyes and submitted to biochemical analysis by High Performance Liquid Chromatography (HPLC) for excitatory amino acids detection, especially glutamate.

Results The eyes submitted to PFCL and SF6 injection showed a greater L-glutamate increase in the vitreous compared to air, BSS and control groups (p< 0.05). Histological results confirmed small changes on SF6 group and important lesions on PFCL group, such as external photoreceptor segment disruption, external and internal plexiform layer thinning, ganglionar and internal nuclear layer decrease of nucleus number, edema, and presence of macrophages in the superficial layers. No major histological changes were observed on air, BSS and control with sclerotomy groups.

Conclusion Sulfur hexafluoride gas (SF6) and perfluorocarbon liquid (PFCL) intravitreous injection induces increase of the excitatory amino acid glutamate concentration in the vitreous body.

■ 152

Human macular pigment distribution from hyperspectral imaging of the fundus

BAPTISTA AMG (1), NASCIMENTO SMC (1), FOSTER DH (2)
(1) Department of Physics, University of Minho, Braga
(2) Visual & Computational Neuroscience Group, University of Manchester Institute of Science and Technology, Manchester

Purpose The purpose of this work was to estimate the spatial extent of macular pigment in human retinas by hyperspectral imaging of the fundus with high spatial and spectral resolution.

Methods An indirect ophthalmoscope linked to a hyperspectral illuminating system was used to obtain images of the fundus. An area of the retina of about 15 deg was illuminated by light from a xenon lamp coupled with a fast tuneable liquid-crystal filter (VariSpec, VS-VIS2-10-HC-35-SQ, Cambridge Research & Instrumentation) with a bandwidth of 10 nm and peak wavelengths in the range 450–530 nm. Spectral images of the fundus were acquired with a low-noise Peltier-cooled digital camera (Hamamatsu, model C4742-95-12ER,) with a spatial resolution of 1344x1024 pixels and 12-bit output. The optical system for image acquisition was such that each individual pixel element corresponded to approximately 2 arcminutes visual angle. Total acquisition time was approximately 15 s. The retinas of ten healthy subjects were analysed and the area corresponding to the macular pigment was estimated in each case by comparing the reflectance spectra at the pixels in the fovea with those in the parafovea.

Results The spatial extent of the macular pigment varied with the observer and was in agreement with values reported in the literature.

Conclusion The technique provides a fast and efficient method of estimating the extent of macular pigment and may be useful in detecting retinal pathology.

EVER-2004-abstractbook.indd 30 8/19/04 12:25:52 PM

153

Auto-ophthalmoscopy: Looking at one's own retina

ARMOUR R H
Surgery, Lister Hospital, Stevenage, Hertfordshire

Purpose An investigation of auto-ophthalmoscopy. Can anyone learn it? What are its practical uses?

Methods Equipment and technique (shown in Figs 1 and 2). Two plane mirrors and a direct ophthalmoscope were used. One eye examines the other. The pupils were not dilated.Personal experience. Over 6000 examinations since 28 August 2001.Pilot study. 24 people tried auto-ophthalmoscopy informally.

Results Personal observations. The optic fundi up to the equator of the eye were studied and watercolour drawings made (shown in Fig 3). Microaneurysms due to Type II diabetes are shown. An extravascular crystal in the left macula that reflects light in 2-6 week cycles is under observation.Pilot study. 12 out of the 24 participants succeeded in seeing their retinal vessels.

Conclusion Can anyone learn it? Half the participants were successful, including two who had not used an ophthalmoscope before. Success was usually related to the amount of time spent trying.What are its practical uses? Auto-ophthalmoscopy allows one to study the retina in detail without troubling patients. It could help those students and doctors who wish to become poficient at retinal examination and who can learn the technique. It is also a research pointer. Thus the intermittent reflection of light by the above-mentioned crystal might imply subtle retinal movements. Coincidentally, the technique proved to be a sensitive method for testing the quality of ophthalmoscopes. Finally, it is strangely fascinating to look directly at ones own retina. A senior ophthlamologist, who tried the author's method, described the view as a "spiritual experience".

154 / 1166

Highly reflective cells in the stroma of diabetic patients visualized by in vivo confocal microscopy

QUADRADO MJ (1), POPPER M (1, 2), MORGADO AM (3), VAN BEST J (1), MURTA JN (1), MÜLLER LJ (4)
(1) Institute of Biomedical Research on Light and Image, Department of Ophthalmology, Coimbra University, Coimbra
(2) 1st Department of Ophthalmology, Semmelweis University, Budapest
(3) Department of Physics, Coimbra University, Coimbra
(4) The Netherlands Ophthalmic Research Institute, Amsterdam

Purpose While examining the corneal stroma of diabetic patients with in vivo confocal microscopy (IVCM) some images showed highly reflective cells with a tail. We have focused our attention on these specific structures.

Methods Four diabetic patients (NIDDM grade 20 ETDRS, age 53y to 69y) and four healthy controls (age 35y to 65y) from a previous study were further analysed. The number of highly reflective cells (HRC) found in the stroma was counted using registered images obtained by IVCM (Tomey Confoscan P4). The results were statistically analysed using the Mann-Whitney test.

Results Structures consisting of a highly reflective head and a vague tail (straight or undulated) were found mainly in anterior and mid-stroma of patients and controls. These are usually observed near the stromal nerves and are rare in the posterior stroma. The total number of HRC across stromal depth in diabetic patients was significantly higher 52.5 ± 9.25 (mean ± SD) than that in healthy controls 5.25 ± 1.5 (P=0.029). The average length and width of a HRC is 20.0 ± 3.4 µm and 18.7 ± 2.8 µm, and those of keratocyte nuclei 27.2 ± 4.6µm and 9.5 ± 1.3µm (N=30). The difference between both lengths and widths is significant ($p<0.0005$). Furthermore, undulated structures in dimensions similar to large stromal nerves were also observed in the diabetic patients. Interestingly enough, they were oriented parallel to and not as, the stromal nerves, oblique to the ocular surface.

Conclusion HRC is a new structure in the mid-upper stroma and seems to be specific for diabetic patients, since its density is significantly higher than that in controls. Currently, these cells cannot be classified and need further investigation.

155 / 1167

Corneal involvement in pseudoexfoliation syndrome

SKINNER KC, SRINIVAS HV, GREGORY PTS
Conquest, Hastings

Purpose Reporting an unusual deposit of pseudoexfoliation material on the cornea and review of keratopathy in pseudoexfoliation syndrome (PXF). Small flakes are known to be deposited on the endothelium. However, our patient had a solitary large deposit which has not been reported before. To emphasise the recognition of corneal involvement when considering intraocular surgery and mydriasis as they may precipitate corneal oedema.

Methods Case Report

Results An 83 year old lady attended the glaucoma clinic for a follow up. She had pseudoexfoliative material deposition on the lens and in the trabecular meshwork. She also had a solitary large lumpy deposit on the endothelium which was noted nine years earlier. There were no signs of intraocular foreign body or other corneal pathology and she had not undergone any intra ocular surgery.

Conclusion Here, the nature of the deposit is most likely to be pseudoexfoliation material as she had other signs of PXF and there was no other intraocular pathology. We could only make a presumptive diagnosis as examination of corneal button is necessary for a definitive diagnosis. Techniques like immumohistochemical, histopathological, biochemical and molecular biological techniques have helped in understanding the pathogenesis. The extent of endothelial loss due to corneal involvment is thought to be 21% with normal IOP and an additional 14% with a rise in IOP. As mydriasis can increase intraocular pressure in these patients, pupils should be dilated with caution. So also the intraocular surgeries.Corneal invovement in PXF has only recently been recognised. These small flaky deposits can be easily mistaken for keratic precipitates. This case reports of a large solitary deposit which can not be mistaken.

156 / 1265

Bioadhesives to seal corneal lacerations

ABAD M, MULET ME, SANCHEZ A, SCORSETTI D, ALIÓ JL
VISSUM Instituto Oftalmológico de Alicante , R&D, Alicante

Purpose To study the efficacy and the clinical and histological corneal biotolerance of different bioadhesives.

Methods We carried out an "in vitro" study on animal eyes of different bioadhesives with an acrylic or biological base. 150 µm lamellar keratectomy was performed with Moria I microkeratome and the corneal lamella was sealed with different bioadhesives. We evaluated effectiveness, speed and hardness of polimerization and corneal transparency.We made an "in vivo" study on Albino New Zealand rabbits (4 eyes per group) evaluating corneal biotolerance (inflammation reaction, neovascularization, opacification) and histological findings. We performed a 5mm intrastromal dissection with Melles spatula and microsclerotome and injected 0.10 mm of the different adhesives: n-butyl cyanoacrylate (Histoacryl®, Tisuacryl®), n-butyl cyanoacrylate ethyl cyanoacetate, n-butyl cyanoacrylate dihexyl maleate and fibrin adhesive (tissucol®)3 months follow up.

Results The bioadhesives from greatest to least in terms of degree of hardness, speed of polimerization and corneal opacity were: Histoacryl®- n-butyl cyanoacrylate dihexyl maleate - n-butyl cyanoacrylate ethyl cyanoacetate, Tisuacryl®- tissucol®.Efficacy: All were effective except fibrin adhesive.Inflammatory reaction: Severe: Histoacryl® and n-butyl cyanoacrylate dihexyl maleate and n-butyl cyanoacrylate ethyl cyanoacetate. Mild: Tisuacryl® and Minimal/no reaction: fibrin adhesives.Histological findings: Presence of edema, fibroblast activation, new vessel formation and remains of bioadhesives.

Conclusion Acrylic bioadhesives can be an effective alternative to sutures for corneal lamellar sealing. Corneal opacification may be produced by different compounds of the bioadhesive mixture. We need more experimental studies to determine the bioadhesive that can substitute traditional sutures in lamellar keratoplasty.

EVER-2004-abstractbook.indd 31 8/19/04 12:25:53 PM

157 / 1266

Corneal epithelial cell homeostasis in organ culture

SOLTANINIA J (1), ARMITAGE WJ (2), BOULTON M (1), ALBON J (1)
(1) Cell and Molecular Biology Unit, School of Optometery and Vision Sciences, Cardiff
(2) Ophthalmology, University Of Bristol, Bristol

Purpose To identify changes in epithelial cell homeostasis in corneas stored in organ culture.

Methods Porcine corneas were organ cultured according to standard protocols. Corneoscleral discs were excised, and stored in organ culture at 34°C for up to 14 days. For proliferation studies, Brdu at a 1/500 dilution was added to the medium. Following storage, cornea was bisected, and one half fixed for wax sectioning. General morphology and epithelial stratification were assessed following H&E and Hoechst staining by light and fluorescence microscopy. The BrdU labelling index was quantified in central, peripheral and limbal regions of the cornea. The TUNEL assay was also performed to identify epithelial cell death.

Results A significant decrease in corneal epithelial thickness during storage from 45µm ± 3.6 at 0 day to a minimum of 7.7µm ± 0.6 at 14 days (P<0.0001). Stromal thickness increased from 691µm ± 53 at 0 day to a maximum of 1569µm ± 126 at 14 days organ culture storage (P<0.0001). The proliferative activity of the corneal epithelium was not equally distributed across the cornea and greatest in the peripheral epithelium at 12 days (27.7% ± 8.6%). The labelling index appeared to increase in the peripheral (r = 0.79), central (r = 0.62) and limbal (r = 0.67) region with organ culture storage time (P<0.05). The TUNEL technique identified epithelial cell death in the porcine cornea during organ culture storage.

Conclusion The porcine cornea appears to be a good model for organ culture storage. Furthermore, like human corneas there is a loss of epithelial cell layers. The proliferative index with increased culture time may be an unsuccessful attempt to reinstate the lost cells and thus return the cornea to normal homeostasis.

158 / 1267

Induced expression of insulin like growth factor 1 by amniotic membrane conditioned medium in cultured human corneal epithelial cell

LEE HK, MA KT, SEONG GJ, LEE JH, SEO KR, KIM EK, CHUNG SH
Ophthalmology, Yonsei University College of Medicine, Seoul

Purpose To determine whether insulin like growth factor-1 (IGF-1) and IGF-1 receptor (IGF-1R) is induced by amniotic membrane conditioned medium (AMCM) and also evaluate the effect of AMCM and IGF-1on human corneal epithelial cell (hCEC) proliferation and migration

Methods With immunohistochemical staining, we tried to confirm the existence of IGF-1 and IGF-1R on human cornea. For in vitro study, hCECs were cultured from corneolimbal tissue with supplemental hormonal epithelial medium (SHEM). After administration of AMCM (50ul/ml, 100ul/ml) and IGF-1, cell migration and proliferation were determined by proliferation and migration assay. We also tried to determine whether the expression of IGF-1 and IGF-1R on hCEC was changed by AMCM using western blot and immunofluorescein staining technique.

Results In this study, we found the existence of IGF-1R in human corneal epithelium. However, IGF-1 was not found in all layers of human cornea. Compared with the control group, increased expression of IGF-1 by AMCM dose dependant manner using Western blot and immunofluorescein cell staining technique. However, the expression of IGF-1R was not affected by the AMCM. With AMCM and IGF-1, hCEC showed increased in cell migration and proliferation. The induced proliferation and migration by AMCM was inhibited by IGF-1 neutralizing antibody.

Conclusion AMCM may induce IGF-1 during hCEC proliferation, and the increased IGF-1 may participate in facilitated cell migration and proliferation by amniotic membrane.

159 / 1268

Is the corneal endothelial change that seen after 2.45 GHz microwave exposure (near ICNIRP safety limits) microwave exposure specific?

KOJIMA M (1), HATA I (1), WAKE K (2), WATANABE S (2), TAKI M (3), KAMIMURA Y (4), YAMANAKA Y (2), TAKAHASHI N (1), SASAKI K (1)
(1) Department of Ophthalmology, Kanazawa Medical University, Daigaku, Uchinada, Kahoku-gun, Ishikawa
(2) National Institute of Information and Communications Technology, Nukui-Kitamachi, Koganei, Tokyo
(3) Department of Electrical Engineering, Graduate School of Engineering, Tokyo Metropolitan University, Minami-Osawa, Hachioji, Tokyo
(4) Department of Information Science, Faculty of Engineering, Utsunomiya University, Utsunomiya

Purpose We have examined whether the corneal changes reported by Kues et al. (1985) was microwave specific or not.

Methods A 2.45 GHz microwave (20-300 mW/cm2) was exposed unilaterally to male-pigmented rabbits (Dutch, 1.8-2.2 kg) with a systemic anesthesia. Other rabbits received following invasions, eye-lid closure, contact lens wear, carbon dioxide or nitrogen gas exposure, corneal cauterization, and albumin injection into the anterior camber. Changes in the anterior segment were observed by a Scheimpflug image analysis system, specular microscope and a laser flare cell meter.

Results In the microwave exposed group, corneal bleb like changes which was similar to corneal changes that Kues et al. reported, were temporally observed on 2 out of 135 rabbits, and these changes were disappeared within a week. The transient cornea changes which were similar to changes in microwave exposed rabbits were observed in carbon dioxide exposure and cornea cauterization treatment eyes.

Conclusion The appearance of cornea bleb due to the contact lens wearing it was reported that the individual specificity was remarkable, the cornea change shown in the present study and corneal changes reported by Kues in 1985 indicated not only microwave exposure but also possibility of inducing even in other factors.

160 / 1446

Cytokine Regulation of Extracellular Superoxide Dismutase Expression in Keratocytes from Human Corneas with Keratoconus or Bullous Keratopathy

ÅSTRÖM EM (1), MARKLUND SL (2), BEHNDIG A (1)
(1) Department of Clinical Sciences/Ophthalmology, Umeå University Hospital, Umeå
(2) Department of Medical Sciences, Clinical Chemistry, Umeå University Hospital, Umeå

Purpose Extracellular Superoxide Dismutase (SOD3) forms a major physiological defence against superoxide radicals released to the extracellular space. Expression of SOD3 occurs for instance in fibroblasts and smooth muscle cells, and different cytokines and growth factors regulate the expression of SOD3 in these cells. In this study we investigated the effect of different cytokines on the expression of SOD3 in keratocytes from diseased corneas.

Methods Keratocytes obtained from patients with keratoconus (KC) and bullous keratopathy (BKP) undergoing surgery, were cultivated. Platelet-derived growth factor (PDGF), basic fibroblast growth factor (bFGF), interleukin-1α (IL-1α), transforming growth factor-β (TGF-β) and interleukin-6 (IL-6) were added and SOD3 protein was determined with an ELISA, in culture media at 24h, 48h, 72h and 96h and also in cell homogenates. Keratocytes without any added cytokines were used as controls.

Results PDGF down regulated SOD3 expression in both BKP ($p = 0.003$) and KC ($p < 0.001$) compared to the controls. IL-1 ($p = 0.003$) and IL-6 ($p = 0.013$) gave a lower expression of SOD3 in KC keratocytes compared to BKP keratocytes.

Conclusion These findings suggest a general down regulating role for PDGF in SOD3 expression in keratocytes, but also a lower SOD3 expression in KC, than in BKP keratocytes, in response to IL-1 and IL-6.

EVER-2004-abstractbook.indd 32 8/19/04 12:25:53 PM

161 / 1447

Surfactant Protein-D detected in corneal and conjunctival epithelium

SUNDARAM V (1), BRON AJ (1), MCDONALD B (2), CLARK H (3), KNOP E (4)
(1) Nuffield Laboratory of Ophthalmology, Oxford
(2) Department of Neuropathology, Oxford
(3) Department of Biochemistry, Oxford
(4) University Eye Clinic Research Lab, Berlin

Purpose Surfactant Protein-D (SP-D) is a member of the Collectin family of proteins and a component of the lung surfactant complex (eg. SP-A and SP-D). SP-A and SP-D are known to act in first line host defence against microorganisms and modify the inflammatory response to microbial antigens via innate and adaptive mechanisms. SP-D is expressed at extra-pulmonary mucosal sites including the human lacrimal gland, tears and ocular surface. In this study we examined the expression of SP-D in human eye using immunohistochemistry.

Methods We used a Vectastain Elite ABC kit, with polyclonal antibodies against the recombinant fragment of human SP-D, to study the immunohistochemical expression of SP-D in two exenterated human eyes: 1. An 82-year-old male with a baso-squamous carcinoma of the orbit, and 2. A 15-year-old female with recurrent meningioma and proptosis.

Results In case 1 there was strong cytoplasmic staining for SP-D in clusters of basal epithelial corneal cells, sometimes involving more superficial layers, with diffuse conjunctival epithelial staining. In case 2, where central epithelium was missing, there was diffuse staining of conjunctival and peripheral corneal epithelium. There was also scattered positive staining of cells in the conjunctival sub-mucosa and corneal stroma and weak, variable staining of the non-pigmented ciliary epithelium and neuroretina. Negative controls showed no immunoreactivity for SP-D.

Conclusion This is the first immunohistochemical evidence of SP-D localisation in the human corneal and conjunctival epithelium. SP-D may play an immundefensive role at the ocular surface as it does at other mucosal surfaces.

162

Quantitative study of the tear film in a population of young adults

LIRA M (1), RESUA C (2), YEBRA-PIMENTEL VILAR E (2), REAL OLIVEIRA E (3)
(1) Physics (Optometry), Braga
(2) Optics and Optometry, Santiago de Compostela
(3) Physics, Braga

Purpose The aim of this study was evaluate the volume of the tear film in a student's population.

Methods The exams were performed on 32 healthy young adults with the mean age of 21.19 ±1.84 years. The volume of the tear film was evaluated by measure the tear meniscus height with and without fluorescein and the PHENOL red test.

Results The height of the tear meniscus without fluorescein starting from the edge of the inferior eyelid to the superior limit of the meniscus was of 0.25± 0.08 mm (mean± SD) and starting from the edge of the inferior eyelid to the reflex of the tear meniscus was 0.13±0.056 mm (mean± SD). Statistically there are significant differences between the methods. The height of the tear meniscus with fluorescein starting from the edge of the inferior eyelid to the superior limit of the meniscus was of 0.29± 0.11 mm (mean± SD).The medium value obtained with the PHENOL red test was 20.75±7.04mm.

Conclusion Statistically there are significant differences between the measurements obtained with the total meniscus method and the reflex meniscus method. There are no statistically significant differences between the total meniscus measured with and without fluorescein.The results show values of the height of the meniscus tear similar to results obtained in other populations.

163

Qualitative study of the tear film in a population of young adults

LIRA M (1), RESÚA C (2), YEBRA-PIMENTEL VILAR E (2), REAL OLIVEIRA E (1)
(1) Physics, Braga
(2) Optics and optometry, Santiago de Compostela

Purpose The aim of this study was evaluate the stability of the tear film in student's population in Spain.

Methods The exams were performed on 32 healthy young adults with the mean age of 21.19 ±1.84 years. The stability of the tear film was evaluated by the break up time (BUT) and the measure of non-invasive break up time (NIBUT). The Nibut test was evaluated with the tearscope grids for five times and only the three most similar was recorded. The BUT test was measured with fluorescein for three times and only the two more similar was recorded.

Results The value of BUT was 13,12 ± 12,30 seconds (mean± SD) and for the NIBUT was 17,17 ±17 seconds (mean± SD). The maximum value for BUT was 51 seconds and the minimum 1,85 seconds and for NIBUT was of 52 and 4,4 respectively. The medium difference of the values for the tear rupture obtained with both procedures is no statistically significant (P=0,203).

Conclusion The results show that in spite of the difference between BUT and NIBUT the results however can have some implications on clinical practice for certain measure intervals.

164

An artificial meniscus for study of tear properties

TIFFANY JM, WALLACE BJ
Nuffield Laboratory of Ophthalmology, Oxford

Purpose Information about tear film formation and drainage can be obtained from study of the tear meniscus on the lower lid margin. The technique of meniscometry gives the radius of curvature, and hence indicates the fluid volume, of the meniscus. Development of an in vitro system will help in study of shape in relation to capacity, and evaporative characteristics of the tears.

Methods Glass slides were cemented together at right angles to represent the eyeball (vertical) and the lid margin (horizontal). Liquid placed in the angle represented the meniscus, and was viewed through a Keeler Tearscope on the biomicroscope, with a striped target across the front so that stripes were reflected from the meniscus. Digital photographs were taken through the microscope and the spacing of stripe images determined by pixel counting in the computer. The system was calibrated by photographing reflections from the inner surface of standard glass capillary tubes.

Results TMR was measured for different volumes of liquid, and compared with theoretical values assuming a simple circular-quadrant model. The deviation from circular was not significant for curvatures similar to those observed in normal or dry human eyes (TMR up to 0.5 mm). The surface tension of the liquid was varied (acetic acid/water mixtures) but had no detectable effect on surface curvature over the range 42 – 73 mN/m. TMR measurements from a time-sequence of photographs indicated the rate of evaporation to be on the order of 6 nl/mm2/min, comparable to measurements by others from the whole human eye.

Conclusion Experiments so far are still exploring the possibilities of the system. We conclude that this is a small-scale, simple, convenient and rapid technique for investigations on tears and evaporation from the eye.

EVER-2004-abstractbook.indd 33 8/19/04 12:25:54 PM

■ 165

The Application of Capillary Liquid Chromatography-Mass Spectrometry Techniques to the Study of Patient-to-patient Variations in Tear Chemistry

MANN AM (1, 2), CAMPBELL D (1, 2), TIGHE B (1, 2)
(1) Biomaterials Research Unit, CEAC
(2) Aston University, Birmingham UK

Purpose We have been studying how lipoidal species interact with contact lenses and their relationship to tear film stability. A method developed in these laboratories allowed lipids extracted from single contact lenses to be analysed and provide a "fingerprint" of the lipid classes present. This lipid fingerprint shows relative proportions of polar and non-polar lipids obtained; however precise species identification has not been possible because of the number and relative chemical similarity of lipoidal species in tears. The goal of this work is the identification of individual species along with investigation into any link between tear chemistry of individual wearers and the functional behavior of their tear film in the absence and presence of a contact lens

Methods Capillary liquid chromatography (CapLC) is a technique that offers efficient separations of mixtures and mass spectrometry (MS) is a technique that offers high levels of specificity and sensitivity. The use of CapLC coupled to MS using appropriate preparative techniques allows separation and identification of the lipoidal tear species in individual patients for both in vivo samples and those taken from contact lens

Results A range of methods for identification, collection and extraction have been developed. The mass spectrometry detection system used is particularly suitable for identification of charged species which has allowed the identification of individual polar phospholipids from the tear film

Conclusion Polar charged lipids present whether taken from the tear film or contact lenses can be separated and identified by this technique which provides a unique method for the study of patient variation in lipid spreading

■ 166

Surface Wettability of Worn adn Unworn Contact Lenses

TIGHE B (1, 2), N ASSO M (3, 2)
(1) Biomaterials Research Unit, CEAC SEAS
(2) Aston University, Birmingham UK
(3) Biomaterials Research Unit, CEAC

Purpose The surface and interfacial properties of contact lenses are critical to their clinical success. Although most commercially available contact lenses are usually fabricated from hydrogel polymers this does not mean that the surfaces are uniformly hydrophilic. The presence of a contact lens has a deleterious effect on tear film stability, reducing the so-called "break up time" to something like half its normal value. Because of this the front (anterior) lens surface is repeatedly exposed to an air interface. This poster investigates the relative change in front surface dehydration and wetting characterization of silicone hydrogel lenses in comparison to conventional hydrogel before and after wear.

Methods Dynamic Contact Angle (DCA) was used to assess the wettability of soft contact lenses. The technique has been adapted to the measurement of the advancing and receding angles of both worn and unworn contact lenses. A range of contact lens materials has been studied together with the use of both unworn and worn lenses to examine the effects of tear component deposition on surface properties and hydration behaviour.

Results Commercial contact lenses – Focus Night&Day, Purevision, Acuvue Advance, Proclear, 1-day Acuvue and Focus Dailies – were tested and compared. Whereas one day of wear has little effect on surface wettability of conventional daily wear lenses, 30 days of wear produces a unifying effect that masks underlying differences in lens chemistry. The measured values of advancing contact angle are critically dependent upon the period of exposition of the lens surface to air.

Conclusion Dynamic contact angle technique has been shown to provide a useful method of reflecting both individual and combined effects on the surface wettability and surface hysteresis.

■ 167

Contact Lenses & Comfort Enhancers: In Vivo and In Vitro Release of Soluble PVA

MAHOMED A (1, 2), TIGHE B (1, 2)
(1) Biomaterials Research Unit, CEAC
(2) Aston University, Birmingham UK

Purpose The controlled release of water soluble surface active polymers from contact lenses is a logical way of modifying the tear-lens interface in an attempt to increase comfort. We have previously identified the fact that the packing solution of Focus® Dailies® contains soluble polyvinyl alcohol (PVA) that has, apparently, leached from the lens matrix, which is itself composed of cross-linked PVA. Since PVA is a component of some brands of comfort drops the possible link between PVA release and lens comfort has been investigated.

Methods The existence of clinically available lenses of this type provides the opportunity to study in vivo and in vitro release in parallel. This in turn enables the development of an in vitro system that relates closely to in vivo release behaviour, thus providing a platform for the development of more effective controlled release systems for the prolonged enhancement of contact lens comfort.

Results We have developed an analytical technique to monitor levels of eluted material within the packing solution and released in both in vivo and in our in vitro model. These studies have demonstrated that although PVA release continues progressively into the packing solution as the lens is stored, this is a relatively slow process compared with the release that occurs when the lens is transferred to the eye.

Conclusion The poster will present detailed analytical data and an interpretation of the relationship between PVA release and lens comfort. A clearer understanding of these phenomena is of considerable potential importance since the effective design of controlled release comfort systems offers an important approach to the reduction of comfort-related wearer dissatisfaction.

■ 168

The Application of Lab-on-a-Chip Technology in Tear Composition, Deposited Protein and Tear "Envelope" Analysis

MANN AM, TIGHE BJ
Biomaterials Research Unit, Birmingham

Purpose To demonstrate the phenomenon of the "interfacial tear envelope" which is intimately associated with the lens surface. Tear and lens deposit analysis have been extensively researched, however the tear envelope has not received attention; principally due to the lack of appropriate experimental methodologies. The poster presents a comparative study of these three parameters, paying particular attention to the effect of tear interaction on a variety of contact lenses and the consequent generation of inflammatory markers

Methods Exciting new tear-lens interaction results which were achieved using state of the art lab-on-a-chip technology. Whilst it is similar in investigative protocol to SDS-PAGE, it is far superior in all aspects of assay performance from ease of application through to sensitivity and data acquisition. We demonstrate here, the fact that, it is a highly sensitive tool in the analysis of tears, deposited protein and the tear 'envelope' particularly when used in conjunction with the identification immunoassay counter-immunoelectrophoresis.

Results Subtle differences in the composition and relative concentrations of proteins in a 14-200kDa range were detected between each of the 3 groups. Regarding key biochemical markers no kinin activity was detected in either the interfacial tear envelope or normal basal tear samples, the kinin response was only detected in the lens deposits; its deposition was material dependent.

Conclusion We have developed a novel approach to procure the tear envelope from the lens, exploited new microfluidic chip technology for its analysis and have found that the analysis of our so-called tear envelope completes the dynamic lens-tear interaction picture.

EVER-2004-abstractbook.indd 34 8/19/04 12:25:54 PM

■ 169

Comparative Physical and Biochemical Studies of Silicone Hydrogel Contact Lenses

FRANKLIN VJ (1, 2), TIGHE BJ (1, 2)
(1) Biomaterials Research Unit, CEAC
(2) Aston University, Birmingham UK

Purpose It is well known that changes occur in the properties of lens materials during wear. This is particularly true of those properties related to the surface. The commercial appearance of silicone hydrogels has given this opportunity to harvest lenses from wearer groups in a variety of locations using the lens in wear modality range from daily to thirty day continuous wear. This poster examines links between the variety of biochemical consequences of wear and the changes in properties between worn and unworn lenses.

Methods A range of laboratory-based techniques were used to assess the physical properties along with the deposition profiles of silicone hydrogels from in vitro studies or ex vivo lenses.

Results The established silicone hydrogel materials (Focus Night & Day and PureVision) are compared with a newly available (2004) material (Acuvue Advance). Although the underlying chemistry has similarities the properties differ considerably between the materials.

Conclusion The properties and in eye behaviour of silicone hydrogels differ considerably from conventional hydrogels but show many elements of similarity to each other. The presence of extensive blocks of silicone moieties does however add an additional degree of complexity. Two of the three commercial materials have been surface treated and in different ways adds to the complexity. This poster demonstrates that there is not a simple single cause and effect going on between the current silicone hydrogel lenses but a more complex spectrum of behaviour linked to underlying physical and biochemical phenomena. Patient variability coupled with generic differences appear to be responsible for the abnormalities in the behaviour of the lens in the ocular environment.

■ 170

Results of a US Community-Based Evaluation of a Lubricating Eye Drop Containing HP-Guar

PRZYDRYGA J (1), HARTSTEIN I (2)
(1) Alcon Laboratories, Inc., Fort Worth, TX
(2) Private Practice, La Palma, CA

Purpose Evaluation of a lubricating eye drop containing HP-Guar in reducing ocular discomfort and dry feeling eyes.

Methods 168 subjects were enrolled at 29 sites in an open label study conducted in the US. Patients enrolling in the study reported that their eyes "felt dry enough to want to use eye drops" at least "some of the time." Saline was used during a 7 day run-in period, 4 times per day (baseline). Eligible subjects met the screening requirements and used the test lubricating eye drop (Systane™ Lubricating Eye Drops) 4 times per day for 28 days. Ocular discomfort assessments included feeling of dryness, irritation, burning, stinging, grittiness, foreign body sensation and overall ocular discomfort. Dry feeling eyes were rated using a Likert questionnaire.

Results Overall ocular discomfort was significantly less at 28 days compared to baseline ($p<0.0001$) and screening ($p<0.0001$). Treatments used prior to screening included CMC, glycerin/polysorbate and hypromellose containing eye drops. Feelings of dryness, irritation, burning, stinging, grittiness and foreign body sensation were all significantly less at 28 days compared to baseline ($p<0.0001$). Assessments of dry feeling eyes at 28 days were also observed in favor of Systane™ with less morning ($p<0.0001$) and end of day dryness ($p<0.0001$) and ability to forget my symptoms during use of the drops ($p<0.0001$) compared to baseline.

Conclusion Systane™ Lubricating Eye Drops effectively reduces ocular discomfort and dry feeling eyes. Measurable improvement of symptoms is seen within 28 days for the majority of subjects.

■ 171

Behaviour of human tenon fibroblasts after long term low dose beta irradiation

PICHLER A (1), GILBERT I (2), SCHUBERT M (3), ASSMANN W (3), KOTLIAR K (1), LANZL I (1)
(1) Eye clinic Technical University Munich, Munich
(2) Institute of medical engineering, Garching
(3) Nuclear physics institute of LMU, Munich

Purpose The modulation of wound healing is a major subject of interest. Local application of low dose radiation by an 32P electron emitter for a longer period (one week) and monitoring of its effect on tenon fibroblasts is a new approach to understand wound modulation. The goal is to identify new techniques interfering with wound healing. Filtering glaucoma surgery is one area which could benefit from new knowledge in wound healing.

Methods Human tenon fibroblasts from biopsies were used.The cells were exposed to low dose irradiation (9 and 12 Gray) for seven days. Analysis before and after irradiation in regard to growth rate, plating efficiency and morphology was performed. Cells in different stages of growth were used.

Results Concerning the surviving rate of cells after irradiation (between 12 and 20 percent) there was no significant difference between the applied doses (9 and 12 Gray). There was a significant difference between controls and the irradiated group. After irradiation the cells were not able any more to form colonies and morphology of most cells was changed.

Conclusion We were able to demonstrate, that low dose application of radiation for a prolonged period results in severe changes of proliferative rate and morphology of tenon fibroblasts whereas no significant difference could be shown between the two different doses. These findings could represent an important step toward the development of radioactive implants for filtering glaucoma surgery.

■ 172

Distribution and organization of sympathetic human choroidal innervation

DE HOZ R, ROJAS B, RAMÍREZ AI, SALAZAR JJ, RAMÍREZ JM, TRIVIñO A
Instituto Investigaciones Oftalmológicas Ramón Castoviejo. UCM, Madrid

Purpose To determine the organization and distribution of sympathetic human choroidal innervation

Methods Thirteen human choroidal whole mounts were processed for indirect immunofluorescence. Antibody to a component of the neuronal cytoskeleton, neurofilament 200 kDa (NF-200), was combined with antibodies to neuropeptide Y (NPY) and antibodies to tyroxine hydroxylase (TH).

Results NPY(+) and TH(+) fibers were distributed at three different levels: suprachoroid-large size vessel layer, and two different depths of the medium size vessel layer. On reaching the vessel wall, NPY(+) and TH(+) perivascular axons exhibited small terminal dilations that varied in morphology. We also observed intensely immunoreactive (IR) TH(+)/NF200(-) small spindle elements. These THIR elements were mainly distributed in the suprachoroid from the equator to the periphery.

Conclusion The human choroid contains an abundance of sympathetic nerve fibers related to chroroidal vascular structures. NPY(+) and TH(+) innervation could contribute to blood flow regulation. This vascular control could be explained by the presence of neurotransmitters on perivascular and paravascular axons, with proven effects on vascular regulation.

EVER-2004-abstractbook.indd 35 8/19/04 12:25:55 PM

■ 173

Unique M-band composition in human extraocular muscles

PEDROSA-DOMELLÖF F (1, 2), CARLSSON E (1), CARLSSON L (1), THORNELL LE (1)
(1) IMB, Anatomy, Umeå University, Umeå
(2) Clinical Sciences, Ophthalmology, Umeå University, Umeå

Purpose To study the composition of the M-band in the fibers of the human extraocular muscles (EOM) with respect to myomesin, EH-myomesin and M-protein and to correlate this composition with the myosin heavy chain (MyHC) content of the fibers.

Methods Serial cross and longitudinal sections of adult and fetal (18-22 weks of gestation) human EOMs were studied with immunocytochemistry using antibodies specific against these M-band proteins and to slow, slow tonic, fast 2A, extraocular and embryonic MyHC isoforms.

Results The M-band composition of the human EOMs was very complex and varied along the length of the muscles. Myomesin, a hitherto considered ubiquitous component of the M-band was present in all fibers during development. However myomesin was excluded from all or practically all fibers in samples of the rectus inferior, taken in the midportion or proximally in the muscle, whereas it was present in the fibers at the distal part of the same sample. EH-myomesin was present in the fibers lacking myomesin, but it was also observed co-expressed in fibers containing myomesin. M-protein was present in all developing fibers but in the adult it was only seen in subsets of the fibers containing MyHCextraocular but lacking MyHCslow or fast 2A. No further relationship between the M-band composition and the content MyHC of the fibers was apparent.

Conclusion The developmental down-regulation of myomesin and M-protein from large groups of fibers and the presence of the novel isoform EH-myomesin in adult fibers together with the lack of relation between the M-band composition and the MyHC content of the fibers reveal the unique developmental pattern and functional complexity of the human EOMs.

■ 174

Bilateral Panuveitis Revealing Gluten Hypersensitivity

SALAMA BS (1, 2, 3), GICQUEL JJG (1, 2, 3), VABRES PV (4), DIGHIERO PLD (2, 1, 3)
(1) Ophthalmology, Saint Jean d'Angély
(2) Ophthalmology, Poitiers
(3) Ophthalmology, Saintes
(4) Dermatology, Poitiers

Purpose To report a rare case of gluten hypersensitivity disclosed by bilateral panuveitis.

Methods A 78-years old woman presented with bilateral panuveitis followed by gluten hypersensitivity dermatologic and neuromuscular manifestations.

Results Slit lamp examination showed mild OD to severe OS panuveitis with left optic disc edema. Cutaneous histology and direct immunofluorescence put to evidence a dermatitis herpetiformis. EMG showed neuromuscular plate deficit that progressed to an axonal neuropathy within years. Anti gliadin IgA and IgG, anti-endomysium IgA as well as tissue anti-transglutaminase IgA were detected. Jejunal mucosal biopsy showed only moderate villous atrophy. All other known causes of panuveitis were checked and ruled out.Ocular manifestations subsided with topical and systemic corticosteroids; while dermatitis diminished with Dapsone®. Neuromuscular deficits remained unchanged. The patient was put under gluten-free diet to maintain remission and preventing relapse. No review biopsy was performed.

Conclusion To our knowledge gluten hypersensitivity first manifested as panuveitis has never been reported yet. Sensory motor neuropathy of our case appeared before Dapsone® therapy, which opposes anterior consideration to be as treatment side effect; this point needs more clinical proof.

■ 175

CMV retinitis in Good Syndrome

STANESCU D (1), BONNEL S (1), SALLO FB (2, 3), SAHEL J (1)
(1) CHNO les XV-XX, Paris
(2) First Dept of Ophthalmology, Semmelweis University, Budapest
(3) Moorfields Eye Hospital, London

Purpose To report one case of CMV Retinitis (CMVR) in a patient with Good Syndrome.

Methods case report.

Results A 57-year-old male patient presented with blurred vision of the left eye. His past medical history revealed a myasthenia associated with a thymoma, Campylobacter septicemia and multiple chest infections during the last year. Visual acuity was 20/20 OD and 20/100 OS. Left eye examination disclosed small inferior keratic precipitates with mild anterior inflammation. Fundus examination revealed supero-temporal active retinitis and moderate vitritis. An anterior chamber tap and vitreous biopsy were performed and were positive for CMV by Polymerase Chain Reaction. The examination of the other eye was normal. The retinitis was under control after 15 days with combined systemic intravenous and repeated weekly intravitreal injection of both Gancyclovir and Foscavir. Despite visual improvement, patient was admitted for pancytopenia work-up. Lymphopenia, reverse rate of CD4/CD8, absence of B lymphocyte and hypogammaglobulinemia combined with previous thymoma and multiple chest infections were in accordance with the diagnosis of Good syndrome.

Conclusion To our knowledge, CMVR has been reported before in only 3 patients with thymoma. Indeed, Lightman reported two patients who developed CMVR in conjunction with Good syndrome. This syndrome consists in thymoma, hypogammaglobulinemia, a reverse rate of CD4/CD8 and low or absent lymphocyte B. Early diagnosis and treatment of CMV retinitis leads to better prognosis and better visual acuity, particularly these patients are at high risk of relapse. Patients with thymoma and altered CBC should regularly receive an ocular fundus or being referred to an ophthalmologist in case of blurred vision.

■ 176

An Unusual Case of Periorbital Necrotising Fasciitis With Implications for Future Management of the Condition

ROBBIE S J, MUHTASEB M, QURESHI K
Moorfields Eye Hospital, Duke-Elder Eye Centre, London

Purpose A case of bilateral necrotising fasciitis with unusual features which suggests that individual cases may benefit from early categorisation into those which are steroid-responsive and those which are non-steroid responsive.

Methods This is a case presentation incorporating a discussion of the aetiology and pathogenesis of periorbital necrotising fasciitis with reference to the literature. The case raises particular questions regarding the rapidity and severity of bilateral visual loss in the absence of demonstrable orbital abscess or post-septal cellulitis.

Results A 78 year-old diabetic woman who presented with clinical signs of necrotising fasciitis and a severe bilateral visual loss which failed to improve despite high-dose broad spectrum antibiotic therapy and limited surgical debridement. Radiographic investigations confirmed involvement was confined to the preseptal tissues and microbiological investigation revealed Group A Beta-haemolytic Streptococcus to be the causative organism.

Conclusion Periorbital necrotising fasciitis is an uncommon condition with few cases described in the literature. Group A Beta-haemolytic Streptococci have been implicated in cases of polyarteritis nodosa and other vasculitides. We conclude that a streptococcal-induced vasculitis was the main pathogenic factor involved in this case and that early administration of steroid therapy in certain cases of periorbital necrotising fasiciitis should always be considered.

EVER-2004-abstractbook.indd 36 8/19/04 12:25:56 PM

■ 177

Tacrolimus in the treatment of uveitis in children

VOROS GM, RESSINIOTIS T, PANDIT R
Ophthalmology Dept., Royal Victoria Infirmary, Newcastle Upon Tyne

Purpose To report our experience with tacrolimus for the treatment of non-infectious chronic uveitis in children.

Methods Case1: A 7-year-old female with oligoarticular seronegative juvenile idiopathic arthritis and bilateral chronic uveitis refractory to oral steroids and methotrexate was given tacrolimus. Case 2: A 14-year-old male with idiopathic chronic uveitis responded favourably to systemic steroids, and tacrolimus was added to his treatment.

Results In both our patients, introduction of tacrolimus led to control of intraocular inflammation and a reduction or cessation of systemic steroids. In the first case, there was sustained remission of the uveitis over 18-month follow up, and reduction of steroid dose to 2.5mg on alternate days. In the second case, control of the uveitis was finally achieved by monotherapy with tacrolimus alone over an 18-month follow up. In both cases, no significant tacrolimus-related side effects were encountered.

Conclusion To the best of our knowledge, this is the first report of the use of tacrolimus in the treatment of uveitis in children. Tacrolimus may be a useful therapeutic option, as it can lead to control of uveitis and allow for significant reduction or cessation of systemic steroids.

■ 178

Proliferation of peripheral blood lymphocytes in vitro and Interleukin-2 secretion in uveitic patients

URBAN E (1), MISIUK-HOJLO M (2), RUSIECKA J (3)
(1) Department of Physiology, Medical University, Wroclaw
(2) Department of Ophthalmology, Medical University, Wroclaw
(3) Department of Microbiology, Medical University, Wroclaw

Purpose The objective was to determine the activity of peripheral blood lymphocytes in vitro from the patients with uveitis after mitogen stimulation and to compare the results with the control group.

Methods 21 patients with anterior and posterior uveitis of various etiology were examined. The control group consisted of 11 healthy patients. The activity of peripheral blood lymphocytes was assessed in the blast transformation test with phytohaemagglutinin and lipopolysaccharide.Phytohaemagglutinin was used to the stimulation of peripheral blood lymphocytes and the evaluation of interleukin-2 secretion capacity. Blood samples were obtained from patients with diagnosed uveitis at the beginning of illness and after 4 weeks.

Results The interleukin-2 concentration in supernatants obtained after lymphocytes stimulation was mean 31.90 at the begining and after 4 weeks - mean 29.95. Proliferation index in patients ranged between 0,9 and 2,7 and in the control group - between 1,5 and 2,7.

Conclusion We have not demonstrated the statistically significate difference interleukin-2 concentration between the uveitic patients after stimulation and the control group.

■ 179

CCL-5 and CCR-5 chemokine gene polymorphism in posterior non-infectious uveitis

AHAD M (1, 2), MISSOTTEN T (1), ABDALLAH A (3), LYMPANY P (3), MENEZO V (1, 4), KUO N-W (1), LIGHTMAN S (1, 2)
(1) Moorfields Eye Hospital, London
(2) Department of clinical ophthalmology, Institute of Ophthalmology, London
(3) Clinical Genomics Group, Institute of heart and lung diseases, Imperial College, London
(4) Institute of Ophalmology, London

Purpose CC chemokines are important chemo attractant for Th1 cells that play crucial role in uveitis. Various studies have shown increased production of CCL-5 (RANTES) and its receptor CCR5 in clinical and experimental uveitis. Two single nucleotide polymorphisms at promoter site -403 and -28 of RANTES gene have found to affect the expression of RANTES in various cells. Similarly polymorphism at -59029 of CCR5 also affects the expression of receptor on cell surface and 32bp deletion in CCR5 results in the expression of a truncated, non-functional receptor. This study was carried out to investigate the possible association of these four gene polymorphisms with the susceptibility of posterior non-infectious uveitis

Methods 74 patients with intraocular inflammation behind the lens-iris diaphragm of non-infectious origin and 102 ethnically matched healthy controls were recruited for this study. The patients were stratified according to the primary site of inflammation into intermediate, posterior and panuveitis. Genotyping for RANTES -403 A/G, -28C/G, CCR5 -59029 A/G and 32bp deletion was performed by single specific primer polymerase chain reaction. (SSP-PCR).

Results The frequency of -59029 AA genotype was 45% in patients compared to 28% in controls. (p= 0.02). No significant association was found between the disease as whole and the other three polymorphisms. But in case of intermediate uveitis, the allelic frequency of CCR-5 32bp deletion was 3% compared to 12% in controls. (p=0.03)

Conclusion This pilot study shows that CCR-5 59029 AA phenotype could be associated with posterior non-infectious uveitis. Also the 32bp deletion allele in CCR-5 may give protection against intermediate uveitis

■ 180

Should diagnosis of ocular toxocariasis be revisited?

LABALETTE PL (1), JALIMAIN-SPRIMONT A-S (1), DEWITTE J-M (2), DUTOIT E (2), CAMUS D (2), ROULAND J-F (1)
(1) Ophthalmology, Lille
(2) Parasitology, Lille

Purpose To investigate a consecutive series of patients presented with ocular toxocariasis by analyzing clinical and biological data from infected adults and children.

Methods Twenty-one patients diagnosed in a ten year period were included. Epidemiological and clinical data were noted at the time of diagnosis. Retinographies of the lesions were performed in all cases. Aqueous humor was obtained in the affected eye by paracentesis under topical or general anesthesia at the operating room. Analysis of aqueous humor for local antibody production was performed using Western blot and/or ELISA. In each case, ocular results were compared to those obtained in the peripheral blood collected on the same day.

Results All patients presented with an history of chronic unilateral uveitis or unevolutive unilateral lesions. The series included 12 adults (57%) and 9 children (43%), with a mean age of 28.5 ± 20 years. All children under the age of 8 years old had profoundly affected visual acuity and a higher rate of posterior pole lésions. No statically significant difference was noted between Western Blot and ELISA in detection of anti-T.canis antibodies in serum or aqueous humor.

Conclusion Even if intraocular infestation with T. canis lead typically to unilateral uveitis in children, our data show that most cases occur in adults with better visual results in this unexpected population. Both Western Blot and ELISA methods allow an indirect biological diagnosis by detecting different patterns or higher antibody titers in aqueous humor than in the serum.

EVER-2004-abstractbook.indd 37 8/19/04 12:25:56 PM

■ 181

Inflammatory cells and cytokines production in chalazia

FRUSCHELLI M (1, 2), MASSAI L (2), CARBOTTI P (2), MENCARELLI M (3), ALESSANDRINI C (2), GRASSO G (2)
(1) Ophthalmology and Neurosurgery University of Siena, Siena
(2) Anatomical and Biomedical Sciences University of Siena, Siena
(3) Physiology, Siena

Purpose Aim of the present study was to localize the different types of inflammatory cells and cytokines in chalazion lesions to determine the sequence of events in cellular reaction.

Methods Fifty four chalazia surgically removed by excision were fixed in Bouin's solution and imbedded in paraffin. For immunohistochemical studies we used CD68, CD3, CD4, CD8, CD45RO, lactoferrin antibodies to detect respectively macrophages, T cells, T helper, T cytotoxic, mature activated T lymphocytes and neutrophils. For detection of cytokines we used IFN gamma and TNF alpha antibodies. The EnVision peroxidase detection system were used and the immmunoreactivity was visualized with diaminobenzidine.

Results Large numbers of macrophages infiltrated the stroma around the alveoli and the glandular tissue of the chalazion lesions. Lower numbers of the neutrophils were found with similar distribution to macrophages. CD3(+) lymphocytes also accumulated in large numbers in the stroma, around the glands, and in the areas of granulomatous inflammation indicating an association with macrophages and neutrophils. Within the T-cell population, numerous CD8(+) cells, fewer CD4(+) cells, many CD45RO(+) cells were present. Positivity for IFN-gamma and TNF-alpha was showed in granulomatous areas and near vessels.

Conclusion These cells play a significant role in the formation of the chalazion lesion. Neutrophils might be recruited into granulomatous lesions from the blood and may subsequently promote inflammatory cells accumulation both by direct cell to cell interactions and through the interaction of cytokines. The presence of IFN-gamma and TNF alpha suggests that these cytokines play a paracrine role in chalazion inflammation-

■ 182

Apoptotic Mechanisms in Staphylococcus epidermidis Experimental Endophthalmitis

PHARMAKAKIS N (1), VANTZOU C (1), PETROPOULOS I (1), ANASTASSSIOU E (2), ZOLOTAS V (3)
(1) Ophthalmology, University of Patras, Patras
(2) Microbiology, University of Patras, Patras
(3) Pathology, University of Patras, Patras

Purpose Purpose To investigate the potential role of apoptosis and its regulators bcl-2, bax and Fas in experimental endopthalmitis, due to S. epidermidis (S.epid.).

Methods Experimental endophthalmitis was induced in one eye of 48 Lewis rats by intravitreal injection of S.epid. slime producing strain while control rats received a similar sterile normal saline injection. The injected eyes were graded clinically and they were removed at 6, 12, 24, 48, 72 hours, and 7 days after injection. Retinal tissues were subjected to a) immunohistochemistry for bax, bcl-2 and Fas, and b) to in-situ hybridization (TUNEL method) for the detection of cells undergoing apoptosis.

Results Apoptotic bodies were detected in ganglionic cells (GC) and cones/rodes (C/R); in the latter their expression was lower compared to that of GC ($p<0.01$). In both instances apoptosis index (AI) was higher in sections from S.epid. group at all time points, compared to the control group ($p=0.008$ for GC and $p=0.006$ for C/R). Regarding GC apoptosis in S.epid. group instances, AI reached its peak in 48hrs ($p=0.013$ compared to group A). Similar results were recorded for cones/rodes ($p=0.013$ in 48 hrs). Bax and Fas expression displayed similar alterations to those of AI. Bcl-2 expression was not detected. Spearmanr rank correlation revealed a direct relation between bax protein expression and AI ($p<0.01$).

Conclusion This study demonstrates that apoptosis may be involved in the pathogenesis of S.epid. endophthalmitis. The absence of bcl-2 expression suggests that other inhibitors of apoptosis may be involved in the development and progress of the specific entity.

■ 183 / 1235

P53 expression in the lens after ultraviolet radiation (UVR) exposure

AYALA MN (1, 2), STRID H (3), DONG X (4), SÖDERBERG PG (4)
(1) Eye Department, Örebro University Hospital, Örebro
(2) Research Department St. Erik's Eye Hospital, Stockholm
(3) Clinic Research Centre, Örebro University Hospital, Örebro
(4) St. Erik's Eye Hospital, Karolinska Institutet, Stockholm

Purpose Background: The tumor-suppressor gene p53 encodes a phosphoprotein involved in the control of cell growth. Its expression and function have been documented in malignancy, apoptosis, and other abnormal cell proliferation processes. Apoptosis due to UVR is a well-described process in the lens. Recently, expression of p53 has been demonstrated in the normal murine eye. Purpose: to localize p53 in the albino rat lens and to study if p53 expression increases due to UVR exposure.

Methods Altogether 10 Sprague-Dawley albino rats were unilaterally exposed to UVR meanwhile the other eye was used as control. 1 week after exposure the rats were sacrificed, lenses were extracted, 10 lenses (5 exposed and 5 no exposed) were analysed by immunohistochemistry to localize p53 and 10 lenses (5 exposed and 5 no exposed) were analysed by real-time PCR to estimate p53 expression.

Results Immunohistochemistry showed that p53 was localized in the lens epithelial cells. Real-time PCR showed that P53 expression was higher in lenses exposed to UVR than in no exposed lenses.

Conclusion In the lens apoptosis induced by UVR seems to be mediated by P53 increased expression.

■ 184

A Randomized prospective study comparing 3 methods for providing topical anaesthesia in cataract surgery

SHIEW M, NAGAR M, IONIDES A
St George's Hospital, London

Purpose To compare 3 methods of providing topical anaesthesia for cataract surgery in terms of their relative efficacies

Methods Patients having topical anaesthetic cataract surgery were recruited and randomised to one of 3 groupsGroup 1 - g.Amethocaine onlyGroup 2 – g.Amethocaine and intracameral lignocaine 1%Group 3 – g.Amethocaine and oral Paracetamol 1hour pre opA verbal questionnaire was delivered to the patient at various points perioperatively. Surgeons were asked questions relating to ease of operation

Results 45 eyes were recruited into the study. Each group was demographically similar. Surgical details and complication rates were also similar between groups. Supplemental drops were needed in Grp 1 (25%), Grp 3 (20%). One patient in Group 1 required a subtenons injection for pain relief. None of the patients in Group 2 required any supplemental anaesthesia. Pain scores of 0(no pain)-10(worst pain ever felt) were used in this study. These were scored at three points in each operation (placing of pre-op drops, during the surgery and during a sub-conjunctival injection at the end of surgery). All three groups had the same average total pain score (pain score of 3). Intraoperative pain scores for each group were similar to pre-op drop scores

Conclusion Most importantly, there was no significant difference in the experience of pain between the three groups of patients. However, supplemental anaesthesia was required in groups 1 and 2 during surgery. In most cases this was the additional instillation of Amethocaine drops at various points during surgery. In group 1 a patient required subtenons injection of local anaesthetic. These findings may indicate an advantage in the use of supplemental intracameral lignocaine1%

EVER-2004-abstractbook.indd 38 8/19/04 12:25:57 PM

185

Psychological and physiological effects of different type of local anaesthesia for cataract surgery

GOMBOSS K (1), JAKUBOVICS E (2), KUSNYERIK A (3), SALACZ Gy (1)
(1) 2nd Department of Ophthalmology, Semmelweis University, Budapest
(2) Department of Physiology and Morfology, Semmelweis University, Budapest
(3) St Istvan Hospital, Eye Department, Budapest

Purpose We compared the psychological and physiological effects of retrobulbar and topical anaesthesia on patients undergoing cataract surgery. Some of them received psychotherapy before and during the procedure.

Methods 112 eyes affected by cataracts were randomised and divided into four groups: in group A/I, 47 eyes received topical anaesthesia, in group A/II, 10 eyes received topical anaesthesia and psychotherapy before and during the operation. In group B/I, 45 eyes received retrobulbar anaesthesia, in group B/II, 10 eyes received both retrobulbar anaesthesia and psychotherapy.Patients were tested by STAI, face scale tests and questionnaires before, during and immediately after the operation, and on the following day. Objective parameters were measured (blood pressure and pO2, white blood cells, catecholamine, corticosteroide and glucose levels of plasma) before and after the operation.

Results Satisfactory levels of anaesthesia for cataract surgery were achieved, within all of the groups. In group A (I and II), 23% of the patients reported pain during the operation, while only 3.6% in group B (I and II) (p= 0.002). In group A (I and II) significantly higher systolic blood pressure (p=0.021, F= 0.014, t=0.906) and lower heart rates were measured during the operation. Psychotherapy did not affect the results significantly, but in certain cases the patients' opinions about operation procedure were more favourable.

Conclusion With the retrobulbar technique, we were able to ensure more stable levels of vegetative parameters and patients felt less discomfort and pain during the operations than with topical anaesthesia. Psychotherapy had a positive effect in certain cases.

186

Intra-operative complications of phacoemulsification

TAHHAN M (1), GOGI D (2), RACHDAN D (3), WEHBEH ML (3), THOMPSON S (4)
(1) Sandwell Hospitals, West Browmich
(2) Sandwell, West Bromwich
(3) Sandwell, West Browmich
(4) Sandwell, Birmingham

Purpose National complication surgical survey in 1997/98 reported that intra-operative(phaco) cataract complications are 7.5% and the posterior capsule and vitreous lost are 4.4% of the complication, and the presence of ocular co-morbidity increase the risk of intra-operative complications.This study enumerated the complications during phacoemulsification over a 1 year period, and compared it with the National Complication Surgical survey. Further we assessed the visual outcome in these cases and correlated it with the ocular co-morbidity.

Methods 1168 cataract surgeries at Sandwell District General Hospital between 1st of March 2002 to 28th of February 2003. Intra-operative complications occurring during phacoemulsification were collected from the complication register. The entries in the complication register and surgical notes were compared. Pre existing eye conditions and the pre and post operation visual acuity were noted.

Results The complications were seen in only 39 (3.3%) of the 1168 phacoemulsification operations ; 1.6% were posterior capsule tear and vitreous lost, posterior capsule tear without vitreous loss was 0.5%, dropped nucleus was 0.08%, iris trauma 0.6%, corneal burn 0.14%. Seventy percent of these complicated operations had 6/12 or better, 28% had vision between 6/18 and 6/60 and 2% had 6/60.

Conclusion Incidence of complication at Sandwell District General Hospital was 3.3% which was half of the rate mentioned in NCSS. The posterior capsule tear and vitreous lost rate at Sandwell was 1.6% which was nearly one fourth of the rate of NCSS. Furthurstill, we were able to attain good vision in more than two thirds of these patients signifying efficient management strategy and high quality patient care.

187

Intraocular Eye Lash foreign Body

ISLAM N (1), DABBAGH A (2)
(1) Moorfields Eye Hospital - Medical Retina, London
(2) Moorfields Eye Hospital - Glaucoma, London

Purpose To describe the presentation and appearance of an unreported complication following cataract surgery.

Methods Case Report. Anterior segment photographs.

Results The apparently sterile large intraocular foreign body eye lash did not cause endophthalmitis at 3 months follow up. The patient declined further surgery for removal of the foreign body and did not suffer from pain, photophobia nor monocular diplopia.

Conclusion Careful preoperative preparation and meticulous draping of the eyelids should be performed to avoid such a complication.

188

The Relationship between the Effective Phaco Time (EPT) and Gender, Age at Surgery, Anterior Chamber Depth, Lens Thickness and Preoperative Visual Acuity

ELGOHARY MA (1, 2), BECKINGSALE AA (1)
(1) Ophthalmology, Colchester
(2) Ophthalmology, London

Purpose To examine the relationship between gender, age at surgery, anterior chamber depth (ACD), lens thickness (LT), axial length (AL) and preoperative best-corrected visual acuity (BCVA) and the Effective Phaco Time (EPT), which is known to correlate with increased nuclear hardness and damage of the blood–aqueous barrier.

Methods This is a retrospective study of a consecutive case series of 47 eyes of 45 patients, 30 of whom (67%) were female. All the patients were operated on by a single surgeon using Sovereign phaco machine (Allergan) and stop-and-chop technique. Patients with posterior subcapsular cataract or those with concurrent ocular pathology were excluded.

Results The EPT positively correlated with age at surgery ($r=0.28$, $p<0.03$) and negatively correlated with preoperative Snellen's visual acuity ($r=-0.54$, $p<0.001$), ACD ($r=-0.41$, $p=0.004$) and LT ($r=-0.45$, $p=0.002$). There was no significant correlation between the EPT and the axial length and no significant difference between the EPT of male and female patients.A multivariate analysis showed that the increase in EPT was significantly associated with the decrease in preoperative BCVA ($\beta=-2.54$; $p<0.001$), ACD ($\beta=-7.63$; $p=0.012$) and LT ($\beta=-10.46$; $p<0.001$) but not with the increase in age ($\beta=0.25$; $p=0.058$).

Conclusion Our findings indicate that preoperative BCVA, ACD and LT may be used to gauge the EPT and perhaps the nuclear hardness and difficulty of the case. This should help planning the surgery and selecting the cases for the trainees. The results will need to be verified across surgeons.

EVER-2004-abstractbook.indd 39 8/19/04 12:25:57 PM

■ 189

Visual Outcomes of cataract surgery and posterior chamber IOL implantation in AIDS patients

FERNANDO AI (1), PURI P (2), MITCHELL S (2)
(1) Ophthalmology, Chelsea and Westminister Hospital, London
(2) as above, UK

Purpose Evaluate cataract surgery outcomes in AIDS patients undergoing phacoemulsification and posterior chamber IOL implantation.

Methods Prospectively generated database of patients undergoing cataract extraction at a tertiary care centre from April 1999 to March 2004. Data on patient demographics, visual acuity at cataract surgery, presence/absence of CMV retinitis (and if present macular involvement), concurrent use of highly active anti-retroviral therapy (HAART) and CMV treatment were collected. Cataract surgery details, perioperative complications and final visual acuity were obtained retrospectively. Patients with concurrent ocular pathology or previous vitreoretinal intervention were excluded.

Results 20 eyes of 15 men aged 37-68 years were included. All patients were on HAART, with 11 patients having had CMV treatment in the past, 2 patients still on oral ganciclovir and one patient had an intravitreal injection intraoperatively.Best corrected preoperative Snellen visual acuity was better than 6/12 in 5 eyes, between 6/12 and 6/24 in 4 eyes, between 6/36 and 6/60 in 5 eyes and worse than 6/60 in 6 eyes. All patients underwent routine phacoemulsification with acrylic posterior chamber IOLs. Postoperative corneal oedema and transient intraocular pressure rises were seen in 6 eyes with one eye developing postoperative retinal detachment. Final visual acuity was better than 6/9 in 10 eyes, between 6/12 and 6/24 in 4 eyes, between 6/36 and 6/60 in 5 eyes and worse than 6/60 in one eye. Macula involvement with CMV retinitis was the major factor responsible for poor visual outcome in 7 eyes.

Conclusion Phacoemulsification with IOL implantation provided good visual recovery in AIDS patients provided there was macula sparing CMV retinitis.

■ 190

AcrySof (SA60AT) and AcrySof Natural (SN60AT): can they be distinguished after intraocular implantation?

TEIXEIRA C (1), FREITAS S (1), ROCHA-SOUSA A (1, 2), COENTRÃO L (1), CAPÃO-FILIPE J (1, 3), FALCÃO-REIS F (1, 3)
(1) Ophthalmology of S. João Hospital, Porto
(2) Physiology of Porto Medical School, Porto
(3) Ophthalmology of Porto Medical School, Porto

Purpose To compare the visual behaviour of Acrysof Natural and AcrySof (Alcon) intraocular lenses (IOLs). AcrySof Natural is an IOL similar to Acrysof except by its capacity to absorb blue-light.

Methods Twenty-two patients submitted to cataract facoemulsification extraction by the same surgeon, with two different procedures: Group 1 patients received an AcrySof Natural IOL implant in one eye and an Acrysof IOL in the other (n=9); Group 2 patients had an implant of AcrySof Natural IOL in one eye and maintained an incipiens cataract in the other (n=13). The following parameters were evaluated in all patients: visual acuity (VA), automated perimetry, Farnsworth-Munsell 100-hue test, chromatic contrast sensibility (CCS) test and achromatic contrast sensibility (ACS) test (with and without dazzling).

Results In Group 1: eyes with AcrySof IOL showed greater protan (6,11±0,64 versus 7,6±1,08) and tritan (9,87±0,70 versus 13,7±1,73; $p<0.05$) CCS thresholds than eyes with AcrySof Natural IOL; eyes with AcrySof IOL presented lesser ACS threshold with dazzling at short (15cpg; 6,75±1,02 versus 9,17±1,34; $p<0.05$) and mean (12cpg; 13,0±7,65 versus 21,67±5,97; $p<0.05$) special frequencies than eyes with AcrySof Natural IOL. In Group 2: eyes with AcrySof Natural IOL showed lesser CCS and ACS thresholds than eyes with incipiens cataracts ($p<0.05$).

Conclusion AcrySof presents better dazzling ACS and has better tritan axis CCS than Acrysof Natural. Acrysoft Natural has an abortion of blue light more similar to the senerescent crystalline than to Acrysoft. It is important to know what kind of IOL was implanted to valorise the results of contrast sensibility tests.

■ 191

Nd:Yag capsulotomy and its effect on refractive status in patients with silicone foldable lenses

DE WIT DW (1), SALEH GM (2), GALIBA V (3), ALLEN R J (4)
(1) Ophthalmology, Essex County Hospital, Colchester
(2) Ophthalmology, Queen Mary's Hospital, Sidcup, South London
(3) ophthalmology, Leeds General Infirmary, Leeds
(4) Optometry, Colchester

Purpose To investigate refractive changes post Nd:YAG capsulotomy in patients fitted with silicone foldable lenses and the need for routine refraction post Nd:Yag capsulotomy.

Methods Sixty eyes with uncomplicated phacoemulsification and silicone foldable lens implant (CLARIFLEX® IOL) were included. Objective and subjective refraction were performed to get the best visual acuity before and after Nd:YAG capsulotomy.

Results The spherical equivalent before the Nd:YAG capsulotomy was -0.58 +/- 0.70 and after the capsulotomy, -0.57 +/- 0.78.The paired Student's t-test showed no significant difference in the refraction following Nd:YAG capsulotomy.

Conclusion Routine refraction is unnecessary following Nd:YAG capsulotomy in patients who have had uncomplicated phacoemulsification using CLARIFLEX® IOL intraocular lenses.

■ 192

A dynamic light scattering study of the reversibility of protein dynamics during cold cataract formation

PHARMAKAKIS N (1), PETTA V (2), PAPATHEODOROU G (2), YANNOPOULOS S (3)
(1) Opthalmology, University of Patras, Patras
(2) Chemical Engineering, University of Patras, Patras
(3) FORTH-ICE/HT, Patras

Purpose To find possible indicators and investigate the reversibility of cold cataract formation, and the role of structure and dynamics of protein aggregation with the aid of Dynamic Light Scattering (DLS).

Methods Porcine lenses were placed into an optical cell whose temperature could be adjusted. The lowest temperature reached was at 4 C, where a full opacification of the lens occurred. In order to investigate the reversibility of the cold cataract formation, the temperature of the lens was raised to 37 C.

Results Time correlation functions obtained by the DLS technique are monotonously decaying exponential or stretched-exponential curves. The decay steps at short and long time scales are associated with "particles" of small and bigger size, respectively. The analysis of the experimental data showed that the diffusion dynamics of both the fast and the slow component become progressively sluggish with decreasing temperature; this effect becomes dramatic below 17 C. It has also been observed a systematic increase of the amplitude of the slow component relatively to that of the fast one while decreasing the temperature of the lens. This effect becomes prominent below 25 C.

Conclusion The analysis of the experimental time correlation functions has revealed systematic changes in the dynamics of crystallines' diffusion and in the growth of aggregates with decreasing temperature. Based on these two observations, useful indicators can be found for monitoring cold cataract formation. However, it is not yet fully understood whether the slowing-down of the diffusion dynamics or the change in the ratio of the weight factor of the fast to that of the slow component is the best indicator of cataract formation.

EVER-2004-abstractbook.indd 40 8/19/04 12:25:58 PM

■ 193

Pseudophakic monovision for good near and distance uncorrected visual acuity

JAHN CE, TÖPFNER VON SCHÜTZ K, JAHN SE, STROTMANN H
Augenpraxisklinik Dr. Jahn, Kempten

Purpose To examine the usefulness of pseudophakic monovision to achieve good bilateral uncorrected distance and near visual acuity and to evaluate the risks of such an approach when using monofocal intraocular lenses.

Methods We examined uncorrected visual acuity as a function of distance for bilaterally pseudophakic subjects.We also examined the deviations of obtained pseudophakic refractions from predicted pseudophakic refractions after implantation of a PC/IOL in 250 consecutive eyes.

Results The analysis of uncorrected viusal acuity at distances between 40 cm and infinity demonstrated that the rarely encountered combination of slight myopia (-0,25, -0,5 dpt) in one eye together with moderate myopia (–1,5 dpt) in the second eye yielded a large object-room for which high uncorrected visual acuity exists. In the analysis of obtained pseudophakic refractions mean and median deviations from predicted refraction were 0.1 dpt + 0.8 dpts rsp. 0 dpt (range –3.0 dpt to +2.75 dpt) indicating only moderate chances of succes in obtaining the desired refractions in combination with substantial risk of generating uncomfortable amount of anisometropia.

Conclusion A subset of patients with pseudophakic monovision can do without correcting glasses for near and distance vision. Currently this can only be achieved on purpose with little precision and by taking the risk of creating disturbing anisometropia due to the limited accuracy of biometry for predicting postoperative refraction. Both problems could be overcome using PC/IOLs which can be adjusted after implantation. This would make intended monovision a valid strategy for cataract surgery.

■ 194

Effect of ultraviolet radiation-B on development of cataract in albino rats in vivo and effect on lens ascorbate content

MODY VC Jr (1), KAKAR MK (1), ELFVING Å (2), LÖFGREN S (1), AYALA M (1), DONG X (1), MEYER L (1), SÖDERBERG PG (1)
(1) Karolinska Institutet/St. Erik's Eye Hospital, Stockholm
(2) Karolinska Institutet/Department of Physiology and Pharmacology, Stockholm

Purpose To investigate Maximum Tolerable Dose (MTD) for UVR-B-induced cataract in albino rats and to study effect of UVR-B eye exposure on lens ascorbate content.

Methods Part one: Fifty female Sprague Dawley rats, 7 weeks of age, were divided into five groups and unilaterally exposed to UVR-B (300 nm) under anesthesia in vivo, receiving between 0 and 4.9 kJ/m2 over a duration of 15 minutes. Each rat was sacrificed 7 days after exposure. Lenses were extracted in vitro, and intensity of forward light scattering was determined. Lenses were saved for ascorbate measurement. Data were analyzed with regression. Part two: Each lens was processed using homogenization in metaphosphoric acid, centrifugation, and ultrafiltration. The ultrafiltrate was injected into an HPLC column equipped with a 254 nm ultraviolet detector for ascorbate measurement.

Results Part one: MTD estimation. Animals exposed to UVR-B dose greater than or equal to 3.5 kJ/m2 developed cortical cataract. MTD for avoidance of UVR-B-induced cataract was estimated to 3.01 kJ/m2. Part two: Effect of UVR-B exposure on lens ascorbate content. Means and 95% confidence intervals for difference in lens ascorbate concentration (micromol/g wet weight lens) between UVR-B-exposed minus non-exposed lenses were: -0.004± 0.004 [0 kJ/m2 UVR-B]; -0.027± 0.010 [0.25 kJ/m2 UVR-B]; -0.104± .013 [3.5 kJ/m2 UVR-B]; -0.103± 0.013 [4.3 kJ/m2 UVR-B]; -0.111± 0.009 [4.9 kJ/m2 UVR-B].

Conclusion MTD for avoidance of UVR-B-induced cataract in the albino rat was estimated to 3.01 kJ/m2. UVR-B exposure decreases lens ascorbate content in the rat, with a supra-threshold UVR-B dose having greater effect than a sub-threshold dose.

■ 195

Ascorbate effect on development of ultraviolet radiation-B (UVR-B)-induced cataract in cultured rat lenses

KAKAR MK (1), MODY JR VC (1), LUNDBERG B (1), ELFVING Å (2), LÖFGREN S (1), MEYER L (1), DONG X (1), AYALA M (1), SÖDERBERG PG (1)
(1) Karolinska Institutet/St. Erik's Eye Hospital, Stockholm
(2) Karolinska Institutet/Dept. of Physiology and Pharmacology, Stockholm

Purpose To investigate loading of ascorbate into lenses in vitro and to study whether ascorbate protects against UVR-B-induced cataract in vitro.

Methods Part #1: Six Sprague-Dawley rats were sacrificed and lenses extracted. Lenses were incubated for 5 hours in culture medium with 0 mM or 4 mM ascorbate. Thereafter, each lens was processed and HPLC with ultraviolet detection was used for ascorbate measurement.Part #2: Ten Sprague-Dawley rats were sacrificed and lenses extracted. Lenses were incubated for 5 hours in culture medium with 0 mM or 4 mM ascorbate. Both lenses from each animal were exposed to 2.0 kJ/m2 UVR-B (302 nm) and cultured. On day 1, 3, 5, and 7 after exposure, lens forward light scattering was measured.

Results Part #1: Lens ascorbate concentrations expressed as means ± 95% confidence intervals (micromol/g wet weight lens) were 0.208 ± 0.019 [0 mM ascorbate] and 0.903 ± 0.069 [4 mM ascorbate]. Part #2: UVR-B exposed lenses developed severe cortical cataract. The means ± 95% confidence intervals of forward light scattering (tEDC) for the lenses incubated with 0 mM ascorbate for the post-UVR-B exposure time points were: 0.067 ± 0.013 [1 day]; 0.168 ± 0.023 [3 days]; 0.429 ± 0.067 [5 days]; 0.473 ± 0.022 [7 days]. For the lenses incubated with 4 mM ascorbate, the measurements were: 0.062 ± 0.015 [1 day]; 0.158 ± 0.021 [3 days]; 0.455 ± 0.083 [5 days]; 0.475 ± 0.034 [7 days].

Conclusion The ascorbate concentration in rat lenses increased with ascorbate loading in culture medium for 5 hours. Increased ascorbate content in the rat lens did not protect against UVR-B-induced cortical cataract in vitro.

■ 196

Genomic organization and mRNA heterogeneity of LENGSIN, a glutamine synthetase-like protein preferentially expressed in lens

GRASSI F (1, 2), BETTI M (3), MáRQUEZ A (3), MARAINI G (1), OTTONELLO S (2)
(1) Dipartimento di Scienze Otorino Odonto Oftalmologiche, Parma
(2) Dipartimento di Biochimica e Biologia Molecolare, Parma
(3) Departamento de Bioquímica Vegetal y Biología Molecular, Sevilla

Purpose To learn more about the gene anatomy and expression pattern of Lengsin (LGS), an abundant transcript in the human lens that codes for a protein resembling prokaryotic glutamine synthetase (GSI).

Methods Gene searches were carried out with the Ensembl Genome and NCBI browsers. Phylogenetic trees were constructed with the neighbour-joining algorithm. cDNA was prepared by RT of total RNA extracted from transparent human epithelial-capsule samples. PCR amplification primers for the LGS mRNA were designed on the cDNA sequence available at NCBI (AF242388). The resulting amplicons were cloned.

Results BLAST searches indicate that the LGS gene is only present in vertebrates. Standard programs predict three introns in the LGS gene from Homo sapiens. Instead, we identified three cDNAs upon RT and PCR amplification mapping of total RNA from human lenses. One of them matches the sequence found in the NCBI database. Another cDNA lacks the central region of the last exon, whereas the third cDNA contains an unspliced portion of the second putative intron, which blocks the reading frame. We propose that human LGS undergoes extensive alternative splicing. As revealed by phylogenetic analyses, LGS forms a unique cluster that is closer to GSI than to eukaryotic GS (GSII). Sequence similarity to GSI regards sites involved in oligomerization, glutamate or metal cation binding.

Conclusion These data raise a number of questions as to the mode of expression and possible function of LGS in the lens. LGS may share only a subset of the functions of true GS enzymes. Human LGS2 is currently being expressed as a recombinant protein.

EVER-2004-abstractbook.indd 41 8/19/04 12:25:58 PM

■ 197

The ubiquitin-proteasome pathway competes with heat shock proteins for denatured proteins in the lens

MARQUES C (1, 2), PEREIRA P (1), GUO W (2), TAYLOR A (2), SHANG F (2)
(1) IBILI - Center of Ophthalmology, Coimbra
(2) Human Nutrition Research Center Aging, Boston

Purpose Protein misfolding and aggregation are associated with the pathology of many age-related diseases. The objective of this study is to define the interaction between the ubiquitin-proteasome pathway (UPP) and the chaperone machinery in the cells.

Methods To determine the interaction between the UPP and heat shock proteins during protein quality control, we used heat denatured firefly luciferase as a model subtrate. The renaturation of the denatured proteins was determined in rabbit reticulocyte lysate (RRL) in the presence or absence of a ubiquitin ligase (CHIP) or an isopeptidase (UBPy). Luciferase activity in the cells was determined to monitor the refolding of denatured luciferase.

Results Heat denatured luciferase was preferentially ubiquitinated and degraded by the UPP as compared with the native form. CHIP promoted the ubiquitination and degradation of the denatured luciferase. However, CHIP inhibited the refolding of thermally denatured firefly luciferase in vitro in the presence of Hsp90. On the other hand, UBPy, which remove ubiquitin from the substrates, enhanced the renaturation. Furthermore, removal of proteasome from RRL increased renaturation.

Conclusion These results demonstrated that the UPP is involved in protein quality control by selective degradation of denatured proteins. The ubiquitin conjugation machinery utilizes the same mechanism as heat shock proteins to recognize denatured proteins, therefore it works in a concert or competitive manner with heat shock proteins to remove proteins with abnormal structures. This quality control is relevant to maintaining protein in solution thereby account for lens tranparency.

■ 198

7-ketocholesterol stabilises ubiquitin activating enzyme E1 in lens epithelial cells

GIRAO H, CATARINO S, PEREIRA P
IBILI - Centre of Ophthalmology, Coimbra

Purpose Activation of ubiquitin by the formation of a high-energy thiol ester with the ubiquitin-activating enzyme (E1) is the first step in the ubiquitination-proteasome pathway (UPP). The objective of this study is to evaluate the effects of oxysterols on the activity of E1 in the lens.

Methods Lens epithelial cells were incubated with 7-ketocholesterol and the levels of E1 determined by western blot. The effect of 7-keto on the transcription and translation of E1 was evaluated by incubation with cycloheximide or actinomycin B, respectively. Activity of E1 and E2s was determined by their ability to form 2-mercaptoethanol labile thiol-ester bonds with [125I]-ubiquitin. mRNA levels were determined by northern blot. The effect of 7-keto on the turnover of the E1 was evaluated by metabolic labelling with [35S]-methionine. Subcellular distribution of E1 was evaluated by immunofluorescence confocal microscopy.

Results 7-keto induced accumulation of E1, while mRNA levels were not altered. Incubation of lens epithelial cells with protein synthesis inhibitor did not prevent the accumulation of E1 induced by 7-keto, suggesting that E1 synthesis was not being affected. The half life of E1 increased when cells were incubated with 7-keto as did the enzymatic activity. Immunofluorescence analysis showed that 7-keto induces an accumulation of E1 in the nucleus.

Conclusion 7-keto induces accumulation of E1 in lens epithelial cells through a mechanism that involves a decrease in the turnover of the protein. The increased stability of E1 is probably due to an effect of 7-keto in the pathways involved in degradation of the protein. Accumulation of E1 in the lens may disrupt regulation of UPP thus contributing to loss of lens transparency.

■ 199

High glucose levels affects markers of oxidative stress and proteolytic activity in human lens epithelial cells and intact mouse lenses

PÅLSSON AZ, PETERSEN A, KARLSSON J-O
Inst of Anatomy & Cell Biology,University of Goteborg, Goteborg

Purpose To investigate the mechanisms behind lenticular/cellular damage due to high levels of glucose.

Methods Confluent human lens epithelial cells (HLEC) and whole mouse lenses were exposed to 50 mM glucose for 24 hours. Sections of fixed cultured mouse lenses were examined by light microscopy. By the use of cell permeable fluorogenic indicators we monitored, on line, intracellular proteolytic activity and markers for oxidative damage. The following fluorogenic substrates were used; 50 µM LLVY-AMC for detection of proteolytic activity. 5 µg/ml Rhodamine 123 and 25µM Monochlorobimane for analysis of alterations in mitochondrial membrane potential and glutathione (GSH) levels respectively. The production of superoxide was monitored through 5 µM HET, and peroxides were assayed with 20µM DCFH-DA.

Results In the presence of 50 mM glucose the mouse lens showed globulization, liquefaction and fiber cell swelling of equatorial cortex. The epithelial layer in the germinative zone shows an increase in cell height and signs of degeneration. The level of GSH was significantly increased by 18 % during high glucose. There was also a significant decrease by 17 % in peroxide levels in HLEC but an increase by 32 % in the intact mouse lenses. No change was observed in superoxide levels and mitochondrial membrane potential compared to control. Proteolytic activities at high glucose levels were 1,7 and 3,8 fold higher in intact mouse lens and HLEC, respectively.

Conclusion The glucose-induced lenticular/ cellular damage may be the consequence of uncontrolled activation of proteolytic systems due to changes of oxidative stress. In the epithelial cells high glucose induced an adaptive antioxidant response.

EVER-2004-abstractbook.indd 42 8/19/04 12:25:59 PM

201 / 2146

Human papillomavirus - cause of epithelial lacrimal sac neoplasia?

SJO NC (1), BUCHWALD C (2), FLAMANT P (3), HEEGAARD S (1), LINDEBERG H (4), NORRILD B (5), PRAUSE JU (1), ORTH G (3)
(1) Eye Pathology Institute, Copenhagen
(2) ENT department, Copenhagen
(3) Papillomaviruses Unit, Paris
(4) Oral Pathology Laboratory, Aarhus
(5) Protein Laboratory, Copenhagen

Purpose Tumours of the lacrimal sac are rare but important entities that may carry a grave prognosis. The purpose of the study was to investigate papillomas and carcinomas of the lacrimal sac for the presence of human papillomavirus (HPV)

Methods Five lacrimal sac papillomas and six lacrimal sac carcinomas (four transitional cell carcinomas and two squamous cell carcinomas) were investigated for presence of HPV with polymerase chain reaction (PCR) technique, DNA in situ hybridisation (ISH) and mRNA ISH. HPV positive specimens were investigated by PCR with type specific probes for HPV types 6/11, 16 and 18. Furthermore, ten specimens of dacryocystitis were included in the PCR reactions as control of HPV prevalence in inflamed, vulnarable lacrimal sac mucosa.

Results HPV was present in five of five lacrimal sac papillomas and in four of six lacrimal sac carcinomas. All transitional cell carcinomas were HPV positive, whereas the squamous cell carcinomas were HPV negative.The analysis with type specific probes identified HPV type 6/11 in the papillomas and both HPV types 6/11 and 16 in the lacrimal sac carcinomas. All specimens of dacryocystitis were HPV negative. DNA ISH and mRNA ISH was positive in three specimens; two papillomas and one transitional cell carcinoma.

Conclusion We demonstrated human papillomavirus in all lacrimal sac papillomas suitable for PCR analysis and in four of six carcinomas of the lacrimal sac using PCR technique. Thus our investigation found a strong association between HPV and lacrimal sac papillomas and –carcinomas.

202 / 2147

Erdheim-Chester disease: severe orbital involvement treated by Vinblastin associated to Interferon

TONINI M (1), SARROT-REYNAUD F F (2), BERNAL DESCOUR F (1), MOUILLON M (1), ROMANET JP (1)
(1) Ophthalmology, Grenoble
(2) Internal medecine, Grenoble

Purpose To describe a patient with Erdheim-Chester disease and to outline treatment. Erdheim-Chester disease is a xanthogranulomatos disease which can involved orbital, bone, neural, pulmonary and cardiac tissues.

Methods Case report:We report a case of a 62-year-old female with hypophyse, bone, and orbital involvement. She experienced a severe proptosis, with elevated intraocular pressure and optic nerve compression. Several treatments were used and their efficacy were assessed.

Results Systemic steroids were used first, and resulted in an incomplete recovery of the orbital findings and a lot of side effects. So steroids were discontinued and replaced by Vinblastin associated to Interferon. After a 10 month follow up, the patient had no more proptosis, bone and hypophyse involvement remained stable. No side effect occured.

Conclusion Vinblastin associated with interferon is an effective therapeutic modality in patients with severe or steroid-resistant Erdheim-Chester disease.

203 / 2148

Pilomatrixoma: A Reminder (Clinical &Histopathological Similarity to Basal Cell Carcinoma)

TAHHAN M (1), BENSKIN S (2), ASHWIN P (3), KASMIYA M (3)
(1) Sandwell and West Birmingham Hospitals, West Browmich
(2) Sandwell Hospital, West Browmich
(3) Dudley Gest Hospital, Dudley

Purpose Pilomatrixoma is a relatively benign skin neoplasm. Eyelid pilomatrixoma derived from hair follicles are rare and frequently misdiagnosed as basal cell carcinoma. Three cases of Pilomatrixoma have been studied for the similarity with Basal cell carcinoma and how can we avoid that and what is the best surgery for it.

Methods three cases of pilomatrixaoma been studied for the clinical presentaion and histological apperance similaraty with BCC.what is the best histopathology methods can be used.

Results Eyelid pilomatrixomafrequently misdiagnosed as basal cell carcinoma,if evaluation is based on clinical evidence alone due to the tumour presenting as a hard nodule with possible erosion through the skin. Histologically, especially in partial biopsies they can be confused with basal cell carcinoma.

Conclusion The pilomatrixoma may be safely excised with a narrow margin of clearance. Whereas a macroscopic clearance of 3 to 5 mm or surgery with frozen section histological control is desirable for excision of basal-cell carcinoma. Therefore in suspicious cases, wide excision can be avoided if the diagnosis of pilomatrixoma is confirmed on incisional biopsy.

204 / 2149

Orbital involvement in multifocal fibrosclerosis

HEEGAARD S (1), KYHN M (1), HERNING M (2), PRAUSE JU (1)
(1) Eye Pathology Institute, University of Copenhagen, Copenhagen
(2) Danish Research Centre for Magnetic Resonance, University Hospital Hvidovre, Hvidovre

Purpose To present the clinical and histopathological findings in a patient with sclerosing, idiopathic orbital inflammation and retroperitoneal fibrosis.

Methods A 40-year-old Caucasian woman presented with diplopia, swelling and erythema of her right eye region. An orbital CT scan showed thickening of the lateral rectus muscle and of the lacrimal gland. During the following 6 months the patient developed right flank- and abdominal pain. Abdominal CT images revealed a retroperitoneal tumor shredding the aorta and the ureteres. An explorative laparatomy disclosed retroperitoneal tumour masses and a biopsy was performed. Systemic treatment with prednisolone was initiated, resulting in regression of symptoms. When prednisolone was discontinued the orbital symptoms recurred and a lateral orbitotomy was performed.

Results Histopathological examination of the tissue from the orbit and the retroperitoneum demonstrated the same morphology with masses of dense, hyalinised fibrous tissue. Areas with moderate, diffuse lymphocyte and plasma cell infiltration were seen. A heterogeneous lymphocytic cell population was identified.

Conclusion We present a case of multifocal fibrosclerosis with similar histopathological morphology of the two involved regions. Aetiology and treatment of the disease is discussed.

EVER-2004-abstractbook.indd 43 8/19/04 12:25:59 PM

205 / 2247

Effects of Glivec®/STI571 in human uveal melanoma cell

MOURIALIX F (1, 2), LEFEVRE G (2), CALIPEL A (2), GLOTIN AL (2), MASCARELLI F (2)
(1) Service d'Ophtalmologie, Caen
(2) INSERM U598, Institut Biomédical des Cordeliers, Paris

Purpose c-Kit is expressed in 75% of primary choroidal melanomas. The pharmacological compound Glivec® inhibits the tyrosine kinase activity of c-Kit activation. We investigated the potential therapeutic role of Glivec®, in controlling uveal melanoma cell tumorigenesis.

Methods Six Melanoma cell lines were used in this study. Cells were treated with various concentrations of Glivec®, and cell proliferation was analyzed by the MTT method. The efficiency of Glivec® to affect the ability of cells to proliferate under anchorage-independent conditions and to form colonies in soft agar was also tested. Apoptotic cell death was analyzed with the annexin-V-EGFP and PI double-staining method. The percentages of apoptotic (annexin V-positive) and necrotic (IP-positive) cells were determined by flow cytometry.

Results Glivec® reduced cell proliferation in a concentration-dependent manner, but with various efficiencies. The efficiency of Glivec® depended on c-Kit levels in the uveal melanoma cell lines. SP6.5, Mel270, TP31 and 92.1 were the most sensitive to Glivec® treatment. Flow cytometry analysis showed that Mel270 underwent massive apoptosis after 48 hours of treatment, with cell death rates increasing by a factor of nine. Conversely, treatment with Glivec® did not induce cell death in the c-Kit-negative melanoma cell line, OCM-1. Glivec® greatly reduced the number of colonies of the c-Kit-positive melanoma cell line, Mel270, in methylcellulose whereas it had only a minor effect on the c-Kit-negative melanoma cell line, OCM-1.

Conclusion We provide the first evidence that Glivec®/STI571 could be used to treat uveal melanoma cell in vitro.

206 / 2248

A tale of two diagnoses : A case of ocular and intracranial tumors

MISSOTTEN GS (1), LAAN LA (2), DE WOLFF-ROUENDAAL D (1), DE KEIZER RJW (1)
(1) Dept Ophthalmology, Leiden University Medical Center, Leiden
(2) Dept Neurology, Leiden University Medical Center, Leiden

Purpose To present a patient with multiple congenital ocular surface tumours, cerebral calcifications and hypertrophic cerebral blood vessels. The report demonstrates the diagnostic difficulties in neurocutaneous syndromes.

Methods Case report

Results A one month old girl was presented at Leiden University with a conjunctival and subconjunctival mass in the right eye. Additionally, there were two dermoid-like corneal tumours. Further ocular examination showed no retinal or orbital anomalies. Paediatric examination revealed an idiopathic dismatury. No cutaneous lesions or ear appendages were found. The ocular masses were excised and sent for pathological examination. Histology showed a dermoid-like lesion, suggestive for neurofibroma. Staining was positive for CD34 and almost entirely negative for S100. Lack of S100 is uncommon for neurofibromatosis. The CD34 positivity is more characteristic for an angiofibromatous lesion. A tentative diagnosis of dermoid tumour with neurofibromatous characteristics' was made. Afterwards the child had a normal psychomotor development. At the age of three, the child developed convulsions. No indications for intracranial neurofibromatosis were found. Two months later a vascular anomaly typical for Sturge-Weber was found by a repeated CT scan. No ocular glaucoma, facial angioma, or other Sturge-Weber sign was found.

Conclusion The patient was diagnosed with an intracranial Sturge-Weber syndrome concomitant with congenital ocular neurofibromatosis/angiofibromateous tumours. To our knowledge this is the first report of this association. Histological differentiation of clinical neurocutaneous syndromes remains difficult. Repeated imaging may reveal unexpected associated conditions.

207 / 2344

Treatment of uveal melanoma near to the optic nerve or macula by strontium-90 brachytherapy

VAN GINDERDEUREN R (1), SPILEERS W (1), VAN LIMBERGEN E (2)
(1) oogziekten, Leuven
(2) radiotherapy, Leuven

Purpose Uveal melanomas localised near to the macula or the optic nerve are difficult to treat by brachytherapy because of the devastating radiation effect on the surrounding tissue. Strontium-90 has a limited penetration depth and very few radiation effects outside the treated area.

Methods Study of 6 clinical cases with uveal melanoma localisation in the area of the macula or nearer than 3 mm of the optic nerve. All patients were followed for at least 3 years and the visual acuity, visual fields and retinal and choroidal changes are investigated.

Results No optic nerve atrophy or radiaton retinitis was found after 3 years. All patients could retain good central vision and no loss of vision outside the treated area could be detected.

Conclusion Strontium-90 brachytherapy is favourable for the treatment of difficult uveal melanomas in the vicinity of the macula and the optic nerve without complications in the surrounding tissues

208

Co-expression of vimentin and cytokeratin as prognostic factor of metastases in experimental uveal melanoma

MORILLA A (1), CAISSIE AL (2), LOPEZ R (1), ORDOñEZ JL (1), BLANCO G (1), ALMARAZ A (3), SAORNIL MA (1), BURNIER MN (2)
(1) Ocular Oncology, Instituto Universitario de Oftalmobiología Aplicada (IOBA), Valladolid
(2) The Henry C. Witelson Ophthalmic Pathology Laboratory and Registry, McGill University, Montreal
(3) Epidemiology Department, School of Medicine, University of Valladolid, Valladolid

Purpose To determine the co-expression of vimentin (Vi) and cytokeratin (Ck) in the cells of primary ocular tumors and lung metastases obtained from immunosuppressed rabbits injected with two uveal melanoma cell lines with different metastatic potential (SP 6.5, high; and OCM-1, low), and to correlate Vi-Ck co-expression with metastases appearance in this animal model.

Methods Fourty rabbits immunosuppressed with cyclosporine A were injected with one million cells of 92-1 cell line (n=20) and OCM-1 cell line (n=20). After 12 weeks, euthanasia was practiced and injected eyes, lungs and livers were fixed and paraffin-embedded. Samples were immunostained using ABC method with monoclonal antibodies against Vi and Ck 8-18. Sensitivity and specificity were calculated to correlate presence of metastases with co-expression of Ck-Vi.

Results Eight of 20 (40 %) in OCM-1 group and 19 of 20 (95 %) in SP 6.5 developed primary ocular tumors. One of 8 (12 %) in OCM-1 group and 8 of 19 (42 %) developed lung metastases. None of the animals developed liver metastases. All primary and metastatic tumoral cells expressed Vi. Eight of 9 animals (1 from OCM-1 group and 7 from SP 6.5) presented metastases and co-expressed Vi-Ck in primary or metastatic tumoral cells. Thirteen of 18 (6 from OCM-1 group and 7 from SP 6.5 group) did not present metastases and only expressed Vi. Test sensitivity was 88,9 % (50.9-99.3, as 95 % confidential intervals) and specificity was 72 % (46.5-89.2).

Conclusion Vi-Ck co-expression may be used as prognostic factor of uveal melanoma metastases. Further clinical research must be carried out to clarify the use of this test as prognostic factor in human uveal melanoma.

EVER-2004-abstractbook.indd 44 8/19/04 12:26:00 PM

209

Metastatic orbital leiomyosarcoma: a case report with CT scan, MRI and Ultrasound findings

VOROS GM (1), RESSINIOTIS T (1), OWEN RI (2), NEOH C (1), STRONG NP (1)
(1) Department of Ophthalmology, Royal Victoria Infirmary, Newcastle Upon Tyne
(2) Sunderland Eye Infirmary, Sunderland

Purpose To present a case of a metastatic orbital leiomyosarcoma and the corresponding computerized tomography (CT) scan, magnetic resonance imaging (MRI), and echographic findings.

Methods Correlation of CT scan, MRI and ultrasound characteristics with the clinicopathologic findings.

Results A 74-year-old male presented with a 3 month history of diplopia, left red eye, and left exophthalmos. He had a 10-year history of left knee leiomyosarcoma with multiple soft tissue and lungs metastases. His left globe was displaced anteriorly and inferolaterally, and fundoscopy showed choroidal folds. A CT scan revealed a large intraconal soft tissue mass in relation to the left medial rectus (MR) muscle, and incidentally a right maxillary antrum soft tissue mass. An enhanced MRI showed that the orbital mass was indistinguishable from the MR muscle, extending from the insertion of the muscle to the optic nerve. The optic nerve was slightly displaced, but the nerve sheath was not involved. A- and B-scan echographic examination showed a well defined, hyporeflective, encapsulated orbital mass involving the MR muscle with indentation of the globe, and high frequency ultrasound suggested that the anterior edge of the mass was 7mm posterior to the limbus.

Conclusion CT scan, enhanced MRI and Echographic studies provided complementary useful information regarding the features, location and characterisation of this rare metastatic orbital tumour. These correlated well with the clinicopathologic findings. They all have an important role in the diagnosis and the therapeutic management of this rare malignancy.

210

Distance thermography in diagnostics of orbital diseases

PANTELEEVA OG
Dep. Ophthalmooncology and Radiology Moscow Helmholtz Research Institute of Eye Disease, Moscow

Purpose To determine the informative value of distance thermography as an noninvasive method of diagnostics of orbital diseases.

Methods The statistical thermography has been performed in the cases of benign, malignant tumors of the orbit, pseudotumour of orbit, thyroid-associated eye disease (TAED). When there was a suspicion for malignant tumour the dynamical thermography was performed in addition, with carbohydrate load and thermography of regional lymphatic nodes.

Results The statistical thermography has been performed in 380 patients with different diseases of the orbit. Hyperthermy over the lesion higher than +1,0˚C was assessed as suspicion for the malignant process. In the case of uncertain research result, in patients with tumours of the orbit additionally the dynamic thermography with glucose load was carried out. In 93% cases the asymmetry of thermoimages of affected side and symmetrical side of other orbit were diagnosed, ranging from +0,6˚C to +3,4˚C (mean +1,2˚C), out of the those in 59 cases of uncertain research results (thermoasymmetry from +0,6˚C to +0,9˚C) the test with the glucose load turned out to be highly positive (higher than 1,5˚C).The examination of 37 patients with TAED (mainly with the affection of one orbit) has let us determine thermoasymmetry in the center of cornea (up to 1,7˚C), which in our opinion indicates the dysfunction of blood supply in the optic nerve system. In patients receiving medication the increase in temperature and appearance of thermosymmetry of cornea in both eyes have been found.

Conclusion The method of distance thermography is highly informative in the diagnostics of tumors and pseudotumors of the orbit, it allows to indirectly assess the blood supply in the optic nerve system and the results of the treatment.

211

Molecular diagnosis of human adenovirus C and D and phylogenetic relationships based on the sequencing of the hexon gene

FERRER RODRIGUEZ C (1), MASCIOPINTO F (1), ALIO JL (2, 3)
(1) Molecular Biology, VISSUM, Alicante
(2) VISSUM, Alicante
(3) Patologia y Cirugia, Universidad Miguel Hernandez, Alicante

Purpose To identify the genotype of adenovirus (ADV) causing conjunctivitis by PCR and sequencing of the hypervariable regions of the hexon gene and their phylogenetic analysis

Methods Hypervariable regions (HVR 4, 5 and 7) of 16 samples of patients with sharp conjunctivitis were amplified by nested-PCR. These samples were collected in our centre over a period of 3 years. The amplified region was sequenced and compared by the program Blastn with the sequences of adenovirus present in the GenBank database. We constructed a phylogenetic tree of our 16 sequences together with 20 sequences prototype of ADV deposited in this database

Results The most frequent ADV genotype in the samples was the ADV 8 followed by the ADV 19, both typical of epidemic keratoconjunctivitis. The resulting phylogenetic tree showed the strict homology between our patients infected by ADV 8 and a strain obtained in Japan, called Trim. The patients infected by ADV 19 showed high homology with two sequences of ADV 19a of Japanese origin. Other types of ADV revealed in the clinical samples (ADV serotype D 37, ADV serotype C 1) were distributed in the tree according to their sequence. A relationship between the genotype and the clinical manifestations was detected.

Conclusion The PCR and molecular typing of the hypervariable regions of the hexon gene seems to be an effective tool for detection and identification of adenovirus causing conjunctivitis and it could permit the analysis of the phylogenetic relations.

212

A ret-cam imaging study of macular retinoblastoma pre and post treatment

HADJISTILIANOU T, MARTONE G, DE FRANCESCO S, CAPOROSSI ALDO
Department of Ophthalmology, Retinoblastoma Referral Center, Siena

Purpose To evaluate tumor reduction in retinoblastoma treated with thermo chemotherapy (TCT) by using the RET CAM fundus camera software for image analysis.

Methods Fundus camera (RET CAM) records at diagnosis and following TCT were compared by using a dedicated software supplied with the camera.Post-treatment fundus photographs were taken when clinical and ophthalmoscopic remission were evident. Therefore, the time lapse between the pre- and post-treatment photographs was variable from patient to patient.

Results In all macular tumors we have been able to document a reduction of about 45% of the initial size. The mean follow up has been 13,1 months.

Conclusion TCT is commonly used in retinoblastoma to combine the physical action of heat on tumor vasculature and the chemical effects of anticancer drugs. The "heated" tumor is supposed to become more sensitive to chemotherapeutic agents. In the present investigation, by storing serial images of tumors at diagnosis and in complete remission, and using a dedicated image analysis software, we have been able to demonstrate a remarkable reduction of the tumor size in a two dimensional range in all cases treated by TCT, with particular reference to papillo-macular retinoblastoma.

EVER-2004-abstractbook.indd 45 8/19/04 12:26:00 PM

■ 213

Optical Coherence Tomographic (OCT) findings in case of subfoveal choroidal metastasis

PICCIRILLO V, PESCE G, SCORCIA V, BRUZZICHESSI D, CARNOVALE-SCALZO G, SCORCIA G
Eye Clinic - University "Magna Graecia", Catanzaro, Italy

Purpose OCT in a non invasive no contact technique for morphologic cross sectional study of structures at the posterior pole of the eye. Aim of the study is to describe OCT findings in case of subfoveal choroidal metastasis

Methods Three cases of subfoveal choroidal metastasis were diagnosed angiografically and ecographically. Patients (2 males and 1 female) were treated surgically for lung and breast cancer about 16 months before visual loss; radiologic follow up revealed no metastasis using nuclear medical techniques. After complete ophthalmic examination, patients underwent optical coherence tomography of the macular area.

Results OCT revealed an elevation of macular area with foveal profile modification (no foveal clivus) and thickening of the neurosensory retina referred to intraretinal oedema. The complex Retinal Pigment Epithelium – Choriocapillaris appeared thickened and hyperreflective disomogeneously. Only one case exhibited RPE detachment and two cases were complicated by neurosensory retinal detachment . Shadowind was common finding in all cases.

Conclusion OCT is complementary to angiographic and tomographic technique in choroidal metasthasis diagnosis. It's may be useful to understand clinical and pathophisiologic features of visual loss in cases of subfoveal choroidal metastasis.

■ 214

Microsurgical Biopsy of Intraocular Tumors with High Diagnostic Accuracy

ALL-ERICSSON C, KVANTA A, BERGLIN L, SEREGARD S
St Eriks Eye Hospital, Stockholm

Purpose Most intraocular tumors are correctly diagnosed by non-invasive investigations. However, tissue sampling may be required for diagnosis. We assessed the safety and accuracy of a microsurgical technique designed to optimize the diagnostic sensitivity and specificity.

Methods A standard three-port vitrectomy followed by retinotomy and incisional biopsy under microsurgical control was used to provide tumor samples for histopathological examination in 7 eyes of 7 patients harbouring choroidal tumors.

Results A correct diagnosis could be made by histopathological and immunohistochemical studies in all 7 patients. Diagnosis included choroidal melanoma (3 cases), metastasis (2 cases), subretinal fibrosis associated with choroidal neovascularization (1 case) and nodular scleritis (1 case). One patient had postoperatively vitreous hemorrhage and retinal detachment that could be managed by routine detachment surgery.

Conclusion Subretinal incisional biopsy under microsurgical control is a safe procedure with high diagnostic accuracy.

■ 215

Commissioning applicators for epiescleral brachytherapy

MORILLA A (1), DE FRUTOS-BARAJA JM (2, 1), SAORNIL-ALVAREZ MA (2, 1), PÉREZ-CALATAYUD J (3), LÓPEZ-LARA-MARTÍN F (2)
(1) Instituto Universitario de Oftalmobiología Aplicada (IOBA), Universidad de Valladolid, Valladolid
(2) Hospital Clínico Universitario, Valladolid
(3) Hospital Universitario La Fe, Valencia

Purpose Epiescleral brachytherapy is an indication in the treatment of choroidal melanoma and other ocular tumors. As in the rest of brachytherapy procedures it is necessary to commissioning the appliccators that are going to be used. In the present work those test called acceptance and reference tests are showed and their results are described.

Methods Seven aplicadores COMS type are examined, of sizes between 10 mm and 22 mm. Tests are the indicated ones by the Spanish protocol of brachytherapy: Description, configuration and complete scheme, dosimetric evaluation, positioning of the source, integrity and positioning of shields, coincidence of the active and dummy source.

Results As a result of the verifications the dimensions and the complete scheme, as well as the coordinates of the sources in the apliccators have recalled of the manufacturer. We are compared the measured dimensions of the aplicador with the employees in the treatment planning system with good agreement. The sources position has been verified that maintains an accuraccy of +/- 1 mm Also has been confirmed that the dose distribution is in agreement with published data.

Conclusion We are verified that the set of applicators analyzed is adapted for epiescleral brachyterapy. Commissioning test is useful to establish the program of periodic verifications of the studied applicators.This work was, in part, supported by grant Nº 01-1604 of FIS, Ministerio de Sanidad y Consumo, Spain, and a grant of José Mª Aguilar Bartolomé Foundation Spain

■ 216 / 2126

Glaucoma and optic nerve drusen

KAWA P, NOWOMIEJSKA K, BIALEK M, HASZCZ D, CZOP DC, MANKOWSKA A, KRUKOWSKI J, ZAGÓRSKI Z
1 st. Eye Hospital & Lublin University School of Medicine, Lublin

Purpose To present 28 patients with optic nerve drusen. Ten of them had glaucoma. We tried to evaluate if there was any correlation between clinical picture of OND and the visual field defects and whether glaucoma made any of the clinical parameters worse in these patients.

Methods Basic clinical examination, Goldmann applanation tonometry, 30-2 threshold visual field – Humphrey perimeter, HRT, Ischihara color testing, pupil reaction , central corneal thickness (CCT) measurement, endothelial cell count in specular microscopy, VER and lab tests were performed in 28 patients with OND.

Results There was an abnormal retinal nerve fiber layer thickness, mean and maximum cup depth in 25 patients (90 %) in HRT. In 25 patients (90 %) patients visual field defects were present. There was no correlation between clinical picture of OND and the visual field defects.

Conclusion The optic nerve drusen cause significant RNFL thickness thinning and visual field defects, which might be due to coexisting glaucoma.

EVER-2004-abstractbook.indd 46 8/19/04 12:26:01 PM

217 / 2127

Doppler Velocities in Retrobulbar Arteries in Normal Pregnancy and Postpartum. A Longitudinal Study

VIGANDER K (1), TAKSERMAN A (2), HAUGEN G (3), KERTY E (4)
(1) Ophthalmology, National Univ. Hospital, Oslo
(2) Cardiology, Aker Univ. Hospital, Oslo
(3) Obstetrics and Gynaecology, National Univ. Hospital, Oslo
(4) Neurology, National Univ. Hospital, Oslo

Purpose To estimate the changes in retrobulbar blood flow throughout pregnancy and postpartum by means of Colour Doppler Velocimetry (CDV) and to evaluate the influence of general hemodynamic changes on ocular blood flow.

Methods Blood flow was measured by means of CDV at five intervals from week 12 to week 36 in normal pregnancy and day two and month six postpartum in the ophthalmic artery (OA), central retinal artery (CRA) and posterior ciliary artery (PCA). Peak systolic (PSV) and end diastolic (EDV) flow velocities were measured and the resistivity index (RI) was calculated. Mean blood pressure (MAP), heart rate (HR) and intraocular pressure (IOP) were measured. ANOVA test, Bonferroni post hoc test and Pearson correlation analyses were performed.

Results Twenty-nine healthy women (mean age: 30.3+3.5 years) were recruited. CRA EDV was lower in the first half of pregnancy ($p<0.001$) and showed a strong increasing trend in the second half of pregnancy ($p<0.001$). PCA PSV decreased in the second half of pregnancy ($p=0.032$). For CRA and PCA the RI was higher in the first half of pregnancy compared to month 6 postpartum ($p<0.001$ in both cases) and showed a strong decreasing trend in the second half of pregnancy ($p<0.001$ in both cases). No significant correlations between the Doppler velocities and IOP, MAP or HR were observed.

Conclusion We found hemodynamic changes in the retrobulbar arteries during pregnancy compared to month 6 post partum. The most marked findings were in the CRA. The decreased vascular resistance could be interpreted as orbital vascular vasodilation. Estrogen may play a role due to the multifold increase throughout pregnancy and the known vasodilatative effects of this hormone.

218 / 2128

Influence of papilloedema on globe shape

MADILL SA, CONNOR S
King's College Hospital, London

Purpose We investigated how globes are deformed by papilloedematous optic discs by studying globe shape in patients with Idiopathic Intracranial Hypertension (IIH).

Methods 5 IIH patients and 10 age-matched normals were studied. 0.6mm section CT scans were reformatted on a workstation to create sagittal and axial sections through the globes of each patient along the respective visual axes. The reformats were magnified and the globe length and width measured for axial reconstructions and globe length and height measured for sagittal reconstructions. A single masked observer took all the measurements.

Results The mean difference between globe length and height in sagittal sections in the IIH patients was 1.9mm (SD=1.0mm) for right eyes and 2mm (SD=0.7mm) for left eyes compared to 0.2mm (SD=1.2mm) for right eyes and 0.1mm (SD=1.2mm) for left eyes in controls. For all 5 IIH patients globe height was greater than length in both eyes. Using a 2-tailed T-test for independent samples this gives a significance of $p=0.005$ for right eyes and $p=0.003$ for left eyes when comparing the length to height differences of eyes of IIH patients to controls. Considering the difference between globe length and width on axial sections, there was no significant difference between IIH patients and controls.

Conclusion There is a highly significant distortion of globes in patients with IIH compared to controls but manifesting only in sagittal sections.

219 / 2225

Pupillometry reveals increased inter-eye pupil escape ratio in the eye with a subretinal membrane

ZAIDI FH (1, 2), MOSELEY MJ (1)
(1) Visual Neuroscience, Imperial College London, London
(2) Ophthalmology, St Marys and The Western Eye Hospital, London

Purpose To ascertain if macula dysfunction in subretinal neovascular membranes (SRNs) is associated with the phenomenon of pupil escape by comparing healthy eyes with those with SRNs.

Methods Non-randomised trial of dynamic binocular infrared pupillometry of 24 eyes with unilateral SRNs and healthy fellow eyes. Full-field achromatic stimuli (22 x 14 deg) were presented to each eye alternately at 7 intensities within a range of 1-2 log cd.m-2 for 5 s. Recordings were undertaken after 20 minutes of dark adaptation. Aetiology of SRN was age-related macular degeneration (n=9), inflammatory (n=2) and infective (n=1).

Results Inter-eye comparison of pupillary responses showed that eyes with subretinal membranes have a statistically greater reduction in sustained contraction as a proportion of the phasic component ($p<0.05$).

Conclusion Inter-eye comparison of pupil escape ratio differentiates normal eyes from those with significant retinal pathology in the form of subretinal membranes. This observation is consistent with reports of pupil escape in patients with central field loss (Bergamin O, Kardon RH. Ophthalmology 2002;109:771-80). Changes in the pupil waveform suggest potential for clinical application of dynamic pupillometry to diagnosis of significant macula pathology and investigation of retinal function in cases of ocular media opacities. Unlike most other investigations the pupil light reflex continues to function in this situation, and is often enhanced.

220 / 2226

Eye velocities during static fixation in patients with central scotoma

MACEDO AF (1), GOMES AOS (2), NASCIMENTO SMC (1)
(1) Department of Physics, University of Minho, Braga
(2) Department of Electrical Engineering and Computers, Faculty of Engineering, University of Porto, Porto

Purpose The aim of this work was to study eye velocities during static fixation in patients with central visual field defects.

Methods Eye-position data were recorded from 10 patients and 10 controls with a modified infra-red xy-gaze-tracking device using the pupil and corneal reflection (iView, SensoMotoric Instruments GmbH; sampling rate 60 Hz; angular resolution 0.2 deg). The patients had visual acuity in the range 0.7-1.0 Log MAR. The task consisted in fixating a static white cross of 2.5° against a black background during 60 sec. Data were analyzed offline and such that outliers, blinks and saccadic movements were removed. Mean eye velocities were then computed for the period of fixation.

Results It was found that the mean eye velocity was significantly higher for patients.

Conclusion During static fixation patients with central field defects have faster eye movements than controls, suggesting that central visual field defects may impair slow control of eye movements.

EVER-2004-abstractbook.indd 47 8/19/04 12:26:02 PM

■ 221

Dural carotid-cavernous fistulas : evolution of the therapeutic strategy from 1992 to 2004. About 9 cases.

VINH VV (1), LEFOURNIER VL (2), BERNAL FB (1), VASDEV ASHOK (2), BESSOU PB (2), MOUILLON MM (1), ROMANET JPR (1)
(1) Ophthalmology, Grenoble
(2) Neuroradiology, Grenoble

Purpose To compare the therapeutic choices applied to treat dural carotid-cavernous fistulas between the early and middle 90s, and the therapeutic strategy used at present.

Methods A retrospective study of 9 patients who underwent examination and treatment for dural carotid-cavernous fistulas between 1992 and 2003 was performed. Two patients had type B dural fistulas and 7 had type D. Until 1997, non-invasive treatment such as decoagulation and/or carotid-jugular compressions was first carried out, followed by an embolization. On the contrary, in 2003-2004, prior embolization was favoured, associated, if not efficient enough, with non-invasive treatment.

Results Between 1992 and 1997, 3 patients had only decoagulation and/or compressions : the symptoms improved in 2 cases and were stationary in 1. The 4th patient underwent an embolization after non-invasive treatment, with a complete cure. Concerning the 2nd group of patients (2003-2004), 1 patient, for whom embolization was not possible and compressions contraindicated, had a decoagulation alone and remained clinically stationary, and 2 could receive nothing but a non-invasive treatment with slight improvement for 1 and a complete cure for the 2nd. At last, 2 patients underwent prior embolization associated with decoagulation and/or compressions, allowing an important clinical improvement for 1 and a complete cure for the other.

Conclusion Prior embolization when possible seems to be efficient and safe. Nonetheless, non-invasive treatment remain an important therapeutic alternative. Anyway, whatever the therapeutic strategy we choose, it has to be done in close collaboration with the neuroradiologists.

■ 222

Retained orbital wooden foreign body in children

EL SHEHA H (1, 2), EL TOKHY E (1), TSE DT (3)
(1) Ophthalmology, Research institute of Ophthalmology, Cairo
(2) Ophthalmology, Saudi German Hospital, Jeddah
(3) Ophthalmology, Bascom Palmer Eye Institute, Miami

Purpose To emphasize the management of retained orbital wooden foreign body (WFB) in children.Review of literature and case report.

Methods A four years old child sustained an orbital WFB despite repeated attempts to remove it. Computed tomography and magnetic resonance imaging at different intervals revealed evidence of residual orbital foreign body. Anterior orbital approach was used to remove the foreign body .

Results All preoperative symptoms and signs were resolved after the complete removal of the foreign body. No postoperative complications were detected during the follow up period.

Conclusion A retained orbital foreign body should be suspected in any child under the age of five with a history of trauma, skin break, ptosis, and motility disturbance. In this case, imaging study such as CT or MRI must be performed to confirm the diagnosis and to exclude intracranial migration.

■ 223

Compressive optic neuropathy in patients with Thyroid Associated Ophthalmopathy (TAO)

CARNOVALE SCALZO G (1), PAOLA A (2), LABONIA AF (3), BRUZZICHESSI D (2), COSTANTE G (3), SCORCIA V (2), SCORCIA G (2)
(1) Eye Clinic, University "Magna Graecia" ., Catanzaro, Italy
(2) Eye Clinic, University "Magna Graecia", Catanzaro, Italy
(3) Endocrinology Unit,University "Magna Graecia", Catanzaro, Italy

Purpose Thyroid associated ophthalmopathy(TAO) is an autoimmune disorder usually associated to Graves' disease.TAO may be complicated by compressive optic neuropathy[NOC] leading to possible sight loss.The management of Graves'ophthalmopathy patients is still based on the Clinical Activity Index(CAI).Aim of the study to evaluate anatomic and/or functional optic nerve involvement and the correlation with the CAI.

Methods We examined 75 TAO patients.The patients underwent standard thyroid evaluation,clinical ophthalmic examination and evaluation of functional and anatomic optic nerve damage by automated perimetry and nerve fiber analyzer (GDx).

Results The results were related to proptosis and CAI.In 48 patients with exophthalmometry<22 mm,33%exhibited visual field defects,12% nerve fiber loss,55% both alterations.In 27 patients with exophthalmometry >22 mm,30% exhibited visual field defects,5% nerve fiber loss,65%both alterations. In terms of clinical activity,15 patients presented CAI 1-2. In such patients, 40%visual field defects , 60% nerve fiber loss, 0 % both alterations occurred.CAI 3-5 was observed in 45 patients, presenting 35 %visual field defects ,15% nerve fiber loss,50% both visual field defects and nerve fiber los.15 patients with CAI 6-7 were observed, showing 22%visual field defects ,8% nerve fiber loss ,70% both alterations.

Conclusion The data obtained confirm the progression to compressive optical neuropathy in patients with TAO, independently from the proptosis. The observed optic nerve involvement can be attributed to functional rather than anatomical alterations. The combined anatomical and functional damage occurs in the moderate-severe TAO only.

■ 224

Thyroid-Associated Eye Disease (TAED) from Ophthalmologist's point of view

PANTELEEVA OG
Dep. Ophthalmooncology and Radiology Moscow Helholtz Research of Eye Disease, Moscow

Purpose The significant increase in the no. of patients with thyroid dysfunction (i.e. Diffuse Toxic Goiter, hypothyroidism or Hashimoto's disease) has been observed in the last ten years. These disorders are accompanied by extra thyroid symptoms, among which is the TAED in 70% of cases. However, despite the clear clinical features at the developed stage of disease, the one-sided endocrinologist's treatment tactics leads to the late patient referral to ophthalmologist, which results in EOP development and structural changes in organ of sight with the loss of visual functions.

Methods In the year 2003 we have performed a full clinical, physiological examination of 45 patients with TAED. The mean patient age was 43.4 years. Females:males =2.7:1.

Results From first clinical manifestations of the illness till referral was 27 months. TAED has developed in 86.7% of patients of diffuse toxic goiter, in 8.9%-euthyroidism and in 4.4%-hypothyroidism. Without adequate hormone replacement therapy after subtotal thyroidectomy the patients reported the slow worsening of their eyes state and visual acuity. In 64% patients visual functions had diminished by the time of referral to ophthalmologist. In all the patients the defects of visual fields were found. The electrophysiological and psychophysical examinations showed the deviations from normal values, which confirmed the presence of optical neuropathy of different development stages.

Conclusion In this report we would like to attract attention to the necessity of observation and treatment of patients with disthyroid conditions not only by endocrinologist but by ophthalmologist as well, from the moment of first clinical illness manifestations.

EVER-2004-abstractbook.indd 48 8/19/04 12:26:02 PM

■ 225

Teletransmitted stereoscopic video images in oculoplastic surgery

BERGUA A, MARDIN C, HOLBACH L
Ophthalmology University Erlangen-Nuremberg, Erlangen

Purpose To establish an easy and inexpensive system to record stereoscopic images in video, its stereo visualization and publishing on an internet platform for collaborative research or remote surgery supervision.

Methods For stereoscopic video recording a NuView (i-O Display Systems, USA) adapter was attached to a mini-DV camcorder Panasonic NV-DS30 (Panasonic corp, Japan). Eight patients having oculoplastic surgery (i.e basaliom excision) were recorded by means of this system. Visualisation of stereoscopic video images was performed using a CRT monitor or TV set that display left/right images time-sequentially. The TV set was connected with a TV adapter P/N103822 which controls wired LCD-shutter glasses P/N 103624 (H3D, Inc).

Results Flicker free stereoscopic video visualization was achieved with this system permitting excellent spatial orientation related to surgical instruments, recognition surgeon's hand movements etc.

Conclusion The use of stereoscopic video technology bears a great potential to enhance the comprehension in oculoplastic surgery and may improve in the future telemedical assistance in this type of surgery. The use of stereoscopic video in eye surgery will be developed for research and educational purposes, specially using internet as a communication medium.

■ 226

Accommodative convergence measurement in strabismus using a oculomotor register system by infrared

VIDAL LÓPEZ J
Oftalmología, Otorrinolaringología y Anatomía Patológica - Universidad de Murcia, Spain

Purpose To develop a new measuring technique of accommodative convergence (AC) in patients with strabismus that calculates deviation of each eye related to accommodation.

Methods One student of psychology, female, 24 years old with right esotropia (22ΔBI) and normal visual acuity (VA right eye =VA left eye= 1.2). An infrared oculomotor register system (Eye Track) was used. Horizontal and vertical gaze position (X/Y) on the display screen, fully compensated for head position, was obtained. Individual holded up fixation on a dot of screen for a minute. Five sessions were carried out for each experimental condition. In each session 15000 measurements of each eye horizontal and vertical gaze position were obtained (Xre, Yre, Xle, Yle; re: right eye, le: left eye). Independent variables were: a) Binocular/monocular conditions, b) Eye (re/le) and c) Accommodation (A): -3.00D / -2.00D/ -1.00D/ 0.00D/ +1.00D/ +2.00D/ +3.00D (varied with soft contact lenses, radius=8.90mm, diameter=14.0mm). Dependent variables were Xre, Yre, Xle and Yle.

Results Regression lines X´re, Y´re, X´le, Y´le were calculated in terms of accommodation. Null and alternative hypothesis (Ho:b=0 and H1:b≠0, b: line regression slope) were tested using Student´s t Test. Only right eye changed its horizontal position, in binocular position, when accommodation was varied (X´re=5.90*A+350.25, t=4.66, p=0.006). No significant variations were found for other conditions.

Conclusion This technique allows compute, with very high accuracy, contribution of each eye to AC in patients with strabismus.

■ 227

The AC/A ratio in University Students in Portugal

QUEIROS A (1), JORGE J (1), FERNANDES P (1), ALMEIDA JB (2), PARAFITA MA (3)
(1) Physics (Optometry), Braga
(2) Physics, Braga
(3) Surgery (Ophthalmology), Santiago de Compostela

Purpose To examine how the response AC/A ratio varies as a function of refractive error, age and sex.

Methods The refractive error was measured by the standard subjective refraction and all refractive errors were corrected.The AC/A ratio were measured by the gradient method in to the phoropter.The refractive error of the sample, ranged from –8.75 to +3.75 D mean spherical equivalent + 0,20 ± 1,53D (Mean ± SD.). The maximum amount of astigmatism was –2,25 D.

Results The mean value for the population was 4.3 ± 2.13 D/D (mean ±SD). Statistically there are no significant differences between male and female (male AC/A ratio = 4.3 ± 2.10 D/D; female AC/A ratio = 4.3 ± 2.16 D/D) or any significant differences between the age groups (less than 20 years old AC/A ratio = 4.5 ± 2.29 D/D; between 20 and 25 years old AC/A ratio = 4.2 ± 2.00 D/D, more than 25 years old AC/A ratio = 4.2 ± 2.38 D/D) or any significant differences between myopes, hyperopes and emmetropes, (myopes AC/A ratio = 4.6 D/D ±2.15 D; hyperopes AC/A ratio = 4.4 ± 2.52 D and emmetropes AC/A ratio = 4.0 ± 1.77 D).

Conclusion The results show an AC/A ratio similar to results obtained in other populations. An elevated response AC/A ratio were present in the myopic group but the difference was not statically significant.

■ 228

The Frisby-Davis 2 (FD2) distance stereotest in evaluation of exotropia

HOLMES J. M., LESKE D. A.
Department of Ophthalmology, Mayo Clinic College of Medicine, Rochester, MN

Purpose We have recently developed a presentation protocol for the new Frisby-Davis 2 distance stereotest (ARVO 04), which allows measurement of distance stereoacuity free from monocular cues. Tests of distance stereoacuity may be useful in evaluating strabismus when the angle of deviation, or control of that deviation, differs at distance and near fixation. We therefore conducted a pilot study to evaluate the FD2 in patients with exotropia.

Methods Twelve patients with exotropia were tested with the FD2 distance stereotest, using our new presentation protocol which incorporates a monocular phase to determine whether initial binocular thresholds represent true stereospsis. Stereoacuity at near was also tested with the Preschool Randot and Frisby tests. Angles of distance exotropia ranged from 18 to 80 PD. The control of the distance deviation ranged from constant tropia to very intermittent (control score of 5 to 1, on a scale of 0 to 5, where 0 is always phoric and 5 is always tropic).

Results None of the 7 patients with constant exotropia had measurable distance stereoacuity using the FD2. In contrast, all 5 patients with intermittent exotropia had measurable distance stereoacuity, ranging from 20 secarc (the finest disparity on the FD2 test at 3 m) to 160 secarc (p=0.001, Fisher's exact test). Near stereoacuity was 40-60 secarc in all intermittent cases, whereas patients with constant exotropia had no near stereopsis.

Conclusion Patients with intermittent exotropia have a wide range of distance stereothresholds using the FD2, in contrast to more uniform near stereoacuity. Constant exotropia was associated with no measurable stereopsis. The new FD2 distance stereotest may be useful for monitoring deterioration of intermittent exotropia.

EVER-2004-abstractbook.indd 49 8/19/04 12:26:03 PM

■ 229

Homonymous hemianopia due to paradoxical embolus in a young adult with interatrial septal defects and cystic fibrosis

KALHORO A (1), MATAFTSI A (1), MEARZA A (1), BRECKER S (2)
(1) Royal Eye Unit, Kingston-Upon-Thames
(2) St George's Hospital, London

Purpose We describe an episode of acute field loss due to paradoxical embolism in a young adult with cystic fibrosis and interatrial septal abnormalities. The mechanisms underlying atrial septal abnormalities and associated paradoxical embolus are reviewed. Patient management in the setting of cystic fibrosis is also discussed.

Methods Single observational case report.

Results We report the case of a 31 year old female with mild cystic fibrosis. This patient presented with a 12-hour history of left-sided field loss. An incongruous left homonymous hemianopia was found on perimetry.The patient underwent specialist neurological investigation for cryptogenic stroke. Magnetic resonance imaging revealed right occipital infarction. Transoesophageal echocardiography showed an atrial septal defect involving the fossa ovalis and an aneurysmal septal membrane. Aspirin was commenced. At 9 months, the defect was closed using a transcatheter occluder. The patient was registered partially-sighted and has remained free from recurrent thromboembolism.

Conclusion The significance of combined interatrial septal abnormalities and paradoxical embolism is not fully understood. The incidence of interatrial septal defects in cystic fibrosis is unknown.Patients with atrial septal abnormalities associated with paradoxical embolus require treatment to reduce the risk of recurrence. Surgical repair of the defect is advocated in young patients with recurrent thromboembolic events. In the setting of cystic fibrosis, we suggest that transcatheter surgical closure should be considered prior to a recurrent event, particularly if atrial septal aneurysm is detected in association with an interatrial septal defect.

■ 230

The incidence of visual field defects following selective amygdalohippocampectomy

KIRCHER K (1), NOVAK K (2), PATARAIA E (3), MARSCHALEK J (2), BALIMGARTNER C (3), CZECH T (2), REITNER A (1)
(1) Medical University of Vienna - Department of Ophthalmology, Vienna
(2) Medical University of Vienna - Department of Neurosurgery, Vienna
(3) Medical University of Vienna - Department of Neurology, Vienna

Purpose To study the changes of visual fields induced by selective transsylvian amygdalohippocampectomy.

Methods 54 patients undergoing surgery for temporal lobe epilepsy were studied prospectivelyusing automated static perimetry (Humphrey autoperimeter, program 30/2). Mean deviation of threshold values of preoperative and postoperative visual field testing was entered into the analysis of postoperative visual field changes. Extent of relative and absolute skotomas was measured in degrees from the center.

Results Visual field defects were detected in 83.3% of the patients postoperatively.In 5.6% the field defect was classified as incomplete hemianopia,always sparing the center of the visual field, in 76% as incomplete quadrantanopia,in one patient (1.8%) as complete quadrantanopia.In patients with incomplete quadrantanopia or hemianopia even relative scotomas spared20 degrees from the center in 28%, 10 degrees in 40%, 5 degrees in 13%. Thus, the mean difference of preoperative and postoperative mean deviation was only -2.3 dB.

Conclusion Meticulous analysis of visual fields using computer perimetryreveals that incomplete quadrantanopia is more frequentlyinduced by selective amygdalohippocampectomy than previously reported. However, clinical significant changes are rare and can be outweighedby benefits of successful treatment of refractory epilepsy.

■ 231

Anterior ischemic neuropathy secondary to interferon alpha treatment: a case report

BASSIME L (1), BARLET T (1), KOCH P (1), MULS V (2), WILLERMAIN F (1)
(1) Ophthalmology, Brussels
(2) Gastro-enterology, Brussels

Purpose To describe a case of anterior ischemic optic neuropathy which occur in a hepatitis C patient treated with peg-interferon alpha and ribavirin

Methods CASE REPORT

Results Case report : A 53 years old man complained of sudden visual loss of the right eye. He was treated peg-interferon alpha and vibavirin since 5 months for chronic hepatitis C. The patient was a mild smoker and had a slight hypercholesterolemia. Visual acuity was on the 1/10 right. There was an afferent pupillary defect and a altitudinal inferior visual field defect on the affected eye. Anterior chamber was normal. Fundus examination showed optic nerve oedema, more pronounced superiorly, and a few papillary haemorrhages. Orbit and brain scanner was normal except for a small asymptomatic thrombotic sequelae on the external capsule. An extensive worked-up was normal. Interferon and ribavirin were stopped and methylprednisolon 1 g/IV was given for 3 days. Two weeks after, VA was 4/10 and visual field was slightly better

Conclusion Our case report illustrated that interferon alpha and ribavirin treatment might be associated with severe ocular complications. Early discontinuation of the drugs and high dose steroids might be considered in the management of such cases.

■ 232 / 1126

Local retinal venous reaction to moderate artificial IOP increase in normals and glaucoma patients

KOTLIAR K (1), NAGEL E (2), VILSER W (3), LANZL I (1)
(1) Eye Clinic, Technical University, Munich
(2) Eye Consultant, Rudolstadt
(3) Biomedical Engineering, Technical University, Ilmenau

Purpose The Retinal Vessel Analyzer (RVA) measures temporal and spatial retinal vessel reactions in response to stimuli in real time. Local reactions to moderate artificial intraocular pressure (IOP) increase in retinal veins are investigated in healthy subjects and glaucoma (POAG) patients.

Methods 14 untreated POAG patients (61,2+/-7,6 years, IOP 22,4 +/-6,0 mmHg) and 13 healthy volunteers (62,6+/-6,7 years, IOP 13,8+/-2,9 mmHg) were examined. After baseline assessment for 2 min IOP was moderately increased for 100 s by suction cup. Diameter changes of retinal veins were measured along a 1 mm segment. Local vessel behaviour was analyzed.

Results At baseline no significant difference was found in spectral edge frequency of the power spectrum (SEF) between normals (0,112+/-0,042) and POAG patients (0,108+/-0,035) (p>0,3). During IOP provocation venous diameter decrease was observed in all cases. No significant difference in SEF between normals (0,128+/-0,039) and glaucoma patients (0,135+/-0,045; p>0,2) was found. No significant difference in SEF values was found between the groups during reactive dilation after provocation (p>0,3): normals: 0,114+/-0,026; glaucoma: 0,106+/-0,039.

Conclusion SEF is an expression for the frequency in amplitude change of vessel width along a vessel segment which we termed "vessel thickness change frequency" (VTCF). We found no significant difference in VTCF between normals and glaucoma patients here. In an earlier study using short term suprasystolic IOP provocation we found significantly higher VTCF in glaucomatous arteries during reactive dilation phase but not in veins. Local retinal venous behaviour in normals as well as in glaucoma patients seems not to be affected by IOP-peaks.

EVER-2004-abstractbook.indd 50 8/19/04 12:26:03 PM

233 / 1127

The assessment of conjunctival hyperemia with latanoprost 0.005% versus travoprost 0.004% therapy

SIEGEL LI (1), SAROLI TL (1), JENKINS JN (2), STEWART WC (2, 3), PRZYDRYGA JT (4)
(1) Glaucoma Center of Michigan, Southfield, MI
(2) Pharmaceutical Research Network, Charleston, SC
(3) Carolina Eye Institute at USC School of Medicine, Columbia, SC
(4) Alcon Laboratories, Fort Worth, TX

Purpose To evaluate if physicians could determine, by the amount of ocular hyperemia, if a patient was instilling latanoprost 0.005% or travoprost 0.004% after previous treatment with latanoprost. The hypothesis: pretreatment with latanoprost will minimize any potential ocular hyperemia increase observed with travoprost.

Methods Twenty patients who were undergoing latanoprost therapy were randomized at the first visit to either latanoprost or travoprost treatment in a double-masked fashion for eight weeks. At the second visit the attending physician guessed which medicine the patient was administering. As an additional control, a different off-site physician randomly guessed the patient treatment.

Results The 10 latanoprost patients had a mean baseline hyperemia scale (graded 0-3) of 0.2 in both eyes that increased to 0.4 in both eyes on the second visit ($P > 0.05$). The eight travoprost patients had a baseline hyperemia scale of 0 in both eyes that increased to 0.6 in the left eye and 0.7 in the right eye on the second visit ($P > 0.05$). The on-site physician correctly deduced the therapeutic agent in five patients (50%) for latanoprost and in five patients (63%) for travoprost. The off-site physicians correctly guessed the glaucoma medication 50% of the time for both treatment groups.

Conclusion This pilot study suggests that following prior treatment with latanoprost a physician may not be able to clinically distinguish (on the basis of hyperemia) if a patient is currently on latanoprost or travoprost therapy.

234 / 1128

Volume of hypotensive eyedrops: Potential influence factors

ANTON LOPEZ AAL, MARTIN MARTIN BMM, BLAZQUEZ ARAUZO FBA
Ioba, Valladolid

Purpose To asses the drop volume, its variability and the factors that could influence on the drop volume of the different commercial glaucoma eyedrops available in Spain.

Methods 10 of 14 commercial hypotensive eyedrops were examined. Drop volume was calculated using an avg. density. Every drop was expelled in the same conditions: room Temp., handling angle, and expelling technique. Variability of the drop volume was calculated in different situations: intrabottle (same drug: same and different shipment), intrabottle at different usage moment (out of the box, middle, almost empty), interbottle (same and different drug). Variance and variation coefficient were calculated to evaluate variability. To assess any nozzle design influence scaled photographs were taken. The influence of the drug solution's properties was evaluated replacing it with water.

Results Drop volume varied between drug brands (22.26µl-37.35µl). Variability between brands was approximately 15 times greater than the one attributable to differences within the same brand. Different shipments and usage moments didn't offer significant variability. In all cases water drop volume was larger than drug drop volume (20% - 90%) and varied between bottles of different brand (34.28µl - 55.01µl). 50% of the brands offered more variability, 30% offered less variability and 20% didn´t offer any difference respect to drug variability. Differences in drop size were found to be related to the outer nozzle diameter for all but 2 cases (r=0,90).

Conclusion Differences up to 100% between drop volumes associated to drug type were found. Drop volume showed a significant variation according to a variety of factors such as the nozzle design (outer diameter) and the drug solution properties.

235 / 1129

Dynamic autoregulation in the eye and brain

KOLODJASCHNA J (1), BERISHA F (1), POLSKA E (1), SCHMETTERER L (1, 2)
(1) Clinical Pharmacology, Vienna
(2) Medical Physics, Vienna

Purpose Dynamic autoregulation assesses the full time course of the autoregulatory process by analyzing beat-to-beat changes in perfusion pressure and blood flow parameters. We have adapted the tigh cuff technique to induce an ocular perfusion pressure step disturbance.

Methods 12 healthy male subjects were studied. Ultrasound parameters and arterial blood pressure (ABP) were recorded before, during, and after a step drop in blood pressure. Large bilateral thigh cuffs were inflated and the thigh cuff pressure was 20 mm Hg above systolic blood pressure (SBP). The occlusion was maintained for 3 minutes and a drop in ABP was induced by rapid deflation of the cuffs. Peak systolic flow velocity (PSV) and end diastolic flow velocity (EDV) were assessed with a color Doppler probe for the posterior ciliary arteries, the central retinal artery, the ophthalmic artery and the middle cerebral artery. SBPs and diastolic blood pressures (DBP) were measured continuously using a Finapres system. Autoregulation index, as a measure of vascular resistance, was calculated for systole and diastole as AIS= SBP/PSV and AID=DBP/EDV, respectively.

Results The time course of mean ABP and blood flow velocity in response to the thigh cuff release was statistically significant for systole and for diastole versus baseline in all arteries. In addition, we found a statistically difference in the response of the time course of flow velocities and autoregulatory indices between the 4 arteries ($p < 0.001$).

Conclusion Our results indicate differences in the autoregulatory response of the 4 arteries after a step decrease in perfusion pressure. This may be due to differences in the myogenic responses but also due to differences in sympathetic innervation.

236 / 2326

Retinal endothelial cell dysfunction caused by hyperglycemia and oxidative stress

CASTILHO A, SERRA A, LEAL EC, AVELEIRA C, AMBRÓSIO AF
Center of Ophthalmology of Coimbra, IBILI, Coimbra

Purpose Hyperglycemia plays a major role in diabetic retinopathy, and oxidative stress injury appears to be involved in this pathology. In this work, we investigated whether retinal endothelial cells exposed to hyperglycemia are more susceptible to oxidative stress.

Methods Rat retinal endothelial cell line - TR-iBRB2 - was exposed to high concentration of D-glucose (30 mM) or mannitol (24.5 mM), an osmotic control, for 7 days, and to NOC-18 (NO donor) or H2O2 for 24 hours. In addition, high glucose treated cells (7 days) were also exposed to NOC-18 or H2O2 during the last 24 hours. Cell viability, cell proliferation and the identification of apoptotic cells was assessed by MTT assay, [methyl-3H]-thymidine uptake and Hoechst assay, respectively.

Results Long-term exposure of retinal endothelial cells to high glucose concentration decreased cell viability and increased the number of apoptotic cells. Cell viability was not affected by mannitol. Furthermore, high glucose and mannitol decreased endothelial cell proliferation. Short-term exposure (24 h) of endothelial cells to NOC-18 or H2O2 also decreased cell viability and increased the number of apoptotic cells. The effect of both high glucose (7 days) and NOC-18 or H2O2 (24 h) either on cell viability or programmed cell death was significantly higher than the effect of high glucose, NOC-18 or H2O2 alone.

Conclusion These results demonstrate that hyperglycemia decrease the proliferation and increase the degeneration of retinal endothelial cells. In addition, endothelial cells exposed to hyperglycemia may become more susceptible to stress conditions.

EVER-2004-abstractbook.indd 51 8/19/04 12:26:04 PM

■ 237 / 2327

Metipranolol is the only ophthalmic beta-blocker to counteract oxidative stress-induced death to cultured human RPE cells

WOOD JPM, OSBORNE NN
Nuffield Laboratory of Ophthalmology, Oxford

Purpose To investigate the influence of known ophthalmic beta-blockers on cultured human RPE cells subjected to different oxidative stresses.

Methods Cultured human RPE cells (passage 3-5), in medium lacking serum, were insulted with a range of concentrations of either zinc sulphate (ZnSO4), t-butylhydroperoxide (t-BH) or buthionine sulphoxamine (BSO) for 24 hours. Cells were analysed for the appearance of DNA breakdown by the terminal deoxynucleotidyl transferase UTP-linked nick-end labelling (TUNEL) reaction, by viability determination using the MTT reduction assay and by electrophoresis/immunoblotting for the appearance of cell death-associated protein changes. In some instances, incubations were carried out in the presence of a range of ophthalmic beta-blockers, to determine whether such compounds could counteract the detrimental changes seen after oxidative stress.

Results Each of the oxidative insults caused concentration-dependent reductions in cell viability and the appearance of markers that were suggestive of apoptotic cell death (positive TUNEL reactivity in cell nuclei, cleavage of PARP, increased levels of active caspase-3). Of the beta-blockers tested (metipranolol, carteolol, timolol, betaxolol, levobunolol), only metipranolol was able to significantly counteract the effects of oxidative stress to the RPE cells and this compound was effective against all oxidants. The effect of metipranolol was comparable with that of vitamin E and trolox, which are known antioxidants.

Conclusion Oxidative stress to cultured human RPE cells causes death that is characteristic of apoptosis. Metipranolol, like the known antioxidants Vitamin E and trolox, is able to counteract such oxidative insults to these cells.

■ 238 / 2328

Expression of Monocarboxylate Transporters in the Rat Retina: Effects of Retinal Degenerations

CHIDLOW G (1), WOOD JPM (1), GRAHAM M (2), OSBORNE NN (1)
(1) Nuffield Laboratory of Ophthalmology, University of Oxford, Oxford
(2) AstraZeneca R&D, Loughborough

Purpose Monocarboxylate transporters (MCTs) are expressed in the retina but the cellular localisation of the individual isoforms is still unclear. The purpose of this study was to investigate the expression of MCTs in the normal rat retina and in the retinas of rats which had undergone specific retinal degenerations to kill particular cell types.

Methods In order to kill neurons within the inner retina, Wistar rats were injected intravitreally with kainate and killed after 3 or 7 days. To induce degeneration of photoreceptors two experimental approaches were taken: (1) Wistar rats were exposed to bright light (approximately 2000 lux) for 48h and allowed to recover for 5 days, (2) Dystrophic Royal college of Surgeons' rats were killed at 3 time points: prior to, at the mid point of, and post-degeneration of photoreceptors. Levels of MCTs were determined by real-time RT-PCR, while immunohistochemical localization of MCTs was performed using isoform-specific peptide antibodies.

Results RT-PCR experiments showed that MCTs 1,2 and 4 are all expressed in the normal retina. Rats which had undergone photoreceptor degeneration expressed a lower level of MCT1 but higher levels of MCTs 2 and 4 mRNAs. In contrast, rats treated with kainate expressed reduced levels of MCTs 2 and 4 mRNAs. Immunohistochemistry of control and experimental retinas revealed that MCT1 labelling, although widespread, is concentrated in photoreceptor inner segments, while labelling for MCTs 2 and 4 is highly expressed by inner retinal neurons.

Conclusion MCTs 1, 2 and 4 are specifically and differentially expressed within the retina and altered expression of MCTs following inner or outer retinal degenerations reflects the loss of particular neuronal populations.

■ 239 / 2329

Aqueous humour formation is inhibited by bradykinin via production of cyclic GMP

WILSON WS, ALMALKI W, MARTIN W
Biomedical & Life Sciences, University of Glasgow, Glasgow

Purpose Arterial perfusion of the bovine isolated eye allows resumption of aqueous humour (AH) formation. We have studied the effect and mechanism of bradykinin (BK) on AH formation.

Methods AH formation rate was measured by perfusing bovine eyes through a ciliary artery with Krebs solution (2.5ml/min). AH formation was estimated by fluorescein dilution in a circuit that recycled AH from the cannulated anterior chamber via a fluorimeter. The slope of the regression line (loge [fluorescein] vs time) was taken as the rate constant for AH formation (Kout/min). Drugs were added to the arterial perfusate. Data were subjected to one-way ANOVA and expressed as mean +/- s.e. mean (n = 8 to 17). Once fluorescence values were stable, the starting value for AH formation rate was calculated over 40min. These values were somewhat variable among eyes, but for a given eye, remained stable for at least 120min.

Results Continuous infusion of BK produced a slow, concentration-dependent suppression of AH formation. BK at 1nM inhibited AH formation by 23 +/- 7%. When UK114542 (an inhibitor of phosphodiesterase V; 100nM) was infused simultaneously with BK (1nM), this inhibition was 32 +/- 7%. The effect of BK was mimicked in a concentration-dependent manner by perfusion of 8-bromo cyclic GMP (10pM to 1microM) and was abolished by KT-5823 (an inhibitor of protein kinase G; 10nmol injected every 15min).

Conclusion In the bovine eye, BK inhibits AH production by stimulating synthesis of cyclic GMP.

■ 240

Non-invasive detection of antibiotics in the aqueous humor by raman spectroscopy

SIDEROUDI TI (1, 2), PHARMAKAKIS N (3), PAPATHEODOROU GN (1), VOYIATZIS GA (1)
(1) FORTH/ICE-HT, Rio-Patras
(2) Department of Chemical Engineering, University of Patras, Rio-Patras
(3) Department of Ophthalmology, University of Patras, Rio-Patras

Purpose The purpose of this study is to develop a non-contact and non-invasive spectroscopic method to identify and quantify the presence of medicines (e.g: antibiotics and antiglaucomatics) in the aqueous humor of the eye.

Methods A new laser light delivery probe, adapted to an integrated CCD-based Raman spectroscopic system, gives the opportunity of favourable collection at 90o scattering geometry of the Raman light scanning the anterior chamber of the eye. The unique Raman signature of antibiotic Solvetan/ceftazidime was assessed at several concentrations.

Results Specific Raman signatures of probed molecules were easily resolved and low concentration of forenamed antibiotic (0,1 mg), lower than the clinical dose, that injected in the anterior chamber of porcine eyes were detected in vitro.

Conclusion Laser Raman spectroscopy is an inelastic light scattering technique capable of detecting and characterizing molecules in a variety of aqueous environments. This special illumination design might broaden the use of Raman spectroscopy into the field of ophthalmology since the direct exposure to laser light of basic cordial tissues of the eye like lens and retina are been avoided although an optimum scattered light collection is accomplished. Future studies are oriented to use this technique to investigate the pharmacokinetic of intraocular drugs in-vivo.

EVER-2004-abstractbook.indd 52 8/19/04 12:26:04 PM

■ 241

Differential Localization of c-Myc in Retinal Pigment Epithelial Cells.

KOTHARY PC, BANSAL A, ZIERENBERG A, DEL MONTE MA
Ophthalmology, Ann Arbor

Purpose Oncoprotein c-Myc has been identified in cytoplasm as well as in nucleus of a cell. c-Myc also plays a role in the cellular proliferation stimulated by growth factors. However, very little is know about the role of growth factors (GFs) on cellular localization and function of the cytoplasmic and the nuclear c-Myc.

Methods Cell proliferation was measured by the trypan blue exclusion method (TBE) and tritiated thymidine incorporation (3H-thy). c-Myc protein was measured by immunoprecipiation method. Immunocytochemistry was also performed using anti-c-Myc. Statistical analysis was done using the student "t" test. Hepatocyte growth factor (HGF) and adrenomedullin(ADM) response was compared with Ham's F12 medium alone as a control.

Results A maximum of 160% and 233% increase in hPRE cell number was observed in presence of ADM and HGF as measured by TBE. 3H-thy incorporation showed an increase of 125% in presence of ADM and 177% in presence of HGF. The studies of c-Myc synthesis showed that ADM stimulated 14C-c-Myc synthesis to 125% and HGF to 221%. Immunocytochemical studies using anti c-Myc showed c-Myc localized predominantly to the cytoplasm in presence of ADM and the nucleii in presence of HGF.

Conclusion ADM is a mild stimulator and HGF a potent stimulator of hRPE cell proliferation. c-Myc protein stimulated by ADM is primarily localized to cytoplasm and by HGF is primarily localized to thenucleus. The data suggest that nuclear translocation of c-Myc may be a potent growth regulator in hRPE cells and may play a role in the pathophysiology of proliferative vitreoretinal diseases.Supported by the Skillman Foundation.

■ 242

Transscleral Transport of the Triamcinolone Acetonide

MORA P (1), EPERON S (2), FELT-BAEYENS O (3), GURNY R (3), SAGODIRA S (4), BRETON P (4), GUIEX-CROSIER Y (2)
(1) Ophthalmology - University of Parma, Parma
(2) Jules Gonin Eye Hospital - University of Lausanne, Lausanne
(3) University of Geneva - School of Pharmacy, Geneva
(4) VIRSOL, Paris

Purpose Triamcinolone Acetonide (TA) is a corticosteroid largely used for therapy of intermediate/posterior ocular inflammations. In order to define the transscleral flux after a local administration, human scleral permeability to the TA was assessed in vitro.

Methods the in vitro experiments were carried out using a Franz type vertical diffusion cell. The scleral samples were obtained from the whole globes of the Eye Bank of the Jules Gonin Eye Hospital (Lausanne, Switzerland). A suspension of 20 mg/ml of TA was placed in the donor chamber of the apparatus, while a balanced salt solution filled the receptor compartment. TA concentration in the receptor chamber was measured by high-performance liquid chromatography (HPLC) analysis after 1, 2, 3, 4 and 7 days. The human sclera permeability coefficient (Ps) was finally calculated according to the Fick's law expression.

Results the rate of solved TA (+/- SEM) in the donor solution was 10.69 +/- 1.28 microg/ml. The steady state was reached after a 96-hour diffusion. 72% of the solved TA in the donor chamber was detected in the inferior compartment at the equilibrium, and the sclera permeability coefficient (Ps +/- SEM) was 1.47 +/- 0.17 x10-5 cm/second. The quantity of TA retained in the scleral disc increased with diffusion time and reached 4 microg/mg of scleral tissue after 7 days.

Conclusion TA crossed the human sclera. The mean amount of drug retained in the sclera increased with time, suggesting that the tissue could function as a reservoir. Four days were necessary to equilibrate the unidirectional flux. TA permeability coefficient was comparable to that of other corticosteroids.

■ 243

Potential protective effects of NSAIDs/coxibs/ASA in oxidatively stressed human lens epithelial cells and intact mouse lenses in culture

PETERSEN A (1), ZETTERBERG M (2), SJÖSTRAND J (2), PÅLSSON AZ (1), KARLSSON J-O (1)
(1) Institute of Anatomy & Cell Biology, Göteborg University, Göteborg
(2) Section of Ophthalmology, Institute of Clinical Neuroscience, Göteborg University, Göteborg

Purpose To investigate potential protective effects of NSAIDs/coxibs/ASA in oxidatively stressed human lens epithelial cells (HLEC) and intact mouse lenses in culture.

Methods Cultured HLEC were incubated with H2O2 (100 µM) alone or in the presence of indomethacin, diclofenac, celecoxib (0·005 and 0·05 µM) or acetylsalicylic acid (0·3 and 3 µM) for 24 hours. The cells were then assayed for caspase-3 activity or stained with Hoechst 33342 for nuclear morphology.Mouse lenses were oxidatively stressed by addition of 100 µM H2O2 once a day. Some lenses were simultaneously incubated with indomethacin, diclofenac, celecoxib (0·5 µM) or acetylsalicylic acid (30µM). Transparency of the lenses was examined every day for 8 days. Dose-response experiments of H2O2 as well as of NSAIDs/coxibs/ASA were performed prior to the presented experiments.

Results In HLEC, a low concentration of NSAIDs/coxibs (0·005 µM) or ASA (0·3 and 3 µM) showed a highly significant protective effect against mild oxidative damage caused by exposure to 100 µM H2O2 as revealed both by Hoechst staining and caspase-3 activity assays.In oxidatively stressed intact mouse lenses simultaneously exposed to H2O2 and acetyl salicylic acid, minor protection against oxidative damage could be detected with regard to lens transparency as compared to H2O2 only. Other NSAIDs/coxibs did not present any significant protective effect.

Conclusion We found a protective effect of NSAIDs/coxibs/ASA at low concentrations, against peroxide induced apoptosis in HLEC. In intact mouse lenses, only acetylsalicylic acid gave a week protection against oxidatively induced opacification.

■ 244

Method for Functional Imaging of the Reaction of Retinal Vessels to Provocation with Flicker Observation Light

KASSNER C (1), FINK A (1), NAGEL E (2), HENNING G (1), VILSER W (3)
(1) Technical University, Ilmenau
(2) Ophthalmic Private Practice, Rudolstadt
(3) Imedos GmbH, Jena

Purpose The dynamic analysis of retinal vessels is able to investigate autoregulative functions and its disorders in the field of retinal microcirculation. One way to stimulate the autoregulation is a provocation by flicker light. The change in vessel diameters in response to the provocation is captured with high temporal and local resolution along the vessel. The produced amount of data is huge, complex and difficult to interpret. Functional imaging was developed as an opportunity to show the vessel reaction corresponding to the local curse of the vessel.

Methods Before, during and after provocation by flicker light (12,5Hz monochromatic luminance flicker, provocation period 20s) flashed images of the fundus were taken.At first an eye movement compensation was done. Next the diameters of several vessels were measured in every image. The diameter response to flicker light was quantified by calculating the vessel dilatation relative to the baseline for every segment along every vessel. The dilatation was color coded and assigned to its location in the fundus image.A dedicated software system was used which is able to investigate several vessel sections.

Results Functional Imaging with high resolution along the vessel allows a segmental display of the vessel response and an evaluation of the functionality of every single vessel segment. It can be seen that segments of a vessel differ in its response to the provocation. Also vessels that show a good response in mean have segments that almost do not respond. This can clearly be seen in the functional image.

Conclusion Functional Imaging is a new method to display parameters describing autoregulative features of the microcirculation with a high spatial resolution.

EVER-2004-abstractbook.indd 53 8/19/04 12:26:05 PM

■ 245

Intraocular pressure lowering effect after Nd-YAG laser posterior capsulotomy: 0.2% brimonidine tartrate versus 0.15% brimonidine-Purite

SEONG GJ, LEE HK, LEE ES, KIM CY, HONG YJ
OPHTHALMOLOGY, YONSEI UNIVERSITY COLLEGE OF MEDICINE, Seoul

Purpose 0.2% brominidine is known to be effective in preventing IOP increase after Nd-YAG laser posterior capsulotomy. Reports of ocular allergy associated with chronic brimonidine therapy range from 4.2% to 12.7%. Brimonidine-Purite has a different preservative and a lower concentration of active drug than original brimoniedine tartrate. In this study, we compared the IOP lowering effect between 0.2% bromonidine tartrate and 0.15% brimonidine after Nd-YAG laser posterior capsulotomy.

Methods In patients who had received Nd-YAG laser posterior capsulotomy, 0.2% bromonidine tartrate and 0.15% brimonidine-purite were administered an hour before and immediately after the procedure randomly, and IOP was measured by Goldmann applanation tonometer at 1, 2, 3 and 24 hours after the procedure.

Results 71 patients were included in this study (0.2% bromonidine tartrate group: 37 patients, 0.15% brimonidine-purite group: 38 patients) Total laser energy was 57.9± 10.3mJ in 0.2% bromonidine tartrate group and 58.7±21.3mJ. In 0.15% group, IOPs at baseline, 1, 2, 3 and 24 hours after the procedure were 14.5±2.7mmHg, 11.8±2.9 mmHg, 12.1±3.6 mmHg, 12.2±3.9mmHg, 14.4±2.5mmHg in 0.2% bromonidine tartrate group. IOP at baseline, 1, 2, 3 and 24 hours after the procedure were 14.6±2.5mmHg, 12.1±2.7 mmHg, 12.4±3.1 mmHg, 12.3±3.3mmHg, 14.7±2.4mmHg in 0.15% brimonidine-purite group. There was no statistically significant IOP lowering effect between two groups at each time point.

Conclusion 0.2% bromonidine and 0.15% brimonidine-purite showed similar IOP lowering effect after Nd-YAG laser posterior capsulotomy.

■ 246

Nitric oxid formation in the eye of pregnant and virgine autoimmune MRL/lpr mice

GEHL Z (1), BAKONDI E (2), KÖKÉNY G (3), HAMAR P (4), VIRAG L (2)
(1) 1st Dept. of Ophthalmology, Semmelweis University, Budapest
(2) Dept. Medical Chemistry, Medical and Health Science Ctr, University of Debrecen, Debrecen
(3) Dept. Pathophysiology, Semmelweis University, Budapest
(4) Dept. Pathophysiology, Semmelweis University, Debrecen

Purpose The MRL/lpr mouse strain is a well known model of murine systemic autoimmunity, including eye inflammation. Animal studies using this model demonstrated increased severity of the systemic disease after pregnancy. However, according to other reports pregnancy may mitigate autoimmune uveitis.The present study aimed at investigating the possible involvement of pregnancy in the production of nitric oxid (NO) and its toxic metabolite, peroxynitrite. Reactive nitrogen species, in particular, peroxynitrite have been proposed to play an important role in the pathogenesis of eye inflammation.

Methods Nitrotyrosine, the biochemical marker of in vivo peroxinitrite production was detected by immunohistochemistry in the eyes of 8 pregnant and 10 virgine mice.

Results Examination of nitrotyrosine staining revealed pronounced immunopositivity in the cornea and sclera of eyes of virgine mices, and only minimal stainig of eyes of pregnant mices.

Conclusion In virgin MRL/lpr mice, autoimmune uveitis is associated with nitrotyrosine formation which may indicate in vivo peroxynitrite production. On the other hand, pregnancy suppressed intraocular nitrotyrosine formation (peroxinitrite formation). Our data implicate peroxynitrite in the pathogenesis of autoimmune uveitis. Characterization of the effect of pregnancy on the ocular inflammatory response will provide information critical to the understanding of the pathogenesis of intraocular inflammation so that more effective therapeutic interventions can be developed.
Supported by OTKA Nr. T35182 and OTKA Nr. F034498

■ 247

The influence of diclofenac ophthalmic solution on the intraocular pressure lowering effect of 0.005% latanoprost in glaucomatous patients

GAVIOLI IG, SEBASTIANI AS, RUSSO AR, CASILLO FC, PARMEGGIANI FP, COSTAGLIOLA CC
Department of Ophthalmology, Ferrara

Purpose To verify the influence of a non-steroidal anti-inflammatory drug (NSAID) ophthalmic solution on the intraocular pressure (IOP) reduction induced by 0.005% latanoprost and 0.5% timolol eyedrops, in patients affected by primary open-angle glaucoma (POAG).

Methods Randomized, prospective, masked clinical study.Thirty-two POAG adults, compensated with 0.5% timolol, were randomized into two study groups (A and B). Timolol was continued for two weeks in all patients. At the 3rd week, group A started a 5-week therapy with topical 0.1% diclofenac, whereas placebo were administered to group B. On the 15th day, in both groups timolol was replaced by latanoprost, and this regimen lasted for eight weeks. IOP was recorded at 7-day intervals during the first seven weeks and at the 10th week.

Results NSAID and placebo did not modify the IOP-lowering effect induced by timolol. In both groups, latanoprost induced a significant IOP decrease. NSAID-treated patients exhibited a marked fall in IOP ($p < 0.01$) whereas, in placebo-treated patients, this diminution was less noticeable ($p < 0.05$). After NSAID withdrawal, in group A IOP significantly increased ($p < 0.01$), remaining approximately at the same level up to the end of the study. In group B there were no significant differences in IOP at the same checks.

Conclusion In POAG patients, diclofenac significantly enhances the latanoprost-induced IOP-lowering effect, without affecting the timolol hypotensive efficacy. The synergism between NSAID and latanoprost could represent an advantage, but also an unconsidered risk of ocular hypotony, during the long-term treatment of glaucomatous patients.

■ 248

Penetration of oral Ofloxacin into aqueous humour in Cataract surgery

SHIEW M (1), KARIM A (1), FIRTH G (2), FIRTH M (2), THOMPSON GM (1), MOSS R (1), COWDREY G (2)
(1) St George's Hospital, London
(2) Princess Royal Hospital, Haywards Heath, W.Sussex

Purpose We have previously shown that many antibiotics given as prophylactic cover during cataract surgery fail to achieve minimum inhibitory concentrations (MIC) in aqueous humour. We have also reported that aqueous levels of Ofloxacin reached the MIC90 of Staphylococcus epidermidis in 88% of patients after single dose Ofloxacin. We now report on the measurement of Ofloxacin in aqueous humour after 2 oral doses.

Methods 30 patients received 2 doses of 400mg Ofloxacin before surgery (one dose the night before, and the other dose on the morning of surgery). At operation, 100-200µl of aqueous was collected via a paracentesis, placed into Eppendorf vials and stored deep frozen until analysis. We used capillary electrophoresis with UV detection to measure concentrations of Ofloxacin in the samples.

Results The mean aqueous humour concentration following 2 oral doses was 2.01mg/l. We have previously shown that a single oral dose achieved a significantly lower mean concentration of only 0.69 mg/l ($p < 0.0001$) and that there was no advantage to topical application. 93% of those taking 2 oral doses achieved the MIC90 of staphylococcus epidermidis. There were no cases of endophthalmitis in the study.

Conclusion Oral Ofloxacin given as 2 separate 400mg doses may be useful as prophylaxis against endophthalmitis in patients undergoing cataract surgery. Penetration of topical Ciprofloxacin is not adequate for prophylaxis. Capillary electrophoresis is a useful method for assay of Ofloxacin in small volumes of aqueous humour.

EVER-2004-abstractbook.indd 54 8/19/04 12:26:06 PM

■ 249

Retinal arterial vessel response: Comparison of local phenylephrine or liquid tear eye drop application

LANZL I (1), VILSER W (2), KOTLIAR K (3)
(1) Eye Clinic, Techical University, Munich
(2) Biomedical Engineering, Techical University, Ilmenau
(3) Eye Clinic, Technical University, Munich

Purpose Phenylephrine 10%, a sympatomimetic agent, is widely used to induce mydriasis in ophthalmology. The aim of this study was to determine, whether a single drop of topical phenylephrine 10% is able to influence retinal branch artery diameter.

Methods The diameter of retinal branch arteries after phenylephrine 10% or liquid tear (control) application was assessed in 10 young healthy volunteers between the age of 22 to 45 years (28,4 +/- 8,2). The volunteer did not know which drop was given. Changes in vessel diameter were observed by Retinal Vesel Analyzer (RVA) for 30 min after application of the drop to the study eye. Every 2 min pulse and systemic blood pressure were assessed. On a different day the other eye drop was given.

Results Liquid tears: 3 persons showed significant change in blood pressure and vessel diameters. 3 volunteers showed significant change in blood pressure but no changes in vessel diameters. The others showed no change in any parameter.Phenylephrine 10%: Significant changes in blood pressure in 2 volunteers; in 7 no systemic blood pressure change (4 vessel constriction of 6,9%+/-3,7% (p<0,01) after 13,1+/-3,3min; 2 no significant changes in vessel diameter (p=0,2) compared with baseline 1 vessel dilation of 6,8% after 11,2min); 1 volunteer showed a significant drop in blood pressure and constriction.

Conclusion Topical single application of phenylephrine 10% may alter retinal branch arterial diameter and blood pressure and exceeds changes in the liquid tear group. Whether arterial diameter change is a reaction to change in systemic parameters or a local vessel regulatory response can not be determined from our study.

■ 250

A Change in the Trace Element Composition of Aqueous Humor in Cataract and Glaucoma as a Possible Derangement Factor of its Metabolic Activity and Hydrodynamics

IOMDINA EN (1), KISELEVA OA (2), KACHAN OV (2), ZHUKOV CR (3)
(1) Helmoltz Research Institute of Eye Diseases, Moscow
(2) Helmholtz Research Institute of Eye Diseases, Moscow
(3) Perkin-Elmer Instr, Moscow

Purpose Aqueous humor (AH) provides nutrition for avascular ocular structures. For this reason, its composition, physical and chemical properties (in particular, the viscosity) as well as the circulation rate are physiologically important. Purpose: to study the change of trace element concentration in AH of patients with different stages of glaucoma and senile cataract.

Methods Inductively Coupled Plasma Mass Spectrometry (ELAN 6100, Perkin-Elmer) was used to determine the content of more than 80 trace elements in AH of 38 patients with immature and mature senile cataract and 14 patients with diverse stages of primary open-angle glaucoma (POAG).

Results It was found that with the maturing of the cataract the content of Ca in the AH is increased by about 30%. A 1.5–2 times increase was observed in the content of Zn, Ti, Pb, and B. A statistically significant reduction was noted in the levels of Cu, Al, and Co. Even more essential changes occur in the trace element composition of AH when the course of POAG worsens: the levels of B, Mg, P, Na, K, Cr and Fe increases several times, whilst a drastic decrease (by over 5 times) is observed in the concentrations of Al, Ba, Si, Mn, Ti and Zn: essentially, these are the elements directly related with the functioning of the antioxidant protection system of eye media and tissues, as well as with collagen metabolism.

Conclusion Significant changes in the trace element composition, more expressed in POAG than in senile cataract, testify to changed physical and chemical properties of the circulating AH. They may be a serious derangement factor of its hydrodynamics, ion exchange and antioxidant protection system functioning.

■ 251

Effects of cAMP on Short-Circuit Current in Porcine Ciliary Epithelium

NI Y, WU RY, FLAMMER J, HAEFLIGER I.O.
University Eye Clinic Basel, Laboratory of Ocular Pharmacology and Physiology, Basel

Purpose To investigate and attempt to characterise how cyclic adenosine monophosphate (cAMP) analogues modulate short-circuit current (Isc) in isolated porcine ciliary processes and/or epithelium bilayers.

Methods In an Ussing-type chamber, peak Isc dose-response curves to cAMP analogues 8-OH-cAMP, 8-bromo-cAMP, and/or 8-CPT-6-Phe-cAMP (0.01 µM - 30 µM were constructed. Effects of a protein kinase A inhibitor (30 µM Rp-8-OH-cAMP), cations (1 mM amiloride, 10 mM BaCl2) and anions channel blockers (0.1 mM bumetanide, 1 mM DIDS, 0.1 mM niflumic acid), a carbonic anhydrase inhibitor (1 mM acetazolamide), Na+-, Cl--, or HCO3--free solutions on 8-bromo-cAMP-induced Isc increase were assessed.

Results Applying cAMP analogues on the non-pigmented epithelium (NPE) side induced marked peak Isc increase, while on the pigmented epithelium (PE) side they induced no or very little Isc increase. 8-bromo-cAMP-induced Isc increase (10 µM: ~ 17.72 ± 2.7 µA/cm2) was significantly reduced by bilateral exposure (both on NPE and PE sides) to Na+-, HCO3--, or Cl--free solutions. 8-bromo-cAMP-induced Isc increase was significantly prevented by applying on the NPE side Rp-8-OH-cAMP, bumetanide, niflumic acid, DIDS, acetazolamide, and on the PE side by niflumic acid, but not by bilateral application of amiloride or BaCl2.

Conclusion In isolated porcine ciliary epithelium, essentially on the NPE side, cAMP stimulates transepithelial ionic transport. This transport appears to involve a protein kinase A (inhibited by Rp-8-OH-cAMP) as well as potentially a Na+-K+-2Cl- cotransport (inhibited by bumetanide on the NPE side) and a Cl- channel (inhibited by niflumic acid on the PE side).

■ 252

The effec of methamphetamine in the rabbit retina after in vitro exposure

RODRIGUES LG (1, 2), TAVARES MA (3, 1), OSBORNE NN (2)
(1) Neurobehaviour, IBMC, University of Porto, Porto
(2) Nuffield Laboratory Ophthalmology, University of Oxford, Oxford
(3) Institute of Anatomy, Faculty of Medicine, University of Porto, Porto

Purpose To determine whether methamphetamine (MA) can influence the uptake and/or release of norepinephrine (NE), Epinephrine (E) dopamine (DA), 3,4 - dihydroxyphenylacetic acid (DOPAC), serotonin (5-HT) and 5-hydroxyindoleacetic acid (5-HIAA) in the rabbit retina.

Methods In the uptake assays, pieces of freshly dissected retina were preincubated for 15 min in 2mL of buffer with various amounts of MA or chlorimipramine (CA, 10µM). 5-HT (10µM) was then added and the incubation allowed to continue for 30 min. In the release assays, tissues were incubated with 5-HT for 15 min and then exposed to fresh buffer (20mL) containing various amounts of MA or 30mM KCl for 40 min.Tissues were fixed and processed for the immunohistochemical localisation of 5-HT or were used for neurochemical determination.

Results Immunohistochemistry analysis showed that MA at concentrations of 100µM or greater inhibits the uptake of 5-HT and potentiates the release of accumulated 5-HT in an apparent dose dependent manner. Neurochemical analysis showed that MA, for concentrations higher than 100µM, affects the uptake of 5-HT, 5-HIAA and DA. MA potentiates, as well, the release of 5-HT and DA for concentrations higher than 20µM and 1mM respectively. No differences could be found for NE, E and DOPAC content by HPLC analysis both for the uptake and the release assays after MA exposure. The uptake of 5-HT was almost blunted by 1mM MA or 10µM CA. Moreover, 1mM MA or 30mM KCl completely released the accumulated 5-HT.

Conclusion MA inhibits the uptake and increases the release of accumulated serotonin and dopamine, in vitro, at concentrations greater than 100µM. The effect of MA on the retinal system seems to be similar to what has been described to occur in the brain.

EVER-2004-abstractbook.indd 55 8/19/04 12:26:06 PM

■ 253

Effects on morphometric parameters in the rat optic nerve following prenatal exposure to methaphetamine

MARTINS ALMEIDA MELO P (1, 2), PINAZO DURAN MD (3), TAVARES MA (1, 2)
(1) Institute of Anatomy (Faculty of Medicine), Porto
(2) Neurobehavior (IBMC), Porto
(3) Ophalmology Research Unit "Santiago Grisolia", Valencia

Purpose To evaluate the effect of prenatal exposure to methamphetamine (MA) on morphometric parameters of the rat optic nerve.

Methods Pregnant female rats were given 5mg/kg body weight/day MA, s.c., in 0.9% saline from the gestational day 8 to 22. The control group was injected an isovolumetric dose of 0.9% saline. Animal model parameters, such as pregnant females body weight evolution, pregnant females food intake and pups parameters were registered. The pups were sacrificed at postnatal day 21 and samples of optic nerve cross-section were obtained. Optic and electronic morphometric analyses were performed on optic nerve diameter and area, axons density, total number of axons and myelin thickness.

Results The animal model parameters, such as maternal and pups weight showed no significant differences. Optic nerve diameter and area were smaller in the MA group, both for males and females. The mielinated axon density was higher in MA group in both male and female. No differences in the non-mielinated axons. The myelin thickness of the small axons on the MA females was reduced when compared with the respective control group. No other differences were found concerning myelin thickness.

Conclusion The exposure to MA during the prenatal period appears to influence some morphometric parameters at the postnatal age studied-PND21. The ON diameter, area and net area were smaller, both of males and females, in the MA group when compared with the control group. The myelinated axons density was not influenced by the prenatal exposure of MA. The myelin thickness was significantly reduced on MA females, both on small and large axons.

■ 255 / 2427

Adaptive Optics: a new in vivo in situ non-invasive method toward a high resolution image of retinal photoreceptors

SALAMA BS (1, 2, 3), GLANC MG (4), GICQUIEL JJG (1, 5, 3), LE GARGASSON JFL (6)
(1) Ophthalmology, Saint Jean d'Angély
(2) Saint Jean d'Angély, Poitiers
(3) Ophthalmology, Saintes
(4) Astronomy, Meudon
(5) Ophthalmology, Poitiers
(6) Laboratoire de Biophysique de la Vision, Paris

Purpose To expose our experience in visualizing retinal photoreceptors of human eye in vivo with a non-invasive method in order to test the difference in image resolution obtained with and without Adaptive Optics (AO).

Methods The essential component of AO system is Shack-Hartmann wavefront sensor SH. This sensor analyzes the retinal wavefront, determines its deformations, and calculates in real time the corrections to be applied on. SH output is transmitted to an adaptive optical element: the deformable mirror DM composed of 13 actuators. It cancels wavefront aberrations by applying an opposite distortion that is the exact reverse of that measured by SH. The resulting wavefront is nearly plane.

Results First subject has aberration limited eyes: with AO we obtained a sharper retinal image. The difference of retinal photoreceptors distinction with and without AO is obvious.Second subject has post radial keratotomy higher order aberrationsthat exceeded the capacity of our DM.AO increase retinal image sharpness. It may specify the pathogenesis of different macular degenerations. It may better analyze the mechanism of functional recovery failure after macular surgery.In addition, with AO we may trace photoreceptors' development and functioning during amblyopic occlusion therapy.

Conclusion AO system was already used in refractive surgery: it decreases the postoperative higher order eye aberrations, with superior post operative vision. In retinal field, obtaining a low-cost AO that could be easily integrated to different diagnostic and surgical instruments will be a great challenge to achieve remarkable progress in visual science.

■ 256 / 2428

A method of retaining LogMAR visual acuity data in a "loss-less" fashion

ANDERSON OA, FERNANDO FI, DAVIES NP
Chelsea and Westminster Hospital, London

Purpose LogMAR charts are usually scored via the chosen method at the time of reading. It is not possible to retrospectively alter the scoring method unless data is stored in a "loss-less" fashion. The purpose of the study is to design a data storage method accurately retaining LogMAR data for scoring via any method. We subsequently go on to compare data obtained by each scoring method.

Methods A simple and novel scoring grid was designed. The grid represents the LogMAR chart and allows the number of correct responses at each visual angle to be recorded. Data was recorded as a frequency of seeing curve. Twenty healthy volunteers read the LogMAR chart and the responses were recorded.

Results Three visual acuity scoring methods were performed, namely single letter scoring, line assignment, and logistic regression. Logistic regression consistently resulted in higher scores when compared to single letter scoring. Logistic regression, compared to line assignment, consistently scored higher, but only for visual acuities of less than 0.1 LogMAR.

Conclusion This 'loss-less' scoring grid provides accurate data storage, which allows choice, even at a later date, in scoring technique. This is important as visual acuity results may vary depending on the scoring methods adopted.

■ 257

30 Hz flicker multifocal electroretinography in different macular diseases

LESCH B (1), FARKAS A (2), VAMOS R (1), MODOS K (3), SALACZ Gy (1)
(1) 2nd Department of Ophthalmology, Semmelweis University, Budapest
(2) 2nd Department of Ophthalomology, Semmelweis University, Budapest
(3) Department of Biophysics and Radiation Biology, Semmelweis university, Budapest

Purpose To compare the results of examinations carried out with the usual multifocal stimulation method and the 30 Hz flicker multifocal stimulation, which theoretically only measures the function of cone-photoreceptors.

Methods Four patients, each a typical sufferer of one of the following inherited and acquired macular diseases: Stargardt macular dystrophy, Cone dystrophy, AMD, Macular hole, were examined with 30 Hz flicker stimulation and usual FOK multifocal stimulation. The results were expressed as percentages of the results obtained from control volunteers. Patients and controls were divided into two different age groups (I. 15-35 years, II. 36-75 years). The 30 Hz flicker mfERGs were obtained binocularly using Retiscan equipment (RolandConsult). The central 30° (radius) of the retina was stimulated by 61 hexagons using CRT. An ERG jet was used as the different electrode. For each patient, the trace array (calculated on the Fourier Analysis) was recorded and the response densities (DFT Digital Fourier Transformation 1st harmonic, nV/deg2) in the 5 concentric rings were calculated.

Results In each of the four patients, the reduction of the 30 Hz flicker responses compared to the normal values was much larger than the reduction of the multifocal ERGs responses compared to the normal values. The most pronounced reduction was found in the cone dystrophy and macular hole cases with the use of the 30 Hz flicker multifocal stimulation method.

Conclusion Both stimulation methods seem to be suitable for assessing the level of central retinal function. Our experiences show that in cases of cone dystrophy and macular hole, the 30 Hz flicker multifocal stimulation method is more suitable for measuring the function of the central retina.

EVER-2004-abstractbook.indd 56 8/19/04 12:26:07 PM

■ 258

Dominance of the Scotopic on the Photopic Mechanism in Developing Pigmented Rat Retina

YINON U, GURSHUMOV N
Physiol. Lab., Goldschleger Eye Res. Inst., Tel-Aviv Univ. Fac. of Med., Sheba Medical Center, Tel-Hashomer

Purpose Anatomical and physiological studies of the mammalian retina have established that the difference in retinal function between the various species and hence the dominant mechanisms are determined by the proportion of rods and cones. We have assumed that in our experimental model, i.e., pigmented rats, the scotopic mechanism, which is the dominant one, would develop before the photopic one.

Methods We have characterized, electroretinographically, the development of the dark- and light-adaptation processes in pigmented rats, differentiating between the two visual mechanisms from the first postnatal day (PD) to adulthood.

Results The first scotopic response could be detected from the pigmented rat's retina on the 8–9 PD, whereas the first photopic response appears only on the 12-13 PD. Such a difference, first time shown here, indicates that the two mechanisms are completely independent. In addition, all ERG parameters are characterized by increasing sensitivity with age, while the development of changes in both scotopic and photopic components continues till the 24-25 PD. In addition, we described all ERG latency parameters, which also reflect the dominant visual mechanism and its developmental changes. The most prominent result found was the significantly longer reaction time at younger age groups, under photopic conditions, and during the initial phase of visual function recovery.

Conclusion It has been concluded that there is a difference in the independent development of the scotopic and photopic ERG components in the rat retina, which depends directly on the dominant retinal mechanism. Consequently, we suggested that our experimental model imitates the retinal function of most mammals living in the scotopic conditions.

■ 259

Recording motion VEPs with an enhanced Roland RETIport system

KNEZY K (1), MOLNAR FE (1, 2), NEMETH J (1)
(1) 1st Department of Ophthalmology, Budapest
(2) Department of Ophthalmology, Stanford

Purpose Motion-onset visual evoked potentials have been proposed as a diagnostic tool for various diseases including retrobulbar neuritis, multiple sclerosis, as well as for amblyopia research. We here report our experiences with upgrading the Roland RETIport system to allow for the recording of motion-onset visual evoked potentials.

Methods Based on earlier studies (OphthRes 2003; S1,35), we decided to use a motion stimulus with the following characteristics: dartboard pattern, radial motion directions (expansion and contraction) to reduce optokinetic nystagmus, short duty cycle to avoid motion adaptation. The motion visual evoked potential capabilities were added to the off-the-shelf system through a software upgrade which was provided by the manufacturer based on our specifications.

Results The new motion VEP module integrates well into the user interface and allows for adjustment of stimulus parameters and presentation times. Application of the software upgrade was overall easy. It does not affect the possibilities to record standard visual evoked potentials and electro-retinograms as with the original system.

Conclusion In clinical applications the motion stimuli in use of rutin measurements of retrobulbar neuritis shows obvious usefulness, as well in amblyopia helps the follow up. The RETIport system can be enhanced without much effort. It is thus worth considering specialized stimuli if one is planning research projects for which the standard set of stimuli is not optimal. Supported by ETT 209/2003.

■ 260

Flash visual evoked potentials after pre- and postnatal exposition on zinc - experimental study

HERBA E, POJDA-WILCZEK D, POJDA SM, PLECH AR, MAKOWIECKA-OBIDZINSKA K
Department of Ophthalmology and Eye Clinic Division Medical University of Silesia, Bytom

Purpose Zinc is an essential element in our diet. It plays the important role in growth and development, the immune response and neurological function. The zinc deficiency as well as its too high level are harmful for the body. The supplementation with zinc, as the antioxidant agent, is known and often used. The aim of this study was to find some alterations in visual cortical potentials after pre and postnatal zinc exposition in rats.

Methods The study was carried out on 52 white, Wistar rats: 24 rats were the control group, 18 were prenatally exposed to ZnSO4x7H20 (50ppm/per day in drinking water) and 10 drank the solution of ZnSO4x7H20 (50ppm/per day) during the three weeks after delivery. FVEP were recorded by the LKC 1000 electrophysiologic set interfaced with personal computer system with Ganzfeld stimulator. The latencies and amplitudes of N1 and P1 peaks of FVEP were measured. The Student t-test was used for statistic analysis.

Results The differences between FVEPs in both exposed groups versus control were observed. The shortened of the N1 and P1 latencies and the increased of the N1 and P1 amplitudes were observed in group prenatally exposed to zinc only.

Conclusion The maternal zinc supplementation may have beneficial influence on visual cortical responses.

■ 261

Relationship between crowding effect and background color in disabled readers

VIDAL LÓPEZ J
Oftalmología, Otorrinolaringología y Anatomía Patológica - Universidad de Murcia, Spain

Purpose Crowding is the negative effect of surrounding visual elements on the recognition of a central target. The aim of this work is to test if improvement in accuracy reading obtained with coloured overlays is related to crowding effect diminution.

Methods Participants were two disabled readers (RR and ER), females, 7 and 8 years old respectively, CI >115 (WISC-R, Spanish version, 1999) and reading level below 5 percentile rank (Ramos and Cuetos, 1999). They used orange (RR) and aqua (ER) colored overlays. Stimuli consisted in 34 letters alone and 59 letters flanked by two adjacent letters. Each stimulus was presented printed in black on white paper. Individuals must recover the text with an overlay and read aloud the letter or the sequence flank/letter/flank. Participants read the list of letters six times for each color condition. The order of presentations was counterbalanced for avoid practice effect. Independent variables were: a) color (12 colored overlays of Cerium Visual Technologies Ldt.) and b) flanks (flanked and not flanked letters). Dependent variable was omissions of letters while subjects read aloud.

Results Two Repeated Measures ANOVA was performed, one for each disabled reader. In both cases, analysis showed a main effect of flanks [RR: $F(1, 5)=21.61$, $MSC=0.02$, $p=0.006$ and ER: $F(1,5)=10.94$, $MSC=0.02$, $p=0.02$] indicating that flanks produces significatively more omissions (RR: 21% and ER: 24% respectively) than letters alone. Color and color x flanks interaction were not significant indicating that improvement in reading with colored overlays was not related with the presence of flanks near to stimuli.

Conclusion Results suggests that crowding effect was not related to color background variations with colored overlays.

EVER-2004-abstractbook.indd 57 8/19/04 12:26:07 PM

■ 262

Eye-gaze position and contrast in natural environments

PINTO PD (1), NASCIMENTO SMC (1), FOSTER DH (2), AMANO K (2)
(1) Department of Physics, University of Minho, Braga
(2) Visual & Computational Neuroscience Group, University of Manchester Institute of Science and Technology, Manchester

Purpose To investigate the relation between eye-gaze position and contrast in natural environments.

Methods Eye-position data were recorded with a modified infra-red xy-gaze-tracking device in ten outdoors urban and rural stationary environments. Observers were instructed to look at each scene for 5 min so that they could answer a question about its composition afterwards. Hyperspectral data were recorded at the same time as eye-position data. Luminance and chromaticities were computed for each pixel of the scene and their absolute values and relative contrasts analysed in relation to the frequency of eye fixations.

Results It was found that, in general, the distributions of eye-gaze positions were close to the corresponding luminance distributions, showing that observers did not look preferentially to specific luminance regions. On the other hand, the distributions of eye-gaze positions were different from the luminance-contrast distributions: observers looked more frequently to locations with higher contrast levels. Chromatic contrast had little effect on eye-gaze position.

Conclusion Luminance contrast seems to influence eye-gaze position more than luminance or chromaticity.

■ 263

Contrast sensitivity during night driving in subjects older than 50 years

AGUSTIN GONZALO AGUSTIN M (1), SANCHEZ RAMOS SANCHEZ C (2), PEREZ CARRASCO PEREZ MJ (2), PUELL MARIN PUELL C (2), LANGA MORAGA LANGA A (2), ELENA TIRADO ELENA MJ (1), MARTINEZ DE MIGUEL MARTINEZ M (1)
(1) C/Gran Habitat n°1, Bajo D, Arganda Del Rey, Madrid
(2) Escuela Universitaria de optica (Universidad Complutense de Madrid), Madrid

Purpose To evaluate contrast sensitivity (CS) in mesopic conditions in the presence and absence of glare in vehicle drivers over the age of 50 years.

Methods Mesopic CS (3 cd/m2) was determined in 120 subjects (right eye) using the OPTEC 3500 device and the F.A.C.T. test. This involved evaluating the contrast threshold for the spatial frequencies: 1.5, 3, 6, 12 and 18 cycles/°. All tests were performed with habitual correction for long distance. Contrast sensitivity measurements with and without glare were made after a 5 min period of dark adaptation.

Results Maximum mesopic CT values with and without glare were obtained for the spatial frequencies 6 and 12 cycles/°; mesopic CS decreasing for higher or lower frequencies. Mesopic CS also diminished with age ($p<0.03$). Higher mesopic CS values were recorded for heavy vehicle drivers than motorcar drivers ($p<0.05$) and for subjects driving more than 5 days per week ($p<0.05$).

Conclusion The mesopic CS function shows a band-pass pattern similar to that shown by the photopic CT function. The higher mesopic CS in heavy vehicle drivers could reflect the visual requirements upheld by Spanish legislation. The fact that subjects with less mesopic CS drive less than 5 days/weeks suggests they are more reluctant to drive since they feel more insecure. The OPTEC 3500 instrument does not have an effective source of glare that is capable of producing disability glare.

■ 264

Effect of environmental luminance on contrast sensitivity in vehicle drivers

DEL MORAL MARTÍNEZ MI, SANCHEZ-RAMOS C, PEREZ-CARRASCO MJ, PUELL MC, LANGA-MORAGA A, PÉREZ-PÉREZ JM
Óptica fisiológica, Madrid

Purpose To evaluate the effect of the luminance of the environment on contrast sensitivity (CS) in vehicle drivers.

Methods CS was determined under photopic (100 cd/m2) and mesopic (3 cd/m2) conditions in 103 subjects (right eye) using the OPTEC 3500 instrument and the F.A.C.T. test (for spatial frequencies of 1.5, 3, 6, 12, 18 cycles/°). Both photopic and mesopic CS were evaluated after a 5 min period of dark adaptation.

Results Maximum photopic and mesopic CS values were recorded for a spatial frequency of 6 cycles/°. Under both luminance conditions, significant differences in CS were observed according to subject age and whether they had undergone cataract surgery. CS diferences between the two levels of luminance were noted for all spatial frequencies expect 3 cycles/°.

Conclusion Photopic and mesopic CS are both band-pass functions. Age shows a negative effect on mesopic and photopic CS. Higher driving frequencies were related to improved photopic CS for intermediate stimuli but these did not affect mesopic CS. Cataract surgery led to improved CS for intermediate spatial frequencies at both luminance levels. A reduced ambient luminance negatively affects CS in non-operated eyes.

■ 265

Effects of age and the retinal zone stimulated on differential luminance sensitivity in vehicle drivers over 65 years

VILA J, DEL-MORAL I, SANCHEZ-RAMOS C, PUELL C, PEREZ MJ, LANGA A, PÉREZ-PÉREZ JM
Óptica U.C.M., Madrid

Purpose To evaluate central visual field (30°) differential luminance sensitivity (DLS) in drivers over the age of 65 years and compare responses according to the zone of the retina stimulated and age.

Methods DLS was determined under photopic conditions (85 cd/m2) in 62 subjects (right eye) using a Humphrey model HFA-II 730 campimeter (Zeiss) to perform the STACTPAC technique with Goldmann's stimulus III. Tests were conducted with habitual correction for near vision.

Results The mean age of our population sample was 72.5 ± 5.4 years (85% men/15% women). Mean visual acuity was 0.82 ± 0.14. The mean spherical power of the lenses was +0.93 ± 1.87 D, and cylindrical power −0.87 ± 1.63 D. Mean added power was 2.42 ± 0.59 D. Mean DLS was 27.01 ± 2.52 dB. Values by retinal zone were: 30.32 ±2.35 dB (foveal), 28.77 ± 2.50 dB (parafoveal), and 26.14 ± 2.76 dB (peripheral). When the sample was stratified by age (older or younger than 70 years), significant differences in DLS were obtained for the four quadrants and the different retinal zones.

Conclusion Mean DLS values for the drivers differed significantly among the foveal, parafoveal and peripheral zones of the retina, with measurements made at the fovea being significantly higher. In drivers above 65 years, age showed a negative effect on DLS in all the retinal zones examined.

EVER-2004-abstractbook.indd 58 8/19/04 12:26:08 PM

266

Effect of coloured sunglasses on the colours of natural scenes

LINHARES JMM (1), NASCIMENTO SMC (1), FOSTER DH (2), AMANO K (2)
(1) Department of Physics, University of Minho, Braga
(2) Visual & Computational Neuroscience Group, University of Manchester Institute of Science and Technology, Manchester

Purpose To estimate the effect of coloured sunglasses on the chromatic diversity of natural scenes.

Methods Hyperspectral images of natural scenes were taken from 400-720 nm at 10 nm intervals (Nascimento et al, 2002 Journal of the Optical Society of America A 19 1484-1490) and calibrated to obtain the spectral radiance for each pixel of the scene. The transmittance spectra of 11 coloured lenses of commercial sunglasses were measured with a spectrophotometer and their effect on the light reaching the eye from the natural scenes computed. The coloured lenses were of acrylic type with blue, rose, grey, green and brown colours, and of glass type with green and brown colours. The number of discernible colours in each scene viewed with and without the coloured lenses was estimated by computing for each image the CIELAB representation of all pixels and counting the number of unit volumes in the three-dimensional volume defined by the scene in that space.

Results It was found that in general the effect of coloured sunglasses was to increase the estimated number of discernible colours and with some lenses, such as brown and green glass lenses, it was possible to obtain increases of around 15%.

Conclusion Contrary to expectations, coloured sunglasses need not impoverish the chromatic content of the scenes and in some cases they may actually improve it.

267

Computerised Chromatic Contrast Threshold Measurement Study of Digoxin Therapy

GALIBA V (1), ONG GL (1), SALEH G (2), DEWIT D (2)
(1) Vision research department, Sussex Eye Hospital, Brighton
(2) Ophthalmology Department, Colchester

Purpose To study the use of a computerised chromatic contrast threshold (CCT) measurement system to look at the following associations:1)Therapeutic digoxin levels and CCT2)Digitoxicity and CCT 3)Duration of digoxin use and CCT

Methods Study group: 56 patients receiving maintenance digoxin therapy with no other conditions known to affect colour vision.Control group: 62 age and sex-matched healthy subjects, with no history or signs of eye disease.Measurements: Venous blood sample for serum digoxin concentration taken at least 6 hours after the last digoxin dose. CCT was measured using a computerised cathode-ray-tube based system along the red-green (constant S-cone) and tritan (constant L/M-cone) confusion axes.

Results Of the study group, 54 had therapeutic digoxin levels and 2 were digitoxic. Laboratory therapeutic reference range for digoxin was 0.8 - 2.0 ng/ml.1)Mean red-green CCT (RGCT) and tritan CCT (TCT) for patients with therapeutic digoxin levels were 0.45 and 0.53 compared to 0.44 and 0.51 for the control group respectively. This difference was not statistically significant ($p>0.05$). However TCT was significantly correlated with serum digoxin levels ($r=0.56, p<0.0001$) more so than RGCT ($r=0.4, p<0.005$).2)RGCT and TCT for the digitoxic patients was significantly worse than therapeutic patients.3)Duration of digoxin therapy was not significantly correlated with CCT.

Conclusion CCT does not appear to be significantly affected in the therapeutic digoxin range, however TCT deteriorates significantly with increased plasma digoxin levels. CCT is significantly affected in digitoxic patients and may be useful as a screening tool requiring further study. The duration of digoxin therapy seems to have no significant bearing on CCT measurements.

268

Studies on the perception of very small visual stimuli (microdots)

NILSSON M, MARTIN L
Clinical Neuroscience, Stockholm

Purpose To quantify the effect of age, binocular summation, luminance and contrast on the perception of the microdot stimulus in normal subjects.

Methods The Rare Bit Microdot Foveatest (Frisén 2002), relies on the perception of very small (< 0.5 MAR) bright stimuli, called microdots.Three experiments were made.1. 25 subjects were tested with reduced screen luminance by the use of neutral density filter transmitting 50, 20, 15, 10, 7.5 or 5 % respectively. 2. 35 subjects were tested with reduced stimulus luminance by adjustment of the RGB settings such that four different stimulus luminances were defined, 64 cd/m2, 53 cd/m2, 41 cd/m2 and 33 cd/m2. 3. 19 subjects were tested with binocular stimulation in order to define the binocular summation by comparing the responses from monocular and binocular viewing. Stimulus luminance 33 cd/m2 was used to avoid a ceiling effect, which would hide the expected hit rate increase.

Results 1. A statistically significant reduction of mean hit rate was observed when filters transmitting 20% or less of the standard screen luminance were used.2. Significantly reduced mean hit rate and intra- and interindividual SD´s were observed at stimulus luminance 64 cd/m2 or less. 3. The mean hit rate to binocular stimulation, compared to the highest value from monocular stimulation in the same subject, was increased by a factor of 1.54, SD 0.45.

Conclusion The results in the current study indicate that microdots can identify some of the well-known features of the visual system, e.g. binocular summation and effect of age, provided that the stimulus luminance is carefully selected. The Rarebit Microdot Fovea may be useful for diagnosis in patients with age related macular degeneration or maculopathy in diabetes patients.

269

The influence of the cycloplegic in the objective refraction

JORGE J (1), QUEIRÓS A (1), FERNANDES P (1), ALMEIDA JB (2), PARAFITA MA (3)
(1) Physics (Optometry), Braga
(2) Physics, Braga
(3) Surgery (Ophthalmology), Santiago de Compostela

Purpose The purpose of this study was to compare refractions measured with an autorefractor and retinoscopy in cycloplegic and noncycloplegic eyes.

Methods The exams were performed on 199 right eyes from 199 healthy young adults. With a mean age of 21.6 ±2.66 years. These measurements were performed first without cycloplegia and repeated half one hour later with cycloplegia.Autorefraction was carried out with the ARK 700A. The retinoscopy was performed in each eye over the phoropter lenses. Data was analyzed using Fourier decomposition of the power profile.

Results The comparison of the autorefractor values with and without cycloplegic verifies that, for the component M, the autorefractor without cycloplegic yields more negative values (MARn vs MARc –0.86 ±0.79D), for the cylindrical vector J0 the autorefractor without cycloplegic yields more negative values (J0ARn vs J0ARc –0.05 ±0.11D), and for the J45 vector, the autorefractor without cicloplegic yields more positive values (J45ARn vs J45ARc 0.01 ±0.08D). The differences found for the M and J0 components are statistically significant. The comparison of the retinoscopy values with and without cycloplegic verifies that, for the component M, the retinoscopy without cycloplegic yields more negative values (MRETn vs MRETc –0.37 ±0.45D); for the cylindrical vectors J0 and J45 the autorefractor without cycloplegic yields more negative values (J0RETn vs J0RETc –0.01 ±0.11D; J45RETn vs J45RETc -0.01 ±0.07D). The differences found for the M component are statistically significant.

Conclusion The present results confirm that when performed by an experienced clinician, the retinoscopy is more accurate than automatic refraction giving a starting point to non-cycloplegic refraction.

EVER-2004-abstractbook.indd 59 8/19/04 12:26:08 PM

■ 270

Visual acuity anisotropy in simulated visual impairment

CACHO I (1), REEVES B C (2), DICKINSON C M (1), HARPER R A (3)
(1) Department of Optometry and Neuroscience, UMIST, Manchester
(2) Health Services Research Unit, London School Hygiene and Tropical Medicine,, London
(3) Academic Dept. of Ophthalmology, Manchester Royal Eye Hospital, Manchester

Purpose The gap in a Landolt-C optotype is more difficult to resolve when vertical than horizontal. We investigated this visual acuity (VA) anisotropy in normally sighted subjects with optimal acuity and with simulated visual impairment (VI).

Methods VA thresholds were measured for 12 subjects (mean age 26, range 21-32) in five conditions, viewing normally or with mild or severe VI simulated by contrast sensitivity reduction (fogging with Ryser occlusion foils) or blur (positive lenses). Single Landolt-C stimuli were presented in each of the 4 cardinal directions with the gap position selected randomly. The size of the gap when 3/5 stimuli were correctly identified was taken to be the threshold. Separate regression models were fitted to compare thresholds by gap position for each viewing condition.

Results VA anisotropy was not observed when viewing normally. For simulated visual impairment, right (R) and left (L) VA thresholds were better than up (U) by -0.14 logMAR ($p = 0.006$ and 0.005). Because thresholds for R and L, and U and down (D) were similar, a second analysis compared vertical (V) and horizontal (H) positions. This analysis found a significant main effect of position ($p=0.005$) and an interaction of position and condition ($p=0.008$); the difference in threshold between H and V was greater for fogging (H vs. V, -0.12 logMAR) than blurring (H vs. V, -0.06 logMAR).

Conclusion The step size for small stimuli may have been large relative to the size of the VA anisotropy when viewing normally. The anistropy observed for simulated VI was consistent with previous studies. The finding that the size of VA anisotropy depends on the type of simulated impairment justifies closer study of the phenomenon in subjects with simulated and real vision impairment.

■ 271

Variations in ocular biometry in University Students in Portugal

QUEIROS A (1), JORGE J (1), FERNANDES P (1), ALMEIDA JB (2), PARAFITA MA (3)
(1) Physics (Optometry), Braga
(2) Physics, Braga
(3) Surgery (Ophthalmology), Santiago de Compostela

Purpose This study was initiated to describe the variation in ocular biometry in university student's population in Portugal.

Methods The exams were performed on 199 right eyes from 199 young adults. Mean age of 21.6±2.66 years.Axial ocular dimensions, including axial length (AL), anterior chamber depth (ACD), lens thickness (LT), and vitreous chamber depth (VCD) were measured using an A-scan ultrasound device. Corneal eccentricity (CE) was measured with an autorefractor.The sphere values (S) were measured using the subjective distance refractive method with cycloplegic.High myopia (HM) was defined as $S<-1.50D$, low myopia (LM) $-1.5D \leq S < -0.25D$, emmetropia (E) as $-0.25D \leq S \leq +0.25D$,low hyperopia (LH) as $+0.25D < S \leq +1.5D$ and high hyperopia (HH) as $S > +1.50D$.

Results The AL, ACD, LT, VCD, and CE,values were 23.31±0.88mm, 3.51±0.26mm, 3.64±0.14mm, 16.17±0.80mm and 0.48±0.12 (mean±SD), respectively. Statistically there are significant differences between the groups for the AL, ACD, and VCD. The values for the AL component in mm was (HM=24.61±1.09; LM=23.78±0.62; E=23.29±0.60; LH=23.08±0.73; HH=22.69±0.64).The values for the ACD component in mm was (HM=3.76±0.27; LM=3.67±0.24; E=3.48±0.25; LH= 3.46±0.24; HH=3.35±0.24).The values for the VCD component in mm was (HM=17.24±1.08; LM=16.47±0.59; E=16.23±0.60; LH=15.96±0.69; HH=15.72±0.62).For LT, and CE there are no significant differences.

Conclusion This is one of the first survey from the Portuguese population. Just like in other studies, ours results also revealed that ocular refraction vary with ocular dimensions. The ACD e VCD have the main influence in the development of the error refractive.

■ 272

Optoelectronic visual aid based on reconfigurable logic for severe peripheral vision loss rehabilitation

VARGAS-MARTÍN F (1), PELáEZ-COCA MD (1), ROS E (2), DÍAZ J (2), MOTA S (2)
(1) Departamento de Física (área Óptica), Universidad de Murcia, Murcia
(2) Dep. Arquitectura y Tecnología de Computadores, Universidad de Granada, Granada

Purpose A low cost non-invasive optoelectronic visual aid based, to provide information on the peripheral field of view without compromising the residual visual acuity of central fovea. To improve the reduced navigation capabilities of tunnel vision patients, due to diseases as RP, Usher syndrome, or advanced glaucoma. The aid pretends be portable and useful during the evolution of the disability and for other user requirements, as zoom or night blindness.

Methods A head-mounted video camera captures a wide angular field. After video processing, a see-through head mounted display presents a minified only-edge version of the captured image overlapping the user normal view in the central visual field.For the video processing unit, we have selected a reconfigurable hardware (FPGA) logic that allows the easy and cheap modification of the device features.As preliminary evaluation, subjects with simulated tunnel vision have selected settings adapted to realistic video scenes in a wide field screen.

Results A first prototype has been integrated. Real time video edge extraction is achieved with the FPGA with user customized settings. The user can modify processing parameters dynamically. Selected settings are dependent on subject preferences even with similar visual loss.

Conclusion We have shown the feasibility of such a portable visual aid for peripheral field loss. The inclusion of a reconfigurable circuit FPGA allows real time video processing, the setting control by the user, and personalisation for each individual person in a simple way. This platform has the possibility of having several processing configurations at the same time as digital zoom or TV enhancement.

■ 273

Disadvantage of the superotemporal field in normal subjects as revealed by techniques that study the function of the magnocellular pathway

SILVA M (1), GUERREIRO M (1), CASTELO-BRANCO M (1, 2)
(1) IBILI/Center for Ophtalmology, University of Coimbra, Coimbra
(2) Departement of Biophysics, Faculty of Medicine, Coimbra, Portugal

Purpose Available evidence regarding anisotropies of superior/inferior and nasal/temporal retinal function have been previously documented based on psychophysical measurements. We aimed to assess such anisotropies within the magnocellular pathway, using frequency doubling technology (FDT) which isolates the My magnocellular pathway.

Methods FDT perimetry was performed by the following tests: T1. Humphrey C-20 (n= 36 eyes) and T2. N-30 (n= 22) T3. N-30-F Threshold (n=80) T4. our custom-made C-20 -like(n = 69). Groups performing tests 3 and 4 were independent from all the other groups.

Results The superotemporal(ST) field showed in general higher thresholds. The interaction between ST and inferonasal(IN) fields was statistically significant for all tests: T3 ($p < 0.0001$, ANOVA), T2 ($p = 0.0032$), T1 ($p = 0.0025$) and T4 ($p = 0.0012$). Also for ST and superonasal (SN): T3 ($p = 0.0008$), T2 ($p = 0.0028$), T1 ($p = 0.0028$) and T4 ($p = 0.0343$). The same for the ST and the inferotemporal(IT) fields, except for T2. T3 ($p = 0.0043$), T1 ($p = 0.0343$) and T4 ($p = 0.0002$). No significant differences were found for left and right hemifields. Significant effects between upper and lower fields were found only for tests T3 and T4 ($p= 0.0025$ and 0.0001, respectively). T3 revealed a significant interaction between nasotemporal and updown assymetries ($p= 0.03$).

Conclusion The results showed that in normal subjects the magnocellular pathway within the superotemporal quadrant has relatively worse performance as compared to other regions of the visual field. This type of anisotropy is consistent with the previous finding that this region shows earlier abnormalities when assessed by motion perimetry in glaucoma.

EVER-2004-abstractbook.indd 60 8/19/04 12:26:09 PM

274

The impact of cellular phone usage on ophthalmic equipment

SALEH GM (1), DE WIT DW (2), ALLEN RJ (3), GAUBA V (4), AZIZ O (5)
(1) Ophthalmology , Essex County Hospital, Colchester
(2) Optometry, Essex County Hospital, Colchester
(3) Optometry, Colchester
(4) Ophthalmology, Leeds
(5) General Surgery, London

Purpose To identify and quantify the degree of interference cellular phones inflict on ophthalmic equipment and assess its clinical significance.

Methods The investigation utilized the UK Medical Devices Agency electromagnetic compatibility testing protocol. Evaluation of cellular phone interference was performed at 10 different distances (0m to 2m) and three settings (standby, connected call and ringing/dialling), with field strength quantification of each of these combinations determined using a spectrum analyzer. Two cellular phones, operating at 900MHz and 1800MHz carrier frequencies, were used to test the following ophthalmic equipment: Two Phacoemulsification machines, cryotherapy machine, cautery machine along with previously tested Field Analyzers, surgical lasers and A/B Scanners, whilst each device was on standby and then operational.

Results The field strength emitted by the phones (in milli Watts of peak power above background random noise) ranged from 10.18mW to 243.82mW. Interference was demonstrated with three pieces of equipment. The B scanner (Ultravision) showed horizontal banding on the display screen at 0m test distance, with both the 900MHz and 1800MHz frequencies, present in the dialling and connected modes only. The YAG laser (Alcon YAG 2500) emitted a buzzing sound when the 900MHz phone was within 10cm in connected and dialling modes but no problems were noted at 1800MHz. The Legacy Sseries 2000 Advantec Phacoemulsification machine also emitted a buzzing from the speaker with the 900MHz phone at 20cm and less in calling and connected modes but no problems occurred at. There was no evidence that the interference induced any clinically significant malfunctioning whilst the devices were operational.

Conclusion Cellular phone usage around the afore mentioned ophthalmic equipment appears to be relatively safe with interference only occurring at <10cm on two machines and even then being of no detectable clinical significance.

EVER-2004-abstractbook.indd 61 8/19/04 12:26:09 PM

301

Angiogenesis in the eye after an intravitreal injection of adenovirus vegf-a

KINNUNEN K (1), RISSANEN T (1), UUSITALO H (2), YLA-HERTTUALA S (1)
(1) Dept of Biotechnology and Molecular Medicine, A.I.Virtanen Institute, University of Kuopio, Kuopio
(2) Dept of Ophthalmology, University of Kuopio, Kuopio

Purpose It is well established that vascular endothelial growth factor (VEGF) is important for angiogenesis in the eye. The aim of this study was to determine which tissues in the eye respond to an intravitreal injection of adenovirus expressing VEGF-A (AdVEGF-A) and find the optimal dose for gene transfer.

Methods Eight New Zealand White rabbits were divided in four groups. The intravitreal injections were performed under the microscope. AdVEGF-A was injected to the right eyes with different titers (10e10vp/ml, 10e11vp/ml, 10e12vp/ml) and two animals had AdLacZ (10e12vp/ml) as controls. Left eyes were injected with saline. Fundus photographs were taken before the injection and postoperatively on day 5 and the anterior parts were digitally pictured. The animals were killed on day 6, vitreous and blood samples were collected and eyes enucleated for histological analyses.

Results There were changes in postoperative fundus photographs in all groups except the control group. Changes included microaneurysms, hemorrhages and new vessels and they increased as the dose of the adenovirus vector increased. With the highest dose (AdVEGF-A 10e12vp/ml) the adenovirusvector caused severe endophthalmitis in the eye. In histologic analysis both the anterior parts and the retina had new vessels as compared to the control eye. The changes increased as the dose increased. The best titer for AdVEGF-A seemed to be 10e11vp/ml.

Conclusion In this study we induced neovascularization both in the posterior and in the anterior parts of the eye with an intravitreal injection of adenoviral VEGF-A. The model will be useful for studies regarding the pathogenesis of angiogenesis and for the development of new therapeutic strategies for angioproliferarive retinopathy.

302

Measuring the cone contribution to the ERG b-wave to assess function and predict anatomical rescue in RCS rats

PINILLA I (1, 2), SALIVÉ Y (1), LUND RD (1)
(1) Department of Ophthalmology. Moran Eye Center, Salt Lake City
(2) Servicio de Oftalmologia. Hospital Univesitario Miguel Servet, Zaragoza

Purpose To study anatomical and by ERG the photoreceptor rescue after subretinal injections of human retinal pigment epithelial cells early in the course of retinal degeneration in Royal College of Surgeons (RCS) rats.

Methods Ten injected animals were studied using a double flash electroretinogram (ERG): six were examined longitudinally (59 and 90 days) and four terminally (90 days) with immunohistochemistry.

Results The ranking of animals with respect to ratios of rod/cone function remained the same at the two time points studied. Furthermore, the functional data obtained at 59 days of age correlated with the anatomical data obtained at 90 days of age. Correlations were seen for areas in the center and adjacent to the injection site: these areas tended to have the highest number of photoreceptors. Comparison between ERG results and anatomical observations from all areas achieved the highest correlation. Furthermore, despite the anatomical observation that the highest proportion of cones reached 15.6% in individual retinal areas studied, and 12.6% for averaged areas (from the same animal), the corresponding functional data indicated no rod contribution to the b-wave. This suggests that although rods still comprise the majority of photoreceptor population, they do not contribute to ERG responsiveness.

Conclusion The proportion of cone contribution to the ERG b-wave rather than the absolute size of isolated response proved to be a reliable indicator of functional rescue over time and a predictor of the proportion of cones identified anatomically in the area of optimal photoreceptor rescue.

303

Cone function in P23H rats

SALIVÉ Y (1), PINILLA I (1, 2), LUND RD (1)
(1) Department of Ophthalmology. Moran Eye Center, Salt Lake City
(2) Servicio de Oftalmologia. Hospital Universitario Miguel Servet, Zaragoza

Purpose The P23H transgenic albino rat is an animal model of autosomal dominant RP, which exhibits a mutation in the rhodopsin gene. The purpose of this study was to examine the impact of the degeneration process on cone function using flicker electroretinogram (ERG).

Methods Normal albino Sprague-Dawley (SD) rats and homozygous P23H transgenic aged from 21 to 250 days were studied. Corneal ERGs were recorded in response to stimuli consisting of white light flashes (1.37 log cds/m2) presented at frequencies ranging from 3 to 50 Hz, under light adapted conditions (29.8 cd/m2). The effect of light adaptation and increments in background illumination were tested at P30 in both groups.

Results In all responsive animals at all ages, maximal amplitudes were obtained at 3 Hz. SD rats showed a small but statistically significant decrease in fusion frequencies with age (46±5 Hz at P22; 35±2 Hz at P150). At P21, amplitudes and fusion frequencies were significantly lower in P23H compared with age matched SD rats. With increasing age, response amplitudes and critical fusion frequencies declined progressively. Other changes included prolongation in latency. At P250, P23H rats were still responding, with flicker fusion values of 12-14 Hz.With the first 10 minutes of light adaptation, 20 Hz flicker amplitudes increased significantly, after which amplitudes started to decrease with prolonged exposure to bright light. Increase in background illumination caused a diminution in flicker response amplitude and critical fusion frequencies in both animals.

Conclusion In P23H rats, cone function is already impaired at P21. Flicker responses can be recorded up to P250, at which point the retina has undergone severe regressive and reactive changes in its connectivity patterns.

304

Subretinal injection of human retinal pigment epithelial cells can preserve rod and cone function in a model of retinal degeneration, the RCS rat

SALIVÉ Y (1), PINILLA I (1, 2), LU B (1), WANG S (1), LUND RD (1)
(1) Department of Ophthalmology. Moran Eye Center, Salt Lake City
(2) Servicio de Oftalmologia. Hospital Universitario Miguel Servet, Zaragoza

Purpose The Royal College of Surgeons (RCS) rat undergoes a progressive loss of photoreceptors due to a primary defect in retinal pigment epithelial cells. We examined whether healthy human retinal pigment epithelial (hRPE) cells (line ARPE19) would preserve rod and cone function when injected subretinally prior to significant retinal degeneration (age P23).

Methods Animals with subretinal hRPE and sham (culture medium alone) injections received dexamethasone for 2 weeks and were kept under oral cyclosporin. They were examined with electroretinogram (ERG) recordings at age P60. Intensity responses curves were obtained and fitted with Naka-Rushton to determined maximal amplitudes between hRPE and sham treated groups.

Results Dark-adapted ERGs showed preserved a-waves (33±6 μV vs none), mixed b-waves (136±36 μV vs 15±9 μV), and double flash isolated rod b-waves (108±17 μV vs 11±3 μV) and cone b-waves (63±16 μV vs 20±5 μV). Maximal mixed b-wave amplitudes were obtained at -0.02 log cds/m2, showing reductions at higher stimulus luminance (up to 2.8 log cds/m2) regardless of prolongation in inter stimulus intervals. Cone b-waves remained stable after maximal amplitudes were reached. Photopic ERGs showed preserved b-waves (43±9 μV vs 15±8 μV) and critical flicker fusions of 27±4 Hz vs 14±2 Hz. Cone related events persisted for as long as age P250, with no evidence of any rod driven activity.

Conclusion Human retinal pigment epithelial cells injected into the subretinal space of dystrophic RCS rats limit deterioration of both rod and cone function, but with time rod responses are lost even though rods are still preserved in these retinae.

EVER-2004-abstractbook.indd 62 8/19/04 12:26:10 PM

305

Leber congenital amaurosis - a case report

VÁMOS R, FARKAS Á, SALACZ G
2nd Department of Ophthalmology, Budapest

Purpose To present a rare, inherited retinal dystrophy with early-onset severe visual impairment.

Methods A 13 month-old girl with lack of visual attention since 3-4 months of age attended our department Her pupil reactions were sluggish and she had slight roving eye movements. Examination methods included indirect binocular funduscopy, measuring refraction and electrophysiology.Follow-up: 12 month after the first examination.

Results At the age of 13 months the only retinal alteration was a marbleized pattern at the periphery. At the age of 18 months funduscopy revealed diffuse, confluent whitish spots exept in the central area within the vascular arcades. Full-field electroretinography was not detectable under either scotopic or photopic conditionsat at repeated examinations.

Conclusion The reported case was clinically diagnosed as leber congenital amaurosis on the basis of ERG-examinations. In cases of unexplained, severe visual impairment in preverbal infants, electrophysiological tests are of prime importance.

306

The Prevalence of Refractive Errors in University Students in Portugal

JORGE J (1), FERNANDES P (1), QUEIRÓS A (1), ALMEIDA JB (2), PARAFITA MA (3)
(1) Physics (optometry), Braga
(2) Physics, Braga
(3) Surgery (Ophthalmology), Santiago Compostela

Purpose This study was initiated to assess the prevalence of refractive state in university student's population in Portugal.

Methods A population sample of 199 university students were randomly selected and examined in cycloplegia. The results obtained using the subjective distance refractive method were used in the analysis and refractive values were converted into spherical equivalents (SER) for some analysis (i.e. sphere value + 1/2 of the cylinder value). Myopia was defined as SER<-0.25 D, emmetropia as SER >= -0.25 D and <= +0.25 D and hyperopia as SER > +0.25 D.

Results The refractive error of the sample, ranged from –8.75 to +3.75 D mean spherical equivalent + 0,20 ± 1,53D (Mean ± SD.). The maximum amount of astigmatism was –2,25 D. The incidence of refractive errors was: 22.1% of the students had myopia, 23.1% had emmetropia and 54.8% had hyperopia. Statistically there are no significant differences between male and female (male mean refractive error (MRE) = 0.21 ±1.55 D; female MRE = -0.06 ± 1,59 D) or any significant MRE differences between the students in the first year or in the last year (1st year (MRE) = 0.051 ±1.685 D; 4th year MRE = -0.03 ± 1,29 D). However, the prevalence rates of myopia in females (26%) are higher than the rates in males (14%). And the prevalence rates of hyperopia in 1st year students (57%) are higher than the rates in the 4th year (49%).

Conclusion The results then show an incidence of myopia similar to results obtained in other countries. Just like in other studies, ours also revealed a higher prevalence of myopia among women than men, as well as show a myopia shift during the university course.

307

Five-year mortality rate following blind/partially sighted registration in Sunderland, UK

SETHU MADHAVAN A (1), VAIDEANU D (2), FRASER S (2)
(1) Ophthalmology, Royal Victoria Infirmary, Newcastle Upon Tyne
(2) Ophthalmology, Royal Victoria Infirmary, Sunderland

Purpose To compare five-year mortality rate of the patients registered blind/partially sighted (BD8) with mortality in the general population.

Methods Retrospective study of patients registered blind/partially sighted during one-year period in an UK eye hospital. The data was collected from the hospital records and the death registry for the area covered by the hospital. The age at BD8 registration and death, the cause of BD8 and sex were recorded. The data was age and sex stratified, according to the UK national statistics office for calculating death rates. Statistical analysis was done with and without patients with diabetes and cardiovascular events, using chi-squared test.

Results 153 patients were BD8 registered in 1995 by the hospital: 92 (60.13%) females and 61 (39.87%) males. The mean age at registration was 73.37 years for the whole sample. However, the mean age at BD8 registration for males was 67.04 years and 77.56 years for females. The mean age at death was 82.55 years for the whole sample and 77.7 years for males and 85.77 years for females. The number of deaths in each age group was evenly distributed for the males; the female deaths were concentrated in the older age group.

Conclusion The expected death rates in our sample were lower than expected compared with the general population for both female/male subgroup and the whole group. It was also observed in this sample that the younger at BD8 registration (less than 65 years of age) the more likely to die if visually impaired than general population. This might be because the patients registered blind/partially sighted younger had a higher incidence of cardiovascular disease and diabetes.

308

The prevalence of open angle glaucoma on the west coast of Iceland

LINDEN C (1), JÓHANNESSON G (1), GUÐMUNDSDÓTTIR GJ (2)
(1) Dept of Clinical Sciences, Ophthalmology, Umeå University, Umeå, Sweden
(2) Ophthalmology Clinic, Akranes, Iceland

Purpose To establish the age- and sex-specific prevalence of open-angle glaucoma (OAG) on the west coast of Iceland.

Methods The compulsory ophthalmologic examination needed for prescription of eye glasses in combination with information obtained from Statistics Iceland were used to retrospectively establish the glaucoma prevalence in the town of Akranes and to estimate the lowest prevalence for the greater west coast area.

Results 79.1% of 1443 inhabitants > 50 years of age in Akranes had visited the eye clinic at least once during the past 5 years. The overall prevalence of OAG in this population was 4.8% (95% CI 3.6-6.1) with no significant difference between sexes. The lowest prevalence calculated for the west coast as a whole was 3.8% (95% CI 3.2-4.4). The prevalence of OAG increases with increasing age ($p<0.001$). The predominant glaucoma types were simplex and capsular glaucoma, similarly distributed.

Conclusion The results with respect to glaucoma prevalence and participation rate are in the same magnitude as in similar studies indicating that the method used in this study is comparable to other methods used to establish glaucoma prevalence.

EVER-2004-abstractbook.indd 63 8/19/04 12:26:10 PM

■ 309

Vision screening of secondary school children in Poland

SALOMON E (1), JANOCHA A (2), URBAN E (2)
(1) Department of Physiology Medical University of Wroclaw Poland, Wroclaw
(2) Department of Physiology Medical Universityof Wroclaw Poland, Wroclaw

Purpose The aim of the study was to assess value of vision screening of secondary school children population.

Methods Examinations were carried on 1462 children 15 years old. Visual acuity, stereopsis, fundus of the eye, cover test and refraction (by autorefractometer) were measured.

Results Examinations revealed 26,6% children with refraction errors: > 32,4% of them were undetected before sreening, > 28,3% of them will need correction glasses change, 5.6% children were examined for the first time by ophthalmologist. We found 1,7% children with stereopsis disturbances and squint. There were no children with pathological changes of the eye fundus.The most frequent refraction error in this population was myopia (13,2%), astigmatism (12,8%) and hyperopia (5,6%).

Conclusion The obtained results point on high value of specialistic vision screening of secondary school children population besacuse of high frequency of undetected refraction errors and amount of children which will need correction glasses change.

■ 310

Clinical outcome of endonasal KTP laser assisted dacryocystorhinostomy

RESSINIOTIS T, VOROS GM, KOSTAKIS VT, NEOH C
Department of Ophthalmology, Royal Victoria Infirmary, University of Newcastle upon Tyne, Newcastle upon Tyne

Purpose To evaluate the clinical outcome and success rate of endonasal laser assisted dacryocystorhinostomy (ENL-DCR) using the potassium-titanyl-phosphate (KTP) laser.

Methods We retrospectively reviewed in detail all primary ENL-DCRs performed between March 2001 and March 2002 by the same combined Ophthalmology and ENT team in Newcastle upon Tyne NHS Trust, UK. The main outcome measure for success was resolution or significant improvement of epiphora. Intraoperative complications and causes of failure were also studied. Mean postoperative follow-up interval was 16 months (range 12- 24 months).

Results A total of 44 consecutive ENL-DCRs were performed on 29 patients (22 females, 7 males, mean age 75 years) within the studied period of 12 months. All patients had bicanalicular silicone intubation for at least 4 months. The success rate at 12 months postoperatively was 75%. Preexisting pathology related to failure included: mucocele (5 cases), sinus disease (2 cases), previous nasal fracture (2 cases) and systemic sarcoidosis (1 case). No intraoperative or significant postoperative complications were recorded.

Conclusion The primary ENL-DCR performed with KTP laser is a safe and efficient method for the treatment of nasolacrimal duct obstruction.

■ 311

Acute dacryoadenitis and the prominent role of non-steroidal anti-inflammatories.

DE WIT DW (1), ROSE GE (2)
(1) Adnexal Firm, Moorfields Eye hospital, London
(2) Adnexal Firm , Moorfields Eye hospital, London

Purpose To compare the efficacy and clinical outcome of initial treatment options such as observation, NSAID (non-steroidal anti-inflammatory drugs) and antibiotic usage in acute dacryoadenitis.

Methods The records of 40 patients referred to the Moorfields Eye Hospital between 1980 and 2002 with the diagnosis of acute dacryoadenitis were reviewed with special reference to computed tomography scans, histopathologic specimens (in 1 patient), treatment regimens and final clinical outcome.

Results Initial treatment consisted of antibiotics alone (5), NSAID alone (15), a combination of antibiotics and NSAID (11), and observation alone (9). At two weeks one of the patients treated with antibiotics alone had improvement (20%), 13 of the patients treated with NSAID alone had improvement (87%), eight of the patients treated with combined antibiotic and NSAID had improvement (72%) and not one of the observed patients showed any improvement (0%). The main complication post therapy was a residual mass, this being highest in patients who had antibiotic treatment only (40 %) The mean follow-up was 5 months (range 14 to 365 days).

Conclusion Although steroids have been advocated as first line treatment in the past for all types of IOID new treatment options are being established for specific disease entities. In patients with acute dacryoadenitis, NSAID usage appears to offer faster relief of symptoms with fewer residual complications as opposed to antibiotics or observation alone.

■ 312

3D tele-ophthalmology adds new clinically useful informations the the images of the anterior segment of the eye

LIBONDI T (1, 2), COLONNA G (3), CRICELLI R (2), GRIFFO E (4)
(1) Dept. of Ophthalmol. and CRISCEB (Center for Res. in Comput. Sci. and Biotech.) II University, Napoli
(2) Medical Services sas, Napoli
(3) CRISCEB and SIM (Serv. Inform. Med.) II University, Napoli
(4) Dept. of Ophthalmol. II University, Napoli

Purpose The importance of visual information in ophthalmology makes it obvious that telemedicine can offer substantial benefits in terms of ophthalmological consultation. The reality of these images is hampered by the lack of the third dimension, which can add depth sense.

Methods A Haag Streit BQ900 photographic slit-lamp was equipped with two C-mounts adapters, one for each objective. Two Olympus Camedia C-4040Zoom digital cameras were mounted on. The images for left and right eye of theobserver were simultaneously acquired and sent in JPEG format to a workstation. They were processed and rendered by using Stereographics Stereo3D(TM) software and CrystallEyes 3 goggles on a high definition monitor and/or sent through the net.

Results High definition stereo-images of the anterior segment of the eye were acquired. The anterior chamber depth, lens thickness and the spatial relationships between the different structures were clearly appreciated. The approx. size of a single (left or right) image was about 1 Mb by using the JPEG compression algorithm. They were easily sent though the net and viewed in different locations with the same stereo effect.

Conclusion The possibility to take, store, send and render 3D images of the anterior segment of the eye with a relativey simple and inespensive tool has been tested. It has been proved to be possible and feasible. The addition of stereopsis to adds new informations, as compared to a bidimensional image, to the clinical image of the anterior segment of the eye. Its potential usefulness in scientific, clinical and didactic fields are outlined.

EVER-2004-abstractbook.indd 64 8/19/04 12:26:11 PM

■ 313

Paracetamol induced hepatic injury leading to bilateral vitreous haemorrhage

ALLEN RJ (1), SALEH GM (2, 3), RACHAPALLI S (4), DE WIT DW (1, 2), SHELDRICK J (1)
(1) Essex County Hospital, Colchester
(2) Institute of Ophthalmology, London
(3) Princess Royal University Hospital, London
(4) Colchester General Hospital, Colchester

Purpose To report a case of sudden bilateral vision loss secondary to paracetamol overdose.

Methods Single observational case report

Results A previously well 37-year-old man presented to the emergency department six hours after taking 45 grams of paracetamol along with an unknown quantity of alcohol. Initial investigations showed paracetamol levels of 522mg/L, abnormal renal and hepatic function and evidence of Lactic acidosis. He was given vitamin K, n-acetyl cysteine and admitted to Intensive care unit Consequently, he complained of a reduction in vision. Visual acuities were hand movements with good projection of light in the right eye and 6/18 in the left eye. Bilateral vitreous hemorrhages were found on ophthalmoscopy and confirmed with B-scan ultrasonography. The vitreous hemorrhages cleared spontaneously over the next few months and the acuity recovered.

Conclusion Vitreous hemorrhage is a frequent complication of vitreoretinal pathologies but rarely occurs as a result of a coagulopathy. This case highlights the importance of ocular manifestations of systemic disease and adds a previously unreported association to the literature. Physicians should be wary of visual complaints in those with coagulopathy as although uncommon, a clear causal association exists. We recommend that vitreous hemorrhage be considered in cases of blurred vision with coagulopathy

■ 314 / 3355

Degradation of GLUT1 by the ubiquitin proteasome pathway (UPP) on retinal endothelial cells

FERNANDES R (1), CARVALHO AL (2), MURTA J (3), FERNANDES A (3), FARO C (2), PEREIRA P (3)
(1) Center of Opthalmology, Coimbra
(2) Center for Neurosciences, Coimbra
(3) Center of Ophthalmology, Coimbra

Purpose GLUT1 is the main transporter responsible for the glucose uptake in retinal endothelial cells. The purpose of this study is to determine if the UPP participates in regulation of levels of GLUT1 in response to oxidative stress.

Methods Retinal endothelial cells were exposed to 40 or 100 µM of hydrogen peroxide. Endogenous ubiquitin conjugates and GLUT1 were detected by Western Blotting and immunofluorescence confocal microscopy. The levels of GLUT1 in cell membranes were determined following biotinylation of membrane proteins. The involvement of the UPP on constitutive GLUT1 degradation was further assessed by transfection of HEK cells with pCAGGS-GLUT1.

Results Proteasome inhibition leads to an accumulation of total GLUT1 content and to a specific stabilization in membrane of endothelial cells. The same was observed for HEK 293 T cells transfected. These results suggest the involvement of the UPP on constitutive GLUT1 degradation. Moreover, oxidative stress further enhances degradation of GLUT1. Inhibition of proteasome following oxidative stress results in a dramatic increase in the amount of GLUT1. Significantly, recovery from oxidative stress leads to increased degradation of GLUT1 by a proteasome dependent mechanism.

Conclusion The data suggests that the oxidative stress is a potencial mechanism that may induce increased degradation of GLUT1 by the UPP presumably contributing to alter glucose homeostasis in diabetes.

■ 315 / 3356

Detection of basic fibroblast growth factor after scleral implantation of orbital adipose tissue in a pig's eye

PINNA A (1), CARTA A (2), MANUNTA L (3), CAREDDU GM (3), MADEDDU P (4, 5), CARTA F (1)
(1) Institute of Ophthalmology, University of Sassari, Sassari, Italy
(2) Institute of Ophthalmology, University of Parma, Parma, Italy
(3) Institute of Veterinary Surgery, University of Sassari, Sassari, Italy
(4) Institute of Internal Medicine, University of Sassari, Sassari, Italy
(5) National Laboratory of the National Institute of Biostructures and Biosystems, Osilo, Italy

Purpose Evidence indicates that the basic fibroblast growth factor (bFGF) has a protective effect on the retina. Previous studies have shown that adipocytes can produce bFGF. The present experiment was undertaken to investigate the effect of the scleral implantation of orbital adipose tissue on bFGF production in the eye of a pig.

Methods A 2-month-old pig underwent the surgical procedure performed in Cuba for the treatment of retinitis pigmentosa under general anesthesia. A conjunctival incision was made in the right eye and a pedicle flap of retrobulbar fat with blood vessels was implanted in a scleral pocket in the posterior part of the globe. The left eye served as the control. The animal was suppressed 8 months after surgery and the eyes were enucleated. A specific ELISA was used to detect bFGF levels in the choroid and in the retina along with the proximal portion (3 mm) of the optic nerve.

Results ELISA showed that bFGF levels were as follows: 4122 pg/ml (right choroid), 40,297 pg/ml (right retina + optic nerve), 5362 pg/ml (left choroid), 19,631 pg/ml (left retina + optic nerve).

Conclusion Results suggest the surgical procedure used in Cuba might increase bFGF levels in the nerve tissue of the eye. Further "in vitro" and "in vivo" studies are necessary to confirm these preliminary data.

■ 316

Causes of blindness in equatorial rain forest, Democratic Republic of Congo

KAIMBO WA KAIMBO D (1), MISSOTTEN L (2)
(1) Dept of Ophthalmology, Univ of Kinshasa, Kinshasa
(2) Dept of Ophthalmology, Catholic University of Leuven, Leuven

Purpose To determine the causes of blindness in equatorial rain forest, Democratic Republic of Congo, to aid in planning for the prevention and management of avoidable causes.

Methods During a one month period (may 2003), a study was carried out in equatorial rain forest (three rural centres). A total of 790 persons were examined and ocular examination included visual acuity, refraction, slit-lamp examination, funduscopy and measurement of intraocular pressures. The WHO definition of blindness was used.

Results Of 790 persons, 95 were bilaterally blind with a mean age of 58 years (range, 6 to 89 years). Monocular blindness was found in 114 persons. The main causes of bilaterally blindness were cataract (55%), glaucoma (29%), corneal opacity (4%), age-related macular degeneration (3%), and phthisis bulbi (2%). The main causes of unilateral blindness were cataract (32%), glaucoma (15%), and corneal opacity (12%).

Conclusion This study demonstrated that major causes of blindness are cataract, glaucoma and corneal opacity. A prevention strategy is therefore needed and targeted to these diseases.

EVER-2004-abstractbook.indd 65 8/19/04 12:26:11 PM

■ 317 / 3357

Cumulative incidence of visual impairment and competing risks in childhood-onset type 1 diabetes

VIRTAMO T (1), KIVELÄ T (1), YKI-JÄRVINEN H (2), STENMAN UH (3), HARJUTSALO V (4), TUOMILEHTO J (4), LAATIKAINEN L (1), SUMMANEN P (1)
(1) Ophthalmology, University Hospital, Helsinki
(2) Medicine, University Hospital, Helsinki
(3) Chemistry, University Hospital, Helsinki
(4) Epidemiology and Health Promotion, National Public Health Institute, Helsinki

Purpose To study the cumulative incidence of visual impairment in relation to lifetime glycaemic control, systolic (SBP) and diastolic blood pressure (DBP) in childhood-onset diabetic patients in Finland.

Methods 5166 Finnish patients under the age of 18 were diagnosed with Type 1 diabetes between 1965-1979. In a population-based sample of 1032 patients clinical data on retinal examinations, visual acuity (VA) and medical risk factors were analysed since the onset of diabetes. Mean annual HbA1c, SBP and DBP were calculated. The vitality data were obtained from Statistic Finland. Cumulative incidence of permanent loss of VA 0.5, 0.3 and 0.05 in the better eye is reported using death without visual loss as a competing risk. Cox regression analysis of loss of VA 0.5 with HbA1c, SBP and DBP as a time-varying covariates is reported.

Results Cumulative incidence of loosing VA 0.5, 0.3 and 0.05 by 20 of diabetes was 4.1%, 2.7% and 1.6% and by 30 years 6.6%, 5.4% and 2.0%, respectively. Cumulative incidence of death without loosing VA 0.5, 0.3 and 0.05 by 30 years was 9.6%, 10.3% and 11.2%, respectively. Loosing VA 0.5 in the better eye was significantly related to HbA1c (HR 1.42 for every 2% unit increase p = 0.000), SBP (HR 1.47 for every 10 mmHg increase; p = 0.000), and DBP (HR 1.49 for every 5 mmHg increase; p = 0.000), not to gender, age and year at the onset of diabetes.

Conclusion Hyperglycaemia and hypertension were significantly related to visual loss. Cumulative incidence of dying was 5 times higher than blindness by 30 years of diabetes.

■ 318 / 2316

Ocular & Dermal Hydration: The Role of Hydrogels in the Control of Moisturisation

TIGHE B (1, 2), BAHIA R (1, 2)
(1) Biomaterials Research Unit, CEAC
(2) Aston University, Birmingham UK

Purpose Inadequate hydration of the cornea and skin can result in unacceptable symptoms of dryness associated with these body organs. The presence of a contact lens presents additional complications. Nature often uses similar control mechanisms in related body sites. This poster considers the tissue hydration control mechanisms that operate in the anterior eye and the skin, together with the potential for exploitation of techniques from one field in the other.

Methods Model substrates representing lipoidal and aqueous delivery pathways to cellular layers are prepared. Hydrogels are prepared loaded with species known to be important in promoting skin hydration (natural moisturising factors – NMFs). Examples include: - 2-pyrrolidone-5-carboxylic acid- amino acids (e.g. glycine)- alpha hydroxy acids (e.g. lactic and lactobionic acids)- Vitamins (especially B5, A, B6, E).

Results The study illustrate that it is possible to release NMFs from a polymer matrix through both aqueous and lipoidal routes. Release data will be presented. Biphasic hydrogel technology allows control of the release the release of both hydrophilic and hydrophobic NMFs.

Conclusion The eye is dominated by the aqueous environment and the skin is dominated by the lipoidal environment. Nonetheless dry skin and dry eye are both induced by inadequacies in lipid and moisture levels and control mechanisms. It seems logical to investigate treatment of early stages of dry eye, particularly contact lens induced dry eye, by delivery of selected natural moisturising factors. The use of the contact lens as a delivery matrix offers great potential in this respect, provided that the subtleties of the release mechanisms are properly utilised.

■ 319 / 2317

Correlation of Schirmer test score and tear break up time with Ocular surface staining in Dry Eye disease

SUNDARAM V, EVERY S, BRON AJ, SAMARASINGHE S, PRABHAKARAN E, VATHESATOGIT C
Nuffield Laboratory of Ophthalmology, Oxford

Purpose Controversy exists as to the value of diagnostic tests in the dry eye diagnosis. Questions remain as to the relation between test parameters and disease severity. This study aims to evaluate correlations between the Schirmer test, tear break up time (TBUT) and ocular surface staining in patients with dry eye disease.

Methods A retrospective review of dry eye patients was performed. Patients with the diagnosis of dry eye were retrieved from the Oxford Eye Hospital database. Of the 98 patients located, 20 were identified with a Schirmer test score of less than 10 mm, who had a full record of both inter-palpebral and extra-palpebral ocular surface staining with the Oxford Grading Scheme. There were 19 females and 1 male, with a mean age of 50.9 years (range 20-83 years). For statistical analysis, correlation coefficients were calculated for right and left eyes using the Spearman rank correlation test with SPSS version 10.

Results TBUT was significantly correlated with total ocular surface staining ($p<0.01$), staining in the inter-palpebral region ($p<0.01$) and temporal conjunctival region staining ($p<0.05$), in both eyes. In the left eye, TBUT was also significantly correlated with nasal conjunctival ($p<0.05$) and corneal ($p<0.05$) staining. The Schirmer test did not correlate significantly with any areas of ocular surface staining in either eye. Also there was no correlation between the Schirmer test and the TBUT.

Conclusion TBUT showed significant correlation with degree of ocular surface staining and may reflect the severity of ocular surface inflammation more accurately than the Schirmer test in patients with dry eye disease.

■ 320

Ultrastructural findings and BIG-H3 expression in a new syndrome of corneal lattice dystrophy with myelopathy

AKHTAR S (1), TALBOT K (2), BRON A (3), DONAGHY M (4)
(1) Optometry and Vision Sciences, Cardiff
(2) Department of Clinical Neurology, Oxford
(3) Nuffield Department of Ophthalmology, Oxford
(4) Department of Clinical Neurology, Radcliffe Infirmary, Oxford

Purpose To describe the ultrastructural findings in the cornea of an individual from a family with a novel, dominantly inherited phenotype of lattice corneal dystrophy (LCD) associated with muscle wasting and spasticity of the limbs.

Methods Method: Structural study of a corneal button obtained at keratoplasty. Amyloid deposits localised by post-embedding gold labeling using polyclonal big-h3 antibody and 10nm gold conjugate.

Results The affected family consisted of a father and two daughters. Each family member demonstrated clinical signs consistent with a progressive, intrinsic spinal cord lesion. MRI examination demonstrated high signal within the cervical spinal cord attributable to a myelopathy. Signs were more advanced in the daughters. Corneal signs were of flake-like opacities and branching lattice-like lines in the corneal stroma and were sufficiently severe in the father, to lead to corneal grafting. There were no erosive symptoms. Ultrastructural examination of the father's cornea indicated the presence of amyloid deposits in the corneal stroma, in keeping with the diagnosis of LCD. Although mutations in the Big-h3 gene were not found in the patients with this disorder, the product of this gene, keratoepithelin was found in the corneal tissue. Screening for mutations in the gelsolin gene, (responsible for the lattice corneal dystrophy with Familial Amyloid Polyneuropathy) and of the Big-h3 gene (responsible for dominantly inherited lattice corneal dystrophy, types I, III and IV) were negative.

Conclusion This family represents a combination of lattice corneal dystrophy and myelopathy which may be due to deposition of insoluble amyloid protein in both the cornea and the spinal cord.

EVER-2004-abstractbook.indd 66 8/19/04 12:26:12 PM

321

Differentially altered proteins in keratoconus

NIELSEN KN (1, 2), VORUM HV (3), PER FAGERHOLM PF (4), BIRKENKAMP-DEMTRÖDER KBD (2), HONORÉ BH (3), ORNTOFT TFO (2), EHLERS NE (1)
(1) Department of Ophthalmology, Aarhus
(2) Molecular Diagnostic Laboratory, Aarhus
(3) Department of Medical Biochemistry, Aarhus
(4) Department of Ophthalmology, Linköping

Purpose Purpose: Keratoconus is a bradytrophic corneal disease that causes myopia and astigmatism. Several genes/proteins have been investigated over the last two decades, in particularly stromal proteases and their inhibitors in attempt to describe a patho-mechanism. Last year we published data showing epithelial transcript alterations related to the extracellular matrix, the cytoskeleton, and signalling. This study will focus on differentially expressed proteins.

Methods Proteins were isolated from the corneal epithelium from 6 keratoconus patients and 6 references (myopia) and separated using two-dimensional gel electrophoresis. The 6-12% polyacrylamid gels were silver stained and quantified by densitometry. Selected proteins were identified by mass spectrometry (Alphalyse A/S, Denmark).

Results Nineteen protein spots were analysed by mass spectrometry and 4 individual proteins were identified including gelsolin (1.6-fold), alpha-enolase (0.7-fold), cytokeratin 3 (not determined), and S100A4 (1.9-fold). Mutations in the gelsolin gene are known to cause Lattice dystrophy type II and mutations in keratin 3 may be involved in Meesmann's dystrophy. The transcript encoding enolase is also encoding the lens protein, tau crystallin. The S100A4 protein is involved in corneal wound healing.

Conclusion Four proteins were found altered in keratoconus comparing a group of keratoconus corneas to a reference group; three of them described to be involved in other corneal dystrophies. No relation was found to genes or proteins known implicated in keratoconus.

322

Prophylactic and therapeutic efficasy of active and passive immunization using 20-kDa against S. epidermidis keratitis

GEORGAKOPOULOS C (1), EXARCHOU A (1), GARTAGANIS S (1), ANASTASSIOU E (2), DIMITRAKOPOULOS G (2), HJERPE A (3), THEOCHARIS A (4), KARAMANOS N (4)
(1) Department of Ophthalmology, University of Patras, Patras, Greece
(2) Department of Microbiology, University of Patras, Patras, Greece
(3) Department of Laboratory Medicine, Karolinska Institutet, Huddinge University Hospital,, Stockholm
(4) Laboratory of Biochemistry, University of Patras, Patras, Greece

Purpose To study the protective and therapeutic effects both of active (AI) and passive immunization (PI) in an experimental model of slime-producing S. epidermidis keratitis.

Methods For AI, 20 rabbits received an intradermal immunization with 20-kDa PS (a major immunogenic determinant of slime). For (PI), 20 rabbits were administrated with specific IgG Abs against 20-kDa PS. Lesions were graded clinically for one month period. The levels of 20-kDa PS Abs in serum and aqueous humor in both groups were determined by ELISA. The distribution of certain extracellular matrix macromolecules, during corneal healing was analysed immunohistochemically.

Results The levels of specific anti-20-kDa PS Abs in serum, and aqueous humor obtained following either AI or PI were significantly higher as compared to those obtained from non-immunized control groups ($p<0.001$). Clinical grading showed that both AI and PI rabbits had a significantly less corneal damage as compared to the non-treated rabbits. In the immunohistochemical analyses for proteoglycans (PGs), accumulation of keratan sulfate PGs, heparan sulfate PGs and decorin was observed in the corneal stroma of the infected rabbits. This phenomenon was significantly reduced or disappeared in immunized animals in accordance to the decreased corneal damage macroscopically observed in these animals.

Conclusion The results of this study showed that either AI or PI immunization could protect against corneal damage and suggest a key role for 20-kDa PS and its Abs as prophylactic and therepeutic agent in slime-producing S. epidermidis keratitis.

323

Study of metastatic cancer cell lines survival in corneal organ culture conditions

DEB N (1), HERRAG S (1), MANISSOLLE C (1), GRESTA P (1), CAMPOS L (1), PEOCH M (2), GAIN P (1), THURET G (1)
(1) EA3063 Lab 'Cell survival and adherence', Faculty of Medicine, Saint-Etienne
(2) Pathology dpt, University Hospital, Saint-Etienne

Purpose The transmission of cancer via corneal graft has been debated though long term retrospective studies have shown no evidence to that effect. To investigate the theoretical possibility of such a transmission, we studied the survival of 3 metastatic cancer cell lines under corneal organ culture (OC) conditions

Methods Cutaneous melanoma (HTB72), epidermoid lung carcinoma (HTB 54) and breast adenocarcinoma (CAL51) were classically cultured in their respective media and in corneal OC medium with 2% foetal calf serum at 31°C in sealed flask. Cell proliferation and viability were evaluated by vital staining, colorimetric assay (MTT and neutral red) and quantification of protein synthesis. Endothelia of scientific human corneas were seeded with 104, 5.104, and 106 cancer cells, incubated for 6 hours to allow adherence and then organ-cultured for 2 weeks. Pathological, immunohistochemistry (IHC) with specific antibodies and RT-PCR with cancer cell gene-matched primers were done to detect cellular adherence

Results Despite a slower proliferation as compared to the reference media, cancer cells remained viable in OC. IHC revealed cellular adherence, especially on the peripheral endothelium and the trabeculum. RT-PCR showed overtranscription of the mRNA studied but controls also expressed low level of these markers

Conclusion In our experimental conditions using a high number of cancer cells, cells were viable in stringent OC conditions and capable of adhering to the peripheral endothelium. We intend to lower the inoculum to a 'clinically relevant' amount, use more specific markers and study more metastatic cell lines. Whether adherent cells are capable of subsequent proliferation in recipient eyes needs further studies

324

Application of Multivariate Analysis on High-Resolution Magic Angle Spinning (HR-MAS) 1H NMR Spectra of Rabbit Cornea.

TESSEM MB (1), BATHEN TF (2), CEJKOVA J (3), MIDELFART A (1)
(1) Norwegian University of Science and Technology (NTNU), Trondheim
(2) Cancer Clinic, St. Olav University Hospital, Trondheim
(3) Institute of Experimental Medicine, Academy of Sciences of Czech Republic, Prague

Purpose The present study is concerned with the application of multivariate statistical methods for extraction of metabolic information from spectra of High-Resolution Magic Angle Spinning (HR-MAS) 1H NMR spectroscopy. The purpose of the study is to investigate metabolic changes in rabbit corneas after exposure to either UV-A or UV-B radiation.

Methods Adult albino rabbits (2.5-3.0 kg) were exposed to UV-radiation (UV-A; 0.589 J/cm2 or UV-B; 1.667 J/cm2) for 8 minutes, once daily in 5 days. HR-MAS 1H-NMR spectroscopy was performed on removed corneas using a BRUKER Avance DRX600 spectrometer (14.1 tesla, Bruker BioSpin GmbH, Germany) operating at 600 MHz for protons. The NMR spectra were statistically analysed by Principal Component Analysis (PCA) and Soft Independent Modelling of Class Analogy (SIMCA).

Results The multivariate analysis of the spectra revealed significant metabolic changes of the rabbit cornea in eyes exposed to UV-B radiation ($p<0.05$). The UV-B irradiated samples have relative higher concentrations of β-glucose, betaine, glycine, pyruvate, acetate and valine, and relatively lower concentrations of ascorbate, myo-inositol, taurine, hypo-taurine and choline. No significant difference was found between the UV-A exposed corneas and the normal corneas.

Conclusion In the present study, multivariate analysis was an efficient tool to analyse complex metabolic information from HR-MAS 1H-NMR spectra. The observed metabolic alterations detected in UV-B irradiated corneas compared to normal corneas increase the knowledge of corneal protection against UV radiation which might be important in the process of UV-induced development of cataract.

EVER-2004-abstractbook.indd 67 8/19/04 12:26:12 PM

■ 325

Ocular manifestations in nephropathy cystinosis: a long-term study in children treated with cysteamine

PINELLO L (1), MONTINI G (2), CERMAKOVA I (1), ZACCHELLO G (2)
(1) Paediatric Ophthalmology Unit, Dept of Paediatrics, Padua
(2) Paediatric Nephrology and Transplant Unit, Dept of Paediatrics, Padua

Purpose Cystinosis is a rare autosomal recessive metabolic disorder leading to a storage of cystine crystals in the cells of many tissues, but mainly in the kidney and the eye. Crystal deposits in the cornea and conjunctiva and peripheral retinopathy are the most common eye complications. Renal transplantation and oral cysteamine have improved the general prognosis.This study describes the ocular follow-up in 7 kidney transplanted patients with infantile cystinosis,confirmed by molecular analysis,treated with oral and topical cysteamine.

Methods 7 patients (5 males and 2 females) were examined and long-term followed-up between 1987 and 2004. Ocular evaluation was performed each year: measurement of visual acuity, degree of photophobia, slit lamp examination and fundus ophthalmoscopy.

Results 7 patients received oral and topical eye drops cysteamine.The mean age at last visit was 13 years(range 2-35).The follow-up of topical treatment ranged from 1 to 12 years.Photophobia began by 2 or 3 years of age.Peripheral corneal epithelial infiltration appeared in the first year of age and evolved towards the depth and center of the cornea by 3 years.None of them presented retinopathy.Visual acuity was normal in 5 patients;1 patient was unable to cooperate for age and another presented a reduced acuity for high astigmatism.Spectral filters for photophobia were prescribed in2 cases.

Conclusion The effectiveness of topical cysteamine depends on the concentration and the number of instillations: a concentration of 0,5% 4-6 times a day is recommended. In our study cysteamine eye drops were effective in reducing photophobia, not in removing corneal crystals.Moderate compliance and safety were reported in all our patients.

■ 326

Sub-conjunctival haemorrhage during subtenon injection: reduced rates with localised conjunctival cautery

GALIBA V (1, 2), SALEH G (3), DEWIT D (3), CHUNG A (2)
(1) Sussex Eye Hospital, Brighton
(2) Department of Ophthalmology, Leeds
(3) Department of Ophthalmology, Colchester

Purpose To evaluate the effect of localised conjunctival cautery on the rate and extent of sub-conjunctival haemorrhage (SCH) associated with sub-tenon anaesthetic (STA) injection in patients with various clotting states.

Methods 144 patients undergoing blunt posterior STA injection by a single surgeon were prospectively divided into three groups. Group A (n=36) were on warfarin (INR 1.8-4.2), group B (n=48) on aspirin (75mg), group C (n=12) on clopidogrel (75mg) and group D (n=48) on no anti-coagulant or anti-platlet agents. All patients had no other known coagulopathy. Each group was divided into two equal age- and sex-matched subgroups, one of which received conjunctival cautery whilst the other served as a control. The localised bipolar cautery was administered under direct microscope control to the conjunctival entry site of the STA injection prior to tissue dissection. The frequency of SCH and quadrants of the conjunctival surface involved were objectively recorded.

Results Localised conjunctival cautery reduced the SCH rates from 67% (75%>2 quadrants) to 6% (100%<2 quadrants) in group A, from 37.5% (67%>2 quadrants) to 4% (100%<2 quadrants) in group B, from 50% (67%>2 quadrants) to 0% in group C and from 17% (100%<2 quadrants) to 0% in group D. The incidence and extent of chemosis not associated with haemorrhage remained subjectively unchanged in all the sub-groups as did the extent of anaesthesia and akinesia. The counjunctival wound appeared fully healed in all cases two weeks post-operatively.

Conclusion Localised conjunctival cautery prior to STA injection may considerably reduce the frequency and extent of SCH especially in patients on anti-coagulant or anti-platelet agents.

■ 327

A refined measure of the economic and quality life impact of seasonal allergic conjunctivitis in Spain

SMITH AF (1, 2)
(1) Health Economics Unit, Alcon Laboratories (UK) Ltd, Hemel Hempstead, UK
(2) Nuffield Laboratory of Ophthalmology, Oxford, England

Purpose The aim of this study was to examine quality of life (QoL) and economic consequences of SAC amongst private health care patients in Spain.

Methods 201 sufferers of SAC and 200 controls were recruited from four private eye clinics and one public hospital in five Spanish cities. Participants were between 10 and 80 years of age and Spanish speaking. Sufferers were administered a set of four questionnaires by researchers consisting of the EQ-5D, NEI VFQ-25, RQLQ and a Health Economic and Demographic Questionnaire. Control participants self-administered the full EQ-5D and VFQ-25 and abbreviated versions of the RQLQ and HEDQ.

Results Sufferers returned significantly lower quality of life scores than Controls in all EQ-5D domains other than mobility (p=0.14). SAC VFQ-25 scores were significantly less than Controls in the overall vision (p<0.01), distance vision (p<0.01), ocular pain (p<0.01), mental health (p=0.01), role limitations (p<0.01), and dependency (p=0.01) domains. Mean scores for the activity domain of the RQLQ were greater in the sufferer group than the control group (P<0.01) . The total mean per-sufferer cost of SAC amongst our sample of private patients was 348.50 Euros.

Conclusion Sufferers experienced QoL reductions in general health and specific aspects of vision as a result of their SAC. In relative terms, the per-capita economic cost of the condition was higher than a previous public health care study. This was ascribed to sufferers' willingness-to-pay for symptom alleviation. The unexpectedly high expenditure of the proportion of SAC sufferers who receive private health care serves to highlight the importance of SAC as a costly condition.

■ 328

Photokeratitis secondary to exposure to UV light from fish tank water purification systems

DWARIKA D (1), BHOLA RM (2)
(1) Birmingham and Midland Eye Centre, Birmingham
(2) The Royal Hallamshire Hospital, Sheffield

Purpose To present a case series of photokeratitis secondary to exposure to UV light emitted by lamps used in water purification systems for fish tanks.

Methods All patients were seen by a single observer during casualty sessions at The Birmingham and Midland Eye Centre between July and December 2002.

Results Four cases were identified with an age range of 30 to 55 years. A common feature in each patient's history was the recent manipulation of UV lamps used in water purification systems for fish tanks. Each presented with photophobia, epiphora, and foreign body sensation bilaterally. On examination all patients had bilateral punctate keratitis.

Conclusion Although UV light has been reported to cause photokeratitis, cases due to UV light from fish tank water purification systems have not been previously reported. We advocate more explicit warning in the literature accompanying the devices and a heightened awareness of the condition by first line healthcare professionals.

EVER-2004-abstractbook.indd 68 8/19/04 12:26:13 PM

■ 329

Evaluation of Corneal Curvature and Thickness in Posterior Microphthalmos

NOWILATY SR (1), AL-JISHI Z (2), AL-HAMAD A (3)
(1) Vitreoretinal Division, King Khaled Eye Specialist Hospital, Riyadh
(2) Anterior Segment Division, King Khaled Eye Specialist Hospital, Riyadh
(3) Diagnostic Imaging, King Khaled Eye Specialist Hospital, Riyadh

Purpose To assess the type and the consistency of changes in both corneal curvature and thickness in posterior microphthalmos, a rare condition in which the posterior segment is disproportionately small compared to an anterior segment of normal size.

Methods Nine patients aged 7 to 45 years from four sib-ships presented with typical bilateral posterior microphthalmos. The eyes underwent a prospective detailed examination, ocular standardized A-scan echography, corneal topography and pacchymetry.

Results All 18 eyes had a normal external appearance and marked hyperopia ranging from +8.50 to +16.50 (average +13.00). The short axial lengths (15.3 to 19.8 mm, average 16.65 mm) were due to short vitreous compartments (8.3 to 12.4 mm.). Funduscopy revealed the typical papillomacular fold or radiating macular striae. All eyes had normal-appearing anterior segments. Corneal diameters (11.1 to 12.1 mm), central anterior chamber depth (3.0 to 3.5 mm) and lens thickness (3.9 to 4.5 mm) fell within normal dimensions when correlated for age. Increased corneal curvature, however was a consistent finding in all eyes. K-readings ranged between 46 and 52 diopters (average 49D) and increased with decreasing axial length of the globe. Although increased scleral and retinochoroidal thickness was a constant finding in all cases, corneal thickness was normal (500 to 560 microns) in 14 eyes, and slightly increased to 610 microns in four eyes of two patients.

Conclusion Increased corneal curvature is a constant finding in posterior microphthalmos and appears inversely proportional to the degree of ocular shortening. Corneal thickness, on the other hand, is frequently normal. Increased corneal curvature appears as an "emmetropizing" compensation for the short globe.

■ 330

The Development Of A Disposable Ophthalmic Barrier System To Prevent Cross-Infection From Contact Ophthalmic Devices - An Update

FRANKLIN VJ (1, 2), HENLEY C (1, 2), TIGHE B (1, 2), KERR J (3), GEE H (4), FLANAGAN J (5)
(1) Biomaterials Research Unit, CEAC
(2) Aston University, Birmingham
(3) Senior Optometrist Mayday, University Hospital Croydon, Croydon
(4) First Water Ramsbury Ltd, Wiltshire
(5) School of Optometry, University of Waterloo, Waterloo

Purpose It is generally accepted there is a potential risk of cross-infection from contact ophthalmic devices. Examples of potential cross-infection include Herpes Simplex, variant CJD, and HIV. The current methods used to prevent this cross-infection are either inefficient or not cost effective and have limited applications e.g. tonometer heads and silicone sheaths. Most commonly the contact areas of these ophthalmic devices are sterilised by wiping with an alcoholic swab, but this is inadequate and ineffective. The solution to this is to design and develop a sterile, cost effective, universal, barrier system.

Methods In order for the barrier system to be successful it must have the following properties: disposable, reversible adhesive layer, optically transparent, < 0.1g to avoid recalibration of tonometer, non permeable barrier film, and compatible barrier film with the tear film. Each of these aspects has been studied and the properties of candidate materials evaluated.

Results A thin optically clear polyurethane (with high elongation; >250% at break) has been identified together with a water-based ionic hydrogel adhesive. Coating procedures and a preliminary design have been developed and will be presented.

Conclusion A four-layer barrier system prototype has been developed and is undergoing clinical trials. This four-layer barrier system consists of a polyurethane barrier film, which is coated with an adhesive hydrogel. Protective liners maintain the adhesive layer and barrier film sterility until the device is used.

■ 331

Biglycan affects adhesion of keratocytes

KOULIKOVSKA M, PODSKOCHY A, FAGERHOLM P
Linköping University, Linköping

Purpose During corneal repair keratocytes migrate and repopulate damaged cell-free stroma. At the same time, expression of biglycan is elevated in response to corneal damage. Biglycan was earlier proposed as inhibitor of adhesion for several cell types, for example skin fibroblasts. Aim of this work is to study effect of biglycan on keratocytes adhesion.

Methods For determination of cell adhesion keratocytes were isolated from bovine cornea and cultured with or without serum. Quantitative determination of adhesion was performed by using 96-well CytoMatrix Cell Adhesion Strips coated with fibronectin, vitronectin, laminin, collagen I, collagen IV or bovine serum albumin (BSA). Keratocytes were seeded on the coated substrates with or without biglycan (5-25 µg/ml) for 1 hour. Adherent cells were fixed and stained, and the relative attachment was calculated from the absorbance at 530 nm. The percentage of non-adherent keratocytes cultured in the absence of biglycan was taken as baseline value.

Results The presence of biglycan in concentrations of 5-25 µg/ml led to a dose-dependent reduction in keratocyte adhesion, when keratocytes were cultured under serum-free conditions and plated on wells coated with type I collagen or fibronectin. However, the reduction was not dose-dependent when cells cultured in the presence of serum were used. Concerning to other adhesion molecules used in experiment, no significant changes in adhesion ability were observed.

Conclusion We conclude that biglycan has antiadhesive effect in keratocytes. Moreover, this effect is dose-dependent unless cells were cultured with serum. By our opinion, this can be due to expression of endogenous biglycan by keratocytes subjected to serum.

■ 332

Rat Contact Lens Model: Early Analysis of Pseudomonas aeruginosa Corneal Infection

SZLITER EA (1), BARRETT RP (1), GABRIEL MM (2), HAZLETT LD (3)
(1) Anatomy & Cell Biology, Wayne State University School of Medicine, Detroit
(2) CIBA-Vision Corporation, Duluth
(3) Anatomy & Cell Biology, Wayne State University School of Medicine, Detroit

Purpose The purpose of this study was to examine the early host response to P. aeruginosa infection using a newly developed rat model of extended contact lens (CL) wear.

Methods Lewis rats were fitted with a soft CL (CIBA Vision, Duluth, GA) in the left eye, while the right eye served as control. Infection was induced in the experimental eye by placement of a bacterial-soaked CL and then topical bacterial delivery. Upon first detection of corneal opacity, slit-lamp, histopathology, viable bacterial plate counts, ELISA, myeloperoxidase (MPO), Langerhans cell quantitation and multiprobe ribonuclease protection asays (RPA) were implemented.

Results Analysis of bacterial-induced keratitis in CL-wearing rats revealed an early, vigorous contribution by the host inflammatory response, albeit in the absence of detectable bacteria in the cornea. This was evidenced by the proliferation and migration of Langerhans cells and infiltration of PMN into the cornea with resultant corneal opacity. RPA and ELISA analyses also showed an upregulation of pro-inflammatory cytokines including IL-1 beta and IL-6 after disease onset, further suggesting that in CL wear, the host inflammatory response has a major contribution to early corneal pathology.

Conclusion The rat model allows early analysis of the effects of CL usage after induction of corneal bacterial keratitis without trauma, usually needed for all other rodent models. The lens wearing rat model should prove valuable for delineation of the effects of CL wear in infectious and other CL-related complications and diseases.

EVER-2004-abstractbook.indd 69 8/19/04 12:26:14 PM

■ 333

Topographical Changes in Anterior Corneal Curvature After LASIK

GONZALEZ-MEIJOME JM (1), DIAZ-REY A (1), SAÑUDO F (2), QUEIRÓS A (1), ALMEIDA JB (1), PARAFITA MA (3)
(1) Department of Physics (Optometry), University of Minho, Braga
(2) Department of Optics. University of Valencia., Valencia
(3) Department of Surgery (Ophthalmology), University of Santiago de Compostela, Santiago de Compostela

Purpose Changes in corneal surface after refractive surgery affect several aspects of visual function as well as the ability of this surface to sustain a contact lens when needed. The aim of this study was to know how much the cornea changes its radii from center to periphery within the ablation zone after LASIK correction of myopia and astigmatism

Methods Central and peripheral curvature at the 4 and 6 mm chord of the corneal surface were measured with a videokeratoscope before and at different times after LASIK surgery. Eight corneal semi-meridians were were evaluated in each mid-peripheral area, resulting in seventeen locations being measured

Results Pre-surgical spherical equivalent ranged from -0.50 to -8.5 diopters of myopia. Mean central curvature flattened by 3.5 diopters on average. There was a good correlation between the initial spherical equivalent refraction and change in curvature at the central location (r2=0.883; p<0.001); 4 mm chord (r2=0.914; p<0.001) and 6 mm chord (r2=0.761; p<0.001). There was also a good correlation between pre-surgical spherical equivalent and change in corneal eccentricity (r2=0.720; p<0.001)

Conclusion Cornea becomes oblate after myopic and astigmatic correction with LASIK. Central refractive corneal changes represent about 70% of the net change in refraction for the central area, being 60% when we consider the 4 mm mid-peripheral area and about 40% when we consider the 3 mm chord area.

■ 334

A case of the incidental trauma lasik flap

SCORCIA V, ROTONDO E, PICCIRILLO V, BRUZZICHESSI D, CARNOVALE-SCALZO G, SCORCIA G
Eye Clinic - University "Magna Graecia", Catanzaro

Purpose to report a traumatic flap injury at 3 years after laser in situ keratomileusis (LASIK).

Methods Case report: we describe the inflammation reaction determing corneal aberration in a 36 year old male after incidental ocular trauma.

Results Results The cornea was examined with slitlamp microscopy and computed corneal topography. Visual discomfort was evaluated by best correct visual acuity (BCVA) and contrast sensivity by ETDRS tables.

Conclusion The main advantage of LASIK is related to maintaining the central corneal epithelium flap created by the microkeratome. The flap is primarily held in position by its inherent shape, like a piece of a puzzle. The flap is also held in place by the normal physiologic activity of the cornea, by mucopolysaccarides (a gluey substance secreted by the corneal cells), and by the overlying corneal epithelial cells.It is well estabilished that the flap may slip out of position in the immediate post-operative period. The reported case indicate that microtrauma (by eye rubbing, or incidental injury) may also result in flap iniury also in the long after the surgical procedure. The patient should be well informed about this risk and about trauma-related complications.

■ 335

Second Generation Wavelets for Characterisation of Corneal Topography Height Data

LANGENBUCHER A, PRAUSE A, SEITZ B
Department of Ophthalmology, Erlangen

Purpose To demonstrate a mathematical method for multiscalar decomposition of corneal topography height data into a space-scale space using wavelet analysis techniques, and to detect surface irregularities or scars.

Methods We used the Lifting Scheme as one of the second generation wavelets to detect and to localise surface irregularities and to cluster for frequencies in the spatial domain, which is essential for the mentioned detection of high-frequency components at a particular location. The multiscalar basis components were separated and recovered from the wavelet soft thresholding techniques. Peaks and pits within the three-dimensional corneal surface topography were detected and localised using the wavelet hard thresholding techniques.

Results A number of modules were implemented in C++. Classes were written for the extraction of raw data from the output of the TMS-1 videokeratoscope as well as for the data structure of three-dimensional corneal surface and wavelet analysis including interpolation and the Lifting scheme. The implementation is object-oriented and modules from the Standard C++ Library and the Standard Template Library have been used. The methodology was applied to a set of clinical examples to evaluate the proper benchmarks for thresholdingto and to check for the validity of the decomposition.

Conclusion In our model, the absolute values of wavelet coefficients were used to detect irregularities. They inherit more information than coefficients derived with standard Fourier analysis techniques. Due to the amount of available data, training of classifactors and the automatic detection of diseases affecting the corneal surface may be possible. Examples of tools for classification are Support Vector Machines and Neural Networks.

■ 336

Wavefront analysis of spherical and spherical astigmatic hyperopia with the MEL 80 excimer laser

NAGY Z Z, SZABÓ V, SÜVEGES I
1st Department of Ophthalmology, Budapest

Purpose To investigate the effectivity, predictability, safety and changes in higher order aberrations following photorefractive keratectomy (PRK) in eyes with hyperopic/hyperopic astigmatic refractive error.

Methods In 64 eyes PRK treatement was performed. Treatment groups were: Group 1: +1.0 D to +3.5 D (SE); Group 2: +3.75 D to +7.5 D (SE). Before and after treatment an aberrometry was performed with a Shack-Hartmann device (Wavefront Sciences, Albuquerque, AZ, USA). Refractive treatments were carried out by the Zeiss Meditec MEL 80 (Zeiss Meditec AG, Jena, Germany) excimer laser (0.7 mm beam diameter; 250 Hz). Follow up is 6 months.

Results In Group 1, the preoperative +2.88 +/- 0.8 D(SE) decreased to +0.1 +/- 0.08 D (SE); in Group 2, the preoperative +4.88 +/- 1.4 D (SE) decreased to +0.88 +/- 0.1 D (SE). In Group 1, 100% of the eyes were within +/-1.0 D of attempted correction, while in Group 2, 72% were within +/-1.0 D. In Group 1, 95% of the eyes had the same best-spectacle corrected visual acuity (BSCVA) as preoperatively, 4% gained 1 line and 1% lost 1 line. In Group 2, 42% had the same postoperative BSCVA, while 21% lost 1 line; 12% lost 2 lines and 25% gained 1 line. Higher order aberrations increased in Group 1, from -0.1 to +0.12; while in Group 2, from -0.12 to +1.4.

Conclusion In low hyperopes a good prolaticity was reached with good uncorrected visual acuity (UCVA) and good BSCVA. In high hyperopes high prolaticity did not help acheiving better UCVA and BSCVA.

EVER-2004-abstractbook.indd 70 8/19/04 12:26:14 PM

■ 337

Rotary scanning system for elevation topography and pachymetry

FRANCO S (1), ALMEIDA JB (1), PARAFITA M (2)
(1) Physics Department, University of Minho, Braga
(2) Department of Surgery, University of Santiago de Compostela, Santiago de Compostela

Purpose Most corneal topographers in use perform curvature measurements and derive elevation maps from error prone numerical integrations. This system uses a technique similar to slit scan, providing true elevation and thickness information, but differs from the few existing equipments based on such technique on two key aspects: a novel illuminating system which replaces the slit with a cylindrical lens and rotary scan, resulting in high resolution in the corneal apex region.

Methods Corneal thickness and topography are computed from optical sections obtained by illumination with a collimated beam expanded in a fan by a small cylindrical lens. Compared to more usual slit lamp type optical sections, the cylindrical lens allows the construction of very light and compact illuminating systems and can be rotated continuously at very high speeds. The system has no other rotating parts besides the cylindrical lens and uses two stationary video cameras whose images are combined as if there was one virtual rotary camera synchronised with the cylindrical lens.

Results After appropriate processing of the cameras images it is possible to produce true elevation maps of both corneal surfaces as well as the cornea's thickness map; the latter is derived directly from the distance between the two surfaces. In the presentation we show some of these maps.

Conclusion The system is still under development, mainly for replacement of the cameras by new ones with better resolution and speed and for software optimization allowing faster processing. In spite of the present limitations, this new optical system allows thickness measurements on the entire cornea, simultaneously producing 3-D elevation topography maps of both corneal surfaces.

■ 338

Relationship between central corneal pachymetry and other ocular and general parameters in normal population

HERNANDEZ VJL (1, 2), ROMAN JM (1), MARTÍN B (1), SáNCHEZ JM (3), TEUS MA (1, 4)
(1) VISSUM Hospital Oftalmológico, Madrid
(2) Universidad Complutense, Madrid
(3) VISSUM Hospital Oftalmólogico, Madrid
(4) Universidad de Alcalá, Madrid

Purpose To analyze the relationship between central corneal pachymetry and age, refractive status and axial length.

Methods This is a prospective study. The inclusion criteria were patients with healthy eyes, no previous surgery and ages between 15 and 76. The tests performed were complete visual analysis and central ultrasonic pachymetry (with A-Scan DGH5100). The statistical analysis was done using the non paired t – Student test and ANOVA.

Results We included 340 eyes of 340 patients. The obtained (a) mean corneal pachymetry value of 548,2 + 30 microns (range 464 to 633). Results were analyzed by decades and quartiles.We did not find a statistical correlation between central corneal pachymetry and aged, sex, refractive error or axial length.

Conclusion Corneal pachymetry seems to be an individual value for each subject with no relationship with the parameters included in this study.

■ 339

Photodisruption Characteristics of Femtosecond Laser Effects in Corneal Tissue

VOSSMERBAEUMER U, JONAS JB

Purpose Femtosecond laser pulses can induce circumscript photodisruption within translucent material which can be used for microsurgical procedures. This applies however only within energy limits that depend from both the intrinsic qualities of the laser tool and from the physical characteristics of the absorbing tissue. We investigate the respective energy corridors and propose arithmetic approximations of suitable effect patterns and thresholds in corneal tissue.

Methods 25 enucleated porcine eyes as well as 20 human corneal specimen were used in laser procedures (FEMTEC, 20/10 perfect vision) for robotic trephination, endothelial die preparation and LASIK-flaps. After fixation and staining, slides were histologically analyzed and practical correlation between programmed procedure and visible effects evaluated.

Results At a given fixed pulse duration of under 500 fs, near infrared laser effects led to comparable photodisruptive effects at 2,2 to 15mJ. Targeting of 5µm focus spots could be varied at distances between 4 and 7 µm. Linear contingency in diagonal or sagittal direction required spacing of 4 to 8µm. Cavitation bubble equivalents were of variable confluence and showed partial sealing phenomenon supposedly from compressed stromal debris.

Conclusion Unlike with conventional cutting tools such as blades, femtosecond laser devices are dependent upon a broad spectrum of parameters for reproducible and accurate slicing effects. Among these are, at a given wavelength and pulse duration, the spatiotemporal spacing of the shot pattern (x/y/z distribution, orientation and focus size). Relevant tissue-intrinsic influencing factors are hydration state and structural homogeneity. Observed variation corridors are supposed to be partly due to differential elasticities within the different corneal layers.

■ 340 / 3436

Risk Factors for Laser In Situ Keratomileusis (LASIK)

BEHNDIG AB, JONSSON M
Department of Clinical Science/Ophthalmology, Ummeå University, Umeå

Purpose To see if deviations in the localization of the cornea's thinnest point, or the magnitude and localization of a posterior corneal ectasia, is associated with deviations in the spherical equivalent, the astigmatism or the magnitude of an anterior corneal ectasia. To see if "risk corneas" for iatrogenic keratectasia can be identified without a pachymetry map of the cornea.

Methods 308 eyes of 156 healthy volunteers with various refractive errors were examined with Orbscan II and autorefractometer-keratometer. The corneal thickness was registered at the fixation point, at the geometrical center and at the thinnest point of the cornea. Keratometry and refraction were determined for all subjects.

Results The thinnest point of the cornea was predominantly located in the inferotemporal quadrant, and was significantly thinner than the fixation point (539.6 ± 35.8µm and 548.0 ± 35.4µm, respectively, $P < 0.001$). Interestingly, the larger this difference was, the longer the distance between these points. No relationship was found between the refractive or "external surface" measurements and the "internal surface" measurements.

Conclusion The absence of a clear relationship between the shape of the anterior corneal surface or the refractive error, and the shape of the posterior corneal surface, necessitates a thorough pachymetric evaluation of the cornea before every LASIK procedure, with special attention to the inferotemporal area.

EVER-2004-abstractbook.indd 71 8/19/04 12:26:15 PM

■ 341

Adenovirus-mediated gene transfer of viral interleukin-10 (vIL-10) prolongs survival of corneal allografts and moderates rejection process

GONG N (1), YANG J (2), DANNOWSKI H (1), SCHMIDT N (1), VOGT K (2), VOLK HD (2), PLEYER U (1), RITTER T (2)
(1) Department of Ophthalmology , Charité, Berlin
(2) Institute of Medical Immunology, Charité, Berlin

Purpose IL-10 can modulate a variety of important immunoregulatory effects including expression of Th-1 cytokines and monokines and downregulating antigen presentation via APCs. It also may induce antigen-specific regulatory T cells in certain peripheral immune microenvironments. Viral IL-10 (vIL-10) not only shares these effects but also lacks T cell stimulatory activities of IL-10. In this study we explored the immunomodulatory effects of adenovirus-mediated gene transfer of vIL-10 in experimental keratoplasty.

Methods Wistar-Furth (W/F) rats were used as donors for corneal grafts and Lewis rats were used as recipients. In the control group (n=9) there was no treatment. In the systemic AdvIL-10 group (n=5) Lewis rats were treated with AdvIL-10 (Ad5, E1/E3 deleted, 1*109 pfu/animal) intraperitoneally one day prior to transplantation. An Adβ-Gal construct served as control vector in the systemic control group (n=6). The graft rejection was diagnosed when corneal opacity increased to grade 3 or 4. The graft survival was analyzed using Kaplan-Meier survival method.

Results Systemic administration of AdvIL-10 significantly prolonged the survival of corneal allografts. Mean survival was 17.4±3.1 days ($P<0.01$, compared with 9.7±0.7 days in systemic control group and 10.4±0.9 days in control group). The rejection speed was lowest in systemic AdvIL-10 group.

Conclusion Our data indicate that systemic application by treating the transplant recipient with AdvIL-10 results in a significantly prolonged survival time for corneal allografts. In addition, the application of AdvIL-10 moderated the rejection processing too.
Supported in part by DFG (Pl 150/14-1)

■ 342

Production of nitric oxide during the corneal rat-to-mouse xenograft rejection and the effect of anti-CD4 or anti-CD8 treatment

VITOVA A (1), PINDJAKOVA J (1), KRULOVA M (1), ZAJICOVA A (1), FILIPEC M (2), HOLAN V (1)
(1) Institute of Molecular Genetics, Academy of Sciences, Prague
(2) Department of Ophthalmology, Charles University, Prague

Purpose To determine whether nitric oxide (NO) participates in rat-to-mouse corneal xenograft rejection.

Methods Xenogeneic (Lewis rat to BALB/c mouse) and syngeneic (BALB/c mouse to BALB/c mouse) orthotopic corneal transplantation were performed. Xenograft recipients were treated with monoclonal antibody (mAb) anti-CD4 or anti-CD8. Expression of gene for inducible nitric oxide synthase (iNOS) was determined by RT-PCR, the presence of iNOS protein in corneal frozen sections was detected by imunofluorescence staining and the production of NO by cultivated graft explants was measured by the Griess reaction.

Results Treatment of recipients with mAb anti-CD4, but not anti-CD8, significantly prolonged corneal xenograft survival. Expression of gene for iNOS, occurence of iNOS protein positive cells and NO production were present in rejected corneal xenorafts removed from either untreated recipients or those treated with mAb anti-CD4 or anti-CD8. There was neither expression of gene for iNOS nor presence of cells containing iNOS protein in syngeneic grafts and nonrejected xenografts removed on the 8th day after grafting from anti-CD4 treated recipients.

Conclusion Corneal xenograft rejection is associated with a significantly increased production of NO in untreated recipients or those treated with mAb anti-CD4 or anti-CD8. Our results suggest that NO could play an important role during corneal xenograft rejection.

■ 343

Assessment of the human corneal endothelium. In vivo noncontact specular microscope topcon SP2000 versus ex vivo sambacornea analyser

THURET G (1, 2), MANISSOLLE C (1), GAVET Y (1, 3), CAMPOS-GUYOTAT L (1), GAIN P (1, 2)
(1) EA3063 Lab 'Cell survival and adherence', Faculty of Medicine, Saint-Etienne
(2) Ophthalmology dpt, University hospital, Saint-Etienne, FRANCE
(3) Ecole Nationale Supérieure des Mines de Saint-Etienne, Saint-Etienne, FRANCE

Purpose The endothelial follow-up after corneal graft requires comparison between the donor assessment done in eye banks and specular microscopy of the recipient. Aim of this study: to determine the agreement between endothelial cell density (ECD) and morphometry determined by the non contact small field specular microscope (Topcon SP2000) and by our wide field multi-image analyser Sambacornea (Sambatechnologies)

Methods 51 patients (keratoconus 52%, lattice dystrophy 27%, other 21%) with somehow paracentral clear stroma, had a specular non contact microscopy immediately before graft. The cornea retrieved during surgery was immediately stained with alizarin red and assessed by sambacornea which accuracy was guaranteed by the count of the calibrated endothelial standards (see poster of Gavet et al. EVER 2004). For each count, ECD and morphometry (CV of cell area, percentage of hexagonal ECs) was assessed independently on as much cells as possible. Agreement was determined using the Bland Altman method

Results specular counts under estimated the ECD by 11%, 95%CI[6-15] independently of the ECD itself. In the sub group (n=35) of specular counts performed on 75 cells or more ('the minimum standard' for specular reliability) this under evaluation was of 6%, 95%CI [1-11]. Morphometric parameters did never differ

Conclusion New accurate ex vivo endothelial analysers, like ours, in which calibration can easily be verified, could question the calibration of specular microscope. The slight but constant under evaluation of ECD in the recipient can also help explain in part the dramatic EC loss observed in the very early post operative period

■ 344

Endothelial cell count and morphometry by the tri image analyser sambacornee: multicentric validation

GAIN P (1), GAVET Y (1, 2), MANISSOLLE C (1), HERRAG S (1), DEB N (1), MEULLE A (3), ACQUART S (4), GARRAUD O (4), EGELHOFFER H (5), THURET G (1)
(1) EA3063 Lab 'Cell survival and adherence', Faculty of Medicine, Saint-Etienne
(2) Ecole Nationale Supérieure des Mines de Saint-Etienne, Saint-Etienne, FRANCE
(3) Institut Supérieur des Technologies Avancées de Saint-Etienne, Saint-Etienne
(4) French Blood Center Loire/Auvergne, Eye Bank, Saint-Etienne
(5) French Blood Center Isère/Savoie, Eye Bank, Grenoble

Purpose To validate Sambacornee™ software (Sambatechnologie, Meylan, France) for the endothelial cell density (ECD) and morphometry measurement, and to determine the better counting strategy

Methods 8 technicians determined the ECD of 30 corneas from a set of recorded images. Six counting strategies were used: in the 'guide' (G) method, the areas of counting were preselected, whereas in the 'free' one (F), the technician chose them himself. Within the G and F methods: an automated mode (A) with a fully computerized cell recognition, a touch up mode (T) where the technicians corrected poorly drawn cells, and a 'centre' mode (C) where he picked up cell centres. ECD, CV of cell surface and hexagonality, were compared according to the 6 strategies (GA, GT, GC, FA, FT, FC)

Results All the 6 methods were correlated. Nevertheless both automated methods gave unacceptable over estimation (up to +30%) ECDs. Both 'guide' methods were slightly overestimated (+5%) since the algorithm selected the best contrasted areas which had often the highest ECD. Concomitantly, the free selection of areas of interest with touch up of cells where necessary, was associated with the lowest intra technician variability. Both center methods gave results similar to touched up counts but were more time consuming and led to a non reliable morphometry since the algorithm minimized differences in cells area

Conclusion The free selection of the areas of count associated with all required corrections, appears as the more reliable method of ECD and morphometry determination. For poorly defined images, the determination of cell centre allows to obtain a reliable ECD without trusted morphometry

EVER-2004-abstractbook.indd 72 8/19/04 12:26:15 PM

■ 345

Fixed frame technique for endothelial cell count: inherent errors

GAIN P (1), GAVET Y (1, 2), MALASSAGNE F (3), CAMPOS L (1), ACQUART S (4), GARRAUD O (4), THURET G (1)
(1) EA3063 Lab 'Cell survival and adherence', Faculty of Medicine, Saint-Etienne
(2) Ecole Nationale Supérieure des Mines de Saint-Etienne, Saint-Etienne, FRANCE
(3) Samba technologies, Meylan, France
(4) French Blood Center Loire/Auvergne, Eye Bank, Saint-Etienne

Purpose The corneal endothelial cell density (ECD) can be determined with a fixed or a variable frame method. The former is typically that of the manual counts and is widespread in Europe. The latter can only be adapted to certain modern softwares. Aim: to show that the fixed frame method is associated to inherent errors that could be increased by its inappropriate use

Methods 1/a simulation of fixed frame counts was computerized. It calculated the ECD for 3000 random positions of a calibrated grid on a mosaic. It was repeated for homogeneous and heterogeneous ECD from 500 to 3600 cells/mm² and increasing area of the grid, from a 50x50 to a 300x300 µm grid. Each time a single count, a mean of 5 and of 10 counts were considered. 2/ we also compared ECDs obtained on endothelial pictures after naked eye observation through a calibrated grid ('French method' without picture printing) and after picking cells with a pencil on a transparent overlay ('European method')

Results 1/ the fixed frame technique was associated with an inherent variability all the more important than the grid was small and the ECD low. The best compromise between grid area and time required for manual count was a 125x125 or a 150x150µm grid. The mean of 10 measures dramatically reduced variability. The fixed frame technique tended to underestimate ECD≥2000 cells/mm². 2/ the 'French method' underestimated the ECD of 5 to 10 % compared to the counting method with cell picking on a picture

Conclusion This study calls for an abandonment of the manual count as done in France. At least should we recommend counting on a printing of the endothelial picture, with a grid of 125x125 µm, at best to upgrade for a computer aided method with a variable frame method

■ 346

Updating of the image analysis methods for specular microscopy: tri image endothelial analysis

GAVET Y (1, 2), THURET G (1), PINOLI JC (2), GAIN P (1)
(1) EA3063 Lab 'Cell survival and adherence', Faculty of Medicine, Saint-Etienne
(2) Ecole Nationale Supérieure des Mines de Saint-Etienne, Saint-Etienne

Purpose To develop a multi-image analyser for in vivo endothelial cell density (ECD) measurement and morphometry in non contact-specular microscopy, as we previously developed for images of light microscopy in eye banks

Methods We designed a cross-platform image analysis software (Linux, Windows) in C++, based on mathematical morphology operations. It used the graphical libraries Insight ToolKit and Visualisation ToolKit to manage and display images. The user interface was done with Fast Light ToolKit

Results Our software allowed to select one or more free areas in three different images of non contact-specular microscopy. The user interface was simple (cell borders touch up tools) to limit manipulation errors and make the learning easier. The results computed were presented as HTML pages easily manipulable, and included information on number of cells counted, ECD, coefficient of variation of cell area and percentage of hexagonal cells. These data could be exported to spreadsheet softwares

Conclusion This software improves existing old-generation commercial tools. It should contribute to raise the in vivo control level of corneal endothelium

■ 347

Pan-caspase inhibitor blocks staurosporine induced human corneal endothelial apoptosis

HERRAG S, MANISSOLLE C, CAMPOS-GUYOTAT L, GAIN P, THURET G
EA3063 Lab 'Cell survival and adherence', Faculty of Medicine, Saint-Etienne

Purpose The involvement of apoptosis in endothelial cell loss which lower the tissue quality during corneal organ culture has been demonstrated. In a previous work we established that staurosporine (STS) induces apoptosis of a human corneal endothelial cell (HCEC) line via caspase-3 activation. Our aim was to determine the efficiency of an irreversible cell permeable broad spectrum caspase inhibitor (Boc-D-fmk) on HCEC apoptosis inhibition

Methods HCECs were studied after 3, 6, 12, 18, and 24 hrs of incubation with 0.2 µM STS in the presence or absence of 50 µM Boc-D-fmk with a one hr pre-treatment with Boc only. Controls consisted of culture without drugs. Cell shedding was monitored by cell count. Cell lysates were subjected to fluorometric analysis using a microplate fluorometer to monitor proteolytic activity of caspases using 5 synthetic selective fluorogenic substrates: VDVAD-AFC (casp-2), DEVD-AMC (casp-3), VEID-AMC (casp-6), IETD-AFC (casp-8) and LEHD-AFC (casp-9). Cell viability was measured with a MTT reduction assay for mitochondrial activity in 96-well tissue culture plates

Results STS triggered the activation of the 5 caspases, picking at H12, as we described initially for casp-3. Activity of casp-2, -3, -9 were totally blocked by Boc-D-fmk. A 90% reduction of casp-6 and -8 activities was observed. A complete arrest of shedding was observed as long as the inhibitor was present. Moreover, HCECs treated with the caspase inhibitor displayed a viability similar to control cells

Conclusion 50 µM of Boc-D-fmk proved efficient to protect HCEC from in vitro staurosporine induced apoptosis. Further study will investigate its role in apoptosis inhibition during corneal storage in organ culture

■ 348

From manual to computerized count: how to decide for a new cut off value for cell density to qualify corneas for graft?

HERRAG S (1), GAVET Y (1, 2), THURET G (1), ACQUART S (3), CAMPOS-GUYOTAT L (1), GARRAUD O (3), GAIN P (1)
(1) EA3063 Lab 'Cell survival and adherence', Faculty of Medicine, Saint-Etienne
(2) Ecole Nationale Supérieure des Mines de Saint-Etienne, Saint-Etienne
(3) French Blood Center Loire/Auvergne, Eye Bank, Saint-Etienne

Purpose In our eye bank (330 corneas/year), up to dec 2001, the endothelial cell density (ECD) was determined manually through a reticle in the microscope eyepiece, as in most French eye banks. The cut off value to qualify a cornea for graft was 2000 cells/mm² and a subjective morphometry. Our upgrade to an endothelial analyser (Sambacornee™) made us realise that our manual counts were underestimated, even with a proper calibration. The aim of this study was to determine the new cut off values for ECD and objective morphometry to qualify a cornea with the same endothelial quality as we had previously

Methods During 9 months, 272 consecutive corneas (from 502 to 3120 cells/mm²) were assessed manually and with Sambacornee. The Bland Altman method studied the agreement between both. Mean of the coeff of variation of cell size and % of hexagonality were compared with the manually determined pleomorphism and polymegethism graded high, moderate, or low

Results Manual and computer-determined ECD were highly correlated ($r=0.83$, $p<0.0001$). The higher the ECD, the higher was the underestimation of the manual count ($r=0.7$, $p<0.001$). For the ECD values near 2000 cells/mm², the mean gap between both methods was of 490 cells/mm², 95%CI [400- 570]. A CV <27% corresponded to low pleomorphism, and >35% to high pleomorphism. Hexagonality >54% corresponded to a low polymegethism, and <45% to a high polymegethism

Conclusion This study scientifically determined our new cut off ECD value (2500 cell/mm²) to qualify a cornea for graft without lowering the quality in comparison to our previous standards. Corneas near this value but with CV<27% and/or hexagonality<45% should be suspiciously considered

EVER-2004-abstractbook.indd 73 8/19/04 12:26:16 PM

349

Establishing endothelial standards for the quality control of endothelial cell count in eye banks

ACQUART S (1), GAVET Y (1), THURET G (2), BRUN G (3), RACINE G (4), CAMPOS-GUYOTAT L (2), GARRAUD O (1), GAIN P (2)
(1) French Blood Center Loire/Auvergne, Eye Bank, Saint-Etienne
(2) EA3063 Lab 'Cell survival and adherence', Faculty of Medicine, Saint-Etienne
(3) Laboratoire Traitement du Signal et Instrumentation, UMR CNRS 5516, Université Jean Monnet, Saint-Etienne
(4) Center of micro-nano technology, Ecole polytechnique fédérale de Lausanne, Lausanne

Purpose To develop unalterable calibrated microscopic hexagonal mosaics mimicking a human corneal endothelium. These standards will allow to realise quality controls of the measurement of the endothelial cell density of the graft as well as cell morphometry in eye banks

Methods In collaboration with the Swiss Federal Institute of Technology of Lausanne, we developed calibrated laser printed mosaics with pre-determined 'cell' densities and morphometric parameters (hexagonality and coefficient of variation of cell area)

Results Boundaries of the hexagons were of 0.3 µm, close to real endothelial cells. The printed area was of 1 mm^2. A micrometric scale was associated to each mosaic. The drawing was unalterable and the glass slides were integrated in carbon fibre slides, to ensure an easy handling and safe transport. Homogeneous and heterogeneous hexagonal mosaics, with or without simulated folds, all with different densities were generated

Conclusion We innovated endothelial standards able to: 1/ ensure proper verification of the calibration of the microscopes used in eye banks, 2/ serve for the training of the new technicians, 3/ allow periodical verification of the absence of drift in counting accuracy. These standards should be major tools for the normalization of endothelial cell count between all eye banks

350

Shouldn't we quantify the transparency and thickness of organ cultured corneas ?

ACQUART S (1), GAVET Y (2, 3), ZHAO M (2), MANISSOLLE C (2), THURET G (2), GARRAUD O (1), GAIN P (2)
(1) French Blood Center Loire/Auvergne, Eye Bank, Saint-Etienne
(2) EA3063 Lab 'Cell survival and adherence', Faculty of Medicine, Saint-Etienne
(3) Ecole Nationale Supérieure des Mines de Saint-Etienne, Saint-Etienne

Purpose Corneal tissue should theoretically meet 3 quality requirements to be qualified for penetrating keratoplasty after organ culture (OC): Endothelial cell density (ECD), transparency and thickness must all three be sufficient. Contrary to the ECD that can be objectively quantified thanks to image analysis software, transparency is only subject to a naked eye appreciation at procurement or during storage, and thickness is never assessed. Aim of this study: to report 2 cases of cornea provided for graft in spite of significant opacities or reduced thickness, in order to propose some solutions to increase these aspects of graft quality control

Methods Report of 2 cases

Results Case 1. Cornea with stromal opacities sequela of viral keratitis during childhood, remained undetected during both OC and graft (bullous pseudophakic oedema). Case 2. Cornea with dramatic thin stroma, consistent with keratoconus, remained undetected during both OC and graft (bullous pseudophakic oedema). No medicolegal issue for these 2 grafts which fortunately aimed to be only antalgic. The 2 fellow donor corneas led to uneventfull grafts

Conclusion Legal requirements compel surgeons to ensure to the patients a high level of security and quality for the grafted tissue. If such cases still remain scarce, their frequency is likely to increase in a near future as a consequence for the exponential number of refractive surgery performed worldwide. An objective assessment of transparency and thickness during OC is difficult but needs to be carefully examined. It requires non invasive techniques that can be able to take account of the reversible mandatory stromal modifications induced by OC

351

New animal compound free medium for human corneal organ culture

MANISSOLLE C (1), GARRAUD O (2), ACQUART S (2), CAMPOS-GUYOTAT L (1), GUYOTAT D (1), GAIN P (1, 3), THURET G (1, 4)
(1) EA3063 Lab 'Cell survival and adherence', Faculty of Medicine, Saint-Etienne
(2) French Blood Center Loire/Auvergne, Eye Bank, Saint-Etienne
(3) Ophthalmology dpt, University Hospital, Saint-Etiennne, FRANCE
(4) Ophthalmology dpt, University Hospital, Saint-Etienne, FRANCE

Purpose To present the ex vivo evaluation of an animal compound free (ACF) medium compared to the commercial media with 2% FCS available in France. Because of proprietary interest of Stem Alpha (St-Clément les Places, France), the full composition is not available. We added to the AFC medium a new molecule for the deswelling step

Methods Twenty eight paired scientific human corneas were randomized at procurement in either the ACF or the classical medium and assessed blind to the medium type, at D2 and D30 of OC at 31°C (with renewal at D14), and after D2 of deswelling: endothelial cell density (ECD) and morphometry were determined using a Sambacornee™ analyser (Sambatechnologies, Meylan, France), the quality of EC visualisation (good, average, not visible) was graded. Pachymetry and transparency were measured at D30 and D32

Results ECD were similar at D2. Daily EC loss during OC (-0.31±-0.29% vs -0.88±0.38%, $p<0.001$) and EC loss during deswelling (-1.43±3.60% vs -15.41±10.13%, $p<0.001$) were dramatically reduced with the ACF medium. ECD after deswelling was dramatically higher by 40% in ACF medium (2466±447 vs 1729±281 cells/mm^2, $p<0.001$). Neither corneal transparency, nor pachymetry differ between the two media. ACF medium facilitated considerably the EC visualisation

Conclusion The ACF medium proves its superiority over commercial medium with 2% FCS, regarding its ability to preserve EC viability. The innovative deswelling molecule appears far less toxic than dextran

352

Corneoscleral harvesting by automated trephine system: comparison- ophthalmologist with nurse

MANISSOLLE C (1), PEYRAGROSSE T (2), DEFREYN A (3), GARRAUD O (4), ACQUART S (4), THURET G (3, 1), GAIN P (3, 1)
(1) EA3063 Lab 'Cell survival and adherence', Faculty of Medicine, Saint-Etienne
(2) Coordination team for organ and tissue harvesting, University Hospital, Saint-Etienne
(3) Ophthalmology dpt, University Hospital, Saint-Etienne
(4) French Blood Center Loire/Auvergne, Eye Bank, Saint-Etienne

Purpose The French law authorizes corneal harvesting on non heart-beating donors only by corneoscleral disc recovery, under the supervision of a medical doctor (MD). The corneoscleral disc must have at least 16 mm in diameter. The recent Berland's report of the French Graft Agency proposes to delegate this act to trained technician in a near future. We consequently aimed to evaluate an automated cutting system of the corneoscleral disc designed to facilitate the delegation of the harvesting to non MD

Methods Ten pairs of corneas have been trephined by the automated ASMOTOM Trephine system (Deutschmann Instruments, Zittau, Germany). This wireless instrument was equipped with a central suction system and a rotating 18 mm disposable trephine. One eye was trephined by a skilled ophthalmologist, the other by the full time nurse coordinator for organ and tissue harvesting of our university hospital. The coordinator had received a one hour training for cornea harvesting

Results The 10 corneoscleral discs were successfully cut by the automated trephine, with a 360° full-thickness cutting in 50% of cases, the rest needing a complementary scissors cut. The quality of cut did not depend on the operator. No misalignment, no endothelium traumatism, nor microbiological contamination was observed regardless of the operator

Conclusion The automated trephine system allows the standardization of corneoscleral disc cutting after only a basic training. Considering the growing shortage of MD, especially ophthalmologists in France, such device would facilitate the future delegation of the donor cornea harvesting to professional of tissue collection, as it has already been done since years in other European countries

EVER-2004-abstractbook.indd 74 8/19/04 12:26:17 PM

353 / 3337

Topical hydrosoluble prodrug of cyclosporin A to prevent corneal graft rejection

BOURGES JL (1), VALAMANESH F (2), AGLA EK (1), LALLEMAND F (3), GURNY R (4), JEAN-MAURICE D (5), BESSEGHIR K (5), BEHAR-COHEN FF (6, 2)
(1) ophthalmology, Hotel-Dieu Hospital, Paris
(2) INSERM U598, Paris
(3) Biopharmaceutics, University of Geneva, Lausanne
(4) Biopharmaceutics, University of Geneva, Geneva
(5) DeBiopharm, Lausanne
(6) Ophthalmology, Rothschild Foundation, Paris

Purpose UNIL-088 is a hydrosoluble prodrug, enzymatically converted into cyclosporin A (CsA), within minutes after contact with tears. The aim of the study was to evaluate the effect of topically applied UNIL-088 on acute corneal graft rejection in rat eyes and to compare its effect to CsA systemic administration.

Methods Fifty-two Lewis rats with technically successful corneal allografts from Brown Norway donors were included. UNIL-088 (Debiopharm,Switzerland), dissolved at 0.2% in phosphate buffer saline was instilled 5 times/day. Rats were divided in 3 groups: Group I received PBS, 5 times/day (n=18); Group II received UNIL-0880.2% drops in PBS 5 times a day (n=18); and Group III received systemic CsA 10mg/Kg/day (n=16). Treatments were administered for 2 weeks. The rejection evaluation was based on graft opacity, edema and neovascularization. Blood levels of CsA were measured 2 and 13 days after surgery.

Results On day 13, group II and III had significantly less graft rejection in all parameters tested versus group I (p= 0.026 for group II vs. I, and p= 0.013 for group III vs. I, chi2 test). On day 13, CsA blood levels were above 1,000 ng/ml in group III, but below 40 ng/ml in group II.

Conclusion Topical instillation of 0.2% UNIL-088 efficiently reduce corneal graft rejection as well as systemic CsA after conversion of the prodrug to active CsA and local release, while preventing CsA systemic adverse effects. Blood CsA levels after UNIL-088 administration were below the detection limits.

354 / 3338

The role of T Helper 1 (Th1) and Th2 cytokines in corneal graft rejection

HOLAN V (1), VITOVA A (1), PINDJAKOVA J (1), KRULOVA M (1), ZAJICOVA A (1), FILIPEC M (2)
(1) Institute of Molecular Genetics, Prague
(2) Dept. Ophthalmol., 1st Medical Faculty, Prague

Purpose To investigate expression of genes for cytokines and other immunologically relevant molecules in rejected corneal allografts and xenografts.

Methods Corneal grafts from syngeneic (BALB/c mouse), allogeneic (B10 mouse) or xenogeneic (Lewis rat) donors were grafted orthotopically in mouse BALB/c recipients. The recipients were untreated or treated with monoclonal antibody (mAb) anti-CD4 or anti-CD8. Expression of genes for Th1 cytokines interleukin (IL)-2 and interferon (IFN)-g and Th2 cytokines IL-4 and IL-10 and for inducible nitric oxide synthase (iNOS) in the grafts was detected by RT-PCR.

Results Rejection of corneal allografts was associated with a strong expression of genes for Th1 cytokines IL-2 and IFN-g and a low expression of Th2 cytokines IL-4 and IL-10. On the contrary, a strong upregulation of genes for IL-4 and IL-10, in addition to the expression of Th1 cytokines, was found in rejected corneal xenografts. Treatment of graft recipients with mAb anti-CD4, but not with mAb anti-CD8, resulted in suppression of all upregulated genes and in a significant prolongation of survival of both corneal allografts and xenografts. Rejection of the grafts was always associated with expression of genes for IFN-g and iNOS and occured even in the absence of detectable IL-2, IL-4 or IL-10. There was not detectable expression of genes for cytokines in syngeneic grafts.

Conclusion Corneal allotransplantation induces typical Th1 cytokine response, while rejection of corneal xenografts is associated with a high production of both Th1 and Th2 cytokines. However Th2 cytokines are not needed for xenograft rejection. Rather, rejection of both allografts and xenografts correlates with the expression of genes for IFN-g and iNOS.

355 / 3339

Roles of Thrombospondin-1 and -2 in Maintaining Corneal Angiogenic Privilege

CURSIEFEN C (1, 2), DANA MR (2), LAWLER J (3), STREILEIN JW (2)
(1) Dept. of Ophthalmology, University of Erlangen-Nürnberg, Erlangen
(2) Schepens Eye Research Institute, Harvard Medical School, Boston
(3) Dept. of Pathology, Beth Israel Deaconess Hospital, Harvard Medical School, Boston

Purpose Thrombospondin (TSP)-1 and -2 are important antiangiogenic factors thought to be involved in maintaining corneal avascularity (angiogenic privilege). This study was undertaken to investigate whether deficiencies of these factors altered developmental and inflammation-induced angiogenesis in the cornea of mice.

Methods Expression of TSP-1 and -2 mRNA and protein was assayed in cornea by RT-PCR and Western blot. Corneas of TSP-1(-/-), TSP-2(-/-), and TSP-1,2(-/-) mice aged 2, 3, and 6 months, and wild-type control mice, were analyzed for spontaneous angiogenesis biomicroscopically, histologically, and with CD31 immunohistochemistry. The mouse model of suture-induced, inflammatory corneal neovascularization was used to evaluate the lack of TSP-1,2 and both TSPs on induced-corneal angiogenesis.

Results Corneas from normal mouse eyes constitutively expressed TSP-1 and -2 mRNAs and proteins. Corneas of TSP-1(-/-), -2(-/-), and -1,2(-/-) mice displayed no evidence of spontaneous developmental-postnatal angiogenesis. One week after suturing, corneas of all TSP(-/-) mice had significantly greater corneal angiogenesis than those of control mice ($P < 0.05$). TSP-1(-/-) had a significantly greater effect on induced corneal neovascularization than did TSP-2(-/-), with the opposite being the case in developmental iris angiogenesis ($P < 0.01$).

Conclusion Corneal avascularity during development is redundantly regulated, shown by the fact that lack of the antiangiogenic factors TSP-1 and/or -2 resulted in no spontaneous corneal angiogenesis. By contrast, TSP-1, more than TSP-2, helps to suppress inflammation-induced corneal angiogenesis postnatally, implying that angiogenic privilege in the cornea is actively maintained.

356 / 3156

Effects of latanoprost 0.005% and the fixed combination dorzolamide/timolol on IOP and retrobulbar hemodynamics in glaucoma patients

MARTÍNEZ-GARCÍA AMG (1), SANCHEZ-SALORIO MSS (2), GARCÍA-FEIJOO JGF (3)
(1) Instituto Galego de Oftalmoloxía, Santiago de Compostela
(2) Instituto Galego de Oftalmoloxia, Santiago de Compostela
(3) Hospital Clinico San Carlos, Madrid

Purpose In a prospective, crossover, randomized study the vascular and the IOP effects of latanoprost and the fixed combination of dorzolamide/timolol were evaluated in patients with open-angle glaucoma.

Methods 22 consecutive subjects with newly diagnosis of open-angle glaucoma were included in this study. IOP and Doppler examination were assessed in all patients at baseline, then patients were randomized in two groups: Group A (12 patients) recieved firstly treatment with latanoprost QD for 1 month; IOP and Doppler examination were measured and, after a 1-month washout period, they recieved treatment with a fixed combination of dorzolamide/timolol BID and, the same measurements were repeated. Group B recieved firstly treatment with the fixed combination during 1 month, IOP and Doppler measurements were assessed and, after 1 month of washout, the patients were treated with latanoprost QD and the same measurements were repeated.

Results IOP and Doppler measurements were similar at baseline. Latanoprost reduced the IOP from 25.83(3.74) to 19.00(1.81) mm Hg in group A, and from 26.90(3.76) to 19.00(2.49) in group B. The fixed combination reduced the IOP from 26.00(3.89) to 18.92(1.00) in group A, and from 27.30(3.80) to 19.30(2.21) in group B. Compared to baseline and washout measurements only the fixed combination dorzolamide/timolol induced a statistically significant decreased in the hemodynamic parameters in the Ophthalmic and Short posterior Ciliary Arteries.

Conclusion Both treatments decreased IOP, but only the fixed combination dorzolamide/timolol had a vascular effect on the retrobulbar vessels.

EVER-2004-abstractbook.indd 75 8/19/04 12:26:17 PM

357 / 3157

The rabbit´s IOP after instillation of the amino acid L-arginin. HCl and antiglaucomatics misture

OLAH Z (1), VESELOVSKY J (2), GRESSNEROVA S (2), VESELA A (2)
(1) Dept. of Ophthalmology,Comenius University, Bratislava
(2) Inst. of Animal Physiology and Ethology, Comenius University, Bratislava

Purpose To compare effectivity of the 3 mixtures: L-arginin.HCl with Timolol, Trusopt and Xalatan on the physiologic intraocular pressure (IOP) in rabbits.

Methods a/ The 10% L-arginin.HCl only; b/ mixture of the 10% L-arginin.HCl with 5.5% Timoptol, 10% L-arginin.HCl with 2% Trusopt and 10% L-arginin.HCl with 0.005% Xalatan was instilled into the left conjunctival sac of te 5 adult rabbit´s (female of the New Zealand Whithe species) and the rigth eye was used as control. The IOP and pupilar diameter were measured before and in 5th, 15th, 30th, 60th, 120th, 180th, 240th min. and 24 hours after the instillation.

Results The 10% L-arginin.HCl decreased the physiologic IOP by 16% (mean value). The mixture of the 10% L-arginin.HCl with 0.5% Timoptol, 2% Trusopt and 0.005% Xalatan decreased significantly the IOP value compared with the contol eye. This mixtures was twice as effective as any of the mentioned antiglaucomatics used separately. The pupilar diameter was not changed.

Conclusion We assume that the mentioned mixtures were able to decrease the physiologic IOP in rabbits through their better penetration to the receptors of the ciliary body followed by decrease of the amino acid secretion into the aqueous humor. We conclude that the increased effectivitiy of the mixtures compared with the separate components is related to the instillation of the by now ready "bioantiglaucomatic".

358 / 3158

Clinical experience with the Ahmed Valve implant in a non-tertiary ophthalmic unit

KALHORO A (1), MATAFTSI A (1), ATTENBOROUGH M (1), MEARZA A (1), BIDGOOD P (2), MCNIECE R (2), GILLESPIE I (1)
(1) Royal Eye Unit, Kingston-Upon-Thames
(2) Kingston University, Kingston-Upon-Thames

Purpose To assess clinical outcomes of Ahmed valve implants in intractable glaucoma.

Methods Single-centre, retrospective case-note analysis. Success was defined as post-operative IOP of 6-21 mmHg in the absence of complications.

Results 23 eyes (21 patients) were treated with an Ahmed valve implant between 1996 and 2002. The mean ± SD (standard deviation) patient age was 72.9 ± 13.7 years (range 33-93). Mean follow-up was 38 ± 27 months (range 12-92).The underlying diagnosis was primary open angle glaucoma in 65% (n=15). In 13 cases (57%), patients had undergone ≥3 previous penetrating ocular surgeries. Intraocular pressure was reduced from a pre-operative mean of 28.4 ± 6.6 mmHg to 15 ± 7.9mmHg at last follow-up. Cumulative probabilities of success at 1 and 2 years were 73% and 53% respectively (Kaplan-Meier life table analysis). 7 implants (30%) remained successful beyond 24 months (range 24-92) with no additional complications. 7 implants (30%) failed by 12 months and 10 implants (43%) failed by 24 months. Major post-operative complications were persistent hyphaema in 2 cases (9%), gross tube or plate extrusion in 3 cases (13%), intra-cameral tube displacement in 2 cases (9%) and one case each of endophthalmitis, corneal graft decompensation and chronic hypotony. Tubes were removed in 4 cases (17%) and additional surgery (not including needling) was necessary in 10 cases (43%). 10 patients (43%) lost at least 2 lines of Snellen acuity.

Conclusion Results for success at 1 year are comparable with studies in tertiary units. Lower rates for success were obtained at 2 years. This may reflect both a significantly higher mean age and previous number of ocular surgeries in this cohort.

359 / 3159

Evaluation of preoperative factors associated with success of mitomycin C needling revision for failed filtration blebs: a prospective study

GUTIERREZ CG, TEUS MT
Hospital de Alcala de Henares, Alcala de Henares

Purpose To study the effectiveness and the factors for success of Mitomycin C (MMC) needling revision for failed filtration blebs.

Methods Prospective, nonrandomized conparative (self-controlled) trial of34 consecutive patients that underwent MMC needling revision for failed filtering bleb.. Needling revision followed by 0.01ml (0.2 mg/ml) MMC injection. Preoperative factors were evaluated for an association with postoperative success using Kaplan-Meier survival analysis.

Results The mean (+/- standard deviation) IOP before the procedure was 25.58 (+/- 4.43) and decreased 11.11, 13.47, 15.82, 16.70, 14.96, 14.19, 113.95 and 13.07 on the first postoperative day, after 1, 3, 6, 9, 12 and 24 months respectively. At each interval, the mean IOP was significantly lower than the preoperative value (P=0.000 for each period). At the last visit overall succes was achieved in 29 eyes (85.2%); absolute in 15 (44.1%) and qualified in 14 (31.2%). The success rates were 90% and 75% at 1 and 2 years respectively (Kaplan-Meier survival analysis). Successful single-needling procedure was highly correlated with past glaucoma filtration surgery of less than 4 months (Kaplan-Meier survival analysis, log-rank test P=0,006).

Conclusion Mitomycin needling revision appears to have high succes rate. Past surgery of less than 4 months isre found to be significant factors for success. We recommend performing the procedure as soon as IOP starts to increase or bleb aplanation is detected.

360 / 3417

Comparison of anterior and posterior corneal curvatures (Orbscan II) in normal and glaucoma patients

HERNANDEZ VJL (1, 2), TEUS MA (1, 3), MARINA C (1), GIL R (4, 2), SáNCHEZ JM (1)
(1) VISSUM Hospital Oftalmológico, Madrid
(2) Universidad Complutense, Madrid
(3) Universidad de Alcalá, Madrid
(4) VISSUM Hospital Oftalmólogico, Madrid

Purpose To evaluate differences in corneal anterior and posterior curvatures between patients with and without glaucoma.

Methods This is a masked prospective study done in a group of glaucoma patients and healthy people (used as control group). Ultrasound central pachimetry (three measurements), refractive error, gonioscopy, Goldman tonometry (prior to hypotensive treatment) in the glaucoma group (three measurements), and elevation topography Orbscan II (three measurements) were done in all patients. Subjects with corneal disease, previous ocular surgery and patients under treatment with inhibitor of carbonic anhidrase were excluded. The statistical analysis was done with the two tail paired t – Student test.

Results We compared 69 glaucomatous eyes with 69 normal healthy eyes, matched pachimetry. The mean age was 51.15 + 16.67 (range 22 to 78 years) and the astigmatism was lower than -3.00 D. The mean keratometric values were 43.77+ 1.68 D. We found significant higher difference in posterior surface elevation (p=0.001) and a significant difference between the highest and lowest elevation points in the anterior surface (p=0.005) in the glaucomatous group when compared to the control group.

Conclusion Our results suggest that elevation of the posterior surface, parameter that is traditionally related to ectasia, is higher in glaucomatous patients than in normal healthy subjects when they are pachimetry and corneal astigmatism matched.

EVER-2004-abstractbook.indd 76 8/19/04 12:26:18 PM

■ 361 / 3418

Central corneal thickness correlated with glaucoma damage and rate of progression

JONAS JB, STROUX A, VELTEN I, JUENEMANN A, MARTUS P, BUDDE WM
Department of Ophthalmology, Faculty for Clinical Medicine Mannheim, Ruprecht-Karls-University, Heidelberg

Purpose To evaluate whether the amount of glaucomatous optic nerve damage at presentation of the patient and the rate of progression of glaucoma during follow-up are related to central corneal thickness.

Methods The prospective observational clinical study included 861 eyes of 454 Caucasian subjects (239 normal eyes of 121 subjects, 250 ocular hypertensive eyes of 118 patients, 372 eyes of 215 patients withchronic open-angle glaucoma). For 567 eyes (304 patients) with ocular hypertension or chronic open-angle glaucoma, follow-up examinations were performed with a mean follow-up time of 62.7 ± 33.2 months (median 60.8 months; range 6.2 to 124.9 months). All patients underwent qualitative andmorphometric evaluation of color stereo optic disc photographs and white-on-white visual field examination. Central corneal thickness was measured by corneal pachymetry.

Results Central corneal thickness was significantly ($p<0.001$) and positively correlated with the area of the neuroretinal rim and negatively correlated with the loss of visual field. Development or progression ofglaucomatous visual field defects detected in 119 (21.0%) eyes was statistically independent of central corneal thickness, in a univariate ($p=0.99$) as well as in a multivariate Cox regression analysis ($p=0.19$).

Conclusion At the time of patient referral, the amount of glaucomatous optic nerve damage was significantly correlated with a thin central cornea. Progression of glaucomatous optic nerve neuropathy was independent of central corneal thickness suggesting that central corneal thickness may not play a major role in the pathogenesis of progressive glaucomatous optic nerve damage.

■ 362 / 3419

Chronic ocular hypertension alters retrograde axoplasmic transport in adult rats

MAYOR - TORROGLOSA S (1), VILLEGAS-PÉREZ MP (1), SALAZAR JJ (2), RAMÍREZ JM (2), TRIVIÑO A (2), RAMÍREZ AI (2), COLL L (1), VIDAL-SANZ M (1)
(1) Departamento de Oftalmología, Universidad de Murcia, Murcia
(2) Instituto de Investigaciones Oculares Ramón Castroviejo, Universidad Complutense de Madrid, Madrid

Purpose To study the effects of chronic ocular hypertension on retrograde axonal transport in adult rat retinal ganglion cells (RGC)

Methods In adult Sprague-Dawley rats, the intraocular pressure of the left eye was chronically elevated by laser photocoagulation (532nm wavelength, 500mW power, 0,25 second duration, 100 µm diameter spot size) of the limbus and most of the episcleral veins following previously described methods (WoldeMussie et al., 2001). Intraocular pressure in both eyes was measured with a Tono-Pen prior to and 1 and 2 weeks after lasering. Retrograde axonal transport was investigated by examining RGCs labeled with fluorogold applied to both superior colliculi 1 week before sacrifice. The nerve fiber layer was examined with neurofilament antibodies (RT97)

Results Laser treatment induced an increase in mean intraocular pressure of approximately 30% over baseline that was maintained throughout the period of study. After three weeks of elevated IOP, there were wedge sectors of the retina lacking RGCs retrogradely labelled with FG. The neurofilament staining in these sectors revealed the presence of RGC axons that showed typical features of axonal degeneration. There was certain variability among different animals in the size of these sectors that often extended to one quadrant of the retina and were more frequent in the superior retina

Conclusion Chronic elevation of the intraocular pressure results 3 weeks later in RGC loss and altered retrograde axonal in pie shaped sectors of the retina Research Support: FIS CO3/13

■ 363 / 341a

Chronic ocular hypertension induced degeneration of retinotectal afferents: long term neuroprotection with topical brimonidine

MAYOR - TORROGLOSA S (1), WOLDEMUSSIE E (2), GARCÍA A (1), RUIZ G (2), BERNAL JM (1), WHEELER LA (2), VIDAL-SANZ M (1)
(1) Dpto Oftalmología, Murcia
(2) Allergan Inc., Irvine, California

Purpose To study chronic ocular hypertension (COHT)-induced alterations of retinotectal innervation and the neuroprotective effects of topically applied hipotensive drugs.

Methods COHT was induced in the right eye of adult male Wistar rats by laser photocoagulation of episcleral veins (WoldeMussie et al., 2001). Right eyes were treated twice daily with 5 µl of Alphagan-P, Timoptic or 0,9% NaCl. Intraocular pressure was measured with a Tono-Pen prior to, 1, 2, 5 and 9 weeks after lasering in experimental and in a group of naïve rats. The effects of these drugs were investigated by examining at 9 weeks retinal afferents to the superior colliculus anterogradely labeled with Cholera Toxin B subunit injected into COHT eyes.

Results At 9 weeks the volume of the retino-tectal projection was 4.09±0.31 (n=16), 3.13±0.74 (n=13), 3.78±0.8 (n=15), or 3.19±0.63 (n=15), for the unlesioned, vehicle-, Alphagan-P-, or Timolol-treated groups of rats, respectively. There were significant reductions in the volume of the retino-tectal projection in timolol or vehicle-treated groups when compared to naïve or BMD-treated groups.

Conclusion COHT results nine weeks later in the loss of approximately 13% of the retino-tectal terminals, Timoptic treatment did not prevent retino-tectal degeneration, and Alphagan-P-treatement resulted in loss of 7%, providing a statistically significant protection against COHT-induced degeneration of the retinotectal projection. These results are consistent with previous studies (WoldeMussie et al., 2001; IOVS 42:2849) showing similar degree of protection. Research support: F.Séneca PI82/00540/FS/01, BFI2002-03742 and Allergan Inc.

■ 364

Retinal ganglion cell death after chronic elevation of intraocular pressure: a novel model of glaucoma in pigs

VECINO E (1), RUIZ J (1), GARCÍA M (1), HERNÁNDEZ M (1), URCOLA H (1), HERNÁNDEZ E (1), ARAIZ J (2), DURÁN JA (2)
(1) Cell biology and histology, University of the Basque Country, Vizcaya, Spain
(2) Ophthalmology, University of the Basque Country, Vizcaya, Spain

Purpose To validate the pig eye as a model of glaucoma, based on chronic elevation of intraocular pressure (IOP).

Methods IOP was elevated by cauterizing three episcleral veins in the left eyes of three adult pigs. Right eyes were used as controls. Measurement of IOP was performed with an applanation tonometer (Tono-Pen). Six months after episcleral vein occlusion, retinal ganglion cells (RGC) from both cauterized and control eyes were retrogradely backfilled with Fluoro-Gold. Analysis of RGC loss and morphometric characterization of surviving RGCs was performed using whole-mounted retinas.

Results Elevation of IOP after cauterization of the epiescleral veins was apparent by the 3rd week and remained elevated through all the experimental period. Elevation of IOP led to a significant RGC death in the peripheral and mid-peripheral retina. Thus mean RGC density (RGC/ mm2) in the peripheral retina was 239 in controls vs 188 in cauterized eyes. In the mid-periphery the mean RGC density was 838 in controls and 727 in cauterized eyes. A more detailed analysis revealed that RGC loss was greater in temporal quadrants. Moreover the mean soma area (micrometer2) of remaining RGC was increased. Thus, in the periphery the mean RGC soma area was 298 in controls vs 328 in cauterized, and in the mid-periphery 235 in controls vs 244 in cauterized eyes.

Conclusion The pattern of RGC death induced in the pig retina by episcleral vein cauterization resembles that found in human glaucoma. The pig retina may be considered as a suitable model for glaucoma-related studies, based on its similarity with human and on its affordability.

EVER-2004-abstractbook.indd 77 8/19/04 12:26:18 PM

■ 365

Relation between polarimetric RNFLT and retinal sensitivity: frequency doubling technology and conventional perimetry show similar structure-function relationship

KOTHY P, KATSANOS A, HOLLÓ G
1st Dept of Ophthalmol Semmelweis Univ, Budapest

Purpose To investigate the structure-function relation between polarimetric RNFLT parameters and retinal sensitivity(MS) as measured with FDT and W/W threshold perimetry.

Methods One eye of 24 OAG patients (age:63.1±12.5 y, MD:5.51±5.22dB) and 17 controls (age:31.9±11.1 y, MD:-0.39±0.95dB) was imaged with the GDx-VCC using customised corneal compensation. The corresponding visual fields (Octopus G2 normal,and FDT 30° threshold) were obtained within 1 week from polarimetry. Correlation between superior(S), inferior(I) and global GDx parameters and W/W and FDT sensitivity was calculated both with and without un-logging the individual point dB values, and Bonferroni correction was used for the p-values.

Results FDT and W/W MS (S,I and global) correlated significantly ($p<0.001$) for the total subject population and the glaucoma subgroup, but not for the controls. For the total study population S average, I average, S maximum and normalized S and I areas correlated positively with both W/W-MS and FDT-MS of the opposite hemifield ($p<0.001$), but I max correlated only with W/W MS ($r=0.495, p=0.02$). TSIN average, TSIN SD, maximum modulation and ellipse modulation correlated positively with both W/W-MS and FDT-MS (r:0.573 to 0.702,$p<0.001$). Un-logging the dB values did not reveal any new correlation. Due to the lack of homoscedasticity the structure-function relationship did not become perfectly linear after the un-logging transformation. No significant correlation was found for the subgroups, separately.

Conclusion W/W perimetry and FDT show a similar relation with polarimetric RNFLT parameters in eyes with no to moderate glaucomatous functional loss.

■ 366

Differences between glaucomatous patients with predominantly functional or structural deterioration

COOPS A, HENSON DB, KWARTZ AJ, FENERTY C, HARPER RA, SPENCER AF, MCLEOD D
Academic Department of Ophthalmology, Manchester

Purpose To establish whether glaucoma and high risk patients who predominantly show progressive functional loss differ from those who predominantly show progressive structural loss.

Methods Longitudinal (average follow-up time 3.22 years) Heidelberg Retinal Tomograph (HRT), Nerve Fibre Layer Analyzer (GDx) and Humphrey 24-2 full threshold visual field (HFA) data were collected from 199 high risk patients (IOP>21mmHG or fellow eye with glaucoma) and 66 glaucomatous patients. Significant deterioration in global neuro-retinal rim area (HRT), the number (GDx) and mean pattern deviation (HFA) was established by linear regression analysis. The optic disc area, use of medication and IOP reduction with trabeculectomy were compared in those that predominantly showed functional loss with those that predominantly showed structural loss.

Results The percentage of patients showing significant progression with the HFA was 7.92%, HRT 6.79% and GDx 5.66%. Few patients showed overlap in significant functional and structural change; HFA and HRT 1.51%, HFA and GDx 0.38%. A larger average optic disc area was found in the structural change groups (HRT 2.06mm^2, GDx 2.23mm^2) compared with the functional change group (HFA 1.87mm^2), with a significant difference in disc area between HFA and GDx ($p=0.05$); HFA vs HRT $p=0.26$. There were no significant differences between the two groups when looking at use of medication and trabeculectomy.

Conclusion Significant functional (HFA) and structural (HRT and GDx) deterioration was found in a small proportion of the population. Only a few of these patients showed both functional and structural loss. Those patients showing predominantly structural loss had larger optic disc areas.

■ 367

Sensitivity and specificity of analysis tools for detection of glaucoma with the Heidelberg Retina Tomograph II

FERRERAS A (1), MAYORAL C (1), POLO V (1), LARROSA JM (1), PUEYO V (1), PAJARIN AB (2), CASTILLO A (3), HONRUBIA FM (1)
(1) Ophthalmology, Zaragoza
(2) Primary Care, Zaragoza
(3) Ophthalmology, Madrid

Purpose To evaluate the diagnostic capacity to detect glaucomatous damage of the linear discriminant functions (LDFs) and the Moorfields Regression Analysis (MRA) included in the HRT II software and to compare with our logistic regression formulas (LRGs) and the regression predictive intervals of rim area (RPI) elaborated from our autoctone population (Servet).

Methods 101 normal eyes and 102 glaucomatous eyes were enrolled in study. Each patient underwent optic nerve head evaluation performed by means of Heidelberg Retina Tomograph II (Heidelberg Eye Explorer 1.3.0.0. software). The abnormality criteria for each diagnostic tool were based on the receiver operator characteristic curves of the formulas and the predictive intervals of the regression analysis.

Results Bathija's LDF showed better results than Mikelberg's LDF (88 and 79% respectively), while our 4 formulas obtained the following specificities LRG1 -81%-; LRG2 -82%-; LRG3 -81%-; LRG4 -79%-. The best sensitivity-specificity balance were observed for the Mikelberg's LDF and our formula LRG2, that includes rim area, cup volume and cup shape measure.The regression analysis tools showed better sensitivities for the Servet RPI for the confidence intervals of 97.5 and 99.5% (sensitivities 86% and 75% respectively).

Conclusion The HRT analysis tools (LDFs and MRA) are useful to discriminate healthy subjects from glaucoma patients. The use of alternative tools based on normative databases of autoctone population can improve the ability to discriminate the presence of structural glaucoma damage.

■ 368

Optical Coherence Tomography (OCT): Retinal Nerve Fiber Layer thickness measurements to detect glaucomatous damage

FERRERAS A (1), POLO V (1), LARROSA JM (1), PUEYO V (1), MAYORAL C (1), PAJARIN AB (2), GARCIA-FEIJOO J (3), HONRUBIA FM (1)
(1) Ophthalmology, Zaragoza
(2) Primary Care, Zaragoza
(3) Ophthalmology, Madrid

Purpose To evaluate and compare the thickness of retinal nerve fiber layer (RNFL) measured by optical coherence tomography (OCT) in normal, ocular hypertensive, glaucoma suspected and glaucomatous eyes.

Methods 56 normal, 70 ocular hypertension, 62 glaucoma suspects and 42 glaucomatous were enrolled in this study. Subject eyes were classified into diagnostic groups based on intraocular pressure, stereoscopic disc photographs and standard automated perimetry. Three 3.4 mm-diameter circular scans centered on the optic disc were obtained for each eye (OCT 3000; Humphrey Zeiss instruments). Average and segmental (quadrants and hour-positions) RNFL thickness values were compared among all the groups.

Results RNFL thickness was thinner ($p<0.05$) in glaucomatous eyes than in normal and hypertensive eyes, in all the retinal quadrants and in most of the hour-positions. There were a significant ($p<0.05$) decrease in the global RNFL average and in the hour-positions of superior and inferior poles of the optic nerve head (5, 6, 7, 10 and 11 hour-positions) in glaucoma group with respect to the ocular hypertensive eyes and glaucoma suspects group.

Conclusion Quantitative RNFL measurements using OCT showed differences between normal, ocular hypertensive, glaucoma suspects and glaucomatous eyes. Furthermore, this technique may be useful in glaucomatous damage detection.

EVER-2004-abstractbook.indd 78 8/19/04 12:26:19 PM

■ 369

Diagnostic ability of scanning laser tomography assessed by means of Heidelberg Retina Tomograph II, to detect structural changes in the optic disc, in glaucoma suspects and glaucomatous eyes

MAYORAL C, LARROSA JM, POLO V, FERRERAS A, PUEYO V, LOPEZ MJ, HONRUBIA FM
Ophthalmology, Zaragoza

Purpose To evaluate the ability of confocal scanning laser tomography of the optic nerve head to detect glaucomatous damage in glaucoma suspects and glaucomatous eyes.

Methods A total of 101 normal subjects, 46 glaucoma suspects eyes (increased intraocular pressure, normal standard automated perimetry and altered short-wavelength automated perimetry –SWAP-) and 102 glaucomatous subjects (defined by standard automated perimetry) were included in the study. Every patient underwent complete ophthalmic examination, reliable standard automated perimetry (full threshold 24-2 Humphrey perimetry), SWAP and confocal scanning laser ophthalmoscopy (HRT II, Heidelberg Eye Explorer 1.3.0.0. software). The receiver operating characteristic curves (ROC) were plotted to obtain the diagnostic value of the different optic nerve head parameters assessed by the HRT II.

Results The most discriminant parameters in the glaucoma group (at a given specificity of 90%) were rim area (sensitivity 63.7 %), cup-to-disc area ratio (sensitivity 59.8 %), vertical cup-to-disc ratio (sensitivity 60.8 %), and FSM discriminant function (sensitivity 68.6 %). In the glaucoma suspects group, the best topographic parameters to detect glaucomatous damage (at a given specificity of 90%) were rim volume (sensitivity 50 %), cup shape measure (sensitivity 52.2 %),.vertical cup-to-disc ratio (sensitivity 52.2 %), and FSM discriminant function (sensitivity 69.6 %).

Conclusion Several optic nerve head parameters measured by confocal scanning laser HRT II are useful to detect early glaucomatous damage, despite the overlapping of results between the groups.

■ 370

Diagnostic value of Optical Coherence Tomography (OCT) to detect structural damage in the Retinal Nerve Fiber Layer (RNFL) in glaucoma suspects and glaucomatous eyes

PUEYO V (1), LARROSA JM (1), POLO V (1), FERRERAS A (1), MAYORAL C (1), PAJARIN AB (2), HONRUBIA FM (1)
(1) Ophthalmology, Zaragoza
(2) Primary Care, Zaragoza

Purpose To evaluate the ability of retinal nerve fiber layer parameters measured by Optical Coherence Tomography (OCT) to detect glaucomatous damage in glaucoma suspects and glaucomatous eyes.

Methods 56 normal eyes, 62 glaucoma suspects and 42 glaucomatous eyes were included in the study. Subject eyes were classified into the diagnostic groups based on intraocular pressure, stereoscopic disc photographs and standard automated perimetry performance. The receiver operating characteristic curves (ROC) were plotted to obtain the diagnostic value of the different RNFL thickness parameters assessed by the OCT.

Results In the glaucoma group, the RNFL thickness parameters with larger ROC areas were the RNFL global average thickness, the inferior retinal quadrant and the 5, 6 hour-positions. The sensitivity of the different RNFL thickness parameters (at a given specificity of 95%) were 45% or higher for RNFL global average and the 7 hour-position. The sensitivity at a given specificity of 90% was 50% or higher for the same RNFL parameters. The diagnostic ability to discriminate glaucoma suspects with a glaucomatous optic neuropathy from normal subjects was higher for the RNFL global average thickness and the 9 hour-position.

Conclusion Several RNFL thickness parameters measured by Optical Coherence Tomography (OCT) are useful to detect glaucomatous damage, despite the overlapping of results between the groups.

■ 371

Correlation between standard automated perimetry global indices and Heidelberg retina tomograph parameters

PUEYO V (1), FERRERAS A (1), LARROSA JM (1), POLO V (1), MAYORAL C (1), PAJARÍN AB (2), HONRUBIA FM (1)
(1) Ophthalmology, Zaragoza
(2) Primary care, Zaragoza

Purpose To correlate the optic nerve head topographic parameters measured by Heidelberg Retina Tomograph II (HRT) with the perimetric indices of standard automated perimetry (SAP).

Methods This study included 101 normal subjects, 247 ocular hypertensive eyes (increased intraocular pressure with normal SAP) and 102 glaucomatous subjects (IOP above 21 mm Hg, abnormal standard automated perimetry and appearance of optic disc compatible with glaucoma). Only one eye was randomly chosen for the study. The visual field was evaluated by means of Humphrey Field Analyzer (24-2 full threshold strategy). The HRT II (Heidelberg Engineering) was used to acquire and measure the optic disc topographic parameters. Pearson correlations between topographic data and perimetric indices were performed for the total sample and each group of patients.

Results A significant correlation was found between several optic disc parameters and the global indices of SAP. Rim area, rim volume, cup/disc area ratio, rim/disc area ratio, cup shape measure, RNFL cross-sectional area, and discriminant functions FSM and RB, showed the strongest correlation with the visual field indices in the total and glaucoma groups. The ocular hypertensive group did not showed many significant correlations.

Conclusion The correlations found between standard automated perimetry and HRTstructural support the use of HRT to assess the structural damage in glaucoma.

■ 372

Reproducibility of optic nerve head asessment and retinal nerve fiber layer thickness measurements using optical coherence tomography

LARROSA JM, FERRERAS A, PUEYO V, POLO V, MAYORAL C, LOPEZ MJ, HONRUBIA FM
Ophthalmology, Zaragoza

Purpose To evaluate the reproducibility of repeated quantitative assessment of optic nerve head topography and retinal nerve fiber layer thickness in normal and glaucomatous subjects.

Methods This study included 25 normal subjects, 37 ocular hypertensive subjects patients (IOP above 21 mm Hg, normal standard automated perimetry). and 31 glaucoma patients (IOP above 21 mm Hg, abnormal standard automated perimetry and appearance of optic disc compatible with glaucoma). The coefficient of variability was elaborated for each subject and parameter. The range, mean and standard deviation of these coefficients was elaborated.

Results The optic nerve head assessment showed higher reproducibility for the following parameters cup-to-disc ratios (vertical, horizontal and area ratios) and (coefficients of variability 5.0%, 4.2%, 6.7%, respectively), followed by disc area and cup area (coefficients of variability 8.0% and 8.0%, respectively).The retinal nerve fiber layer thickness measurement coefficient of variability was 5.8% for the RNFL average and lower at the inferior and temporal sectors (coefficients of variability 6.2% and 7.2%, respectively) than the nasal and superior sectors of the analysis.There are few differences in coefficients of variation among the groups in both analysis (optic nerve head assessment and retinal nerve fiber layer thickness measurements).

Conclusion Optic nerve head and retinal nerve fiber layer thickness can be reproducibly measured with ocular coherent tomography. There are few differences between normal eyes, ocular hypertensive eyes and glaucoma patients.

EVER-2004-abstractbook.indd 79 8/19/04 12:26:20 PM

■ 373

Heidelberg Retina Tomograph II: Multivariate analysis of structural parameters of the optic disc topography

LARROSA JM (1), POLO V (1), FERRERAS A (1), PUEYO V (1), MAYORAL C (1), MARTÍNEZ DE LA CASA JM (2), HONRUBIA FM (1)
(1) Ophthalmology, Zaragoza
(2) Ophthalmology, Madrid

Purpose To evaluate the optic nerve head parameters measured by confocal scanning laser (Heidelberg Retina Tomograph II) performing a multivariate analysis in order to obtain a logistic regression formula that allows to discriminate between normal and glaucomatous subjects.

Methods A total of 97 normal eyes and 94 glaucomatous eyes were enrolled in study. The criteria to define glaucoma were based on intraocular pressure and standard automated perimetry. Each patient underwent optic nerve head evaluation performed by means of confocal scanning laser Heidelberg Retina Tomograph (HRT II, Heidelberg Eye Explorer 1.3.0.0. software). Multivariate analysis (logistic regresion, stepwise algorythms) were applied to determine the multivariate functions that best discriminate presence of glaucomatous damage. The relative operating characteristic (ROC) curves were performed to assess the diagnostic value of each formula to discriminate the presence of glaucomatous damage.

Results Several discriminant functions that differentiated similarly between the groups were found. The best formula used rim area, cup-to-disc area ratio and cup shape measure. Applying the HRT discriminant function to our study population resulted in sensitivity and specificity of 80.9 % and 85.6 %, respectively.

Conclusion Several different discriminant functions are capable to discriminate the presence of glaucomatous damage in a comparable manner. The use of discriminant functions elaborated from autoctone population increases the diagnostic value of HRT functions to detect glaucoma damage in clinical practice.

■ 374

Optimum criteria for Optical Coherence Tomography (OCT) to detect Retinal Nerve Fiber Layer (RNFL) defects in glaucomatous eyes

POLO V, LARROSA JM, FERRERAS A, MAYORAL C, PUEYO V, MARTÍNEZ A, HONRUBIA FM
Ophthalmology, Zaragoza

Purpose To determine the optimum structural criteria that best discriminate between normal and glaucoma for Optical Coherence Tomography (OCT), based on the normative database.

Methods A total of 56 normal subjects and 42 glaucomatous patients were included in the study. Subject eyes were classified into diagnostic groups based on intraocular pressure, stereoscopic optic disc photographs and standard automated perimetry (SAP). Three 3.4 mm-diameter circular scans centered on the optic disc were obtained for each eye (OCT 3000; Humphrey Zeiss instruments). Segmental RNFL thickness values (quadrants and hour-positions) were evaluated for each eye to determine a normative database and the 95% and 99% limits of normalcy.

Results The best combination of sensitivity and specificity was the presence of 2 hour-positions outside the 95% limit (38.6% and 91.1%, respectively). The best combination at the 99% probability level was 2 hour-positions outside the normal probability limits (43.2% and 90.3%, respectively). If both probability levels were considered, the best criterion is 3 hour-positions outside normal limits. The sector-based analysis (retinal quadrants) that yielded best sensitivity-specificity results was the presence of one quadrant outside the 99% probability limit (50% and 94.6%, respectively).

Conclusion The optimum criterion to define glaucomatous abnormalities in Optical Coherence Tomography is the presence of 2 hour-positions outside the 95% limit or one retinal cuadrant outside the 95% limit.

■ 375

Optic Nerve Head Parameters in Normal, Ocular Hypertensive and Glaucomatous eyes measured by Confocal Scanning Laser Tomography (Heidelberg Retina Tomograph II)

POLO V (1), FERRERAS A (1), LARROSA JM (1), MAYORAL C (1), PUEYO V (1), ANTÓN A (2), HONRUBIA FM (1)
(1) Ophthalmology, Zaragoza
(2) Ophthalmology, Valladolid

Purpose To compare the optic nerve head parameters in normal, ocular hypertensive and glaucomatous eyes measured by confocal scanning laser (Heidelberg Retina Tomograph II).

Methods A total of 101 normal eyes, 247 ocular hypertensive eyes and 102 glaucomatous eyes were included in study. Subjects were classified into the 3 groups based on intraocular pressure and standard automated perimetry (SAP) performance. Every patient underwent complete ophthalmic examination (including clinical evaluation of the optic nerve), SAP, short-wavelength automated perimetry (SWAP) and confocal scanning laser ophthalmoscopy (HRT II, Heidelberg Eye Explorer 1.3.0.0. software).

Results There were statistically significant differences between normal and glaucomatous eyes in most optic nerve head parameters ($p<0.05$). Ocular hypertensive eyes showed a pronounced overlap of their optic nerve head parameters with respect to control and glaucoma groups. Nevertheless, when ocular hypertensives were segregated into different subsets of eyes based on clinical evaluation of the optic nerve head or SWAP performance, the ability to discriminate the presence of structural glaucoma damage significantly improved.

Conclusion HRT provides moderate discrimination between normal, ocular hypertensive and glaucoma subjects. The use of diagnostic tests to detect early glaucomatous damage (such as short-wavelength automated perimetry) in ocular hypertensive eyes improve the ability of HRT to discriminate glaucoma.

■ 376

Correlation between Standard Automated Perimetry Global Indices and Retinal Nerve Fiber Layer thickness measurements by means of Optical Coherence Tomography (OCT)

MAYORAL C, POLO V, FERRERAS A, LARROSA JM, PUEYO V, MARTÍNEZ A, HONRUBIA FM
Ophthalmology, Zaragoza

Purpose To correlate of retinal nerve fiber layer (RNFL) thickness measured by optical coherence tomography (OCT) with the perimetric indices of standard automated perimetry (SAP) in normal, glaucoma suspects and glaucomatous eyes.

Methods A total of 56 normal, 62 glaucoma suspects and 42 glaucomatous patients were included in the study. Subject eyes were classified into the diagnostic groups based on intraocular pressure, stereoscopic optic nerve photographs and Humphrey SAP performance. Three 3.4 mm-diameter circular scans centered on the optic disc were obtained for each eye (OCT 3000; Humphrey Zeiss instruments). Average and segmental RNFL thickness values (quadrants and hour-positions) were evaluated for each eye. Pearson correlations between RNFL thickness parameters and perimetric indices were performed.

Results In the global analysis of all the subjects, a significant correlation was found between the RNFL thickness parameters and the global indices of SAP. The RNFL global average thickness, the inferior retinal quadrant and the 7 hour-positions showed the strongest correlation with the visual field indices (0,575, 0,536 and 0,507, respectively). In the glaucoma subset of patients there had been a similar trend with stronger correlations for the global average, quadrants and hour-positions that involve the superior and inferior "poles" of the optic nerve. Normal and glaucoma suspects did not showed significant correlations.

Conclusion The correlations found between standard automated perimetry indices and OCT structural RNFL thickness parameters support the use of OCT to assess the structural damage in glaucoma.

EVER-2004-abstractbook.indd 80 8/19/04 12:26:20 PM

■ 377 / 2227

Clinical pathways in glaucoma elaborated by a new pupillographic test (patent pending)

KANDEL GL (1), KABACK M (2), SANCHEZ R (2)
(1) Bioinstco Lab Troy, New York
(2) Glaucoma Consultants Slingerlands, New York

Purpose To identify the clinical pathways disclosed by pupillary reflex perturbations examined with a new test of optic nerve function. (See ISOPT 2004).

Methods This test administers a fixed set of stimuli to each eye, and concurrently records the pupillary responses evoked by them with a binocular recording device. The stimuli produced by LEDs generate red, yellow, green or blue lights at two photopic levels to a central or a fixed peripheral visual location. The resulting direct and consensual reflexes for each eye are separately recorded. Using the differences in reflex amplitudes as indicators of optic nerve asymmetry, unique patterns of afferent optic neuropathy are postulated for several groups having the same clinical diagnosis. The patterns of a limited standardization group were studied by Discriminant Analysis.

Results The test correctly classified 90 % of the patient's eyes according to their prior categories of glaucoma, glaucoma suspect, family history of open angle glaucoma, retinal pathology or normal examination. The clinical pathways to glaucoma, consisting of a family history of open angle glaucoma, of glaucoma suspect associated with elevated intra ocular pressure and steroid sensitivity, and pseudo exfoliation, were identified.

Conclusion The test results, even with this small sample of patients seems unaffected by concurrent cataracts, surgical retraction of the iris during cataract extraction, or to iridectomy, and to the ocular co-morbidities of ARMD, diabetic retinopathy, central retinal vein occlusion, retinal tears, central serous retinopathy or to mild stroke affecting the brainstem or the parietal lobe. The test's high sensitivity and specificity make it a serious contender as a screening instrument for glaucoma and when suitably calibrated, as a means of assessing glaucoma progression.

■ 378

Hipotensive and neuroprotective effect of antiglaucomatous drugs in an experimental glaucoma model

URCOLA JH (1), RUIZ J (1), GARCIA M (1), HERNÁNDEZ M (1), ARAIZ J (2), DURÁN J (2), VECINO E (1)
(1) Cell biology and histology, University of the Basque Country, Vizcaya, Spain
(2) Ophthalmology, University of the Basque Country, Vizcaya, Spain

Purpose To compare the effect of two well-known antiglaucomatous drugs in an experimental rat glaucoma model.

Methods Elevation of intraocular pressure (IOP) was induced by cauterizing three episcleral veins in the left eyes. IOP was measured weekly using a Tonopen XL in awake animals. Three weeks after surgery, animals were distributed into three groups, which were treated as follows: 1) no treated, 2) 10 µl of latanoprost topically applied (daily). 3) 10 µl of latanoprost topically applied (daily) + 150 µl of brimonidine intraperitoneally applied (once per week). 4) 150 µl of brimonidine applied intraperitoneal (once per weeek). After 12 weeks retinal ganglion cells (RGCs) were retrogradely labeled with fluorogold and counted under a flluorescent microscope. ERG were performed before labeling RGCs.

Results IOP mean value was 21.7 mm Hg in unoperated eyes. After episcleral vein cauterization IOP was increased in untreated animals(34.9 mmHg). Latanoprost or latanoprost+brimonidine reduced the IOP in cauterized eyes (25.6 and 23.9 mmHg, respectively) whereas intraperitoneally applied brimonidine had not effect on reducing IOP mean value. On the other hand, episcleral vein cauterization led to a mean RGC loss of 27.02% in untreated experimental group, however no differences seemed to occur in the ERG of cauterized eyes. Analysis of RGC survival after each treatment was also performed.

Conclusion Episcleral vein cauterization leads to high rates of RGCs death and it is an appropiate experimental glaucoma model to compare different medical treatment and their effect on RGCs survival. Latanoprost is more effective than brimonidine to reduce the IOP increase in this experimental model.

■ 379

Scleral Patch Graft covered with Multilayer Amniotic Membrane Transplantation for the Management of the Conjunctival Erosion in the Implant Seton

FROMOW - GUERRA M, AYALA-FLORES M, ESPINOZA-NAVARRO J, ROMERO-CASTILLO L, GARCIDUENAS-MEJIA M
Glaucoma Department, Fundacion Hospital Nuestra Señora de la Luz, Mexico

Purpose To evaluate the efficiency of scleral patch graft and multilayer amniotic membrane transplantation (AMT) to cover the conjuntival erosion with exposure of the drainage device.

Methods A prospective, longitudinal, and experimental case serie was designed for patients who had been implanted with an Ahmed valve and presented conjunctival erosion with exposure of the drainage device. Scleral graft and multilayer AMT was used to cover the tube and their evolution was observed for a period of at least 6 months. The epithelialization of the amniotic membrane (AM) and the reincidence of the dehiscence was evaluated. The surgical technique consisted in exposing the area, removing celular detritus of the conjunctival defect . The scleral patch graft was placed and then the multilayer AMT AM2 from Sophia laboratories.

Results The evolution of the 5 eyes with AMT and scleral graft was observed. Postoperatively, 4 patients showed a complete integration, only one did not. In this patient the conjunctival defect was over the device, not in the tube. One patient showed melting with the other.

Conclusion AMT seems to be a successful procedure in the treatment of conjuntival dehiscence with exposure of the drainage device The amniotic membrane promotes epithelization and reduces at the same time inflammation, neovascularization and fibroid tissue. . A large number of patients need to be followed to prove this tendency.

■ 380

Under a Sealed Scleral Flap, Effect of Trabeculectomy and/or Sclerectomy on Outflow Facility in Perfused Pig Eyes

XU W, NI Y, SCHAARAWY T, HAEFLIGER IO
Laboratory of Ocular Pharmacology and Physiology, University Eye Clinic Basel, Basel, Switzerland

Purpose Under a Sealed Scleral Flap, Effect of Trabeculectomy and/or Sclerectomy on Outflow Facility in Perfused Pig Eyes.

Methods In perfused pig eyes, OF was calculated before surgery, after surgery with an open scleral flap, or after surgery with a sealed scleral flap (sutures + glue). Surgery consisted of: 1 x 1 mm trabeculectomy (group A), 1 mm para-limbal radial 1 x 2 mm sclerectomy (group B), 1 x 3 mm radial trabeculectomy and sclerectomy (group C), or no trabeculectomy or sclerectomy (group D). Time-control was also performed (group E). In other experiments, after anterior chamber perfusion with ink (300 min, 15 mmHg), ink diffusion from limbus was measured on the inner sclera side in regard to the scleral flap.

Results When compared before surgery, once the scleral flap was sealed, OF significantly increased only in groups B and C (from 0.30 ± 0.06 to 0.51 ± 0.08 µl/min/mmHg and from 0.23 ± 0.04 to 0.47 ± 0.06 µl/min/mmHg, respectively). In groups A - D, sealing the scleral flap significantly decreased OF. In comparison to group A (1.07 ± 0.40 mm), D (1.27 ± 0.55 mm), and E (1.47 ± 0.35 mm), dye diffused significantly more in groups B (7.40 ± 0.87 mm) and C (7.87 ± 1.52 mm).

Conclusion In perfused pig eyes, under a sealed scleral flap, sclerectomy (1 mm from the limbus) increases OF and scleral dye diffusion more than trabeculectomy. Furthermore, creating a limbal scleral flap appeared to increase OF.

EVER-2004-abstractbook.indd 81 8/19/04 12:26:21 PM

■ 381

G-probe use in cases with serious general state of patients (case report)

BUNIATYAN IY
Glaucoma, Ophthalmologic Centre n.a. S.V.Malayan, Yerevan

Purpose The aim of this report is to show the transscleral cyclophotocoagulation (TSCPC) with diode laser with G-probe as an effective method of neovascular glaucoma treatment especially in the cases when it is impossible to prescribe medicine or to do filtering surgery, because the general state of the patient is very serious. The TSCPC enables to keep eye as a cosmetic organ without pain syndrome.

Methods The patient 65 eyars old – diagnosis: OS – neovascular (postthrombotic) glaucoma "c", central retinal vein thrombosis.Visus OS = 0; TOS = 40 mm Hg. OS – severe pain syndrome (by VAS) in the left eyeand pain irradiation to the same part of the head (the patient doesn't have both kidneys, the pain syndrome increase during dyalisis); mixed ocular injection, corneal edema, anterior chamber of medium depth, agueous humor with inflammatory cells, rubeosis iridis, fixed pupil (5-6 mm), The patient is given a course of treatment – Sol. Timoptici 0.5%, Sol.Atropini 0.1%, Sol.Oftan-dexamethasoni 0.1% and general therapy. 28.12.01 the patient gets retrobulbar injection of alcohol. The patient's state remain severe. 10.01.02 the patient gets TSCPC with G- probe (local anesthesia – Sol.Lidocaini 2% - 6.0). Power 1500 mW, duration 1000msec, number of application 15.

Results The pain syndrome decrease the next day the state during dyalisis is normal. 1 month after cyclodestruction the pain syndrome reduces, TOS = 22 mm Hg (by Goldmann) and rubeosis iridis decrease. And 1 year and more – TOS = 15 mm Hg (by Goldmann) without pain syndrome and rubeosis.

Conclusion This case illustrates capabilities of TSCPC with G-probe in such cases.

■ 382

Usage of G-probe diode laser in treatment of neovascular glaucoma after vein thrombosis in caucasion patients

BUNIATYAN IY
Glaucoma, Ophthalmologic Centre n.a.S.V.Malayan, Yerevan

Purpose The aim of this report is to analize the results of contact transscleral cyclophotocoagulation (TSCPC) with G-probe diode laser in treatment of neovascular glaucoma (NVG) after vein thrombosis.

Methods Methods: 12 patients with NVG after thrombosis, out of which 50% are women and 50% are men aged from 58 to 76 underwent TSCPC diode laser. In all cases the pain syndrome was prevailing (by Visual Analog Scale). The average initial IOP level taken by Goldman's method was 40.17 mm Hg. All patients received preoperational treatment namely combination treatment for thrombosis, beta-blockers end carboanhydras inhibitors and Sol.Atropini 0.1% as instillation. The TSCPC was performed after retrobulbar injection of Sol.Lidocaini 2% - 3.0-4.0. The TSCPC was performed with IRIS OcuLight Diode Photocoagulator with G-probe, Medical Instruments, Inc, USA. The affecting power ranged from 1000 to 3000 mW, duration 600 – 1500 msec, average number of coagulants 22 depending on the IOP level and intensity of pain syndrome. After TSCPC the patient underwent instillations of steroids and antiinflammatory therapy.

Results Results: all patients responded to the treatment. The average observation is 32 months. All patients reported of disappeance of pain syndrome. The IOP level reduced, in 58.33 % to normal level (not more then 20 mmHg by Goldmann).

Conclusion Conclusion: treatment with G-probe diode laser is efficient method of treatment NVG after vein thrombosis leading to eliminate the pain syndrome, reduce the IOP level and keep the eye as organ.

■ 383

Selective laser trabeculoplasty vs argon laser trabeculoplasty in open angle glaucoma

CELLINI, BERNABINI B, LEONETTI P, CAMPOS EC
Surgical Science "A. Valsalva", Bologna

Purpose To compare the effectiveness in lowering the intraocular pressure and the anterior chamber reaction after selective laser trabeculoplasty (SLT) or argon laser trabeculosplasty (ALT).

Methods Thirty patients aged from 42 to 73 were randomised to treatment with either SLT or ALT. SLT was performed by a 532 nm Nd:YAG laser and ALT by a 532 nm argon laser. Before laser trabeculoplasty we perfomed an evaluation of anterior chamber cellularity with a flare-cell meter (Kowa 500). ALT was performed using 50 applications of 50 µm, 0.1 msec. duration and a power ranged from 450 mW to 620 mW (mean 513.333±48.990). SLT was performed using 50 spots with a size of 400 µm, pulse duration of 3 ns and a power ranged from 0.400 to 0.700 (mean 0.572±0.115). One day after we performed a flare cell meter evaluation. Intraocular pressure was evaluated one day, one week, one and three months after.

Results We treated 24 eyes in each group. Baseline the IOP in the SLT group and in ALT group was 23.263±2.600 mm/Hg vs 22.632±2.967 mm/Hg ($p<0.459$) the day after treatment we found 18.705±2.800 mm/Hg vs 19.633±2.780 mm/Hg ($p<0.430$). One month later 16.713±2.100 mm/Hg vs 17.650±2.600 mm/Hg ($p<0.390$) and after three months 14.842±2.167 mm/Hg vs 16.053±2.223 mm/Hg ($p<0.317$). The baseline anterior chamber flare-cell in SLT and ALT was 4.600±1.405 photons/ms vs 6.311±3.416 photons/ms ($p<0.169$) and the day after treatment was 5.960±0.983 photons/ms vs 13.289±2.153 photons/ms ($p<0.027$).

Conclusion SLT appears to be statistically equivalent to ALT in lowering IOP during the first three months after treatment even if the SLT patients have a greater drop in IOP. We found a lower anterior chamber reaction one day after SLT.

■ 384

Simultaneous bilateral trabeculectomy

GUTIERREZ CG, TELIS MT
Alcala de Henares Hospital, Alcala de Henares

Purpose To evaluate the results of bilateral simultaneous trabeculectomy under local or general anesthesia.

Methods Design: Retrospective study.Participants: 188 eyes from 94 patients who underwent bilateral simultaneous trabeculectomy , with at least 6 months of follow-up. Intervention: Bilateral simultaneous trabeculectomy . Mitomycin C was used adjunctively in 28 eyes of 14 patients.Main Outcome Measures: Preoperative and postoperative intraocular pressure (IOP), the number of glaucoma medications, visual acuity (VA) and complications were recordered at each follow-up examination.

Results Mean preoperative Best Corrected Visual Acuity (BCVA) was 20/50. Mean postoperatively BCVA was 20/100 at one week, , 20/63 at one month and 20/50 again at the final visit which was between 6 and 12 months. Both intra and postoperative complications were rare. The most frequent bilateral complications were hyphema in 3 patients(3.19%); mild uveitis in 8 (8.51%); choroidal detachment in 2 (2.12%); shallow anterior chamber in 7 (7.44%), cataract in 2 (2.12%) and hypotony in 4 (4.25%)(These complications should be listed in order from most to least frequent.). Bilateral delayed complications were not seen.

Conclusion We found a low rate of postoperative complications following simultaneous bilateral trabeculectomy. In situations where it is difficult for the patient to undergo bilateral trabeculectomy at different times, bilateral simultaneous trabeculectomy should be considered.

EVER-2004-abstractbook.indd 82 8/19/04 12:26:21 PM

385 / 3437

Therapeutic Applications of Contact Lenses in Myopia Control

MAHOMED A (1, 2), PUNYAMOONWONGSA P (1, 2), TIGHE B (1, 3)
(1) Biomaterials Research Unit, CEAC
(2) Aston University, Birmingham UK
(3) Aston Univeristy, Birmingham UK

Purpose Pirenzepine has attracted recent interest in the control of myopia. This poster examines the potential of using micellar phosholipid-based nanostructures ("Astosomes") to incorporate pirenzepine in order to improve the bioavailability and the therapeutic efficacy of the drug when delivered from a contact lens and to determine whether pirenzepine can be incorporated without disrupting the phospholipid assembly.

Methods Monolayers of Astosome-pirenzepine complexes were studied using a Langmuir-Blodgett Trough. The complexes were incorporated into a range of hydrogel compositions.

Results The incorporation of 0.5% pirenzepine into astosome nanoparticles does not cause a remarkable change in the shape of surface pressure-area (A-A) isotherm but increasing of the percent of drug to 1.0% does cause the isotherm to shift to larger areas, indicating that the pirenzepine incorporated inside astosome nanoparticles increases the size of this nanostructure formulation. The cross-sectional molecular area of monolayer of astosome loaded with 1.0% pirenzepine was found to be 20% greater than that of 0.5% pirenzepine. The information was used in the design ofhydrogel release systems.

Conclusion The incorporation of pirenzepine into Astosome formulations produces nanostructures of sub-liposomal dimensions and it is logical to use this approach to improve the bioavailability and the therapeutic efficacy of pirenzepine and other ophthalmic drugs using contact lenses as a delivery device.

386 / 3438

Comparison of early and middle-term microscopic morphological corneal response after PRK, LASEK and alcohol-free LASEK

NUBILE M, LANZINI M, COSTANTINO O, MASTROPASQUA L
Ophthalmic Clinic, University "G.d'Annunzio" Chieti-Pescara, Chieti, Italy

Purpose To compare the early wound-healing and inflammatory response after PRK, standard LASEK, and alcohol-free LASEK by means of confocal microscopy.

Methods 90 eyes of 90 patients were randomly assigned to 3 myopic treatment groups. 30 eyes were treated with PRK, 30 eyes underwent standard LASEK, and 30 eyes underwent alcohol-free LASEK. Confocal microscopy examination was performed by using Confoscan 3 at the baseline, 30', 24 hours, 3,7,15 days, and 1 months postoperatively.

Results At 30' after ablation a superficial acellular layer was visible in all patients without differences in reflectivity and thickness within groups. PRK group showed activated keratocytes as main cell type responsible for repopulation. In LASEK and alcohol-free LASEK groups, both activated keratocytes and inflammatory cells repopulated the acellular layer in the first week. The mean value of inflammatory cell density at day 1 and 3 however showed significant differences ($p<0,01$) between standard and alcohol-free technique (310 ± 66 cell/mm2 and 68 ± 25 cell/mm2, respectively). Epithelial flap was visible in the early postoperative period up to 3 days in both LASEK groups, appearing less damaged in the alcohol-free LASEK group. 15 and 30 days examinations showed in all groups a clear anterior stroma with tendency of keratocyte repopulation with no haze. Keratocyte density and reflectivity of the anterior stroma did not show difference between groups.

Conclusion Epithelial damaging of the LASEK flap due to alcohol exposure could explain the greater inflammatory induction within the anterior stroma. In the middle-term postoperative period no differences in transparency and cellularity among the groups were observed.

EVER-2004-abstractbook.indd 83 8/19/04 12:26:22 PM

Patient-oriented scientific reports covering all aspects of ophthalmology



Ophthalmologica

International Journal of Ophthalmology

Managing Editor
Ch. Ohrloff, *Frankfurt a.M.*

Associate Editors
Y. Honda, *Osaka*
P. Kroll, *Marburg*
E. Lütjen-Drecoll, *Erlangen*
D. Mojon, *St. Gallen*
G. Plant, *London*
F.H. Stefani, *München*
R.L.S. Yeoh, *Singapore*

Published since 1899, 'Ophthalmologica' has become a frequently cited guide to international work in clinical and experimental ophthalmology. Focused on practical problems, it contains a selection of patient-oriented reports covering the etiology of eye diseases, diagnostic techniques, and advances in medical and surgical treatment. Straightforward, factual reporting provides both interesting and useful reading. In addition to original papers, 'Ophthalmologica' features book reviews and a section headed 'Clinicopathologic Case Report'. The large international circulation of this journal reflects the importance of its practical function.

Selected contributions

Clinical Effects of the Nd:YAG Laser Operating in the Photodisruptive and Thermal Modes. A Review: ***Fankhauser, F.; Kwasniewska, S.*** *(Bern)*

Low Specificity of Scanning Laser Polarimetry: ***Mojon, D.S.*** *(St. Gallen)*

Detection of CMV DNA in the Aqueous Humor of AIDS Patients with CMV Retinitis by AMPLICOR CMV Test: ***Yamamoto, N.*** *(Tsukuba-shi/Tokyo);* ***Wakabayashi, T.*** *(Tsukuba-shi);* ***Murakami, K.*** *(Tokyo);* ***Hommura, S.*** *(Tsukuba-shi)*

Biomolecular Markers of Malignancy in Human Uveal Melanoma: The Role of the Cadherin-Catenin Complex and Gene Expression Profiling: ***Conway, R.M.*** *(Sydney);* ***Cursiefen, C.; Behrens, J.; Naumann, G.O.H.; Holbach, L.M.*** *(Erlangen)*

Variance between Program Versions in Measuring Optic Nerve Fiber Layer Thickness Using Optical Coherence Tomography: ***Furuichi, M.; Kashiwagi, K.; Tsukahara, S.*** *(Yamanashi)*

Ocular Blood Flow in Healthy and Primary Open-Angle Glaucomatous Eyes: ***Birinci, H.; Danacı, M.; Öge, I.; Erkan, N.D.*** *(Samsun)*

Efficacy of Latanoprost Additive Therapy on Uncontrolled Glaucoma: ***Bayer, A.; Tas, A.; Sobacı, G.*** *(Etlik);* ***Henderer, J.D.*** *(Phildelphia, Pa.)*

Corticosteroids in Ophthalmology: Past – Present – Future: ***Sherif, Z.; Pleyer, U.*** *(Berlin)*

Invitation for papers

Only original papers written in English will be considered.

Manuscripts should be sent to:

S. Karger AG
Editorial Office 'Ophthalmologica'
P.O. Box
CH–4009 Basel (Switzerland)

Read it online:
www.karger.com/oph

Ophthalmologica
2004: Volume 218
6 issues per volume
Language: English
ISSN 0030–3755
ISSN Online 1423–0267

Listed in bibliographic services, including *Current Contents®, Index Medicus, Reference Update, Biological Abstracts, EMBASE/Excerpta Medica.*

	Online	Print		Print/Online combined
Personal rates per year	**Subscription**	**Subscription**	Postage and handling added to print and print/online	**Subscription**
	CHF 617.–	CHF 617.–	CHF 31.80 (Europe) CHF 47.10 (Overseas)	CHF 658.–
	EUR 457.–	EUR 457.–	EUR 22.80	EUR 487.–
	USD 493.50	USD 493.50	USD 31.80	USD 526.50

Please enquire about institutional rates and reduced rates for members of the: Schweizerische Ophthalmologische Gesellschaft; Netherlands Ophthalmologic Society; ARVO; EVER

Airmail surcharge per year: CHF 39.60 / USD 33.00
Prices subject to change
EUR price for Germany, USD price for USA only

KF 04060

KARGER

ORAL PRESENTATIONS

EVER 2004

September 24-27, 2004
Vilamoura, Portugal

EVER-2004-abstractbook.indd 85 8/19/04 12:26:26 PM

■ 1111

HLA-B35 antigen is associated with susceptibility to ocular opportunistic infections in patients with aids

VERONESE RODRIGUES ML (1), GARDIM DEMARCO AL (2), FIGUEIREDO JFC (3), SOUZA NV (1), PAULA JS (1), ROMÃO E (1), DONADI EA (4)
(1) Ophthalmology, Otolaringology and Head and Neck Surgery - Faculty of Medicine of Ribeirão Preto, University of São Paulo, Ribeirão Preto
(2) Ophthalmology - University Hospital, São José do Rio Preto
(3) Internal Medicine/Infectious Diseases - Faculty of Medicine of Ribeirão Preto, University of São Paulo, Ribeirão Preto
(4) Internal Medicine/Immunology - Faculty of Medicine of Ribeirão Preto, University of São Paulo, Ribeirão Preto

Purpose We have previously reported that HLA-A31 was over represented in AIDS patients presenting or not cytomegalovirus retinitis (CMV-R) and, also that the HLA-B35 was over represented in patients with Toxoplasma gondii chorioretinitis (Tg-CR). To evaluate similarities and dissimilarities in HLA profile in AIDS patients with ocular infections, we compared HLA class I antigen frequency in patients with CMV-R and in patients with Tg-CR.

Methods A total of 110 patients were studied, 42 presented CMV-R, 25 exhibited Tg-CR, and 43 patients presented AIDS with positive serology for Toxoplasma gondii, but without retinitis or chorioretinitis (Ab-Tg). HLA class I antigens were typed using a complement-dependent microlymphocytotoxicity assay. Statistical analysis was performed using chi square test, with Yates correction.

Results The frequency of HLA-A31 antigen in CMV-R or Tg-CR was closely similar that observed for Ab-Tg patients. HLA-B35 antigen was significantly over represented in Tg-R (44%, p= 0.01, OR= 4.85) and CMV-R (35%, p= 0.03, OR= 3.43) patients in relation to Ab-Tg patients (13.9%). When the groups CMV-R and TgCR were considered as a whole the frequency of HLA-B35 antigen was also significantly increased in relation to Ab-Tg (38,8%, p= 0.009, OR= 3.91). In contrast, the comparison of HLA-35 antigen frequency between patients with CMV-R with those with Tg-CR showed no significant difference.

Conclusion The results indicate that HLA-35, in addition to its role in the development of AIDS, may be a shared susceptibility antigen in the development of Tg-CR and CMV-R.

■ 1112

Antigen presentation in a retina

YAMAKI K, HARA K, KAMAYA S
Ophthalmology, Akita University School Of Medicine, Akita

Purpose To identify the possibility of antigen presentation in a retina, we studied the expression of various cytokines and cell surface molecules in the retina by Reverse Transcription-Polymerase Chain Reaction (RT-PCR).

Methods Lipopolysaccharide (LPS) or inactivated Bordetella pertussis (BP) was injected into a vitreous cavity of C57BL/6J mice. The retina was collected 3, 6 and 24 hours after the injection. Expression of MHC class II, CD11c, CD80, CD86, toll-like receptor (TLR) 4, TLR9, IL-12p35, IL-2, IFN-γ, IL-4, IL-5, IL-6, IL-10, IL-1β, TNF-α and TGF-β mRNA were analyzed by semi-quantitative RT-PCR.

Results Expression of MHC class II, CD11c, CD80, CD86, TLR4 and TLR9 mRNA were found in untreated retina. The amount of expression of MHC class II, CD11c, CD80 and CD86 increased after the injection of both LPS and BP. The expression of TLR4 mRNA increased by injection of only LPS and TLR9 increased by injection of both BP and LPS respectively. The expression of cytokines, IL-12p35, IL-2, IFN-γ, IL-4, IL-5, IL-6, IL-10, IL-1β, TNF-α and TGF-β increased by the injection of LPS or BP. The time course study for the expression of cytokines mRNA showed that the peak was 3 hours after injection and then the expression subsided gradually.

Conclusion These results revealed that proinflammatory cytokines related to antigen presentation were upregulated by a stimulation of TLR4 and TLR9 in retina. It was suggested that acquired immunity starting from the antigen presentation take a place after innate immunity reactions in a retina also.

■ 1113

15 PGJ2 inhibit interferon gamma induction of MHC class II on RPE cells through a PPAR gamma and a CIITA independent mechanism

WILLERMAIN F (1, 2), CABAY L (1), DULKU S (2), BLERO D (2), DRIESSENS G (2), DE GRAEF C (2), MIOT F (2), SUAREZ N (2), VELU T (2), CASPERS L (1), BRUYNS C (2)
(1) Dpt of Ophthalmology, CHU St-Pierre, Brussels
(2) I.R.I.B.H.M, Campus Erasme, Brussels

Purpose Since MHC class II expression by RPE cells is important in uveitis development, we investigate the effects of 15-deoxy-delta 12,14-prostaglandin J2 (15 PGJ2) on the induction of MHC class II by interferon γ (IFNγ) on RPE cells

Methods Effect of 15 PGJ2, rosiglitazone, troglitazone and pharmacologic inhibitors on the basal and IFNγ mediated expression of MHC class II, MHC class I and CD54 on ARPE cells (a RPE cell line) were investigated by flow cytometry. PPARγ expression, phosphorylation of STAT, ERK1/2, p38 and protein kinase B (PKB) were tested by western blot. Expression of Class II transactivator (CIITA), SOCS 1 and IRF1/2 were investigated by RT-PCR

Results 15 PGJ2 but not rosiglitazone or troglitazone inhibited MHC class II induction by IFNγ. MHC class I and CD54 expression were unaffected. PPAR gamma was expressed by ARPE cells, but effect of 15 PGJ2 were not change by co-incubation with PPAR gamma antagonists. 15 PGJ2 did not modulate STAT phosphorylation or SOCS 1 induction. Ly and SB203580 (10 μM) inhibited MHC class II induction by IFNγ. 15 PGJ2 did not modulate PKB, ERK1/2 or PKB activity, nor the expression of CIITA, , IRF1 and IRF2

Conclusion 15 PGJ2 inhibited MHC class II induction by IFNγ on ARPE cells. This effect was not PPAR gamma mediated and did not involve SOCS nor CIITA modulation.

■ 1114

CCL-5 (RANTES) Chemokine promoter gene Polymorphism and need for immunosuppressant agents in posterior uveitis

MISSOTTEN T (1), AHAD M (1, 2), ABDALLAH A (3), LYMPANY P (3), MENEZO V (1, 2), KUO NW (1, 2), LIGHTMAN S (1, 2)
(1) Moorfields Eye Hospital, London
(2) Institute of Ophthalmology, London
(3) Dept. Clinical Genomics, Institute of Heart and Lung diseases, Imp.College, London

Purpose CCL-5 (RANTES) is an important chemoattractant for T-cells and other leucocytes. Production of RANTES is genetically controlled: adenine and guanine at the site –403 in the promoter region are associated with high and low production of RANTES respectively. At site -28 guanine and cytosine are also correlated with high and low RANTES production. The aim of this study was to determine the correlation between the RANTES promoter polymorphisms (-403 A to G; -28 G to C) and the need for immunosuppressant agents in non-infectious posterior uveitis.

Methods 55 patients with non-infectious uveitis were phenotyped and divided into intermediate and posterior uveitis. Total genomic DNA from peripheral citrated blood was extracted and RANTES (-403 and -28) promoter polymorphisms were identified using PCR.

Results There was significant less of the RANTES (-28) C/C genotype in patients who needed steroids and a second-line immunosuppressant agent in order to control inflammation (p=0.026). Patients with the (-403) G/G genotype needed less systemic steroids (p= 0.011), and needed less anti-glaucomatous medication (p=0.014). Compared with the other genotypes, patients with the high production of RANTES related (-403) A/A and (-28) G/G genotypes did not have a worse visual outcome (p= 0.5 and 0.863 resp.)

Conclusion In this preliminary study we found that the RANTES (-403) and (-28) promoter polymorphisms are significantly associated with the need for more systemic and 2nd line immunosuppressant agents to preserve visual function in chronic posterior uveitis. Genetic variations of this chemokine may contribute to the variability of the inflammatory process in patients with posterior uveitis.

EVER-2004-abstractbook.indd 86 8/19/04 12:26:26 PM

1115

CCR-5 Chemokine receptor gene Polymorphism and severe outcome in posterior uveitis

MISSOTTEN T (1), AHAD M (1, 2), ABDALLAH A (3), MENEZO V (1, 2), KUO NW (1, 2), LYMPANY P (3), LIGHTMAN S (1, 2)
(1) Moorfields Eye Hospital, London
(2) Institute of Ophthalmology, London
(3) Dept. Clinical Genomics, Institute of Heart and Lung diseases, Imp.College, London

Purpose CCR-5 is a Th1-associated CC-chemokine receptor that binds MIP-1α, MIP-1β and RANTES. Production of CCR-5 is genetically controlled : adenine and guanine at the site –59029 in the promoter region are associated with high and low production of CCR-5 respectively. CCR-5 production is reported to be positively associated with more severe inflammation, and CCR-5 antagonists are being developed. The aim of this study was to determine the correlation between the CCR-5 promoter polymorphism (-59029 A →G) and the outcome of patients with non-infectious posterior uveitis.

Methods 55 patients with non-infectious uveitis were phenotyped and divided into intermediate and posterior uveitis. Total genomic DNA from peripheral citrated blood was extracted and CCR-5 (-59029) promoter polymorphism identified using PCR.

Results Patients with the CCR-5 (-59029) A/A genotype (more CCR-5 expression) had a significantly better visual outcome (p= 0.013) and needed less 2nd line immunosuppressant agents to achieve disease control (p=0.001). They did not need higher amounts of systemic steroids (p=0.855). However they developed more steroid related intra-ocular pressure problems (p=0.026).

Conclusion In this preliminary study we found that the A/A CCR-5 (-59029) promoter polymorphism is associated with improved disease outcome in patients with a chronic posterior uveitis. In contrast to earlier reported inflammatory processes the A/A genotype that favours CCR-5 production seems to have a protective effect in posterior uveitis. Genetic variations in the promoter region of this CC-chemokine receptor may be a factor in disease variability in patients with posterior uveitis.

EVER-2004-abstractbook.indd 87 8/19/04 12:26:27 PM

■ 1121

Modulation of retinal vascular diameter and choroidal blood flow in vasospastics

ZAWINKA C, ORGUL S, REINHARD G, BRANKA F, FLAMMER J
Ophthalmology, University Basel, Basel

Purpose The etiology of the primary vasospastic syndrome is not known. It has been shown previously that hyperglycemia increases ocular blood flow in humans. In the present study, we investigated the effect of fasting blood glucose levels on ocular hemodynamics in otherwise healthy vasospastic subjects compared to non-vasospastic controls.

Methods In this randomized, 2 way cross-over study 15 subjects were included. They were classified as vasospastic (n=7) by history of frequent cold hands. Aspartam and an oral glucose tolerance test as control experiment (OGTT) were administered on two study days. Blood glucose levels and ocular hemodynamics (choroidal blood flow and retinal vessel diameter) were measured at baseline and 120min after intake of the test substance.

Results Blood glucose level decreased significantly vs. baseline in both groups on aspartam (p=0.000001), compared to the relative stability 2 hours after OGTT (p=0.22). Choroidal blood flow response was significantly different after intake of the two test substances (p=0.028). Choroidal blood flow remained stable after glucose intake (p=0.51), but decreased under aspartam (p=0.03) in both groups. Retinal arterial diameter remained relatively stable, while venous diameter tended to decrease under aspartam in vasospastics, but not significantly. The arterio-venous diameter quotient increased significantly vs. baseline after aspartam intake in the vasospastic group when compared to normals (p=0.0332).

Conclusion While both groups showed a decrease in choroidal blood flow under short-term fasting conditions, only vasospastic subjects showed a vascular alteration in the retinal vascular bed. The reason for this response in this specific group of subjects remains yet to be clarified.

■ 1122

Role of NO in the control of choroidal blood flow during a decrease in ocular perfusion pressure

POLSKA E, LUNG S, SIMADER C, WEIGERT G, KOLODJASCHNA J, SCHMETTERER L
Clinical Pharmacology, Vienna

Purpose There is evidence from several recent studies that the human choroid maintains its blood flow despite moderate reductions in perfusion pressure. The mechanisms behind choroidal autoregulation are, however, yet to be elucidated. The aim of the present study was to investigate whether NO plays a role in choroidal autoregulation during a decrease in ocular perfusion pressure.

Methods To test this hypothesis we performed a randomized, double-masked, placebo-controlled, three way cross over study in 14 healthy male volunteers. Subjects received on different study days intravenous infusions of the NO-synthase inhibitor NG-monomethyl-L-Arginin (L-NMMA), the α-receptor agonist phenylephrine or placebo. The decrease in ocular perfusion pressure was achieved by artificial increase in intraocular pressure using suction cup method. Choroidal blood flow was assessed with laser Doppler flowmetry. Ocular perfusion pressure (OPP) was calculated from mean arterial pressure and intraocular pressure.

Results L-NMMA and phenylephrine increased resting OPP by 15% and 12%, respectively, but only L-NMMA reduced resting choroidal blood flow (-13%). The relative decrease in OPP during stepwise increase in intraocular pressure with a suction cup was comparable with all drugs administered. None of the drugs modified the choroidal pressure/flow relationship during this increase in IOP.

Conclusion The present study confirms previously published observations that the choroid shows some regulatory capacity. Our data indicate that choroidal autoregulation during decrease in OPP is not altered by NO-synthase inhibition.

■ 1123

Effects of Timolol and Dorzolamide on Ocular Blood Flow in Patients with Open Angle Glaucoma and Ocular Hypertension

FUCHSJÄGER-MAYRL G (1, 2), RAINER G (2), WALLY B (1), AMOAKO MENSAH T (1), GEORGOPOULOS M (2), VASS C (2), SCHMETTERER L (1, 3)
(1) Clinical Pharmacology, Vienna
(2) Ophthalmology, Vienna
(3) Medical Physics, Vienna

Purpose There is evidence from previous studies that topical dorzolamide may improve ocular blood flow in glaucoma. However, most of the currently available data arise from studies with only a small number of patients included. We set out to investigate the effects of timolol versus dorzolamide in a larger number of primary open angle glaucoma (POAG) and ocular hypertensive (OHT) patients.

Methods In 140 patients with either POAG or OHT the effect of a 6 months treatment period of dorzolamide versus timolol on ocular hemodynamic parameters was studied. The design of the trial was randomized (1:1), double- masked in two parallel groups. Blood flow in the rim (RimBF) and the cup (CupBF) of the optic nerve head were measured with scanning laser Doppler flowmetry. Pulsatile choroidal blood flow was assessed with laser interferometric measurement of fundus pulsation amplitude (FPA).

Results All outcome parameters were comparable between groups at baseline. Both, dorzolamide and timolol reduced intraocular pressure to a comparable degree. However, dorzolamide, but not timolol increased RimBF (8.5±12.0%; p=0.0002 versus timolol), CupBF (13.5±18.2%; p=0.0002 versus timolol) and FPA (8.9±9.2%; p<0.0001 versus timolol).

Conclusion Our data indicate that dorzolamide increases optic nerve head and choroidal blood flow in patients with POAG or OHT. Whether this means that dorzolamide is superior to timolol in preserving the visual field in glaucoma patients remains to be established.

■ 1124

Does retinal venous vessel response depend on temporal frequency of chromatic flicker application?

LANZL I (1), MUECKE B (1), VILSER W (2), KOTLIAR K (1)
(1) Eye Clinic, Technical University, Munich
(2) Biomedical Engineering, Technical University, Ilmenau

Purpose Exposing the retina to flickering light is followed by retinal vessel dilation. The venous response to green-blue and green-red flickering light with different exposure frequency is examined.

Methods In 10 young, healthy volunteers retinal venous diameters were assessed by Retinal Vessel Analyzer (RVA). Baseline measurement was performed for 1,5 min. Flicker light alternating between red (600 - 720 nm) - green (530 - 570 nm) or blue (430 - 520 nm) - green (530 - 570 nm) and a frequency of 2, 6, 12, 16 or 20 Hz was applied for 30 sec. Experiments were repeated at least 3 times. The experiment using 12 Hz stimulation was repeated after 1 week in the same volunteers.

Results With both tested flicker set-ups a prompt dilation of retinal veins compared to baseline could be found in all volunteers (p<0,001). With red-green flicker this amounted to 2,1+/-0,9% at 2 Hz; to 3,1+/-1,1% at 6 Hz; to 3,9+/-1,4% at 12 Hz; to 3,2+/-1,2% at 16 Hz and to 2,0+/-1,1% at 20 Hz. With blue-green flicker we found a dilation of 1,9+/-1,1% at 2 Hz, of 2,8+/-1,2% at 6 Hz; of 3,8+/-1,1% at 12 Hz; of 3,0+/-1,3% at 16 Hz and of 1,9+/-0,8% at 20 Hz. The repeat experiment showed no statistical difference to the first series (p>0,2).

Conclusion Flickering light of 30 sec leads to a prompt and reproducible vessel dilation of retinal veins. An increase in magnitude of dilation could be noted with increased stimulus frequency from 2 Hz to 12 Hz. The maximal dilation amplitude decreases if the stimulus frequency increases further. We think, that application of a 12 Hz flicker stimulus constitutes a feasible basis for examinations of retinal vessel behavior, with satisfactory dilation magnitude and low patient inconvenience.

EVER-2004-abstractbook.indd 88 8/19/04 12:26:27 PM

■ 1125

Short time increase of intraocular pressure does not alter the response of retinal veins to diffuse luminance flicker

GARHOFER G (1, 2), RESCH H (1), WEIGERT G (1), SIMADER C (1, 2), SCHMETTERER L (1, 3)
(1) Department of Clinical Pharmacology, Vienna
(2) Department of Ophthalmology, Vienna
(3) Insitute of Medical Physics, Vienna

Purpose It has been shown that stimulation with diffuse luminance flicker induces vasodilatation in the human retina. In the current study we set out to investigate the influence of a short time increase of intraocular pressure (IOP) on flicker light induced vasodilatation.

Methods In a group of 10 healthy volunteers IOP was increased using the episcleral suction-cup technique. Flicker responses of retinal veins were assessed using a retinal vessel analyzer, which was modified in order to allow for measurements during flicker light stimulation. Flicker responses were determined at baseline conditions and after suction of 70 mmHg and 140 mmHg. Each suction level was be maintained for 3 minutes during which retinal vessel diameters were measured and flicker stimuli were applied. Flicker light consisted of square wave light flashes at a wavelength below 550nm and produced a retinal irradiance of 140µW/cm2. Stimulation frequency was 8Hz.

Results Suction increased IOP from 12±2 to 27±4 and 43±4 mmHg, respectively. Retinal venous diameters decreased by −1.4±1.4% and −2.2±2.5% (each $p<0.05$) after suction. Stimulation with flickering light induced a vasodilatation of 2.0±1.0% ($p<0.05$) at baseline conditions. At a IOP of 27 and 43 mmHg, flicker responses were not significantly different compared to those recorded at baseline IOP. (2.9±2.5% and 2.4±2.4%).

Conclusion Short time increase of IOP does not alter the flicker response of retinal veins to diffuse luminance flicker.

■ 1126 / 232

Local retinal venous reaction to moderate artificial IOP increase in normals and glaucoma patients

KOTLIAR K (1), NAGEL E (2), VILSER W (3), LANZL I (1)
(1) Eye Clinic, Technical University, Munich
(2) Eye Consultant, Rudolstadt
(3) Biomedical Engineering, Technical University, Ilmenau

Purpose The Retinal Vessel Analyzer (RVA) measures temporal and spatial retinal vessel reactions in response to stimuli in real time. Local reactions to moderate artificial intraocular pressure (IOP) increase in retinal veins are investigated in healthy subjects and glaucoma (POAG) patients.

Methods 14 untreated POAG patients (61,2+/-7,6 years, IOP 22,4 +/-6,0 mmHg) and 13 healthy volunteers (62,6+/-6,7 years, IOP 13,8+/-2,9 mmHg) were examined. After baseline assessment for 2 min IOP was moderately increased for 100 s by suction cup. Diameter changes of retinal veins were measured along a 1 mm segment. Local vessel behaviour was analyzed.

Results At baseline no significant difference was found in spectral edge frequency of the power spectrum (SEF) between normals (0,112+/-0,042) and POAG patients (0,108+/-0,035) ($p>0,3$). During IOP provocation venous diameter decrease was observed in all cases. No significant difference in SEF between normals (0,128+/-0,039) and glaucoma patients (0,135+/-0,045; $p>0,2$) was found. No significant difference in SEF values was found between the groups during reactive dilation after provocation ($p>0,3$): normals: 0,114+/-0,026; glaucoma: 0,106+/-0,039.

Conclusion SEF is an expression for the frequency in amplitude change of vessel width along a vessel segment which we termed "vessel thickness change frequency" (VTCF). We found no significant difference in VTCF between normals and glaucoma patients here. In an earlier study using short term suprasystolic IOP provocation we found significantly higher VTCF in glaucomatous arteries during reactive dilation phase but not in veins. Local retinal venous behaviour in normals as well as in glaucoma patients seems not to be affected by IOP-peaks.

■ 1127 / 233

The assessment of conjunctival hyperemia with latanoprost 0.005% versus travoprost 0.004% therapy

SIEGEL LI (1), SAROLI TL (1), JENKINS JN (2), STEWART WC (2, 3), PRZYDRYGA JT (4)
(1) Glaucoma Center of Michigan, Southfield, MI
(2) Pharmaceutical Research Network, Charleston, SC
(3) Carolina Eye Institute at USC School of Medicine, Columbia, SC
(4) Alcon Laboratories, Fort Worth, TX

Purpose To evaluate if physicians could determine, by the amount of ocular hyperemia, if a patient was instilling latanoprost 0.005% or travoprost 0.004% after previous treatment with latanoprost. The hypothesis: pretreatment with latanoprost will minimize any potential ocular hyperemia increase observed with travoprost.

Methods Twenty patients who were undergoing latanoprost therapy were randomized at the first visit to either latanoprost or travoprost treatment in a double-masked fashion for eight weeks. At the second visit the attending physician guessed which medicine the patient was administering. As an additional control, a different off-site physician randomly guessed the patient treatment.

Results The 10 latanoprost patients had a mean baseline hyperemia scale (graded 0-3) of 0.2 in both eyes that increased to 0.4 in both eyes on the second visit ($P > 0.05$). The eight travoprost patients had a baseline hyperemia scale of 0 in both eyes that increased to 0.6 in the left eye and 0.7 in the right eye on the second visit ($P > 0.05$). The on-site physician correctly deduced the therapeutic agent in five patients (50%) for latanoprost and in five patients (63%) for travoprost. The off-site physicians correctly guessed the glaucoma medication 50% of the time for both treatment groups.

Conclusion This pilot study suggests that following prior treatment with latanoprost a physician may not be able to clinically distinguish (on the basis of hyperemia) if a patient is currently on latanoprost or travoprost therapy.

■ 1128 / 234

Volume of hypotensive eyedrops: Potential influence factors

ANTON LOPEZ AAL, MARTIN MARTIN BMM, BLAZQUIEZ ARAUZO FBA
Ioba, Valladolid

Purpose To asses the drop volume, its variability and the factors that could influence on the drop volume of the different commercial glaucoma eyedrops available in Spain.

Methods 10 of 14 commercial hypotensive eyedrops were examined. Drop volume was calculated using an avg. density. Every drop was expelled in the same conditions: room Temp., handling angle, and expelling technique. Variability of the drop volume was calculated in different situations: intrabottle (same drug: same and different shipment), intrabottle at different usage moment (out of the box, middle, almost empty), interbottle (same and different drug). Variance and variation coefficient were calculated to evaluate variability. To assess any nozzle design influence scaled photographs were taken. The influence of the drug solution's properties was evaluated replacing it with water.

Results Drop volume varied between drug brands (22.26µl-37.35µl). Variability between brands was approximately 15 times greater than the one attributable to differences within the same brand. Different shipments and usage moments didn't offer significant variability. In all cases water drop volume was larger than drug drop volume (20% - 90%) and varied between bottles of different brand (34.28µl - 55.01µl). 50% of the brands offered more variability, 30% offered less variability and 20% didn´t offer any difference respect to drug variability. Differences in drop size were found to be related to the outer nozzle diameter for all but 2 cases (r=0,90).

Conclusion Differences up to 100% between drop volumes associated to drug type were found. Drop volume showed a significant variation according to a variety of factors such as the nozzle design (outer diameter) and the drug solution properties.

EVER-2004-abstractbook.indd 89 8/19/04 12:26:28 PM

1129 / 235

Dynamic autoregulation in the eye and brain

KOLODJASCHNA J (1), BERISHA F (1), POLSKA E (1), SCHMETTERER L (1, 2)
(1) Clinical Pharmacology, Vienna
(2) Medical Physics, Vienna

Purpose Dynamic autoregulation assesses the full time course of the autoregulatory process by analyzing beat-to-beat changes in perfusion pressure and blood flow parameters. We have adapted the tigh cuff technique to induce an ocular perfusion pressure step disturbance.

Methods 12 healthy male subjects were studied. Ultrasound parameters and arterial blood pressure (ABP) were recorded before, during, and after a step drop in blood pressure. Large bilateral thigh cuffs were inflated and the thigh cuff pressure was 20 mm Hg above systolic blood pressure (SBP). The occlusion was maintained for 3 minutes and a drop in ABP was induced by rapid deflation of the cuffs. Peak systolic flow velocity (PSV) and end diastolic flow velocity (EDV) were assessed with a color Doppler probe for the posterior ciliary arteries, the central retinal artery, the ophthalmic artery and the middle cerebral artery. SBPs and diastolic blood pressures (DBP) were measured continuously using a Finapres system. Autoregulation index, as a measure of vascular resistance, was calculated for systole and diastole as AIS= SBP/PSV and AID=DBP/EDV, respectively.

Results The time course of mean ABP and blood flow velocity in response to the thigh cuff release was statistically significant for systole and for diastole versus baseline in all arteries. In addition, we found a statistically difference in the response of the time course of flow velocities and autoregulatory indices between the 4 arteries ($p < 0.001$).

Conclusion Our results indicate differences in the autoregulatory response of the 4 arteries after a step decrease in perfusion pressure. This may be due to differences in the myogenic responses but also due to differences in sympathetic innervation.

EVER-2004-abstractbook.indd 90 8/19/04 12:26:28 PM

■ 1131

A study of the genetic background of corneal subepithelial haze following refractive surgery

SZABO V (1), BALOGH K (2), HUNYADY L (3), NAGY ZZ (1)
(1) 1st Dept. of Ophthalmology, Semmelweis University, Budapest
(2) 2nd Dept. of Medicine, Semmelweis University, Budapest
(3) Dept. of Physiology, Semmelweis University, Budapest

Purpose Introduction: Refractive surgery techniques which use the ArF excimer laser to correct refractive errors of the eye increasing worldwide. One of the most significant complications following photorefractive keratectomy is the persistent corneal subepithelial haze, as it deteriorates postoperative quality of vision. Lumican, (OMIM: 600616), a leucin-rich keratan sulfate proteoglycan, has been previously reported as a candidate gene for causing corneal opacity in experimental models. Lumican can be found in large quantities in the corneal stroma, it regulates collagen fibril diameter and interfibrillar spacing, therefore it is essential for the maintaining of corneal transparency. Purpose: To determine whether germline mutation of the lumican gene may have a role in the development of persistent corneal subepithelial haze (Hanna scale 1,0-2,0) among patients one year after photorefractive keratectomy (PRK).

Methods Exon 1, exon 2 and exon 3 of the lumican gene were examined in 10 patients with persistent corneal subepithelial haze (Hanna scale 1,0-2,0) and in 2 controls. All three exons and the immediate intronic sequences of the lumican gene were evaluated by genomic PCR amplification method followed by automated direct nucleotide sequencing.

Results No germline genetic alterations were found among these 10 patients with persistent corneal subepithelial haze compared the controls and Genbank database.

Conclusion There was no evidence that germline mutation of the lumican gene participates in etiology of corneal subepithelial haze developing after excimer laser photorefractive keratectomy.

■ 1132

Identification of XLRS1 gene mutation (608C>T) in a portuguese family with juvenil retinoschisis

TEIXEIRA C (1), ROCHA-SOUSA A (1, 2), BRANDÃO E (1), FALCÃO-REIS F (1, 3)
(1) Ophthalmology of S. João Hospital, Porto
(2) Physiology of Porto Medical School, Porto
(3) Ophthalmology of Porto Medical School, Porto

Purpose To characterize the electroretinogram (ERG) and molecular genetic findings, in a family with XLRS1. The authors present two cases of a portuguese family with juvenile retinoschisis with a mutation in exon 6.

Methods Two brothers, their parents, grandmother and uncle were submitted to a general ophthalmic examination. The two brothers, the only ones with ophthalmic disease, continued the evaluation with colour fundus photography, fluorescein angiography, pattern visual evoked potential (PVEP) and full field ERG (ISCEV standard) and molecular genetic study (Group VI of Retinoschisis Consortium).

Results Both patients presented funduscopic manifestations of a vitreoretinal degeneration. They presented with peripheral schisis and retinal detachment. However, foveal schisis had never been observed. A negative ERG was recorded in both. After that, the younger brother showed a typical foveal schisis in fundoscopic examination and it was identified a XLRS1 gene mutation (608C>T), in both.

Conclusion In these patients, negative ERG was the most secure clinical marker to establish the diagnosis of juvenile retinoschisis. This XLRS1 gene mutation (608C>T) was described for the first time in a Portuguese family.

■ 1133

Lebers Hereditary Optic Neuropathy in Turners syndrome

COLLINS CE, BACKHOUSE O
Ophthalmology dept, Leeds General Infirmary, Leeds

Purpose Lebers Hereditary Optic Neuropathy(LHON) is a rare maternally inherited disease caused by mitochondrial DNA mutations resulting in acute bilateral optic neuropathy affecting predominantly young males.We present a case of LHON in a young woman with Turners (XO) syndrome. We highlight recent literature suggesting that the presence of two X chromosomes in females has a protective role in preventing the development of LHON.

Methods A 33 year old lady was referred to the Ophthalmology department at Leeds General Infirmary with a six month history of a gradual reduction in visual acuity. Her vision was noted to be "counting fingers" in the right eye and 6/60 in the left. She was diagnosed with Turner's syndrome aged 12 following premature ovarian failure.Ocular examination showed normal maculae although her optic discs had slight temporal pallor. Goldmann visual fields demonstrated bilateral central scotomas.There was no family history of problems with visual acuity and she denied any alcohol or substance abuse. All tests including CT brain, full blood count, liver function, B12, folate, ACE, ANA and VDRL proved normal. A test for Lebers Hereditary Optic Neuropathy was shown to be positive with the 11778G>A mutation detected.

Results The diagnosis was explained to the patient along with the implications for her family members. Genetic screening of family members for this mutation has been undertaken Her visual acuity has not improved and her name has been added to the fully blind register.

Conclusion A literature search has shown no other reported case of Lebers Hereditary Optic Neuropathy in a patient with Turners syndrome. We feel this case provides an unusual case study that may help explain the much reduced incidence of LHON in females.

■ 1134

Prevalence of PITx2 mutation/polymorphism in patients with primary open angle glaucoma

VAIDEANU D (1, 2), IDREES F (3), SOWDEN J (3), FRASER S (1)
(1) Ophthalmology, Sunderland
(2) Institute of Human Genetics, Centre for Life, Newcastle upon Tyne
(3) Institute of Child Health, UCL, London

Purpose Mutations of the PITX2 gene disrupt normal development of the anterior segment and cause overt structural abnormalities. It is also possible that, as yet undetected,polymorphisms in PITX2 may produce subtle and undetected abnormalities in anterior segment structure and function that could predispose to glaucoma. The purpose of this study was to screen a cohort of patients with primary open angle glaucoma (POAG) for mutations/ polymorphisms in the PITX2 gene to establish the mutation spectrum.

Methods 105 patients with POAG and 60 age and ethnically matched controls were enrolled in the study. Patients and controls had: clinical history, complete ophthalmologic examination and visual field analysis. Exon-specific primers were used to PCRamplify patient DNA. Direct sequencing was used to identify sequence alterations in the entire coding sequence of the PITX2 gene (isoform A).

Results Search of the NCBI database for single nucleotide polymorphism identified five polymorphic sites reported in the gene segment we investigate. Of these, three sites cause a non-synonymous changes in PITX2 gene. So far we completed work on exon 5 and 6. None of the reported changes were identified in our cohort. Also, for exon 5 and 6 no other new polymorphic sites have been identified in our study group.

Conclusion Polymorphic sites were not detected within the PITX2 gene in our cohort indicating a high level of sequence conservation. We suggest that the main reason for not identifying the reported polymorphic sites in our study group may be due to fact that these changes were found on a different ethnic group (Japanese). However, we still have to complete the screening of the exon 1 and 2.

EVER-2004-abstractbook.indd 91 8/19/04 12:26:29 PM

1135

The role of apolipoprotein E gene promoter polymorphisms in primary open angle glaucoma

RESSINIOTIS T (1, 2), VOROS GM (1), GRIFFITHS PG (1), KEERS S (2), BIRCH MK (1), CHINNERY PF (2)

(1) Department of Ophthalmology, Royal Victoria Infirmary, Newcastle upon Tyne

(2) Department of Neurology, The Medical School, University of Newcastle upon Tyne, Newcastle upon Tyne

Purpose Primary open angle glaucoma (POAG) is a neurodegenerative disease of unknown etiology. Recent genetic association studies have implicated the apolipoprotein E gene (APOE) promoter in the pathophysiology of POAG, but there have been conflicting findings. Our aim is to investigate a possible genetic association between primary open angle glaucoma (POAG) and two functional polymorphisms in the APOE gene promoter.

Methods 140 POAG patients and 73 healthy matched controls from a Caucasian population were genotyped by Polymerase Chain Reaction and restriction digestion with the enzyme DraI to discriminate the –491A/T Single Nucleotide Polymorphism (SNP) and TaqI to discriminate the –219T/G SNP, followed by electrophoresis on a Beckman-Coulter CEQ 8000 capillary fluorescent analyzer. APOE promoter haplotypes were determined for the POAG patients and controls using the well-established mathematical algorithm PHASE.

Results Statistical analysis revealed no strong evidence of an association between POAG and the APOE(-219G) or APOE(-491T) promoter polymorphisms, or the APOE(-219/-491) promoter haplotype.

Conclusion We conclude that neither the -219 nor the -491 APOE promoter polymorphisms have a major influence on the pathophysiology of glaucoma. Power calculations indicate that we had a 80% power to detect an odds ratio of 2.25 for the -219 APOE promoter polymorphism at the 0.05 level. We therefore cannot exclude the possibility that genetic variation at the APOE locus makes a minor contribution to the risk developing POAG or its severity, either in isolation or through an interaction with other genes.

1136

Three novel Pax6 mutations in mice lead to small eyes and cataract, but have different functional consequences on target promoters

GRAW J (1), LÖSTER J (1), MEYER B (2), NÜRNBERG P (2), SOEWARTO D (3), FUCHS H (3), SELBY P (4), FAVOR J (5), PRETSCH W (5), WOLF E (6), HRABÉ DE ANGELIS M (3)

(1) GSF-National Research Center for Environment and Health, Institute of Developmental Genetics, Neuherberg

(2) Max-Delbrück-Center for Molecular Medicine, Gene Mapping Center, Berlin-Buch

(3) GSF-National Research Center for Environment and Health, Institute of Experimental Genetics, Neuherberg

(4) RiskMuTox, Oak Risge

(5) GSF-National Research Center for Environment and Health, Institute of Human Genetics, Neuherberg

(6) Lehrstuhl für Molekulare Tierzucht und Biotechnologie, Ludwig-Maximilians-Universität, München

Purpose Aim of the study is the characterization of a three new mouse small-eye mutants, Aey11, Aey18 and ADD4802.

Methods A genome-wide linkage analysis was performed using microsatellite markers. Histological analysis and in-situ hybridisation were performed between E12.5 and E17.5. DNA transfection studies used the mutant Pax6 gene (+/- exon 5a) cloned into the pcDNA3.1 expression vector, Crygf- or Six3 promotors fused to luc reporter gene and HEK cells as recipients.

Results All three mutations were mapped close to the Pax6 gene. Sequence analysis of the Pax6 gene identified a new stop codon in Aey11 mutants in exon 8 just in front of the homeodomain. In the Aey18 mutants, a splice-site mutation in front of the exon 5a removes exon 5a and 6 from the mRNA and leads to the loss of the major part of the paired domain. The ADD4802 mutants are also characterized by a splice-site mutation; 41 additional bp lead to a changed ORF, a premature stop codon and a loss of the homeodomain. In-situ hybridisation of downstream genes demonstrated an increased expression of Crygf and Cryaa, whereas Six3 does not seem to be altered. These results are supported by functional reporter gene assays; however, it is noteworthy that the ADD4802 constructs lead to a tremendous increase of reporter gene activity mediated by the Six3 promoter.

Conclusion Three new Pax6 mutations in the mouse have been characterized. They all suffer from small eyes with cataracts, but in the reporter gene assay the effect of the Pax6ADD4802 is quite different at the Six3 promoter as compared to the two others; at the Crygf promoter only slight differences have been observed.

EVER-2004-abstractbook.indd 92 8/19/04 12:26:29 PM

■ 1141

Laminins in human extraocular muscles: clues to protection in muscle dystrophy

PEDROSA-DOMELLÖF F (1, 2), KJELLGREN D (2), VIRTANEN I (3)
(1) IMB, Anatomy, Umeå University, Umeå
(2) Clinical Sciences, Ophthalmology, Umeå University, Umeå
(3) Institute of Biomedicin, Anatomy, University of Helsinki, Helsinki

Purpose To determine the laminin isoform composition of the basement membranes (BM) in the human extraocular muscles (EOMs) and relate it to the fact that EOMs are spared in laminin a2-chain deficient congenital muscular dystrophy.

Methods Samples from human fetal (10-22 weeks of gestation) and adult EOMs and limb muscle were immunostained with mAbs against laminin chains (Ln) a1, a2, a3, a4, a5, b1, b2, g1.

Results Ln a1, a2, a4 and a5 were present around developing myotubes from the early stages, but Ln a1 and a5 delineated the future orbital layer more strongly than the global layer. The BM of the adult EOM muscle fibers contained Lna2, b1, b2, g1, and to some extent also Lna4 and a5. Thei distinct laminin composition of the EOMs was confirmed by the presence of Lutheran protein, an a5 chain specific receptor, not found in limb muscle. The neuromuscular junctions had increased expression of Lna4, and maintained expression of Lna2, a5, b1, b2 and g1. The myotendinous junctions contained Lna2, a5, b1, b2 and g1. The capillary density was very high (1050 +/-190 capillaries/mm2) in the EOMs and significantly ($p<0.05$) higher in the orbital layer (1170 +/-180 cap/mm2) than in the global layer (930 +/-110 cap/mm2).

Conclusion The human EOMs showed important differences in laminin isoform composition and capillary density when compared to human limb muscle. The presence of additional laminin isoforms other than laminin 2 in the BM of the extrasynaptic sarcolemma, could partly explain the sparing of the EOMs in Lna2 deficient congenital muscle dystrophy. The BMs in the orbital layer differed from those in the global layer during development, suggesting a potentially important role for different laminin chains in human EOM differentiation.

■ 1142

Uncoordinated expression of myosin heavy chains and myosin binding protein C isoforms in human extraocular muscles

KJELLGREN D (1), STÅL P (2), LARSSON L (3), FURST D (4), PEDROSA-DOMELLÖF F (5, 2)
(1) Department of Clinical Science, Ophthalmology, Umeå University, Umeå
(2) Department of Integrative Medical Biology, Section of Anatomy, Umeå University, Umeå
(3) Department of Clinical Neurophysiology, Academic Hospital, Uppsala University, Uppsala
(4) Institute for Biochemistry and Biology, Department of Cell Biology, University of Potsdam, Potsdam
(5) Department of Clinical Sciences, Ophthalmology, Umeå University, Umeå

Purpose To examine the distribution of myosin binding protein C (MyBP-C) in human extraocular muscles (EOMs) and to correlate the myosin heavy chain (MyHC) and the MyBP-C composition of the fibers.

Methods Samples from 17 EOMs, three levator palpebrae and five limb muscles were analyzed with SDS-PAGE or processed for immunocytochemistry with monoclonal antibodies (MAb) against MyBP-Cfast, MyBP-Cslow, MyHCIIa, MyHCI, MyHCsto, MyHCa-cardiac and MyHCemb.

Results In the limb muscle samples the fast fibers were labeled with anti-MyBP-Cfast and anti-MyBP-Cslow, whereas the slow fibers were immunostained with anti-MyBP-Cslow only, in accordance with previous studies. In 11 EOMs samples MyBP-Cfast was not detected and weak staining with anti-MyBP-Cfast was seen only in a few fibers in the proximal part of two muscles. The MAb against MyBP-Cslow labeled all fibers, but fibers containing MyHCI were generally more strongly stained. In the levator palpebrae immunostaining with anti-MyBP-Cfast was present in some fibers labeled with anti-MyHCIIa and/or anti-MyHCeom.Neither MyBP-Cfast nor MyBP-Cslow was detected by SDS-PAGE in the EOMs or the LP. However, faint protein bands migrating slightly above the MyBP-Cslow isoform and beneath the MyBP-Cfast isoform were observed in the EOMs, but not in the limb muscle samples.

Conclusion The true EOMs have a unique myofibrillar protein isoform composition reflecting their special structural and functional properties. The lack of MyBP-Cfast expression and the novel bands detected by SDS-PAGE suggest the presence of novel, and perhaps unique isoforms of MyBP-C in the human EOMs.

■ 1143

NPY(+) AND TH(+) Intrinsic choroidal neurons in humans

ROJAS B, DE HOZ R, SALAZAR JJ, RAMÍREZ JM, TRIVIÑO A
Instituto Investigaciones Oftalmológicas Ramón Castroviejo.UCM, Madrid

Purpose To determine the presence of NPY(+) and TH(+) intrinsic choroidal neurons (ICNs) in humans

Methods Thirteen human choroidal whole mounts were processed for indirect immunofluorescence. Antibody to a component of the neuronal cytoskeleton, neurofilament 200 kDa (NF-200), was combined with antibodies to neuropeptide Y (NPY) and antibodies to tyroxine hydroxylase (TH).

Results NPY(+) and TH(+) ICNs were observed in the suprachoroid. In addition, TH(+) ICNs were located at the medium size vessel layer. Overall, NPY(+) and TH(+) ICNs were more frequent at the temporal central area, both in isolation and forming microganglia.

Conclusion The existence of NPY(+) and TH(+) ICNs that could contribute to the proposed choroidal self-regulation. The preferential location of these cells in the submacular area suggests the possibility that dysfunction or degeneration of these cells could be a factor in vascular pathologies observed in ocular disease, such as diabetic macular edema or age related macular degeneration.

■ 1144

A Method for Obtaining Progenitor Cells from Adult Rodent and Human Eyes

VOSSMERBAEUMER U

Purpose Primary degenerative processes in the retinal pigment epithelium (RPE) play a pivotal role in the development of non exudative age related maculopathy (ARM). The resulting lack of nutritive support to the overlying photoreceptors severely compromise the physiological function. Replacing RPE cells by grafting pre-differentiated ocular stem cells could constitute an etiologic therapy. We investigate whether progenitor cells can be isolated from the broad ciliary marginal zone, and whether these cells can be cultivated and differentiated prior to transplantation.

Methods The ciliary marginal zone (CMZ) of 4 freshly enucleated albinotic rat eyes was excised and consecutively digested with collagenase, hyaluronidase, trypsin, NaEDTA and DNAse. Preparatory modifications were needed for cultivation of human corneal stem cells from the corneal-limbal area. Subsequently a suspension cell culture was established using optimized medium for primary neuronal cells (DMEM/Ham F12, B27, antibiotics and antifungals). To ensure optimal growth conditions of spheric cell aggregates, basic fibroblast growth factor (20ng/ml) with addition of 10 ng/ml epidermal growth factor was administered. Differentiation of the cells was induced by 1-10 % fetal calf serum (FCS) after adherence of the spheres on a PEI coated surface. After a minimum 14 days differentiation was assessed by immunocytological staining. Cell proliferation was assessed via BrdU incorporation.

Results We established cell culture and differentiation conditions for primary cells obtained from the CMZ of rat and human eyes. Cells within the spheres expressed Nestin, indicating the presence of progenitor cells. Cultivation of progenitor cells was possible over a period of several months. After differentiation, both glial (GFAP) and neuronal (MAP2) markers were expressed on cells migrating from the spheres. Differentiated cells stained positive with cytokeratine markers 8 and 18 as well as Bestrophin, indicating a phenotype characteristic for RPE. Corneal cells displayed a fibroblast phenotype and stained positive for markers like p63 and Nestin as well as Cytokeratine 5 for the respective differentiation levels. BrdU Incorporation indicated proliferation of the specimens.

Conclusion Progenitor cells were found in adult rodent and human eyes within a broad area of the ciliary marginal and corneal-limbal area. Progenitor cells might be a source for causative replacement therapy in ARM. Limbus derived cells could be eligible for use in potential corneal replacement therapy.

EVER-2004-abstractbook.indd 93 8/19/04 12:26:30 PM

■ 1145

Proteasome inhibitor-induced cytoplasmic protein aggregation is modified with geldanamycin in human ARPE-19 cells

KAARNIRANTA K (1), RYHÄNEN T (1), MIETTINEN R (2), SALMINEN A (2, 3), LUUSITALO H (1)
(1) Department of Ophthalmology, University of Kuopio, Kuopio, Finland
(2) Department of Neuroscience and Neurology, University of Kuopio, Kuopio, Finland
(3) Department of Neurology, Kuopio University Hospital, Kuopio, Finland

Purpose Pathogenesis of age-related macular degeneration (AMD) involves to impaired degradation of membranous discs shed from photoreceptor outer segments in lysosomes of RPE cells. In addition to lysosomal protein degradation, many cellular proteins are degraded in ubiquitin-proteasome pathway. In response to various stresses, cells increase the expression of heat shock proteins (Hsps). They function as a molecular chaperones, in order to prevent the accumulation of cellular cytotoxic protein aggregates. Role of Hsp70, Hsp90 and proteasome inhibition were evaluated in cellular aggregation in human RPE cells (ARPE-19).

Methods Accumulation Hsp70 and ubiquitinated proteins were analyzed by Western blotting. Transmission electron microscopy was used to detect cellular organelles in ARPE-19 cells.

Results MG-132 proteasome inhibitor caused robust accumulation of Hsp70 protein and ubiquitinated proteins in ARPE-19 cells. Hsp90 inhibitor geldanamycin potentiated, influence of the protesome inhibitor, when analyzed ubiquitinated proteins. Electron microscopy analyses showed highly, in size and context, varied cytoplasmic protein aggregates in response to proteasome inhibition. Interestingly, the largest cytoplasmic aggregates disappered with geldanamycin treatment.

Conclusion This study reveals that ubiquitin-proteasome pathway is an important way to control protein turnover in the RPE cells. In addition, Hsp70 and Hsp90 are closely related to regulation of cytoplasmic protein aggregation together with proteasomes, and may thus have an essential role in degenerative processes in the retinal cells.

■ 1146

Neural stem cells transplantation is protective to rabbit's retina function against kainate-induced exitotoxicity

ZUEVA MV (1), TSAPENKO IV (1), CHENTSOVA EV (1), PAK NV (1), PETRIASHVILI GG (1), POLTAVTSEVA RA (2), MAREY MV (2), SUKHIKH GT (2)
(1) Moscow Helmholtz Research Institute of Eye Diseases, Moscow
(2) Research Center for Perinatology, Obstetrics and Gynecology, Moscow

Purpose To estimate the effect of human neural stem cells (HNSCs) transplantation to retinal function at kainate retinopathy.

Methods The retinopathy was induced by intravitreal injection of kainic acid (0.04 mg) in the both eyes of 15 rabbits. The standardized culture of first-trimester gestation HNSCs (3x106 cells) was grafted into the right vitreous simultaneously with kainate. BBS was injected into the left eyes. Full-field ERG and 12Hz-flicker ERGs (FERG) were recorded before and at 1, 3, 7, 20, 30 days after injections. For estimation of Muller cells function, the glial index KG was calculated as b-wave/FERG ratio.

Results The selective reduction of b-wave and FERG, but not a-wave, was detected after injection of kainic acid. In most control eyes b-wave was absent and the ERG consisted of pure PIII component, the reduced FERG was registered as a reflection of preserved photoreceptor function. The better preservation of bipolar cells and Muller glia function was revealed in the eyes with HNSCs which had much better amplitudes of b-wave and FERG, than in the control eyes. The activation of Muller cells was shown in the right eyes, but the significant reduction of KG in the control left eyes showed the development of proliferative gliosis in the retina.

Conclusion Intravitreal injection of HNSCs promoted survival of bipolars and preservation of their function at kainate-induced retinopathy. The results support our hypothesis that HNSCs exert their effects on retinal neurons by acting indirectly through the Muller glia, likely by inhibiting apoptosis through the modulation of Muller cells function and glio-retinal interactions in the retina.

EVER-2004-abstractbook.indd 94 8/19/04 12:26:30 PM

■ 1151

Connective tissue growth factor is associated with fibrosis in vitreoretinal disorders in the human eye

SCHLINGEMANN RO (1), KUIPER EJ (1), DE SMET MD (1), VAN MEURS JC (2), TAN HS (1), TANCK MW (3), OLIVER N (4), WIETEN L (5), VAN NIEUWENHOVEN FA (5), GOLDSCHMEDING R (5)

(1) Ocular Angiogenesis Group, Academic Medical Center, University of Amsterdam, Amsterdam
(2) Department of Ophthalmology, Rotterdam Eye Hospital, Rotterdam
(3) Department of Clinical Epidemiological Statistics, Academic Medical Center, University of Amsterdam, Amsterdam
(4) Fibrogen, Inc., San Francisco, CA
(5) Department of Pathology, Academic Medical Center of Utrecht, Utrecht

Purpose Fibrosis and scarring lead to irreparable loss of vision in several major diseases of the retina. Fibrosis is also the unpreventable outcome of ocular neovascularization. To identify factors involved in ocular fibrosis which may serve as new therapeutic targets, we investigated connective tissue growth factor (CTGF), an inducer of fibrosis, and the angiogenesis factor VEGF in relation to fibrosis and neovascularization in human vitreoretinal disorders.

Methods Vitreous samples were obtained from 53 patients with vitreoretinal disorders associated with varying degrees of fibrosis: proliferative diabetic retinopathy (PDR), proliferative vitreoretinopathy (PVR), epiretinal membrane and macular hole. Clinical data, including degree of intra-ocular fibrosis and neovascularisation, were collected using standardized forms. The concentrations of CTGF and VEGF- were measured by ELISA.

Results Significant univariate associations were found between CTGF and degree of fibrosis ($p < 0{\cdot}001$; $R2 = 37\%$), degree of neovascularisation ($p = 0{\cdot}015$; $R2 = 15{\cdot}4\%$), diabetes ($p = 0{\cdot}046$; $R2 = 7{\cdot}6\%$) and VEGF ($p = 0{\cdot}001$; $R2 = 29{\cdot}6\%$). Multivariate analysis demonstrated that degree of fibrosis ($p = 0{\cdot}013$) and VEGF ($p = 0{\cdot}022$) are the best predictors for a rise in CTGF concentration in the human vitreous (together $R2 = 43{\cdot}6\%$). Moreover, CTGF concentration predicts the degree of fibrosis ($p = 0{\cdot}001$). In the 10 PDR cases with neovascularisation, the ratio of CTGF over VEGF strongly correlated with the degree of fibrosis ($rho = 0{\cdot}661$; $p = 0{\cdot}037$).

Conclusion CTGF may be an important causal factor in ocular fibrosis, and an increased CTGF/VEGF ratio may be crucial in the angiofibrotic switch occurring in the course of ocular angiogenesis. CTGF may therefore represent a suitable therapeutic target for prevention of sight-threatening vitreoretinal scarring.

■ 1152

Is erythropoietin involved in diabetic retinopaty? Preliminary comunication

DE SOUZA RAMALHO P (1, 2), PEREIRA DA SILVA A (2), THIRAN C (2), FONTES G (2), BICHO MM (2)

(1) Ophtalmology, Lisbon
(2) Genetics Laboratory and Metabolic Centre, Lisbon

Purpose Hematopoietic cytokine erithropoiethin (EPO), desides stimulating erythrocyte formation, mediates neuroprotection and assists neuronal survival by reducing NO production at low glucose concentrations with important implication of retinal cell death in diabetic retinopathy.Objectives: To study EPO plasma expression in type 2 diabetics under medication, with and without retinal involvement.

Methods In 36 type 2 diabetics 14 with and 22 without retinopathy, with mean age of 66.44±7.59, 15 females and 21 males, EPO levels (mIU/ml) in the plasma were studied using ELISA and compared to 41 non diabetic controls age and sex matched. Student t test was applied.

Results EPO plasma levels varied (1.462 to 44.979) and also in the controls, presenting a trend to higher levels in diabetics and more so in subjects with retinopathy: controls 9.47±6.57, diabetics - 12.07±9.42, (p=0.151), without retinopathy - 10,84±6,11, with retinopathy - 14,00±13,11 p=0.332.

Conclusion EPO levels showing trends towards high expression in the plasma suggest a possible hypoxia/ischemia induced reaction. It could also indicate a preconditioning mechanism to attenuate ischemic induced cell death which may not be present in all tissues. Further studies are needed to understand the role of erythropoietin in diabetic retinopathy.

■ 1153

Sympathetic and parasympathetic cardiovascular neuropathy and diabetic retinopathy

SUMMANEN PA (1), MÄKIMATTILA S (2), SCHLENZKA A (2), MÄNTYSAARI M (3), YKI-JARVINEN H (2)

(1) Ophthalmology, Helsinki
(2) Internal Medicine, Division of Diabetes, Helsinki
(3) Research Institute, Military Hospital, Helsinki

Purpose To assess the relationship between autonomic cardiovascular neuropathy and retinopathy in patients with type 1 diabetes (DMT1).

Methods Multiple tests were used to characterize sympathetic and parasympathetic nervous function in 109 patients (39 F/70 M) (age 31 (1) yrs, duration of DM 23 (1) yrs, urinary albumin excretion rate (UAER) median 10 (6,78 ug/min (25,75 % interquartile range), HbA1c 8,5 (0,1) %), mean (SE) and in 29 matched controls. Severity of diabetic retinopathy (RP) was determined from fundus photographs.

Results Patients with none to moderate non-proliferative RP (score 10-43) differed with respect to age at onset (12 (1) yrs vs. 9 (1) yrs, p<0,05) and duration of diabetes (21 (1) yrs vs. 26 (1) yrs, p<0,001); HbA1c (8,2 (0,2) % vs. 8,7 (0,2) %, p<0,05), BMI, UAER, and systolic and diastolic blood pressure from those with more severe RP (score 51-70). The latter had significantly decreased values in E/I-ratio (p<0,001), HF (p<0,001), Valsalva ratio (p<0,05), orthostatic test (p<0,01), TP, LF, HF and RMSSD (p<0,001 for all) compared to patiens with score 10-43. In simple regression analysis the severity of diabetic retinopathy was negatively correlated with all autonomic function tests, significantly in 7/8. Duration of DM, UAER, systolic and diastolic blood pressure, HbA1c and BMI, were positively correlated with RP-score. In multiple linear regression analysis, the independent determinants of RP-score were 4/8 indexes of autonomic neuropathy, systolic and diastolic blood pressure and HbA1c with duration of DM.

Conclusion Sympathetic and parasympathetic cardiovascular autonomic nervous system defects are associated with the severity of diabetic retinopathy in patients with DMT1.

■ 1154 / 121

Qualitative and Quantitative Comparison Of Autofluorescence And Color Images of Eyes withDrusen And Age Related Macular Degeneration

SIVAGNANAVEL V (1), SMITH RT (2), CHAN J (2), FITZKE F (3), WEBSTER AR (4, 5), JENKINS SA (4), CHONG NV (1)

(1) Kings College Hospital, London
(2) Department of Ophthalmology, Columbia University, New York
(3) Institute of Ophthalmology, London
(4) Moorfields Eye Hospital, London
(5) Institute of Ophthalmology, London, England

Purpose To determine the degree of concordance between autofluorescence patterns and drusen distribution in eyes with drusen.

Methods Thirty consecutive patients with significant drusen were selected from those persons recruited to the UK-MRCage-related macular degeneration collection. Matlab and Adobe software was used to resize and overlay corresponding points between colour (Topcon) and autofluresecence SLO images (Zeiss). Independent graders from Columbia University and King's College Hospital used macular background levelling software to quantify the percentage of drusen in the middle Wisconsin subfields, using both color and autofluorescence images

Results There was considerable variability in the extent of autofluoresence between eyes. Direct visual comparison did not identify a pattern of autofluorescent foci which matched the drusen determined on color imaging. When subgroup analysis was performed according to disease phenotype (eyes with bilateral drusen, drusen in one eye and choroidal neovascularization or geographic atrophy in the fellow eye), a similar discordance in autofluorescence and color imaging was seen. Correlation measures were calculated for the quantity of color and autofluorescent variation for all images

Conclusion The exact relevance of drusen in AMD remains uncertain with regard to a role as a disease marker or causal relationship. Progression of disease is widely accepted to correlate to increase in drusen load. The distinct patterns of drusen and retinal autofluroescence at the macula suggest the preservation of function of those RPE cells overlying drusen in age-related macular disease.

EVER-2004-abstractbook.indd 95 8/19/04 12:26:31 PM

1155 / 102

Effects of vitamin C on hyperoxia-induced reduction of retinal blood flow

LUKSCH A (1, 2), WEIGERT G (1), MAÁR N (2), RESCH H (1), SCHMETTERER L (3, 1)
(1) Department of Clinical Pharmacology, Vienna
(2) Department of Ophthalmology, Vienna
(3) Department of Medical Physics and Biomedical Engineering, Vienna

Purpose The purpose of the present study was to investigate whether ascorbic acid alters retinal blood flow and/or modifies the retinal vasoconstrictor response to systemic hyperoxia.

Methods We performed a randomized, double-masked, placebo-controlled study in 12 healthy male volunteers. Subjects received vitamin C (3g i.v.) or placebo on two different study days. 100% oxygen was inhaled over a period of 12 minutes two times, before and after drug administration, per study day. Retinal vessel diameter (Zeiss retinal vessel analyzer) and retinal blood flow velocity (bi-directional Doppler velocimetry) were assessed continuously. Blood gas analysis was done from arterialized capillary blood from the earlobe. Intraocular pressure and systemic hemodynamics were measured in regular intervals.

Results Systemic hemodynamics and intraocular pressure were comparable on both study days and remained unchanged throughout the study. The values of the blood gas analysis were within the expected range. Administration of vitamin C did not alter retinal blood flow parameters at baseline. Breathing of 100% oxygen for 12 minutes reduced retinal venous diameter ($p<0.0001$ versus baseline) and retinal blood velocity ($p<0.0001$ versus baseline). The reduction of retinal hemodynamic parameters in response to systemic hyperoxia was not altered by administration of vitamin C (venous diameter: $p=0.51$, blood flow velocity: $p=1.0$).

Conclusion In healthy humans vasoconstriction of retinal vessels and decreased retinal blood flow velocity in response to systemic hyperoxia is not altered by a dose of vitamin C. In addition, vitamin C did not influence retinal blood flow at baseline. Accordingly, vitamin C does not influence retinal blood flow to a substantial degree.

1156 / 103

Preterm Birth and Retinovascular Development

FIELDER AR, COCKER KD
Visual Neuroscience, Imperial College London, London

Purpose To study retinovascular development in babies born prematurely, without and with retinopathy of prematurity.

Methods Images were acquired using wide-field non-contact digital imaging (RetCam 120, Massie Labs, Dublin, CA) obtained during routine screening for retinopathy of prematurity (ROP). The following 4 studies were performed: i) measurement of the distance from optic disc to first bifurcation of arterioles and venules; ii) assessment of emergent angle of temporal vessels; iii) quantifying tortuosity of the retinal arterioles, and iv) measurement of venule diameter. Results were categorised by the infant's gestational age (GA): 24-27 weeks, 28-31 weeks and ≥32 weeks (GA), and ROP status.

Results The temporal vessel angles were similar between the 2 eyes of each infant, but the temporal vessel angle increased with time in utero. The superior and inferior retinal vessels differ in their distance from the fovea. There was a trend of increasing distance to the first bifurcation of the inferior temporal arteriole with increasing prematurity, but venous bifurcation was not affected by the degree of prematurity. Arteriolar tortuosity and venous diameter both increased with increasing ROP stage.

Conclusion Recently developed methods of retinal imaging present new opportunites to study in a quantitive manner, retinal development. These preliminary studies demonstrate that shortening the gestational period affects the development of the major retinal vessels, which in turn reflects underlying microvasculature and neural development. In many instances, the influences of prematurity per se and ROP cannot be differentiated. These studies show promise for the quantification of plus disease in ROP.

1157 / 105

Expression of apoptosis markers in retinas of human subjects with diabetes

ABU EL ASRAR AM (1), DRALANDS L (2), MISSOTTEN L (2), AL-JADAAN IA (3), GEBOES K (4)
(1) Department of Ophthalmology, Riyadh
(2) Department of Ophthalmology, Leuven
(3) King Khaled Eye Specialist Hospital, Riyadh
(4) Laboratory of Histochemistry and Cytochemistry, Leuven

Purpose To investigate the expression of the apoptotic mediators in the retinas from human subjects with diabetes mellitus.

Methods Ten postmortem eyes from five subjects with diabetes mellitus, and 8 control eyes were examined. We used antibodies directed GFAP, caspase-3, Fas, Fas ligand (FasL), Bax, Bcl-2, survivin, p53, extracellular signal-regulated kinases (ERK1/2), and p38.

Results In retinas from all subjects without diabetes, weak Bcl-2 immunoreactivity was confined to GFAP+ glial cells in the nerve fiber layer. Weak immunoreactivity for ERK1/2 was noted in a few nuclei in the inner nuclear layer and in a few Müller cell processes. Cytoplasmic immunostaining for survivin was noted in the retinal pigment epithelial cells. All diabetic retinas showed cytoplasmic immunoreactivity for caspase-3, Fas, and Bax in ganglion cells. FasL immunoreactivity was detected in GFAP-positive cells. Up-regulation of Bcl-2 immunoreactivity was noted in GFAP+ cells in nerve fiber and ganglion cell layers, and Bcl-2 induction was noted in Müller cell processes. Strong immunoreactivity for ERK1/2 was observed in many nuclei in inner nuclear layer, GFAP+ cells in nerve fiber and ganglion cell layers, and numerous Müller cell processes. Survivin immunoreactivity was not altered in the diabetic retinas.

Conclusion Ganglion cells in diabetic retinas express several proapoptosis molecules suggesting that these cells are the most vulnerable population. Glial cells in diabetic retinas are activated and express several antiapoptosis molecules in addition to the cytotoxic effector molecule FasL suggesting a possible role of glial cells in induction of apoptosis in ganglion cells.

EVER-2004-abstractbook.indd 96 8/19/04 12:26:31 PM

■ 1161

Recurrent corneal erosions-a second family with autosomal dominant inheritance

FAGERHOLM PPP (1), HAMMAR B (2), LIND H (3), BJORCK E (4), LAGERSTEDT K (4), DELLBY A (1), NORDENSKJOLD M (5)
(1) Dept. of Ophthalmology, University Hospital, Linköping
(2) Dept. of Ophthalmology,University Hospital, Linköping
(3) Dept of Ophthalmology, Hudiksvalls, Sweden
(4) Institute of Molecular Medicine,Karolinska Institutet, Stockholm
(5) Institute of Molecular Medicine, Karolinska Institutet, Stockholm

Purpose To describe the phenotype the pedigree and the preliminary genetical workup of a large family with recurrent erosions as the dominant symptom and sign. Last year another family was presented at the EVER meeting.

Methods Following interviews and examination a pedigree was established in this family with 334 members in 7 generations. The pattern of the disease development and the general health was established via interviews and ophthalmic examination of 35 members of the family. Seven healthy members were included. Blood samples were drawn from 85 members. Preliminary molecular genetic studies were made with polymorphic markers for loci surrounding known autosomal dominant corneal dystrophy genes: TGFB1,GSN,KRT3 and KRT 12.

Results Recurrent corneal erosions started at the age of 5 years in the majority of the affected. The erosions occurred about 4 times per year. The attacs typically lasted for 3-7 days. The attacs subsided at about 20-30 years of age but the eyes remained sensitive to minor trauma. Descrete corneal opacifications develope first (about the age of 20) in the midperiphery in the form of subepithelial fibrosis. With age this fibrosis extended but seldom engaged the central cornea. At the age of 70 and above small droplet like protrusions could be found. None of the affected members had been operated on because of visual reduction due to the ccorneal changes. There were no associated general or eye diseases.

Conclusion From the phenotype and the ptreliminare genetical workup we conclude that this disease has not been described before. The temporary name is Dystrophia Helsingia. We are presently conducting a cross-linking stydy.

■ 1162

Morphological changes in a corneal dystrophy where recurrent erosisons dominate

FAGERHOLM PPP (1), EK S (2), SEREGARD S (3), HAMMAR B (4), DELLBY A (4), STENEVI U (5)
(1) Dept. of Ophthalmology, University Hospital, Linköping
(2) Dept. of Ophthalmology, Sahlgrenska University Hospital, Mölndal
(3) St Eriks Eye Hospital, Karolinska Institutet, Stockholm
(4) Dept of Ophthalmology, University Hospital, Linköping
(5) Dept of Ophthalmology, Sahlgrenska University Hospital, Mölndal

Purpose A corneal dystrophy (Dystrophia Smalandia) with recurrent erosions as major symptoms and signs was described last year at the EVER meeting by our group. 50 per cent of the affected developed kelloid-like changes in the central cornea with time. The purpose is to describe the developing morphological changes using confokal microscopy in patients and histopathology and immunohistochemistry of resected material.

Methods Confocal microscopy was used to examine 4 affected members of the family and 4 unaffected members. The affected members varied in age from 20 to 60 years. The resected material consisted of one primary corneal graft, one regrafted cornea with recurrence of the opacities and one biopsy from a kelloid like formation. The paraffine embedded specimen were stained with haematoxylin and with antibodies to amyloid and basal membrane kollagen.Nerve staining was like-wise employed.

Results Confokal microscopy revealed , in the affected patients, that large parts of the Bowmans layer were thin or absent. Thin normal nerves and thicker truncs were running in the same plane. The epithelium had a normal cytoarchitecture. This finding was verified in sections from the grafts where the Bowmans layer was this or was missing. Subepithelial fibrosis was a rather prominent featureThe corneal nerve endings appeared normal. The biopsy from the kelloid-like formation contained amyloid and no basal membrane collagen

Conclusion Experience from a limited histopathology material and confocal microscopy examination both show that a major event is the degeneration of Bowmans layer. It appears that the nerves are intact.It also appears that the corneal opacities are a combination of subepithelial fibrosis and kelloid formation.

■ 1163

Usefulness of pachymetry in Weill-Marchesani syndrome

GICQUEL JJG (1, 2, 3), QUINTON JQ (1), SALAMA BS (2, 1, 3), GILBERT BG (4), DIGHIERO PLD (1, 2, 3)
(1) Ophthalmology, Poitiers
(2) Ophthalmology, Saint Jean d'Angély
(3) Ophthalmology, Saintes
(4) Human Genetics, Poitiers

Purpose To report a new variable of Weill-Marchesani syndrome (WMS) with elevated pachymetry readings.

Methods A 34 years old woman presented with high ocular applanation pressure values and considerable myopia. She had a short stature with normal cranial measures, maxillary hypoplasia with prognathia and class III mandibular closure abnormality, short philtrum, prominent nose, epicanthus, inferior eyelashes hypoplasia, low neck hairline, rhinolalia due to palatine insufficiency, external ear malformation associated with mixed mild deafness, as well as hypertrophic inter-phalengeal joints.

Results Static and dynamic visual fields were normal. Corneal pachymetry readings were about 760 µm OU. Patient's short stature with the reported facial and fingers dysmorphias and severe myopia constitutes a new variable of WMS (spherophakia and short stature (WMS, MIM 277600)) or more generally GEMSS syndrome (glaucoma, lens ectopia, microspherophakia, stiffness of the joints, and shortness), the dominant form.

Conclusion Similar WMS dominant cases with high myopia and glaucoma but without microspherophakia have been reported. Our patient presents facial dysmorphias and severe myopia which are comparable to those first reported in literature of WMS. Her false high IOP was due to elevated corneal thickness. Any of the anterior reports had measured the corneal thickness; which make it impossible to decide if the documented glaucoma in GEMSS syndrome was real or false. Our case could be considered a new variable of WMS and points the importance of pachymetry measures.

■ 1164

Subbasal nerves and possible dendritic cells in diabetic patients by in vivo scanning-slit confocal microscopy

POPPER M (1, 2), QUADRADO MJ (1), MORGADO AM (3, 4), MURTA JN (1), VAN BEST JA (1), MÜLLER LJ (5)
(1) IBILI, Center of Ophthalmology, University of Coimbra, Coimbra
(2) 1st Department of Ophthalmology, Semmelweis University, Budapest, Hungary
(3) IBILI, Department of Instrumentation, University of Coimbra, Coimbra
(4) Department of Physics, University of Coimbra, Coimbra, Portugal
(5) The Netherlands Ophthalmic Research Institute (NORI), Amsterdam

Purpose To search in vivo for possible changes in density and morphology of subbasal nerves and dendritic cells in diabetic patients.

Methods The left cornea of ten diabetic patients (NIDDM, grade of retinopathy: 20 ETDRS) and ten healthy controls were examined with the Tomey Confoscan P4 scanning-slit confocal microscope. Age in both groups was between 50 and 75 years.Through focus scans were made from epithelium to endothelium and the images were recorded and analyzed in a masked fashion by two independent observers.

Results In diabetic patients the number of subbasal nerve fiber bundles (SNFB) had dramatically decreased (none or 1 single vague SNFB per image) compared to healthy controls (5 to 7 clear SNFB per image). Furthermore very highly reflective cells (HRC) immediately beneath the basal epithelial cells' layer were observed. It is not clear whether they are located between the basal epithelial cells and Bowman's layer or in the most anterior stroma. The density of these cells in diabetic patients exceeded that of the controls. They were more rod-like in shape and different in size from those observed in the mid and anterior stroma.

Conclusion The decrease in the number of SNFB might be related to the decrease in basal epithelial cells' density as observed in our previous study (ARVO 2004 poster #3812).The significance of the HRC beneath the basal epithelial layer is not clear yet. As most of them are different from keratocyte nuclei they seem to belong to another type of cells. In case they are indeed located above Bowman's layer, we consider them on basis of their morphology and their location near the subbasal nerves as dendritic cells.

EVER-2004-abstractbook.indd 97 8/19/04 12:26:32 PM

1165

In vivo confocal microscopic imaging of corneal limbal epithelial and central Langerhans cells (LCs)

NUBILE M, TOTO L, LANZINI M, MASTROPASQUA L
Ophthalmic Clinic, Univeristy "G. d'Annunzio" Chieti-Pescara, Chieti

Purpose To investigate by using in vivo confocal microscopy of the cornea morphology and location of corneal epithelial LCs in healthy and immune-inflammation affected human corneas.

Methods Confoscan 3 and HRT II Laser Confocal microscopes were used to visualize the corneal centre and the limbal morphology. 30 healthy eyes were scanned at the limbus and corneal centre to investigate for in vivo evidence of LCs. LCs were considered as clearly visualised dendritic cellular objects. The proof that dendritic-shaped cells seen at the limbus were LCs was obtained by immunofluorescence staining of limbal biopsy in 2 eyes. 39 diseased corneas (7 HSV and 10 ADV keratitis, 10 RCE and 12 graft epithelial rejection) were analysed at the limbus and at the corneal centre. 30 PRK treated corneas with acute subepithelial reaction after epithelial recovery were examined at limbus and at centre, and served as non-immune inflammation control group. LCs density was calculated for the limbal and central corneal examination by means of computerized software analysis.

Results Dendritic-shaped LCs were imaged within the limbal basal epithelium of all examined eyes. The mean density of LCs at the limbus was 60 ± 26 cell/mm2 in healthy corneas, and 66 ± 21 cell/mm2 in PRK corneas (difference: p>0,05), while the density was significantly higher (p=0,02) 95 ± 32 cell/mm2 in immune-mediated diseased corneas. No LCs were identified in the corneal centre in healthy and PRK corneas, while were present with different densities in immune diseased corneas within the basal lamina.

Conclusion Confocal microscopy revealed as an effective method for evaluating LCs distribution at the limbus and at the corneal centre in both healthy and diseased corneas.

1166 / 154

Highly reflective cells in the stroma of diabetic patients visualized by in vivo confocal microscopy

QUADRADO MJ (1), POPPER M (1, 2), MORGADO AM (3), VAN BEST J (1), MURTA JN (1), MÜLLER LJ (4)
(1) Institute of Biomedical Research on Light and Image, Department of Ophthalmology, Coimbra University, Coimbra
(2) 1st Department of Ophthalmology, Semmelweis University, Budapest
(3) Department of Physics, Coimbra University, Coimbra
(4) The Netherlands Ophthalmic Research Institute, Amsterdam

Purpose While examining the corneal stroma of diabetic patients with in vivo confocal microscopy (IVCM) some images showed highly reflective cells with a tail. We have focused our attention on these specific structures.

Methods Four diabetic patients (NIDDM grade 20 ETDRS, age 53y to 69y) and four healthy controls (age 35y to 65y) from a previous study were further analysed. The number of highly reflective cells (HRC) found in the stroma was counted using registered images obtained by IVCM (Tomey Confoscan P4). The results were statistically analysed using the Mann-Whitney test.

Results Structures consisting of a highly reflective head and a vague tail (straight or undulated) were found mainly in anterior and mid-stroma of patients and controls. These are usually observed near the stromal nerves and are rare in the posterior stroma. The total number of HRC across stromal depth in diabetic patients was significantly higher 52.5 ± 9.25 (mean ± SD) than that in healthy controls 5.25 ± 1.5 (P=0.029). The average length and width of a HRC is 20.0 ± 3.4 µm and 18.7 ± 2.8 µm, and those of keratocyte nuclei 27.2 ± 4.6µm and 9.5 ± 1.3µm (N=30). The difference between both lengths and widths is significant (p<0.0005). Furthermore, undulated structures in dimensions similar to large stromal nerves were also observed in the diabetic patients. Interestingly enough, they were oriented parallel to and not as, the stromal nerves, oblique to the ocular surface.

Conclusion HRC is a new structure in the mid-upper stroma and seems to be specific for diabetic patients, since its density is significantly higher than that in controls. Currently, these cells cannot be classified and need further investigation.

1167 / 155

Corneal involvement in pseudoexfoliation syndrome

SKINNER KC, SRINIVAS HV, GREGORY PTS
Conquest, Hastings

Purpose Reporting an unusual deposit of pseudoexfoliation material on the cornea and review of keratopathy in pseudoexfoliation syndrome (PXF). Small flakes are known to be deposited on the endothelium. However, our patient had a solitary large deposit which has not been reported before. To emphasise the recognition of corneal involvement when considering intraocular surgery and mydriasis as they may precipitate corneal oedema.

Methods Case Report

Results An 83 year old lady attended the glaucoma clinic for a follow up. She had pseudoexfoliative material deposition on the lens and in the trabecular meshwork. She also had a solitary large lumpy deposit on the endothelium which was noted nine years earlier. There were no signs of intraocular foreign body or other corneal pathology and she had not undergone any intra ocular surgery.

Conclusion Here, the nature of the deposit is most likely to be pseudoexfoliation material as she had other signs of PXF and there was no other intraocular pathology. We could only make a presumptive diagnosis as examination of corneal button is necessary for a definitive diagnosis. Techniques like immumohistochemical, histopathological, biochemical and molecular biological techniques have helped in understanding the pathogenesis. The extent of endothelial loss due to corneal involvment is thought to be 21% with normal IOP and an additional 14% with a rise in IOP. As mydriasis can increase intraocular pressure in these patients, pupils should be dilated with caution. So also the intraocular surgeries.Corneal invovement in PXF has only recently been recognised. These small flaky deposits can be easily mistaken for keratic precipitates. This case reports of a large solitary deposit which can not be mistaken.

EVER-2004-abstractbook.indd 98 8/19/04 12:26:32 PM

1211
Clinical, Epidemiological and Immunopathogenic Aspects

MOCHIZUKI M
Dept. of Ophthalmology & Visual Science, Tokyo Medical and Dental University, Graduate School of Medicine, Tokyo

Purpose Vogt-Koyanagi-Harada(VKH) disease is an autoimmune disease against melanocytes. The disease is characterized by bilateral uveitis and inflammation in melanocyte-containing tissues, such as meninges, ear, skin and hair. The disease is common in pigmented ethnic groups, such as Japanese, but rare in non-pigmented ethnic groups. According to a nationwide survey on VKH disease in Japan, the incidence rate was estimated at 6.5 per one million, indicating 800 new cases a year throughout Japan. At our uveitis clinic in Tokyo, VKH disease is the third common cause, consisting of 6.2% of uveitis. As for the immunogenetics, it has been reported that VKH disease is highly associated with HLA-DR4 and the genomic type is DRB1*0405 or DRB1*0410. The characteristic clinical features of the disease and the high prevalence rate of the disease among pigmented people strongly suggest that the disease is autoimmune disease against melanocytes. However, it is still unknown what is the precise antigen in melanocyte-associated antigens responsible for the immunopathogenisity of the disease. Our recent studies demonstrated that infiltrating cells in the eye of patients with VKH disease contained a cell population of CD4-positive memory T cells that recognized melanocyte-associated antigens, i.e. tyrosinase450-462 peptide and GP10044-59 peptide. The immune response was HLA-DR4-restricted, dose-dependent, peptide-specific and disease-specific. This indicates that tyrosinase450-462 peptide and GP10044-59 peptide can be a potential candidate that play a role in the immunopathogenic mechanisms of VKH disease. We further investigate using database screening to search if the antigens might have molecular mimicry to exogenous pathogens and it was found that tyrosinase450-462 peptide had a homology in the amino acid sequence to cytomegalovirus envelope glycoprotein H(CMV-egH290-302). Furthermore, lymphocytes from patients with VKH disease showed a immunological cross reaction to the CMV peptide and tyrosinase peptide. CMV is a common virus and most of individuals are infected with the virus, though the infection was latent. CMV infection may play a role in the immnopathogenic mechanisms of VKH disease.

1212
Animal models of VKH

YAMAKI K (1), TAKIYAMA T (2), ITHO N (2), HAYAKAWA K (1), KAMEYA S (1)
(1) Ophthalmology, Akita University School Of Medicine, Akita
(2) Ophthalmology, Yokohaha city University School of Medicine, Yokohama

Purpose To establish the experimental Vogt-Koyanagi-Harada (VKH) disease model for serving to clarify the immune mechanism of the disease.

Methods Lewis rats, C57BL/6 mice, Akita dogs and rhesus monkey were used for experiments. The peptides were chemically synthesized to cover the entire protein sequences of tyrosinase family proteins, such as tyrosinase (TYR), tyrosinase related protein 1 (TR1), and tyrosinase related protein 2 (TYR2). The peptides or peptides mixture were immunized with CFA and inactivated Bordetella pertussis (BP). The dendritic cells and T cells were separated from naïve mice and were pulsed or primed with peptides in vitro. Thus treated dendritic cells or T cells were injected to naïve mice. Induction of the disease was examined clinically and histologically. Lymphocyte reactivity against the peptides was tested.

Results Immunizations of tyrosinase family proteins induced the VKH like disease in various kinds of experimental animals. Clinical and histological findings of the disease induced in the Akita dogs were almost identical to that of the spontaneously occurring dog VKH disease. In vitiro pulsed dendritic cells and/or primed T cells could induce the autoimmune disease in mice.

Conclusion Tyrosinase family proteins are antigens specific to VKH disease. Experimentally induced VKH like disease in dogs will be a good model for studying the pathogenesis of human VKH disease.

1213
Chemokines and matrix metalloproteinases in VKH

ABU EL ASRAR AM (1), STRUYF S (2), DESCAMPS FJ (2), AL-OBEIDAN SA (1), PROOST P (2), VAN DAMME J (2), OPDENAKKER G (3), GEBOES K (4)
(1) Department of Ophthalmology, Riyadh
(2) Rega Institute for Medical Research, Laboratory of Molecular Immunology, Leuven, Belgium
(3) Rega Institute for Medical Research, Laboratory of Molecular Imunology, Leuven, Belgium
(4) Laboratory of Histochemistry and Cytochemistry, Leuven, Belgium

Purpose Purpose: To investigate the involvement of the chemokines CXCL10/IP-10, CXCL11/ I-TAC, CXCL8/1L-8, CXCL6/GCP-2, CCL3/MIP-1 alpha and CCL18/PARC, and gelatinases A and B in uveitis.

Methods Aqueous humor (AH) samples from 30 patients with active uveitis, and 14 control patients and paired serum samples were assayed for chemokines with specific enzyme-linked immunosorbent assays and for gelatinase levels by quantitative zymography

Results In control AH, none of the chemokines was detected. Gelatinase A was detected in all samples, and gelatinase B was detected in only one sample. In patients with uveitis, IP-10 was detected in all AH samples, whereas I-TAC, IL-8, GCP-2, MIP-1α, and PARC were detected in 3, 16, 6, 2, and 12 samples, respectively. IP-10 levels were significantly higher in AH samples than those of serum ($p = 0.006$). Gelatinase A was detected in 29 AH samples and gelatinase B was detected in 26 samples. Gelatinase A levels were significantly higher in AH samples from patients than those of controls ($p < 0.0001$). In 11 AH samples, gelatinase B was detected in complex with lipocalin (NGAL). Disease activity correlated significantly with the levels of IP-10 ($r = 0.627$; $p < 0.0001$), gelatinase A ($r = 0.508$; $p = 0.002$), gelatinase B ($r = 0.685$; $p < 0.0001$), and NGAL-gelatinase B complex ($r = 0.595$; $p < 0.0001$).

Conclusion These data suggest a pathogenic role of the T lymphocyte chemoattractant IP-10 and gelatinases in the recruitment and activity of T cells into the eye in patients with uveitis and in the pathogenesis of uveitis.

1214
Ocular and systemic clinical signs and diagnosis in VKH

BODAGHI B
Ophthalmology, CHU Pitie-Salpetriere, 47 bd de l'Hopital, 75013, Paris, France

Purpose Vogt-Koyanagi-Harada (VKH) syndrome is a multisystemic disease. Its prevalence is higher in Asian, Middle Eastern, Latin American and Hispanic populations. The disease may occur in all ages, especially from the second to fourth decade of life, and predominantly in women. Diagnosis is based on clinical signs and symptoms with no definitive confirmatory diagnostic tests available. The natural history can be divided into different stages : an initial prodromal phase, characterized by meningeal signs, headache and tinnitus, followed, a few days later, by the acute phase which includes, a posterior segment inflammation, sometimes associated with a mild anterior uveitis. The inflammatory disease is granulomatous in nature. Then, the disease sets into a chronic or convalescent phase, which is defined by a progressive depigmentation of the skin and the fundus. The chronic phase may be interrupted by recurrent, mainly anterior, uveitis. The ophthalmologist should exclude differential diagnosis such as sympathetic ophthalmia, hepatitis C virus infection and intravascular lymphoma, especially in corticoresistant forms of the disease. The importance of a lumbar puncture remains controversial, even though pleiocytosis has been reported in more than 80% of cases, especially when it was performed in the early phase of the disease. Skin lesions occur in a large number of patients during the convalescent stage, whereas auditory difficulties are usually concomitant with the ocular disease. The diagnostic criteria established in 1978 by the American Uveitis Society have been revised in 2001. Based on the new criteria and preliminary data, it seems to be more difficult to diagnose the recurrent forms of VKH.

EVER-2004-abstractbook.indd 99 8/19/04 12:26:33 PM

■ 1215

Importance of ancillary and new imaging methods in VKH disease

HERBORT CP (1, 2)
(1) Inflammatory Eye Diseases, La Source Eye Centre, Lausanne
(2) University of Lausanne, Lausanne

Purpose The initial ocular inflammatory event in VKH selectively involves the choroid. It is only secondarily that structures like the retina, analysed by traditional fluorescein angiography (FA) are involved. Specific choroidal imaging is therefore very much needed to assess this predominantly choroidal disease. Among the new imaging methods, indocyanine green angiography (ICGA) allows to analyse the choroidal compartment and detects lesions not shown by other methods. OCT and UBM are 2 other imaging methods used in VKH.

Methods Imaging methods in VKH were analysed.

Results 1. Classical FA features will be shortly presented. 2. The signs of ICGA in VKH include hypofluorescent dark dots in the intermediate phase that become isofluorescent in the late phase or stay hypofluorescent, representing either partial or full-thickness granulomas of the stroma. The second characteristic sign is fuzzy leaking choroidal vessels in the early and intermediate angiographic phase followed by diffuse choroidal hyperfluorescence in the late phase. In very severe inflammation disc hyperfluorescence and pinpoints with subretinal fluid can be seen.The use of ICGA in the follow-up of VKH disease will be illustrated. 3. The contribution of OCT and UBM will be discussed.

Conclusion ICGA was shown to be very sensitive to detect subclinical choroidal inflammation and significantly influenced disease management by early diagnosis in inaugural disease and by monitoring subclinical recurrence of the disease. It will probably represent the mainstay for monitoring disease evolution, possibly avoiding the irremediable evolution towards sunset glow fundus by more adequate therapy. OCT that images lesions at a more advanced stage and UBM are useful but not essential in the appraisal of VKH disease.

■ 1216

Vogt-Koyanagi-Harada disease - Complications and Therapy

ABU EL ASRAR A
Department of Ophthalmology, Riyadh

Purpose -Vogt-Koyanagi-Harada (VKH) disease is a bilateral granulomatous panuveitis and exudative retinal detachments associated with poliosis, vitiligo, alopecia and central nervous system and auditory signs. The long term complications of VKH disease include cataract, secondary glaucoma, subretinal neovascular membranes, subretinal fibrosis, and severe chorioretinal atrophy. Systemic corticosteroids are the mainstay of therapy for VKH disease. Early and aggressive use of systemic steroids followed by slow tapering over 6 to 12 months may shorten the duration of the disease, prevent progression into chronic stage, prevent severe complications, and reduce the incidence of extraocular manifestations.

EVER-2004-abstractbook.indd 100 8/19/04 12:26:33 PM

1221
An overview of the TNM system and its objectives

KIVELA T, KUJALA E
Helsinki University Central Hospital, Department of Ophthalmology, Helsinki

Purpose To present the Tumor, Node, Metastasis (TNM) system for classifying malignant tumours, and to assess how its objectives are met in classifying uveal melanoma.

Methods Review of TNM editions 4, 5, and 6, which include classification of uveal melanoma.

Results The TNM system describes tumors by classifying them according to their anatomical extent, as determined before treatment. The description is supplemented or modified according to histopathologic data (pTNM). In principle, it requires all cases to be microscopically confirmed, which is rare for uveal melanoma. A key feature of the TNM system is grouping of anatomical tumor categories into prognostic stages, i.e. homogenous groups with respect to survival. Survival rates between stages should be as different as possible. The clinical stage is useful for selecting and evaluating therapy and the pathological stage provides the most precise data to estimate prognosis and end results. Edition 6 describes the anatomical extent of uveal melanoma on the basis of tumour diameter, height, and extraocular extension, whereas edition 4 and 5 additionally took ciliary body location into account. In edition 6, size boundaries resemble COMS classification. All editions inflate some category. TNM and pTNM of uveal melanoma are identical, which vastes data. Edition 4 and 5 translate tumour categories directly into stages. Edition 6 combines 2 categories with different prognosis into a single stage. These conventions do not follow the general principle of the TNM.

Conclusion An organized multicenter study along the lines set by investigators who developed staging for cutaneous melanoma is called for to critically construct, validate and implement a TNM system for uveal melanoma which is optimally based on anatomic extent and life prognosis.

1222
How should ciliary body extension be classified

DAMATO B (1), TAKTAK A (2)
(1) Ocular Oncology Service, Liverpool
(2) Department of Clinical Engineering, Liverpool

Purpose The purpose of this classification is to allow clinicians and scientists to describe and analyse ciliary body melanomas and their outcomes consistently so as to enhance prognostication and evaluation of treatment.

Methods Ciliary body melanomas should be defined as primary or secondary and described clinically according to: source; shape; growth pattern; anterior, posterior, inward, outward, and circumferential spread; dimensions, special features; and secondary effects. Histopathological and cytogenetic features should be recorded in the usual manner. The classification should be accompanied by a user-friendly recording form and a detailed examination protocol, both of which will need to be evaluated by workers in different units. The classification and any categorization of continuous data would need to be validated by outcomes analysis. We are completing an upgrade to our general ocular oncology database (Geoconda) and plan to develop this into a web based database for multicentre research.

Results The presentation will include examples of how a classification of ciliary body melanomas has already been used to describe these tumours and to report various outcomes after different forms of treatment.

Conclusion The European Ophthalmic Oncology Group can play an important role in developing an evidence-based classification of uveal melanoma.

1223
How should extraocular extension be classified

ZOGRAFOS L, FOR THE OPHTHALMIC ONCOLOGY TASK FORCE
University Eye Clinic of Lausanne, Lausanne

Purpose To assess classification of extraocular extension.

Methods Propositions based on the experience in the University Eye Clinic of Lausanne will be communicated in writing for discussion.

1224
What are additional clinical tumor characteristics that should be considered for the classification

DESJARDINS L (1), PLANCHER C (2), LUMBROSO l (1), LEVY c (1), DENDALE r (3), ASSELAIN B (2)
(1) Ophthalmology, Paris
(2) Biostatistics, Paris
(3) Radiotherapy, Paris

Purpose To determine if additionnal clinical characteristics should be considered in the classification of uveal melanoma we performed a retrospective study on all tumour characteristics registered in our database.

Methods Patients sent to Curie Institute for uveal melanoma have a complete initial workshop. Patients and tumour characteristics are registered and entered in a database . Tumours characteristics include location, retinal detachment, optic nerve (or disk) involvment, extrascleral extension, vitreous hemorrhage, tumour diameter, tumour thickness and pigmentation. We performed a multivariate analysis to know what initial tumour characteristics have an impact on the outcome.

Results 2241 patients were registered with a median follow up of 72 months . The mean age is 59,5 years; Median tumour diameter is 12,8 mm and median tumour thickness is 5,7 mm. Enucleation was performed in 7,2% of patients and radiotherapy in 92,8%. The overall survival is 76,3%, metastatic rate is 19,5 %, local reccurrence rate is 3,5 % and enucleation for other cause after radiotherapy is 6,5%. Tumour size is a significant risk factor for survival (p<0,0001), metastasis (p<0,0001), local reccurence (p:0,049) and ocular preservation (p<0,0001).Tumor location is a significant risk factor for survival (p<0,0001) and metastasis (p<0,0001) retinal detachment is a significant risk factor for metastasis (p:0,01) and for ocal reccurrence (p : 0,005)

Conclusion In addition to size, location and extrascleral extension associated retinal detachment should be considered as a risk factor for poor outcome

EVER-2004-abstractbook.indd 101 8/19/04 12:26:34 PM

1225

What are the histopathological tumor characteristics that could be considered for classification

SEREGARD S
St Eriks Eye Hospital and Karolinska Institutet, Stockholm

Purpose There is no universally adopted classification system of uveal melanoma. Most classification system for other tumors rely on the TNM classification, but this system is rarely used in everyday ocular oncology. A classification which would gain widespread acceptance needs to be developed. Ideally such a classification should correlate with prognosis.

Methods A review of the literature based on papers using histopathologic parameters to assess prognosis or classify uveal melanoma.

Results The most often used parameters obtained after histopathologic evaluation include simple measurements (e.g. tumor height and largest tumor diameter), site of orgin (e.g. posterior choroid, anterior choroid and ciliary body), local aggressive behavior (rupture of Bruch´s membrane or, neuroinvasive pattern), degree of infiltration (e.g. scleral or extraocular growth), tumor cell type (e.g. spindle, epitheloid or mixed pattern), cycling tumor cells (quantitative or semi-quantitative assessment). Special techniques allow for detection of specific proteins or cells, e.g. tumor-infiltrating macrophages or vascular density, so-called fibrovascular patterns. The reproducibility and prognostic value are unclear for many parameters.

Conclusion Only some of the parameters have a confirmed prognostic value and a high degree of reproducibility. Ideally, any histopathologic parameter used for classification of uveal melanoma should also be possible to evaluate in a biopsy sample.

EVER-2004-abstractbook.indd 102 8/19/04 12:26:34 PM

■ 1231

Ocular (side-) effects of pharmaceutical compounds and their specific interaction with cataract development

WEGENER A
Department of Ophthalmology, Rheinische Friedrich-Wilhelms-Universität, Bonn

Purpose Ocular side-effects of pharmaceutical compounds are an important feature in drug development often hampering their further clinical application. They mostly become evident in longterm studies in rodents which does not exclude appearance of ocular side-effects only in higher species like dogs and monkeys. Slitlamp microscopy and ophthalmoscopy are standard optical instrumentation to detect morphological ocular abnormalities, but special techniques like Scheimpflug photography and optical coherence tomography are necessary to detect more subtile changes. Another option to detect subliminal oculotoxic effects is the involvement of animal models for specific cataract development or retinal degeneration which allow combination with a drug treatment. Among these are the naphthalene, diabetes and UV cataract model which all proved to be suitable for drug side-effect studies. Among the vast number of compounds which produced unspecific ocular side-effects, quinolones have been investigated in detail with respect to their co- or syncataractogenic potential and retinotoxic effects. A larger selection of the hydantoins and several other chemical compounds have also been tested with respect to their cataract preventive effects. It could be demonstrated that most of the side-effects detected during drug development where unspecificly toxic either touching the retina or the lens. Only the minority demonstrated effects on specific biochemical pathways. In addition, ocular side-effects in some compounds were species specific and could not be detected or reproduced in a second species which often ment that they also did not appear in humans. Ocular pharmaco-kinetic in these studies was mostly poorly understood.

■ 1232

Maximum tolerable dose for ultraviolet radiation induced cataract on repeated exposures with 30 days time interval

DONG X (1), SÖDERBERG P (1), LÖFGREN S (1), AYALA M (1, 2), MODY V (1), KAKAR M (1), MEYER L (1)
(1) St.Erik's Eye Hospital, Karolinska Institutet, Stockholm
(2) Ophthalmology department, Örebro University Hospital, Örebro

Purpose To investigate the impact of repeated exposure with 30 days time interval on maximum tolerable dose (MTD) for ultraviolet radiation induced cataract.

Methods A total of 36 six weeks old female Sprague-Dawley rats were included in the experiment. The time interval between the two repeated exposures was 30 days. The dose-sub groups were 0, 2, 3, 4 and 5 kJ/m2, and 4, 6, 8, and 10 kJ/m2. One eye of each rat was exposed to ultraviolet radiation (lmax=300 nm, l0.5=10 nm). The other eye was kept as a control. The exposure time was 15 minutes. One week after the second exposure, the rats were sacrificed and both lenses were extracted. The intensity of forward light scattering was measured and morphological changes were documented by photography with dark field illumination. MTD was estimated based on the experimentally determined dose-response function.

Results The MTD for ultraviolet radiation induced cataract for the time interval 30 days between two exposures was estimated to be 3.9 kJ/m2.

Conclusion The MTD for two repeated exposures, is higher for long inter exposure time intervals than for short, when the cumulated dose for the two exposures is kept constant.

■ 1233

Metabolic changes in the anterior segment of the eye induced by UV irradiation and measured by NMR spectroscopy

MIDELFART A (1, 2), RISA Ø (3, 4), SÆTHER O (3), TESSEM MB (3), FRIS M (3), SØDERBERG PG (5), CEJKOVA J (6)
(1) Dep.of Ophthalmology, Faculty of Medicine, Norwegian University of Science and Technology, Trondheim
(2) St.Olavs Hospital HF, Trondheim
(3) Faculty of Medicine, Norwegian University of Science and Technology, Trondheim
(4) Faculty of Natural Sciences and Technology, Trondheim
(5) St.Eriks Hospital. Karolinska Institutet, Stockholm
(6) Czech Academy of Sciences, Prague

Purpose To apply high resolution Magic angle spinning nuclear magnetic resonance (MAS –NMR) spectroscopy for a study of metabolic changes in cornea and lens directly in tissue samples, i.e. avoiding tissue extraction. Metabolic changes induced by a) UV radiation and b)combination of UV radiation and topical steroid treatment of the eyes were investigated in animal models.

Methods Samples of aqueous humour, cornea and lens from rabbits or rats exposed to UV B or UV A irradiation or combination of UV B irradiation and topical steroid treatment were analysed with NMR spectroscopy. Samples from aqueous humour were analysed by High resolution proton NMR spectroscopy, while MAS –NMR spectroscopy was applied for samples from cornea or lens.

Results Excellent quality of NMR spectra was obtained with MAS NMR spectroscopy comparable to spectra obtained previously with tissue extracts. It was possible to identify a large number of metabolites in each sample. Significant changes in concentration of many water-soluble metabolites including taurine, hypotaurine, myositols, ascorbate, glutathione and several amino-acids were revealed after the UV irradiation of the eyes. The metabolic changes were more profound in steroid pre-treated eyes and in eyes irradiated with UV B than UV A.

Conclusion High resolution MAS –NMR spectroscopy is found to be a suitable method for direct analysis of metabolic profile in cornea and lens. Avoiding extraction, the risk of modification of substances and possible loss from the samples could be minimized. Large number of metabolites was detected in each sample providing possibility to characterise complex metabolic response in the tissue to pathophysiological stimuli

■ 1234

Oxidative stress and intercellular communication

PEREIRA P, FERNANDES A, FERNANDES R, CATARINO S, GIRAO H
IBILI - Centre of Ophthalmology, Coimbra

Purpose The purpose of this study is to establish the effect of oxidative stress and high glucose in intercellular communication through gap junctions (GJIC) and Cx43 degradation in lens epithelial cells and retinal endothelial cells.

Methods Primary cultures of lens epithelial cells or retinal endothelial cells were exposed to oxidative stress or high glucose in the presence or absence of proteasome inhibitor MG132. The levels of Cx43 were assessed by western blot. The contribution of the proteasome for the degradation of Cx43 upon exposure to oxidative stress or high glucose was evaluated by metabolic labelling of Cx43 with [35S]-methionine. Subcellular distribution of Cx43 was determined by immunofluorescence confocal microscopy. GJIC was evaluated by transfer of the dye Lucifer yellow.

Results The levels of Cx43 in cell cultures exposed to oxidative stress or high glucose decreased as compared to controls as did the half-life of the protein. The proteasome inhibitors prevented the loss of Cx43 and extended Cx43 half-life. The amount of phosphorylated Cx43 increased both in high glucose and following oxidative stress, while GJIC decreased. Significantly, this reduction can be reverted by proteasome inhibitors. The decreased GJIC is apparently associated with loss of Cx43 from the plasma membrane as demonstrated by immunofluorescence and biotinylation of cell surface proteins.

Conclusion Both oxidative stress and high glucose lead to a decrease of GJIC presumably by a similar mechanism, that involves hyperphosphorylation of Cx43 and targeting of membrane Cx43 for degradation by a proteasome-dependent mechanism. Moreover, the mechanism whereby hyperglycaemia leads to reduced GJIC is al least in part associated with increased oxidative stress.

EVER-2004-abstractbook.indd 103 8/19/04 12:26:35 PM

1235 / 183

P53 expression in the lens after ultraviolet radiation (UVR) exposure

AYALA MN (1, 2), STRID H (3), DONG X (4), SÖDERBERG PG (4)
(1) Eye Department, Örebro University Hospital, Örebro
(2) Research Department St. Erik's Eye Hospital, Stockholm
(3) Clinic Research Centre, Örebro University Hospital, Örebro
(4) St. Erik's Eye Hospital, Karolinska Institutet, Stockholm

Purpose Background: The tumor-suppressor gene p53 encodes a phosphoprotein involved in the control of cell growth. Its expression and function have been documented in malignancy, apoptosis, and other abnormal cell proliferation processes. Apoptosis due to UVR is a well-described process in the lens. Recently, expression of p53 has been demonstrated in the normal murine eye. Purpose: to localize p53 in the albino rat lens and to study if p53 expression increases due to UVR exposure.

Methods Altogether 10 Sprague-Dawley albino rats were unilaterally exposed to UVR meanwhile the other eye was used as control. 1 week after exposure the rats were sacrificed, lenses were extracted, 10 lenses (5 exposed and 5 no exposed) were analysed by immunohistochemistry to localize p53 and 10 lenses (5 exposed and 5 no exposed) were analysed by real-time PCR to estimate p53 expression.

Results Immunohistochemistry showed that p53 was localized in the lens epithelial cells. Real-time PCR showed that P53 expression was higher in lenses exposed to UVR than in no exposed lenses.

Conclusion In the lens apoptosis induced by UVR seems to be mediated by P53 increased expression.

EVER-2004-abstractbook.indd 104 8/19/04 12:26:35 PM

■ 1241

Molecular mechanisms of emmetropization and experimental myopia

BEUERMAN R (1, 2), BARATHI A (1), WEON SR (1)
(1) Singapore Eye Research Institute, Singapore
(2) National University of Singapore, Singapore

Purpose Human and mouse scleral fibroblasts are shown to have muscarinic receptors, a type of receptor whose intra-cellular pathways can control a large number of cell functions including proliferation and cell differentiation. These pathways are complex and cell specific. The studies presented here have examined the pharmacology of the muscarinic receptor types.

Methods Human and mouse scleral fibroblasts were cultured and used at passages 2-4. Muscarinic pharmacological probes: carbachol, atropine, pirenzepine, himbacine, and 4-DAMP were used over the concentration range (0.1 to 100 μM). Activated MAPK was measured by ELISA. Proliferation was measured by BrdU uptake using an ELISA assay. All tests were run in quadruplicate from at least three independent experiments. The M1 selective toxin, MT7, was used at 0.5 to 4 μM.

Results We were able to demonstrate the five types of G-protein coupled muscarinic receptors in human (HSF) and mouse scleral fibroblasts (MSF) using western blots, real-time PCR, and RT-PCR. In HSFs and MSFs, atropine significantly blocked proliferation and carbachol increased proliferation in a dose dependent fashion while blocked carbachol stimulation of proliferation in HSFs and MSFs. Pirenzipine blocked non-stimulated proliferation at 1.0 μM in HSFs and at 10 μM in MSFs. In addition, MT7, which is a highly selective antagonist for the M1 receptor, strongly blocked proliferation in MSFs at 0.1 μM. Himbacine and 4-DAMP (0.1 μM) decreased proliferation, but did not show a defined dose-response profile. Activated MAPK was significantly decreased by about 30% at 0.1 μM atropine.

Conclusion The present results are consistent with active muscarinic control of proliferation. It is suggested that muscarinic receptors have a prominent role in the biology of these cells during development and in experimental myopia. Supported by NMRC, Singapore.

■ 1242

Genetics of human refractive errors

YAP E
Singapore

■ 1243

Myopia: prevalence rates and risk factors

SAW SM (1, 2, 3)
(1) Community, Occupational and Family Medicine, National University of Singapore, Singapore
(2) Singapore Eye Research Institute, Singapore
(3) Ophthalmology, National University of Singapore, Singapore

Purpose Myopia is a huge public health problem, especially in East Asian countries. We aim in this talk to review the prevalence rates of myopia worldwide in children and adults, as well as the major environmental risk factors for myopia.

Methods Data from published well-designed studies will be cited and results of the School Cohort study Of the Risk factors for Myopia (SCORM) will also be presented. In brief, cycloplegic autorefraction and biometry measures are conducted annually in 1979 children aged 7 to 9 years at baseline recruited from 3 schools in Singapore.

Results The prevalence rates of myopia (spherical equivalent at least -0.5 Diopters) are highest in East Asian countries such as Singapore (38.7% in Chinese aged 40 to 79 years) compared with the United States (22.7% in adults 40 years or older in Baltimore) or Australia (15% in adults 49 to 97 years in the Blue Mountains Eye Study). The Refractive Error Study in Children (RESC) uses the same methodology and the rates of myopia in children are highest in China (55% in 15 year olds) and lower in Chile (19.4% in 15 year old males). In the SCORM study, children who read more than 2 books per week had 3 times higher risks of higher myopia (spherical equivalent at least -3.0 Diopters) and children who were taller had longer axial lengths and were more likely to be myopic. Nonverbal IQ test scores were positively associated with myopia even after controlling for reading.

Conclusion The rates of myopia vary across countries and are highest in East Asia. Both genetic susceptibility and exposure to environmental factors may contribute to this perceived epidemic. The major risk factors for myopia in children are reading, height and non-verbal IQ.

■ 1244

Myopia and associated ocular morbidity

WONG TY (1, 2)
(1) Singapore Eye Research Institute, National University of Singapore, Singapore
(2) Centre for Eye Research Australia, University of Melbourne, Melbourne

Purpose High myopia is known to be associated with serious ocular complications such as retinal detachment and choroidal neovascularization. The purpose of this study is to review the ocular morbidity associated with mild and moderate levels of myopia in the general population.

Methods Data from population-based studies were reviewed to examine the association of myopia with cataract, glaucoma and age-related maculopathy.

Results Several studies show a cross-sectional association between myopia and nuclear cataract in adults above 40 years. In the Blue Mountains Eye Study (BMES), a myopic refraction was also related to posterior subcapsular cataract, even when controlling for severity of nuclear sclerosis. In the Tanjong Pagar Study, posterior subcapsular cataract was associated with a myopic refraction and longer vitreous chambers. However, myopia was not associated with 5-year incident nuclear, cortical or posterior subcapsular cataracts in the Beaver Dam Eye Study (BDES). A cross-sectional association between myopia and glaucoma was seen in the BMES, BDES and the Barbados Eye Study, but myopia was not related to 5-year incident glaucoma in the BDES. An inverse association between myopia and age-related maculopathy was found in the BMES, but no association was found between myopia and 10-year incident age-related maculopathy in the BDES.

Conclusion Mild to moderate myopia is not consistently associated with cataract, glaucoma or age-related maculopathy in the general adult population. Public perception of blindness from myopia may be unwarranted

EVER-2004-abstractbook.indd 105 8/19/04 12:26:35 PM

■ 1245

Clinical trials of lens treatment of myopia control

GWIAZDA J
Vision Science, Boston, MA

Purpose To review recent clinical trials of spectacle lens treatments for slowing the progression of myopia in children

Methods In most studies progression of myopia was measured with cycloplegic autorefraction, and axial length was measured with A-Scan ultrasonography. Children were randomized to either the conventional spectacle treatment for myopia of single vision lenses (SVLs) or progressive addition lenses (PALs).

Results Treatment effects from recent, well-designed studies ranged from 0.14 to 0.57 D at the end of 2 to 3 ears. In many of the trials, the treatment effect was observed at the end of the first year and was sustained at the same level for the duration of the study. While most of these results were statistically significant, they did not warrant a change in clinical practice. Additional analyses of data from the Correction of Myopia Evaluation Trial (COMET), a multi-center, randomized clinical trial of PALs vs SVLs in the United States, showed that statistically significant 3-year treatment effects were found for children with poor accommodation in combination with near esophoria (0.64D), lower amounts of myopia (0.48D), shorter reading distances (0.44D), or more hours of weekly near work (0.42D). These treatment effects were significant at one year and became larger between 1 and 3 years.

Conclusion In clinical practice in the United States children with poor accommodation and/or near esophoria often are prescribed PALs or bifocals to improve visual performance. Such children, if myopic, may have an additional benefit of slowed progression of myopia. The results also suggest that lens treatments are likely to be effective in subsets of myopic children with specific risk profiles.

■ 1246

Clinical trials of atropine and pirenzipine to retard myopia

TAN D (1, 2, 3), CHUA W H (1, 2)
(1) Singapore Eye Research Institute, Singapore
(2) Singapore National Eye Centre, Singapore
(3) Dept of Ophthalmology, National University of Singapore, Singapore

Purpose Evaluation and comparison of two recent randomized clinical trials evaluating the use of antimuscarinic agents atropine and pirenzepine for controlling the progression of myopia in children.

Methods The Atropine in the Treatment Of Myopia (ATOM) study and the Pirenzepine Gel (PIR) study were randomized, double-masked, placebo-controlled trials involving Asian children aged 6-12 years. In ATOM, 400 children (myopia of -1.00 D to -6.00 D) received either 1% atropine eye drop or Isoptotears daily for 2 years. In PIR, 353 children (-0.75 to -4.00 D) received 2% PIR b.i.d. (PIR/PIR), 2% PIR q.d. (evening, PLC/PIR) or placebo b.i.d. (PLC/PLC) in a 2:2:1 ratio for 1 year. Primary efficacy outcome was refractive error (cycloplegic autorefraction) and secondary efficacy outcome was axial length (ultrasound A-scan).

Results In ATOM, the mean 2-year myopia progression and axial elongation in the placebo-control eyes were -1.20 D ± 0.69 D and +0.38 mm ± 0.38 mm. In atropine-treated eyes, myopia progression was -0.28 D ± 0.92 D while axial length remained unchanged. Differences in myopia progression (-0.92 D 95% CI -0.77 to -1.07 D) and axial elongation (0.39 mm 95% CI 0.32 to 0.47 mm) between groups were statistically ($p < 0.0001$) and clinically significant. In PIR, at 1 year there was a mean myopia progression of -0.47 D, -0.70 D, and -0.84 D in the PIR/PIR, PLC/PIR, and PLC/PLC groups, ($p < 0.001$ for PIR/PIR vs. PLC/PLC). Mean increase in axial length was greatest in PLC/PLC, followed by PLC/PIR then PIR/PIR groups (0.33, 0.30 and 0.20 mm($p = 0.008$).

Conclusion Pharmacological intervention with atropine and pirenzepine eyedrops are effective in reducing myopia progression in children in the short term. Further studies to elucidate long term safety and efficacy are required.

EVER-2004-abstractbook.indd 106 8/19/04 12:26:36 PM

■ 1251

Intravitreal Triamcinolone Acetonide for Retinal Diseases: Increased Risk of Repeat Injections?

KREISSIG I, JONAS J, DEGENRING R, KAMPPETER B
Ophthalmology of University, Mannheim

Purpose To evaluate risks of repeat injections of 20 mg intravitreal triamcinolone acetonide (TA) for retinal diseases.

Methods Prospective clinical interventional case-series study (46 patients = 47 eyes) with at least 2 intravitreal injections of about 20 mg TA: Exudative AMD (n=23), secondary angle-closure glaucoma (n=7), diffuse diabetic macular edema (n=6), central/branch retinal vein occlusion (n=7), others (n=4). 2nd injection (n=47) 6.7 months after 1st, 3rd (n=9) 8.0 months after 2nd, 4th (n=2) 9.5 and 10.8 months after 3rd; 1 eye 6 injections. Mean follow-up after 1st injection 20.7 months, after last 10.0 months. Intravitreal TA injection under sterile conditions.

Results 47 eyes no: lens subluxation, pseudophakos, infectious or sterile endophthalmitis. After 1st injection IOP < 21 mmHg in 24 of 47 eyes (51%), after 2nd in 25 of 47 (53%), after 3rd in 5 of 9 (56%), after 4th in 1 of 2 eyes, after 6th in 1 eye. IOP > 21mmHg controlled in 22 of 23 eyes by antiglaucomatous drops; in 1 eye IOP-rise after 2nd injection to 60 mmHg controlled by trabeculectomy. Eyes with no IOP increase > 21 mmHg after 1st injection, usually no increase after repeat injections. Mean maximal IOP after 1st, 2nd, 3rd, and 4th injection varied not significantly (p >0.50): 22.0 mmHg (n=47) versus 22.6 mmHg (n=47) versus 22.9 mmHg (n=9), versus 14 mmHg and 18 mmHg (n=2).

Conclusion Repeat injections of about 20 mg intravitreal TA might be tolerated during mean follow-up of 21 months after 1st injection and 10 months after last injection. Increase of IOP > 21 mmHg was no more pronounced after 2nd or subsequent injections than after 1st injection, there was no sterile or infectious endophthalmitis.

■ 1252

Morphologic Changes in Diabetic Macular Edema After Intravitreal Triamcinolone Acetonide

KARACORLU M (1), OZDEMIR H (1), KARACORLU S (1), ALACALI N (2)
(1) Istanbul Retina Institute, Inc., Istanbul
(2) Dept. of Opthalmology, Diabetes Foundation Hospital, Istanbul

Purpose To evaluate the morphologic changes in diabetic macular edema after intravitreal triamcinolone acetonide.

Methods Fourty-six eyes of 32 patients with diabetic macular edema who received intravitreal triamcinolone acetonide injection was evaluated. Before treatment eyes were divided in to 3 groups according to optical coherence (OCT) findings. Group I: Eyes with cystoid macular edema (CME) (n=20 eyes), Group II: Eyes with CME and diabetic hard exudates (n=12 eyes), Group III: Eyes with CME and serous macular detachment (n=14). After treatment morphologic changes in the macula was determined by serial OCT examination.

Results After treatment in group I 19 eyes (95%), in group II 10 eyes (83.3%) and in group III 13 eyes (92.8%) showed disapparence in CME. In group II no eyes showed changes in hard exudates. In group III 12 eyes (85.7%) showed disappearence in serous macular detachment.

Conclusion Besides CME, intravitreal triamcinolone acetonide seems to be an effective therapy for the treatment of serous macular detachment in diabetic eyes. Presence of serous macular detachment or hard exudate do not effect the effectiveness of triamcinolone acetonide on the CME.

■ 1253

Evaluation of Macular Changes, Using Ocular Coherence Tomography (OCT) After Photodynamic Therapy and Intravitreal Triamcinolone in CNVM

TEUS MA (1, 2), ALVAREZ MT (2), ARRANZ-MARQUEZ E (2), MARTIN B (2)
(1) University of Alcalá, Madrid
(2) Vissum Madrid, Madrid

Purpose To quantify the morphologic changes in the macular area after PDT and intrevitreal triamcinolone in CNVM eyes

Methods This is a prospective, single masked study. 10 eyes with CNVM candidates to PDT were evaluated using OCT before and after PDT with adjunctive intravitreal triamcinolone injection. Measurements were performed before and 2 days, 2 weeks and 6 weeks after therapy.

Results We did find a significant decrease in total macular volume and foveal thickness (p=0.03 and p= 0.01 respectively). We did find a significant hyperopic refractive change in the first visit (p=0.03)

Conclusion OCT is a valid method to evaluate morphologic changes in the macular area after PDT. These changes could be clinically relevant.

■ 1254

Posterior juxtascleral delivery of anecortave acetate for treatment of exudative AMD

COSCAS G, SOUBRANE G, SOUIED E
CHI Créteil, Créteil

Purpose Anecortave Acetate is a structural analogue of cortisol acetate which structure has been irretrievably altered to eliminate pharmacological activities typically associated with steroids. During development of delivery methods, topical and subconjunctival administrations resulted in subtherapeutic posterior chamber concentrations. Oral and other systemic routes were not satisfactory due to rapid systemic metabolism. An original, safe and effective delivery method of posterior juxtascleral depot was developed.

Methods A blunt-tipped cannula, bent to follow the curvature of the globe, was designed to deposit Anecortave Acetate near the macula. The simple delivery procedure involves a 1-1.5 mm conjunctival incision 8 mm from limbus, in the superotemporal quadrant midway between the insertion location of the superior and lateral rectus muscles followed by dissection to bare sclera. No conjunctival suture is needed. When delivered using this method, animal studies show that therapeutic concentrations of the drug can be found in the choroid and retina up to 24 weeks.

Results The cannula has safely been used to administer Anecortave Acetate in 10 completed or ongoing clinical trials in patients with AMD. After more than 2,000 depot administrations, there have been no serious adverse events associated with the cannula, the administration procedure or the drug. The procedure was found to be non-traumatic, with little or no pain and can be performed in an outpatient setting.

Conclusion Delivery of Anecortave Acetate as a juxtascleral depot with a specifically designed cannula has been shown in clinical trials to be a safe and effective method of achieving therapeutic levels of the drug in the choroid and retina.

EVER-2004-abstractbook.indd 107 8/19/04 12:26:36 PM

■ 1255

Photodynamic therapy combined with intravitreal triamcinolone to treat CNV: preliminary results

RUIZ MORENO JM (1, 2), BARILE S (2), MONTERO J (2)
(1) Department of Ophthalmology, Miguel Hernández University School of Medicine, Alicante
(2) Instituto Oftalmológico de Alicante, Vitreo-Retinal Unit, Alicante

Purpose Purpose: To evaluate angiographic and functional results after treating subfoveal Choroidal Neovascularizartion (CNV) with Photodynamic therapy (PDT) combined with intravitreal injection of triamcinolone.

Methods Methods: We studied the results obtained at 6 months after treating subfoveal CNV in 16 patients with PDT with VisudyneÒ follow by intravitreal injection of 17 mg/0,1 ml of triamcinolone five days later.Mean age was 76,5±9,2 years (range, 62-85). In 14 cases the CNV was associated to ARMD and in 2 cases due to high myopia. The parameters evaluated were: Best Corrected Visual Acuity (BCVA), angiographic leakage and number of treatments with PDT at 3 and 6 months and changes in the intraocular pressure (IOP).

Results Results: Mean BCVA was: initial 0,22±0,16 (range, 0,1-0,6), at 3 months 0,26±0,15 (range, 0,12-0,6) at 6 months 0,27±0,12 years (range, 0,1-0,5). At 3 months leakage of the CNV was present in 6 patients and at 6 months in 6 patients. At 3 months 8 patients were retreated with PDT and at 6 months 4 patients. IOP rise in 12 cases.

Conclusion Conclusions: PDT combined with intraviteal injection of triamcinolone could be a good option to treat subfoveal CNV. These preliminary results need to be confirmed by longer follow-up and great number of patients.

■ 1256 / 140

Reinjection Rates of Intravitreal Triamcinolone

YILMAZ G, GEDIK S, AKKOYUN I, AKOVA Y
Baskent University Faculty of Medicine, Department of Ophthalmology, Ankara

Purpose To determine the indications and reapplying rates of intravitreal 'triamcinolone acetonide' (TA) injections and to assess the causes of repeating the injection procedures.

Methods The records of 150 patients who were treated with intravitreal TA (4mg/0.1ml) injections were evaluated retrospectively. Pre- and post injection visual acuities, intraocular pressure (IOP) measurements and fundus fluorescein angiography (FFA) findings were recorded. The TA injection indications and number of reinjections per eye were analyzed.

Results Ninety women, 60 men total of 150 patients with a mean age and follow-up period of 65 years and nine months, respectively, were enrolled into the study. The distribution of TA injections were as follows: 121 eyes of 97 patients for refractory diabetic macular edema (Group I); 30 eyes of 30 patients for macular edema due to retinal vein occlusions (Group II); 11 eyes of 11 patients for pseudophakic cystoid macular edema (Group III), 14 eyes of 12 patients for uveitic macular edema (Group IV). A total of 145 injections have been carried out for 121 diabetic eyes; 33 injections for group II; 14 injections for group III and 16 injections for group IV. The reinjections rates were 19.8% in group I, 10% in group II, 27.2% in group III and 14.2% in group IV.

Conclusion Intravitreal TA may be effectively used in many ocular conditions like refractory diabetic macular edema, pseudophakic cystoid macular edema, retinal vein occlusions and chronic cystoid macular edema associated with uveitis. Pseudophakic cystoid macular edema is the most refractory disorder among these disorders.

EVER-2004-abstractbook.indd 108 8/19/04 12:26:37 PM

■ 1261

Corneal regeneration with the use of autologous plasma rich growth factors (PRGF)

ABAD M, SCORSETTI D, RODRIGUEZ-PRATS JL, ALIÓ JL
VISSUM Instituto Oftalmológico de Alicante , R&D, Alicante

Purpose Application of topical autologous PRGF (plasma rich growth factors) combined with amniotic membrane transplantation to promote corneal tissue regeneration.

Methods In persistent corneal epithelium defects, autologous PRGF was used in combination with amniotic membrane transplantation. Growth factors released from the platelets include transformig beta type GF (TGF-β), platelets derived GF (PDGF), epithelial GF (EGF), fibroblastic GF (FGF), endothelial vascular GF (VEGF) and insulin type 1 GF (IGF-1). These factors signal the local mesenchymal and epithelial cells to migrate, proliferate and differentiate. The autologous blood was obtained by venipuncture and centrifuged. Concentrated platelets were activated by calcium chloride formating a clot that was applicated immediatly over the ocular defect. In cases of non surgical corneal epithelium defects PRGF eye drops were applied 6 times/day.

Results 10 eyes were evaluated until epithelial wound closure. Patients were followed up for 6 months. A complete corneal re-epithelialization was achieved in 100% of cases. This novel therapy was found to be highly successful in severe corneal perforations.

Conclusion The combination of amniotic membrane transplantation with autologous PRGF therapy leads to speeding healing up in cases of chronic corneal ulcers and perforation. This novel and potentially promising technique can be considered as an effective and easy therapy without adverse events which stimulates tissue regeneration in pathologic conditions.

■ 1262

Impression Cytology in the Follow-up of Ocular Burns treated with Amniotic Membrane Transplantation

BALAYRE SB, GICQUEL JJG, DIGHIERO PLD
Ophthalmology, Poitiers

Purpose To report the use of impression cytology in the follow-up of severe ocular burns treated with Amniotic Membrane Transplantation (AMT).

Methods Based on a retrospective study on 20 patients, we'll evaluate the gain of impression cytology in the follow up of of Grade II to VI ocular burns treated with AMT. Impressions cytology samples were obtained with Supor® filters (Gelman / Ann Harbor) before treatment on patient arrival, and during the follow up (Day 5, 10 and 30). Samples are stained with PAS (Periodic Acid Schiff), Alcian blue and studied in direct immunofluorescence as well as flow cytometry.

Results CMH class II (HLA-DR) (that constitutes a major eye surface inflammation marker) antigenic expression study seems to give new elements in term of prognosis of severe ocular burns.In the meantime, PAS/Alcian blue staining, evaluating the mucous quality of the conjunctiva, gives new objective elements in the follow up of these patients.

Conclusion Severe ocular burns prognosis has been changed thanks to AMT. The new 6 grades Dua classification has improved therapeutic decisions. However, clinical follow-up is based on slit lamp examination and might be insufficient in order to precisely adapt the treatment. Impression cytology is a simple, atraumatic, reproductible technique that helps choose and adapt treatment of severe ocular burns and improves follow up quality.

■ 1263

Amniotic Membrane transplantation for severe bacterial keratitis

BALAYRE SB, GICQUEL JJG, MERCIE MM, DIGHIERO PLD
Ophthalmology, Poitiers

Purpose To determine whether amniotic membrane transplantation (AMT) can be used as adjunctive therapy to promote severe bacterial keratitis healing and improve final BCVA.

Methods Retrospective, comparative case series featuring patients with severe acute bacterial keratitis: 12 treated with topical antibiotherapy and delayed corticotherapy / 9 treated with AMT associated with immediate maximal topical antibiotic and corticosteroid treatment. Single or multilayer graft with epithelial side was performed. Main outcome measurements were pain relief, wound healing of the corneal ulcerations, decrease of stromal inflammation and BCVA.

Results The mean follow up was 9 months (6 to 17 months). AMT was performed once in 7 cases and twice in 2 cases. Improvement of pain was immediate after surgery in all cases with AMT, although most patients were still suffering after 5 days in the non grafted group. Epithelial defects healed within a mean of 4 days (range 3-9 days) in the AMT group, though it took 10 days in the other group (range 6-15 days). Stromal necrosis extension was more limited and improvement of stromal inflammation was noted more quickly in the AMT group (within 7 days (range 5-15 days) versus 16 days (range 11-21). Mean final BCVA was 20/40 in the AMT group versus 20/63 in the non grafted one.

Conclusion In this first series of AMT used in association with steroids and antibiotic topical treatment, we found that our new protocol enabled faster epithelial healing, helped to stop stromal inflammation, and most of all achieved better final BCVA.

■ 1264

Triggering of endothelial cell mitosis by electric pulses

THURET G (1), MANISSOLLE C (1), CAMPOS-GUYOTAT L (1), GARRAUD O (2), GAIN P (1)
(1) EA3063 Lab 'Cell survival and adherence', Faculty of Medicine, Saint-Etienne
(2) French Blood Center Loire/Auvergne, Eye Bank, Saint-Etienne

Purpose To report results of a new technique that triggered cell divisions in adult human corneal endothelium. During ex vivo gene electrotransfer experiments, we constantly observed endothelial cells with a modified morphology of their cytoplasm and nucleus consistent with mitosis

Methods We retrospectively analysed all corneas electroporated during 6 months (current parameters: 8 pulses of 100ms, 1 Hz, 135 mA) as well as non electroporated controls. On permanent flat mounts, counterstained with hematoxylin, we counted the mitosis and determined the mitosis phase

Results All electroporated corneas, but only they, carried dividing endothelial cells independently of the presence of exogenous DNA for gene transfer. The first mitosis were observed 24 hours after electroporation and picked at 72 hours. Exceptionally, a few mitosis was observed at day 14. Their number was extremely variable (from 5 to 400 mitosis per cornea), but markedly similar for paired corneas. It did not correlate with donor age. Noticeably, dividing cells were mostly located at the periphery of the endothelium. Most of the dividing cells were in metaphase, or telophase

Conclusion This unexpected side effect of electroporation on human endothelial cells is particularly innovating but remains questioning. A direct action on microtubule polymerisation by electric current had already been described in other cell model. Partial rupture of cell junctions could also trigger mitosis, as previously described after endothelial treatment with EDTA, but we did not observed any microscopic endothelial disorganization. The peripheral location of dividing cells is in favour of the stimulation of hypothetical corneal endothelial 'stem like cells,' with a high inter-individual variability

EVER-2004-abstractbook.indd 109 8/19/04 12:26:37 PM

1265 / 156
Bioadhesives to seal corneal lacerations

ABAD M, MULET ME, SANCHEZ A, SCORSETTI D, ALIÓ JL
VISSUM Instituto Oftalmológico de Alicante , R&D, Alicante

Purpose To study the efficacy and the clinical and histological corneal biotolerance of different bioadhesives.

Methods We carried out an "in vitro" study on animal eyes of different bioadhesives with an acrylic or biological base. 150 µm lamellar keratectomy was performed with Moria I microkeratome and the corneal lamella was sealed with different bioadhesives. We evaluated effectiveness, speed and hardness of polimerization and corneal transparency.We made an "in vivo" study on Albino New Zealand rabbits (4 eyes per group) evaluating corneal biotolerance (inflammation reaction, neovascularization, opacification) and histological findings. We performed a 5mm intrastromal dissection with Melles spatula and microsclerotome and injected 0.10 mm of the different adhesives: n-butyl cyanoacrylate (Histoacryl®, Tisuacryl®), n-butyl cyanoacrylate ethyl cyanoacetate, n-butyl cyanoacrylate dihexyl maleate and fibrin adhesive (tissucol®)3 months follow up.

Results The bioadhesives from greatest to least in terms of degree of hardness, speed of polimerization and corneal opacity were: Histoacryl®- n-butyl cyanoacrylate dihexyl maleate - n-butyl cyanoacrylate ethyl cyanoacetate, Tisuacryl®- tissucol®.Efficacy: All were effective except fibrin adhesive.Inflammatory reaction: Severe: Histoacryl® and n-butyl cyanoacrylate dihexyl maleate and n-butyl cyanoacrylate ethyl cyanoacetate. Mild: Tisuacryl® and Minimal/no reaction: fibrin adhesives.Histological findings: Presence of edema, fibroblast activation, new vessel formation and remains of bioadhesives.

Conclusion Acrylic bioadhesives can be an effective alternative to sutures for corneal lamellar sealing. Corneal opacification may be produced by different compounds of the bioadhesive mixture. We need more experimental studies to determine the bioadhesive that can substitute traditional sutures in lamellar keratoplasty.

1266 / 157
Corneal epithelial cell homeostasis in organ culture

SOLTANINIA J (1), ARMITAGE WJ (2), BOULTON M (1), ALBON J (1)
(1) Cell and Molecular Biology Unit, School of Optometery and Vision Sciences, Cardiff
(2) Ophthalmology, University Of Bristol, Bristol

Purpose To identify changes in epithelial cell homeostasis in corneas stored in organ culture.

Methods Porcine corneas were organ cultured according to standard protocols. Corneoscleral discs were excised, and stored in organ culture at 34°C for up to 14 days. For proliferation studies, Brdu at a 1/500 dilution was added to the medium. Following storage, cornea was bisected, and one half fixed for wax sectioning. General morphology and epithelial stratification were assessed following H&E and Hoechst staining by light and fluorescence microscopy. The BrdU labelling index was quantified in central, peripheral and limbal regions of the cornea. The TUNEL assay was also performed to identify epithelial cell death.

Results A significant decrease in corneal epithelial thickness during storage from 45µm ± 3.6 at 0 day to a minimum of 7.7µm ± 0.6 at 14 days ($P<0.0001$). Stromal thickness increased from 691µm ± 53 at 0 day to a maximum of 1569µm ± 126 at 14 days organ culture storage ($P<0.0001$). The proliferative activity of the corneal epithelium was not equally distributed across the cornea and greatest in the peripheral epithelium at 12 days (27.7% ± 8.6%). The labelling index appeared to increase in the peripheral ($r = 0.79$), central ($r = 0.62$) and limbal ($r = 0.67$) region with organ culture storage time ($P<0.05$). The TUNEL technique identified epithelial cell death in the porcine cornea during organ culture storage.

Conclusion The porcine cornea appears to be a good model for organ culture storage. Furthermore, like human corneas there is a loss of epithelial cell layers. The proliferative index with increased culture time may be an unsuccessful attempt to reinstate the lost cells and thus return the cornea to normal homeostasis.

1267 / 158
Induced expression of insulin like growth factor 1 by amniotic membrane conditioned medium in cultured human corneal epithelial cell

LEE HK, MA KT, SEONG GJ, LEE JH, SEO KR, KIM EK, CHUNG SH
Ophthalmology, Yonsei University College of Medicine, Seoul

Purpose To determine whether insulin like growth factor-1 (IGF-1) and IGF-1 receptor (IGF-1R) is induced by amniotic membrane conditioned medium (AMCM) and also evaluate the effect of AMCM and IGF-1on human corneal epithelial cell (hCEC) proliferation and migration

Methods With immunohistochemical staining, we tried to confirm the existence of IGF-1 and IGF-1R on human cornea. For in vitro study, hCECs were cultured from corneolimbal tissue with supplemental hormonal epithelial medium (SHEM). After administration of AMCM (50ul/ml, 100ul/ml) and IGF-1, cell migration and proliferation were determined by proliferation and migration assay. We also tried to determine whether the expression of IGF-1 and IGF-1R on hCEC was changed by AMCM using western blot and immunofluorescein staining technique.

Results In this study, we found the existence of IGF-1R in human corneal epithelium. However, IGF-1 was not found in all layers of human cornea. Compared with the control group, increased expression of IGF-1 by AMCM dose dependant manner using Western blot and immunofluorescein cell staining technique. However, the expression of IGF-1R was not affected by the AMCM. With AMCM and IGF-1, hCEC showed increased in cell migration and proliferation. The induced proliferation and migration by AMCM was inhibited by IGF-1 neutralizing antibody.

Conclusion AMCM may induce IGF-1 during hCEC proliferation, and the increased IGF-1 may participate in facilitated cell migration and proliferation by amniotic membrane.

1268 / 159
Is the corneal endothelial change that seen after 2.45 GHz microwave exposure (near ICNIRP safety limits) microwave exposure specific?

KOJIMA M (1), HATA I (1), WAKE K (2), WATANABE S (2), TAKI M (3), KAMIMURA Y (4), YAMANAKA Y (2), TAKAHASHI N (1), SASAKI K (1)
(1) Department of Ophthalmology, Kanazawa Medical University, Daigaku, Uchinada, Kahoku-gun, Ishikawa
(2) National Institute of Information and Communications Technology, Nukui-Kitamachi, Koganei, Tokyo
(3) Department of Electrical Engineering, Graduate School of Engineering, Tokyo Metropolitan University, Minami-Osawa, Hachioji, Tokyo
(4) Department of Information Science, Faculty of Engineering, Utsunomiya University, Utsunomiya

Purpose We have examined whether the corneal changes reported by Kues et al. (1985) was microwave specific or not.

Methods A 2.45 GHz microwave (20-300 mW/cm2) was exposed unilaterally to male-pigmented rabbits (Dutch, 1.8-2.2 kg) with a systemic anesthesia. Other rabbits received following invasions, eye-lid closure, contact lens wear, carbon dioxide or nitrogen gas exposure, corneal cauterization, and albumin injection into the anterior camber. Changes in the anterior segment were observed by a Scheimpflug image analysis system, specular microscope and a laser flare cell meter.

Results In the microwave exposed group, corneal bleb like changes which was similar to corneal changes that Kues et al. reported, were temporally observed on 2 out of 135 rabbits, and these changes were disappeared within a week. The transient cornea changes which were similar to changes in microwave exposed rabbits were observed in carbon dioxide exposure and cornea cauterization treatment eyes.

Conclusion The appearance of cornea bleb due to the contact lens wearing it was reported that the individual specificity was remarkable, the cornea change shown in the present study and corneal changes reported by Kues in 1985 indicated not only microwave exposure but also possibility of inducing even in other factors.

EVER-2004-abstractbook.indd 110 8/19/04 12:26:38 PM

■ 1311

Remicade European Study for Chronic Uveitis (RESCU)

DE SMET M

Purpose Remicade (infliximab) is a monoclonal IgG1 chimeric monoclonal antibody, active against soluble and membrane bound TNF-α. The current study is aimed at: (1) determine response to Remicade in a prospective series of uveitis patients with intermediate and/or posterior uveitis intolerant or unresponsive to standard therapy; (2) determine if a long term remission can be induced in uveitis patients; (3) determine the incidence of side effects.

Methods Fourty eight uveitis patients were recruited from 10 European centers. The diagnoses were equally distributed groups: Behçet's disease, sarcoidosis, intermediate uveitis, Birdshot retinochoroiditis, idiopathic vasculitis, and sympathetic ophthalmia/ Vogt Koyanagi Harada. Patients were given Remicade IV at 5mg/kg at week 0, 2, 6, and every 8 weeks till week 46. From week 6 onwards, an attempt was made to taper all anti-inflammatory medications; however, low dose prednisone (7.5 mg/day), methotrexate (7.5 mg/week), or azathioprine was allowed. A response to Remicade was defined as maintaining or improving visual acuity while not meeting any of the exit criteria. An exit criterion was reached if vision dropped by 2+ ETDRS lines, a significant rise in vitreous haze, a retinal infarction or restarting immunosuppressive therapy. Following the last infusion, patients were followed prospectively for an additional 2 years or until there was evidence of a recurrence.

Results By July 2004, 48 patients were recruited. One patient was beyond week 46, having on no medications and no disease recurrence. For other patients follow-up is shorter. All showed initial improvements in vision. Four patients exited early: disease progression(1), rash(1), elevated liver enzymes(1), musculoskeletal pain(1). F/U at the time of the presentation will be 32 weeks.

Conclusion Preliminary results form the RESCU trial suggest that Remicade may be effective in a broad range of uveitis. It is tolerated well when adequate preliminary screening is performed, and with close follow-up.

■ 1312

Fluocinolone Acetonide Intravitreal Implant in the Treatment of Posterior Segment Uveitis: One Year Results

DE SMET M, FLUOCINOLINE ACETONIDE UVEITIS STUDY GROUP
Dept. of Ophthalmology, AMC, University of Amsterdam, Amsterdam

Purpose A multi-center, randomized, dose-masked clinical trial is being conducted to determine the safety and efficacy of a sustained release fluocinolone acetonide intravitreal implant in patients with posterior segment uveitis.

Methods Two hundred and seventy eight patients were randomized to receive either a 0.5mg or 2.0mg implant. Outcome measures included recurrence rate, visual acuity, adjunctive therapy use and adverse events.

Results At 52 weeks post implantation, the aggregate recurrence rate for the implant eyes was 4.3% versus 56.3% for the non-implanted fellow eyes. Aggregate 52 week mean visual acuity for the implant eyes did not change significantly from baseline (20/68 versus 20/70 at 52 weeks, p=0.58); conversely, mean visual acuity for the fellow eyes significantly decreased from 20/42 to 20/49 at 52 weeks (p<0.005). Adjunctive therapy use significantly decreased post implantation. Systemic corticosteroid and/or immunosuppressive therapy was used by 58.8% of patients at baseline versus 11.9% of patients at 52 weeks (p<0.0001). In the 12 months prior to implantation, 70.9% of implant eyes were given sub-Tenon injections versus 4.3% post implantation (p<0.0001). Similarly, topical steroid use was also reduced; 29.1% of implant eyes at baseline versus 4.7% at 52 weeks (p<0.0001). The most common serious adverse events for the implant eyes included cataract extraction (25.9%) and filtering procedures (11.9%).

Conclusion At 52 weeks, the fluocinolone acetonide implant controlled inflammation in a significant proportion of the eyes studied. IOP and lens clarity must be closely monitored in this patient population.

■ 1313

Anti-TNF. The British experience

DICK AD
Clinical Sciences, University of Bristol, Bristol

Purpose TNF blockade is effective in suppressing experimental autoimmune uveoretinitis (EAU). Focussing on a more selective blockade of TNFR1 (p55) we have shown that suppression of EAU occurs via a down-regulation of macrophage activation. To translate such findings into the clinic we evaluated the efficacy and safety a p55 TNF receptor fusion protein TNFr-Ig for severe sight-threatening non-infectious posterior segment intraocular inflammatory disease (PSII) in 17 patients.

Methods Pilot open-labelled phase 1/11 study. Flow cytometric analysis of systemic CD4 T cells activation phenotype and cytokine secretion

Results Within one month of TNFr-Ig therapy, 9 patients (52.9%) achieved at least a 2 line improvement in visual acuity, 8 of 14 patients (57.1%) with vitreous haze before treatment achieved an improvement in BIO score to zero, and macular edema resolved in 5 of 9 (55.6%) affected patients. Expression of IL-10 in CD4+ T cells was significantly increased after therapy with TNFr-Ig (p<0.01). The ratio between IL-10 and IFNγ expressing CD4+ T cells was significantly increased 2 weeks after therapy (p=0.015). A rapid increase of IL-10 expression after therapy was associated with an improvement of visual acuity of at least 0.2 logMAR within 4 weeks (p=0.029). There was no significant change of CXCR3, CCR4 or CCR5 expression. Neutralising TNFα activity in PSII increases the fraction of peripheral blood CD4+ T cells expressing IL-10 which correlates with a recovery of visual function.

Conclusion Clinically, TNFr-Ig was safe and effective at rescuing patients with sight-threatening non-infectious posterior segment intraocular inflammatory disease resistant to conventional immunotherapy but adjuvant immunosuppression and repeat infusions would be required to maintain long-term remission.

■ 1314

Selective steroid receptor agonists (SEGRA) a future therapeutic option?

PLEYER U
Charité – University Medicine Berlin, Humboldt University, Berlin

Purpose Fifty years after their initial clinical use glucocorticoids (GC) are still the most important and most frequent used anti-inflammatory agents in the treatment of acute and chronic inflammatory diseases. Unfortunately the anti-inflammatory and immunosuppressive effects of GC are frequently accompanied by undesired side effects. Beside unknown individual factors, recent investigations have idientified molecular mechanisms of GC action that may reveal new antiinflammatory agents with a better effect/ side effect profile.The effect of GC on target cells is mediated by the regulation of transcription of steroid-responsive genes. After binding to cytosolic glucocorticoid receptors (GR) the complex translocates into the nucleus and modulates gene transcription either by a positive (transactivation) or negative (transrepression) mode of regulation. There is growing evidence that beneficial effects as well as undesired effects are related to the dissociation of these two major mechanisms, e.g. steroid diabetes and steroid induced glaucoma seems to be mainly related to transactivation mechanisms.The dissociation of these mechanisms has recently led to the development of new agents that may predominantly induce transrepression over transactivation and subsequently lead to potent anti-inflammatory effects while displaying less dominant side effects. Indeed, transgenic mice carrying a defective GR could demonstrate the anti-inflammatory potential of transrepression. The purpose of this presentation is to provide an up-date on recent developments in this field.

EVER-2004-abstractbook.indd 111 8/19/04 12:26:38 PM

1315

Deep sclerectomy to manage refractory glaucoma in uveitis

HERBORT CP (1, 2), AUER C (1), MERMOUD A (3)
(1) La Source Eye Center, Lausanne
(2) University of Lausanne, Lausanne
(3) Department of Ophthalmology, University of Lausanne, Lausanne

Purpose If medical treatment fails in uveitic glaucoma, surgical approach should be considered. Classical trabeculectomy is known to have less favourable outcome in uveitis. Our purpose was to report the first series of uveitis patients with glaucoma resistant to medical therapy that were treated with deep sclerectomy (DS).

Methods Fourteen eyes of 13 patients (mean age 39.0 ± 18.5 ; range 8 to 76) with chronic uveitis underwent non-penetrating filtering surgery from 1995 to 2003.

Results IOP was reduced from a mean pre-operative value of 42.8 ± 13.6 mmHg to a 1-year mean post-operative value of 12.1 ± 4.0 (71.7% reduction). Eleven of the 14 patients completed 12 months of follow-up, resulting in complete success in 5 (45.4%) and in qualified success in 5 (45%) and in failure in one patient (9.2%), later controlled by a second operation. Anti-glaucomatous medication was reduced from a mean of 3.7 ± 0.5 medications preoperatively to 1.2 ± 0.8 medications (71.4% reduction) at 12 months' follow-up. Nine of the 14 patients achieved a 24 months follow-up with a mean IOP of 14.1 ± 3.8 mmHg and mean of anti-glaucomatous medications of 1.6. Four patients have been examined 4 years after the DS: mean IOP was 13.2 ± 2.2 mmHg and mean medication 1.7± 1.0. Post-operative complications included one case of lens opacity and 2 cases of hypotony lasting for five months and four weeks after the intervention respectively.

Conclusion Non-penetrating filtering surgery controlled intraocular pressure in 90% of eyes with uveitic glaucoma resistant to medical therapy. Surgical complications were low which may explain the high success rate of the procedure, compared to classical penetrating surgery.

EVER-2004-abstractbook.indd 112 8/19/04 12:26:39 PM

■ 1331

The influence of Src-family tyrosine kinases on lens Na,K-ATPase

DELAMERE NA (1, 2), DEAN WL (3), TAMIYA S (1), BOZULIC LD (3)
(1) Ophthalmology and Visual Science, University of Louisville, Louisville, KY
(2) Pharmacology and Toxicology, University of Louisville, Louisville, KY
(3) Biochemistry and Molecular Biology, University of Louisville, Louisville, KY

Purpose Na,K-ATPase function is essential for the regulation of cytoplasmic electrolyte concentrations in the lens. Previously this laboratory demonstrated that tyrosine phosphorylation by Lyn kinase, a Src-family member, caused a ~40% inhibition of Na,K-ATPase activity in porcine lens epithelium (Bozulic et al. Am. J. Physiol. 2004). Here, we conducted experiments to compare the ability of other Src-family kinases (Fyn, Src, Lck) and Fes, a non-Src-family tyrosine kinase, to alter Na,K-ATPase activity.

Methods Membranes prepared from porcine lens epithelium were incubated 20 min with partially purified tyrosine kinases in buffer containing 1 mM ATP. Phosphotyrosine-containing proteins were analyzed by Western blot. Ouabain-sensitive ATP hydrolysis was measured to determine Na,K-ATPase activity.

Results Each Src-family tyrosine kinase induced a different pattern of membrane protein tyrosine phosphorylation. Fes, which is not a member of the Src family, also caused tyrosine phosphorylation. Fyn reduced Na,K-ATPase activity by ~30%. In contrast, incubation with Src caused a ~38% increase of Na,K-ATPase activity. Na,K-ATPase activity in membrane material treated with Lck or Fes was not significantly altered, even though robust tyrosine phosphorylation was evident.

Conclusion The results indicate considerable variation in the Na,K-ATPase activity response to different tyrosine kinases. The different Na,K-ATPase activity responses elicited by different tyrosine kinases point to a sophisticated and complex mechanism for control of Na,K-ATPase activity in the lens.

■ 1332

Inhibition of glycogen synthase kinase (GSK-3) in the lens

KARLSSON JO, PETERSEN Anne
Institute of Anatomy and Cell Biology, Gothenburg University, Gothenburg

Purpose GSK-3, an evolutionary conserved S/T kinase which regulates cell fate determination in diverse organisms have been implicated in the formation of amyloid b-peptides and the phosphorylation of tau and catenin. Inhibition of GSK-3 can be obtained via the structurally unrelated substances lithum or Kenpaullone. The lens and the lens epithelial cells are excellent models to study the role of this enzyme.

Methods Confluent human lens epithelial cells (HLEC) were exposed to the GSK-3 inhibitors lithium (2 mM) or Kenpaullone (2 µM) for times upp to 24h. DCFH-DA was used to assay peroxides, mitochondrial function was evaluated with Rhodamine 123, monochlorobimane was used to assay intracellular glutathione (GSH) levels, Proteolytic activities were assayed, on line, with cell-permeable fluorogenic substrates.Proteasome and calpain activities were assayed with LLVY-AMC, Cathepsin B with RR-AMC or FR-AMC. Metalloproteases were assayed with AAF-AMC. Caspase-3, 8 and 9 were assayed in cell extracts with DEVD-, IETD- or LEHD-AMC, respectively.

Results The mitochondrial membrane potential and the level of GSH increased after treatment with Li or Kenpaullone for 24h. No change was observed for peroxide production. The basal (low) level of caspase-3 activity was decreased by 20%. No significant effects were found concerning caspase-8 or 9 activities.No effect was observed on the activity of calpain, the proteasome, metalloproteases and cathepsin D/E activity.

Conclusion Inhibition of GSK-3 may protect against oxidative damage and attenuate apoptosis in HLEC. No changes of the other major proteolytic systems in the cell were detected. These data may be important for the interpretation of Wnt signaling and cell growth in HLEC as well as for the formation of amyloid in the lens.

■ 1333

Proteasome-dependent degradation of Cx43 in lens epithelial cells requires the carboxyl-terminal of the protein

CATARINO S, GIRAO H, PEREIRA P
IBILI - Centre of Opthalmology, Coimbra

Purpose Intercellular communication is vital to maintain lens transparency. Both the proteasome and lysosome have been implicated in the degradation of. The objective of this study is to investigate the role of the ubiquitin proteasome pathway in the degradation of Cx43 in lens epithelial cells and to establish the role of the carboxyl-terminus in the regulation of Cx43 stability at the plasma membrane.

Methods Primary cultures of lens epithelial cells were incubated with proteasome or lysosome inhibitors. The contribution of the proteasome to the degradation of Cx43 was further investigated by metabolic labeling with[35S]-methionine, conjugation assays, cell surface biotinylation and use of chimeric forms of Cx43 truncated in the carboxyl-terminus. Subcellular distribution of Cx43 was evaluated by immunofluorescence confocal microscopy.

Results Inhibitors of the proteasome and lysosome both stabilize Cx43 and increase the half-life of the protein significantly. Conjugation assays show that Cx43 is not a target for ubiquitinylation. Cell surface biotinylation and immunofluorescence data show that, while inhibition of the lysosome results in an accumulation of Cx43 in the cytoplasm, inhibition of the proteasome stabilizes Cx43 at the plasma membrane. Proteasome inhibitors do not stabilize truncated forms of Cx43 at the plasma membrane nor increase.

Conclusion This study supports a model in which degradation of Cx43 is regulated by the proteasome at the internalization step in the endocytosis of the protein. Regulation of endocytosis of Cx43 is likely to depend on a domain localized at the carboxyl-terminal of the protein.

■ 1334

Distribution of the type of cataract and cell density in type II diabetics and nondiabetics - a scheimpflugdensitometric and histomorphological study

STRUCK HG (1), TKACHOV SI (1), LAUTENSCHLÄGER C (2), EHRICH D (1)
(1) M. Luther University Dept. of Ophthalmology, Halle
(2) M. Luther University Instit. of Medical Epidemiology, Biostatistics and Informatics, Halle

Purpose This prospective clinical study deals with the morphometric changes of the lens epithelium of different types of cataract in type II diabetics and nondiabetics.

Methods 150 central lens capsules (type II diabetics, n = 77, 45 female, 32 male, mean age 72.8years; nondiabetics, n = 73, 41 female, 32 male, mean age 68.6years) were gained after phacoemulsification and examined by light microscope. The main parameter was the mean cell density. Further criteria were duration of diabetes, onset of diabetic retinopathy, classification of the type of cataract (PENTACAM), the blood parameters fasting blood sugar and glycolized hemoglobin and glucose content in anterior chamber.

Results The mean cell density in the cataractous lens in type II diabetics is 3951 +/- 528 cells/mm², in nondiabetics 4329 +/- 580 cells/mm² ($p < 0.001$). The decrease in cell density is accompanied with the increase in glucose content in anterior chamber ($p = 0.014$), the increase in fasting blood sugar ($p = 0.003$), and the increase in glycolized hemoglobin ($p = 0.039$). Regarding the types of cataract as water-clefts and spokes (3358 +/- 285 cells/mm²) and posterior subcapsular opacity (3826 +/- 225 cells/mm²) have the lowest cell density.

Conclusion The significant differences of the cell density of the lens epithelium in different types of cataract of the diabetic compared to nondiabetic lens seem to be due to the cataractogenic influence of type II diabetic metabolic disorder on the lens epithelium structure in the development of the age-related cataract.

EVER-2004-abstractbook.indd 113 8/19/04 12:26:39 PM

■ 1335

Determination and quantification of kynurenic acid, a tryptophan derivative in cataractous lenses

ZARNOWSKI T (1), ZIELINSKA-RZECKA E (1), REJDAK R (1), KOCKI T (2), ZAGORSKI ZF (1), TURSKI WA (2)
(1) Tadeusz Krwawicz Chair of Ophthalmology and 1st Eye Hospital, Lublin, Poland, Lublin
(2) Department of Pharmacology, Medical Academy, Lublin, Poland, Lublin

Purpose Kynurenines and their glycoside derivatives absorb ultraviolet radiation, thus, their presence in the lens may be useful in protecting the retina from ultraviolet light. The experiments were designed to analyse kynurenic acid (KYNA) concentration in human cataractous lenses and in experimental cataract in diabetic STZ-treated rats.

Methods KYNA levels were investigated with HPLC and detected fluorimetrically. Ninety one nuclei of human cataractous lenses collected following planned extracapsular extraction were classified accordingly to LOCS III (Chylack et al., 1993) and compared to clear lenses. Cataractous lenses from STZ-treated rats were compared to controls.

Results In clear lenses (NC0), KYNA concentration was 0.95 ± 0.22, in NC1 was 0.8 ± 0.72, in NC2 was 1.18 ± 0.88, in NC3 was 1,31 ± 0.70, in NC4 was 1.78 ± 0.92, in NC5 was 8.80 ± 8.28 ($P<0.05$ vs NC0) and in NC6 was 14.0 ± 11.1 ($P<0.05$ vs NC0). Correlation between the grade of cataract (LOCS III scale) and KYNA concentration was noted ($r=0.047$, $P<0.001$). Elevated KYNA concentration in rat cataractous lenses was also observed ($P<0.05$).

Conclusion KYNA levels are elevated in cataractous lenses of humans and rats.

■ 1336

Biochemical changes in selenite cataract model: Measurements by HR-MAS 1H NMR spectroscopy

FRIS M, TESSEM MB, SÆTHER Ø, MIDELFART A
Dep. of Ophthalmology, Faculty of Medicine, Norwegian University of Science and Technology, Trondheim

Purpose In the present study, high resolution magic angle spinning proton Nuclear magnetic resonance (HR-MAS 1H NMR) spectroscopy was used to investigate changes in the metabolic profile of intact rat lenses after sodium selenite administration.

Methods Selenite cataract was induced by injecting 13-day-old Sprague-Dawley rat pups with a single subcutaneous dose of sodium selenite at 3.28 mg/kg (19 µmol/kg) in 0.9% sodium chloride solution (pH 9). Lens opacification was observed using a photo slit lamp microscope at selected time points from 3 to 9 days after selenite injection and graded (level 0,1 and 2). Thereafter lenses were removed and HR-MAS 1H NMR spectra from intact lenses were obtained. Relative changes in metabolite concentrations were determined.

Results Photo slit lamp microscopy revealed different stages of cataract in all animals treated with selenite. In the high quality HR-MAS 1H NMR spectra of the lenses more than 30 different metabolites were identified. With the exception of taurine, the concentrations of all amino acids showed a significant increase ($P<0.05$) in the second level of cataract. On the other hand, glutathione, succinate and phosphocholine concentrations were significantly reduced.

Conclusion This study demonstrates the potential of HR-MAS 1H NMR spectroscopy as an analytical tool to investigate metabolic processes in intact lenses. Significant alteration of the metabolic profile of rat lenses was observed after the development of selenite-overdose cataract. The results expand the knowledge about the role of different metabolites in the protection of the lens and the complexity of cataractogenesis.

■ 1337

Anticataractogenic Properties of Methylglyoxal-modified Small Heat Shock Proteins

NAGARAJ RH (1), OYA-ITO T (1), LIU BF (1), BHAT M (2), PILCH HA (1)
(1) Ophthalmology, CWRU, Cleveland
(2) Cleveland Clinic, Cleveland

Purpose Alpha-crystallin and heat shock protein 27 (Hsp27) are stress-inducible small heat shock proteins (sHSPs) in the lens. In a recent study, we demonstrated that these sHSPs become better chaperones after modification by methylglyoxal (MGO). This prompted us to investigate whether they become better anti-apoptotic proteins after modification by MGO.

Methods Human lens epithelial cells (HLE B-3) were cultured in MEM. Native and MGO-modified α-crystallin or Hsp27 were treated with BioPORTER and incubated with cells for 3 hrs in the absence of serum. Apoptosis was induced by incubating cells with 1 µM staurosporine (SP) and was measured by flow cytometry. Effect on caspase-3 activity, caspase-8 mediated activation of capase-3, formation of reactive oxygen species (ROS) and cellular glutathione (GSH) content were investigated.

Results ITransfer of α-crystallin and Hsp27 offered ~17 and 20% protection against SP-induced apoptosis. Under similar conditions MGO modified α-crystallin and Hsp27 provided 36 and 23% protection. Cells treated with SP showed increased caspae-3 activity; native proteins blocked to some extent this activity, and the effect was more pronounced with MGO-modified proteins. SP-treatment resulted an increase in ROS content and a decrease in GSH content. These were mildly corrected by native proteins, but strongly by MGO-modified Hsp27. Caspase-8 mediated activation of caspase-3 was inhibited more effectively by MGO-modified α-crystallin than native α-crystallin.

Conclusion These results suggest that MGO-modification of sHSPs may provide lens with better tolerance to cope with apoptotic stresses by enhancing their ability to inhibit caspase-3 activation, reduce ROS accumulation and prevent GSH loss.

EVER-2004-abstractbook.indd 114 8/19/04 12:26:40 PM

■ 1341

Gordon Ruskell's Contributions to Ophthalmic Anatomy

BRON AJ
Nuffield Laboratory of Ophthalmology, University of Oxford, Oxford

Purpose Gordon Ruskell devoted his professional career to the study of human and non-human primate ophthalmic anatomy. He was a dedicated teacher who made many significant personal contributions. He inspired countless students to work under his direction. His research included studies of the innervation of the eye and orbit, with special attention to fibre type, and he described the retro-orbital plexus of nerves deriving from the pterygopalatine ganglion. He described the muscle spindles and palisade endings of the rectus muscles, a dual sensory innervation of the cornea, and the presence of sensory endings at the limbus. He made important observations on the secretory granules of the lacrimal gland. Most of his work concerned normal human anatomy and was carried out with scrupulous care. Some research, such as his keratoconus and migraine-related studies, dealt with human disease. All of his work considered the functional implications and their relevance to disease.Gordon Ruskell was a founder member of the European Club for Ophthalmic Fine Structure, serving as its Secretary and later as its President. He played an important role in the development of eye research in Europe through his involvement with the Association for Eye Research (AER) and as a Board member of JERMOV and EVER. He was until recently chairman of the section of Anatomy of EVER and later served as a Vice President. At all times he displayed a disarming and characteristic mixture of wisdom and courtesy which ensured that his opinions were given due weight. Some of his contributions to our understanding of ophthalmic anatomy will be touched on in this symposium, held in his honour.

■ 1342

Innervation of the Anterior Eye Segment: a Tribute to Gordon Ruskell

VRENSEN GFJM
Department of Opthalmology, Leiden University Medical Center, Leiden

Purpose The role of cornea, lens and ocular adnexa in the visual process seems rather simple as compared to the complex computing activity of the retina. However it has to be realized that the coordination of ocular muscles for binocular vision, the importance of the orbital glands in tear film formation, the role of the ciliary muscle and ciliary body in lens accommodation, nourishment of the avascular cornea and lens and in maintaining a proper intraocular pressure, all presuppose a precise regulation and coordination by numerous and different peripheral nerves.

Methods Gordon Ruskell dedicated most of his scientific career in unravelling the anatomical complexity of this peripheral innervation of the orbit, the ocular muscles and the anterior eye segment. He had excellent skills in anatomy, histology and electron microscopy and some of his contributions to this field are classic and timeless.

Results In my contribution to this symposium I will exemplify his great dedication to the field of neurophhalmology with a short overview of corneal and anterior segment innervation in which we had the pleasure to collaborate and to discuss with him on many occasions.

Conclusion Gordon Ruskell was one of those exceptional individuals who dedicated his life to one particular field of research in his case the peripheral innervation of the eye ball. He will be remembered as one of the most outstanding European specialists in this field with a phenomenal knowledge and extreme skills in morphological methods. Besides he was an excellent teacher and his critical technical and theoretical remarks were always taken serious by students, postdocs and colleagues alike. We will miss his brilliant scientific advices, his wisdom in organizational affairs and certainly also his great friendship.

■ 1343

Sensory receptors in extraocular muscles

BRUENECH JR, KJELLEVOLD HAUGEN IB
Dept of Optometry and Visual Science, Buskerud University College, Kongsberg

Purpose Sensory receptors found in skeletal muscles are either absent or present in modified forms in the extrinsic eye muscles of many species. Large variations in the presence, distribution, frequency and complement of proprioceptors also occur. The role of proprioception in oculomotor control has consequently been a matter of debate for many years.

Methods Morphological studies undertaken by Gordon Ruskell, has provided detailed information regarding sensory receptors in extraocular muscles of a variety of mammals. These findings are considered to be vital contributions to the literature, creating a sounder basis for considering proprioception.

Results In this presentation we would like to pay tribute to Gordon Ruskell's memory by reviewing some of his comprehensive work on mammalian extraocular muscle proprioception. His excellent anatomical knowledge and scientific skills, as well as his artistic gift, have irrefutably influenced the current understanding of the development and maintenance of binocularity.

Conclusion Through his extensive neuroanatomical studies of extraocular muscles, Gordon Ruskell became a highly regarded and undisputed authority within the field of oculomotor control. He will be remembered as an outstanding scientist, academic, artist, colleague and friend. He is deeply missed.

■ 1344

The structure, distribution and putative function of corpuscular nerve endings in the human conjunctiva

LAWRENSON JG
Department of Optometry and Visual Science, City University, London

Purpose Sensory nerves within the conjunctiva display two principal terminal forms: free nerve endings and the more complex corpuscular endings. Corpuscular nerve endings are widely distributed throughout the conjunctiva, but show a particular preponderance for the limbal and the marginal zones. Typically, corpuscular nerve endings lie close to the epithelium. They are round or oval encapsulated structures, approximately 40 microns in diameter, served by a single myelinated axon. The axon loses its myelin sheath upon entering the corpuscle and then branches extensively. The terminal axon displays multiple varicosities containing numerous mitochondria and enveloped by cytoplasmic extensions of Schwann-like lamellar cells. The capsule is variable in thickness, comprising 1-3 layers of perineurial cells. Indirect evidence, based on aesthesiometry in human subjects, suggests that corpuscular nerve endings are low-threshold mechanoreceptors.

EVER-2004-abstractbook.indd 115 8/19/04 12:26:40 PM

1345

The puzzle of the rami orbitales and the relation to the retro-ocular plexus

VAN DER WERF F
Erasmus MC, Rotterdam

Purpose The first description of autonomic innervation of orbit structures was presented over a century ago and was generally acccepted for a long period. The lacrimal gland secretomotor pathway has been described in 1893 by Jendrassik and is still present in several (neuro-)anatomical and ophthalmological textbooks. The pathways runs from the pterygopalatine ganglion, via the zygomatic and lacrimal nerves towards the lacrimal gland. From the onset of Gordon Ruskell scientific career, he was fascinated by the autonomic innervation of cranial structures and the networks involved in orbital nerve pathways

Methods It was Warwick who introduced him in the examination of autonomic innervation of orbital structures in the monkey and learned him the classical denervation technique. Gordon Ruskell combined this technique with EM in order to follow the (denervated) nerves in the orbit

Results Although this technique has its limitations, he disentangled many neuronal pathways. For instance, he described the lacrimal pathway of postganglionic nerve fibres towards the lacrimal gland, entering the orbit through the smooth orbital muscle, via the rami orbitales continuing in the rami lacrimales giving off nerve fibres to the retro-ocular plexus. Retrobulbar and retro-ocular nerve plexus were examined by cross section, EM and denervation technique and his data fitted quite well in the observations made by other authors using different technique

Conclusion Gordon Ruskell published more than 60 papers all related to the orbit, this year, in a Experimental Eye Research, paper he gently warned clinicians that they have to reconsider their anatomical knowledge in lacrimal gland innervation before they try to reduce excessive lacrimation of the patient.

EVER-2004-abstractbook.indd 116 8/19/04 12:26:41 PM

1351

Transscleral diode laser delivery (Diopexyâ) for treatment of Subretinal choroidal neovascular membranes

RUIZ-LAPUENTE C J, PLAZAS A, VÁZQUEZ C, MUÑOZ A
HH UU Virgen Del Rocio, Sevilla

Purpose To evaluate the transscleral diode laser treatment in patients undergoing Subretinal choroidal neovascular membranes with high neurosensorial detachment and subretinal blood.

Methods Ten patients affected of Subretinal choroidal neovascular membranes in the right eye received subconjunctival anesthesia (lidocaine 5%). An small conjunctival dissection was performed in the superior-temporal quadrant and the Diopexyâ probe was carefully placed transsclerally under the lesion. Accurate treatment location was assured with the transillumination of the retina by the aiming beam. After indocyanine green infusion (25 mg in 5 ml), the laser treatment was applied (power: 800 mw, duration:3000 ms. Spot:27-30).Short term control didn't show visual acuity decrease.No important complications were observed during the procedure (mild pain in one patient and subconjuntival hemorrhage in two patients).

Results Short term control didn't show visual acuity decrease. All patients defined the tecnique as practically unpainful. No Tyndall in vitreous was observed.No important complications were observed during the procedure (mild pain in one patient and subconjuntival hemorrhage in two patients).

Conclusion Transscleral diode laser delivery (Diopexyâ) appears to be a safe and controlled treatment of subretinal choroidal neovascular membranes with high neurosensorial detachment and subretinal blood. The posterior extension of subconjunctival blood might theoretically decrease the efficacy of Diopexyâ.Finally we propose some changes in size and design of the probe, in order to enhance the success of the therapy.

1352

Axial Myopia Significantly Reduces Laser Dose in Verteporfin Therapy

NASCIMENTO JCN (1, 2), DIAS JMD (3, 4), CASTANHEIRA DINIS ACD (1, 2)
(1) Instituto Oftalmologia Dr. Gama Pinto, Lisboa
(2) Departamento de Retina e Vítreo, Lisboa
(3) Instituto Superior Técnico, Lisboa
(4) Centro de Fisica dos Plasmas / GoLP, Lisboa

Purpose To evaluate the variations of the laser spot dimension and laser dose used for photodynamic therapy (PDT) induced by different eye's axial lengths.

Methods We have performed ray-tracing simulations using optical models of the eye and of a contact laser lens with the laser output parameters used in PDT.

Results The spot size increases linearly with the axial length, which consequently implies a strong decrease of laser dose, such as 34% for -14D myopia and 44% for -20D.

Conclusion Axial length measurement is important to ensure clinical results reproducibility and PDT optimization in high myopic eyes.

1353

Pseudophakic Implantation in High Myopic Eyes Induces Laser Dose Reduction in Verteporfin Photodynamic Therapy

DIAS JMD (1, 2), NASCIMENTO JCN (3, 4), CASTANHEIRA DINIS ACD (3, 4)
(1) Instituto Superior Técnico, Lisboa
(2) Centro de Fisica dos Plasmas / GoLP, Lisboa
(3) Instituto Oftalmologia Gama Pinto, Lisboa
(4) Departamento de Retina e Vítreo, Lisboa

Purpose To evaluate the intra-ocular implantation effect in laser dose of photodynamic therapy in high myopia.

Methods By ray-tracing simulations using optical models of the eye and of a contact laser lens we have studied the induced intra-ocular implantation effect, calculated by the SRK II formula, in the laser dose.

Results The spot size increases with the pseudophakic implantation which consequently implies a decrease of the laser dose, such as 51% for axial length corresponding to -20D myopia.

Conclusion Pseudophakic implantation aggravates the laser dose reduction induced by the axial length in high myopic eyes.

1354

Krypton laser treatment of chorioretinal anastomoses associated with vascularised retinal pigment epithelial detachment in AMD at the earliest stage: Ten consecutives cases

COSCAS G (1), DARMON J (2), COSCAS F. (3), ZOURDANI A (1), SOUBRANE G (1)
(1) CHI Creteil, Creteil
(2) cabinet d'ophtalmologie, Nice
(3) centre ophtalmologique de l'Odeon, Paris

Purpose To evaluate the results of laser photocoagulation of retinochoroidal anastomoses (RCA) associated with retinal pigment epithelial detachment (RPED) in patients with exudative age-related macular degeneration (AMD) at the earliest stage. : Prospective, non-randomized pilot trial. Participants: Ten eyes of eight consecutive patients with RPED and exudative AMD and non-classic CNV with RCA, during very closed follow-up second eye of eight patients out of ten.

Methods In all cases, the patients presented initially recent vision loss or metamorphopsia. RCA and RPED were identified on clinical examination and confirmed with fluorescein and indocyanine green (ICG) angiography, and OCT examination. Focal Red Krypton laser photocoagulation of the identified RCA was performed.

Results In all cases, the PED was re-applicated and the RCA was occluded after one or few laser treatments. Visual acuity improved in six out of ten patients (60%) . Four patients developed a recurrence. Repeated laser photocoagulation led to improvement in one patient and no improvement in the three others.

Conclusion Laser photocoagulation of RCA is a safe, promising approach for the treatment of a subset of patients with exudative AMD. A randomised controlled prospective trial could be useful to further determine RCA laser photocoagulation efficiency.

EVER-2004-abstractbook.indd 117 8/19/04 12:26:41 PM

1355

Missed re-treatments in photodynamic therapy

SERES A
1st Department of Ophthalmology, Budapest

Purpose to analyze the effect of missed photodynamic therapy (PDT) re-treatment sessions on short term results in patients with age- related macular degeneration.

Methods Visual acuity outcomes of patients underwent PDT for AMD were reviewed. A treatment was considered „missed" in case the patient did not returned for control visit or if there was technical obstacle to the treatment like unavailability of the drug due to reimbursement problems.

Results Changes in visual acuity at 6 months were assessed in 207 patients. 33 of these had missed treatment at 3 months. At 6 months, 72,4% vs. 48,6% of our patients lost less than 3 lines in the normal 3 months re-treatment and the missed re-treatment groups, respectively (p<0,01, Pearson Chi-Square test).

Conclusion Proper re-treatment schedule is indispensable. Since most of the visual loss occurs in the first year, efforts must be made to treat our patients according to the protocol in the first 12 months.

1356 / 126

Photodynamic Therapy for Subfoveal Choroidal Neovascularization Secondary to Vogt-Koyanagi-Harada Syndrome

NOWILATY SR, BOUHAIMED M, ABBOUD EB, KAHTANI E, DHIBI H, AL-HARTHI E, JOHNSTON M, AL ROBAIE M, BANTAN I
Vitreoretinal Division, King Khaled Eye Specialist Hospital, Riyadh

Purpose To assess the effects of photodynamic therapy (PDT) with Verteporfin in the treatment of subfoveal choroidal neovascularization (CNV) secondary to Vogt-Koyanagi-Harada syndrome (VKH).

Methods Six eyes of 6 patients with VKH who developed subfoveal CNV underwent standard PDT. Repeated treatments were performed at 3-month intervals for persistent leakage. The charts and angiographic data were analysed retrospectively.

Results All patients were young (17 -27 years). Five CNV lesions were recent and classic (greatest lesion diameter 1100-3100 microns). One CNV was chronic and partially scarred. Mean visual acuity at presentation was 20/200. Five patients had more than one year follow-up.Five eyes had active inflammation. Of these, three required one PDT. The final CNV scar was smaller/stable with improvement of VA by one line in two eyes. The third developed a larger CNV scar with loss of 2 lines of VA. Submacular fibrosis developed in all three. In eye #4, mild CNV leakage persisted after one PDT, but hazy media precluded a second PDT. At 15 months the CNV scar and VA were stable. The fifth case, with mild inflammation, required three PDTs. The CNV leakage continued but was minimal. The lesion became smaller and VA improved. One eye without inflammation needed two PDT sessions to halt the CNV leakage. The final lesion was smaller and vision was stable. There were no PDT-related complications.

Conclusion Photodynamic therapy with Verteporfin appears to be a safe and viable treatment option for subfoveal CNV secondary to VKH, offering a chance for stabilization or even improvement of vision. Further study is warranted.

1357 / 104

Diode laser (diopexyâ) transmission trough sclera

PLAZAS A, RUIZ-LAPUENTE C
HH UU VIRGEN DEL ROCIO, Sevilla

Purpose The transscleral application of the diode laser can be useful in the treatment of retinopathy of prematurity, intraocular tumors, retinal breaks, retinal detachment and glaucoma. The presence of subretinal blood or high neurosensorial detachment does not allow for Photodynamic Therapy or Transpupillary Termotherapy as demonstrated by several authors.Purpose: to quantify the ex vivo Diode laser (Diopexyâ) transmission trough sclera

Methods Transscleral laser diode transmission was measured by placing human sclera in contact with laser light from Diopexyâ probe. A power sensor behind took the measurements. The mean of five readings was then calculated.

Results

POWER					
100	6.3	2.2	2.0	3.4	4.2
250	3.8	4.3	4.2	9.1	5.7
500	8.5	6.3	8.4	8.1	8.3
1000	24	16.7	25	31.6	27

Conclusion As seen in the table, most part of the energy of the LASER is blocked by the sclera, but in vivo enhanced absorption by choroid could be reached by infusion of ev indocyanine green.

EVER-2004-abstractbook.indd 118 8/19/04 12:26:42 PM

1361
The international keratoprostheses scene

LIU C
Sussex Eye Hospital, Brighton

Purpose The formation of the International Keratoprosthesis Study Group (KPro Study Group) in 1990 has been instrumental in fostering clinical and basic research in keratoprosthesis, synthetic cornea and artificial bio-corneal implants. The group meets regularly (Miami 1992, Rome 1995, Birmingham, England 1999, followed by annual meetings jointly with the International Ocular Surface Society, and various regional meetings). Its website (www.kpro.org) also makes members aware of courses and special interest symposia on keratoprostheses. Those interested in keratoprostheses should become a member of the group.Broadly speaking, the term keratoprosthesis is used when a device has to be deployed due to anticipated or actual failure of conventional cadaveric corneal transplantation, with or without corneal stem cells and amniotic transplantation. Problems arise with keratoplasty when corneal vascularization is severe making immunological rejection likely. Multiple corneal graft failure is another indication. The most severe indication is the dry eye, a situation too hostile for a grafted cornea (± stem cells) to survive and remain clear.The term artificial cornea is used when the aim is to replace conventional keratoplasty. If a perfect bio-engineered or synthetic "cornea" could be made, then the problems of shortage of supply, risk of transmission of infection from donor to recipient, optical aberrations and astigmatism, and immunological rejection would disappear.The author summarizes the predominant device(s) used in each geographical area of the world, as well as research efforts to enhance survival of devices, and the development of new biomaterials and new devices.

1362
Strampelli Osteo-Odonto-Keratoprosthesis. Experience from 1964 to 2004

BARRAQUER J
Instituto Barraquer, Barcelona

Purpose A historical review of the author's experience with Strampelli's osteo-odonto-keratoprosthesis.

Methods Professor Benedetti Strampelli invented in 1963 an interesting, ingenious, biological alternative to the classical keratoprostheses whose use since 1955 had not been very encouraging on longterm observations. Strampelli's original technique consisted in fixing an acrylic prosthesis, using dentists' adhesive, into an osteo-dental support, obtained from the same patient. The dentine remains physiologically adherent to the bone and maxillary periosteum which heal into the ocular tissues and to the buccal mucosa which covers the prosthesis.

Results The technique has undergone modifications over the years and many investigators joined forces to improve the procedure to obtain more encouraging results. Acceptable results can now be obtained in certain selected cases but even after an initial satisfactory result late complications appear frequently, unfortunately often with very little warning, which means that these patients must be followed very carefully all their life and must have immediate access to a specialized Eye Center at all times.

Conclusion The principle emphasized by Strampelli to use a living support for an artificial biological, physiological implant continues fully valid at present. The osteo-odonto-keratoprostheses are true heterotopic autografts which cicatrice with the surrounding tissues as opposed to the keratoprostheses with artificial supports which will only be surrounded but not truly incorporated in the neighbouring tissues around them. This is certainly of primary importance in the evolution of replacing the diseased cornea by artificial devices.

1363
Update of OOKP results in Brighton

PAUL B, TANDON R, HEROLD J, THORP S, LIU C
Sussex Eye Hospital, Brighton

Purpose OOKP surgery is the technique of choice for restoring sight in bilateral corneal blindness secondary to end-stage ocular surface disease. Conventional penetrating keratoplasty is doomed to failure in the dry keratinised eye.

Methods We performed OOKP surgery on 33 patients over an 8 year period. The diagnoses were mostly Stevens Johnson syndrome, ocular cicatricial pemphigoid and severe chemical injury. Patients had bilateral disease and vision was count fingers or worse in the better eye, except one with 6/36 vision in the fellow eye. A lamina was fashioned from the patient's tooth and alveolar bone to support a PMMA optical cylinder. This is implanted submuscularly for 2 - 4 months whilst soft tissue invests in the lamina, and buccal mucous membrane is grafted onto the eye to act as a biological covering. The lamina is implanted on the cornea and under the buccal mucous membrane.

Results 7 patients achieved 6/6 or better, 14 patients achieving 6/9 or better, 18 patients 6/36 or better and a further 7 patients improved their vision from pre op scores. We discuss successes, complications, and their management. 2 patients have had significant resorption of the tooth lamina for which we initiated early repeat OOKP surgery.

Conclusion In patients who have severe bilateral corneal scarring disease OOKP surgery is an effective method to restore sight.

1364
Oculoplastic complications of OOKP surgery

MAVRIKAKIS I, BRITTAIN P, HEROLD J, COLLIN JRO, LIU C
Sussex Eye Hospital, Brighton

Purpose To evaluate the oculoplastic complications associated with OOKP surgery and the surgical procedures used to correct them.

Methods Patients were grouped in 3 categories of complications: a) forniceal and tarsal plate cicatrization. As a result, patients may have shallow fornices, upper or lower lid entropion and wide palpebral apertures. b) Buccal mucous membrane thinning, ulceration, and/or necrosis. c) Miscellaneous.

Results In the first group deepening of fornices was achieved by buccal mucous membrane grafting with insertion of a temporary silicone band, which is maintained in the apex of the fornix with loose 4/0 prolene sutures through the skin. Wide palpebral aperture and entropion were corrected by horizontal lid split, dividing the anterior and posterior lamella of the upper or lower lid. Medial/lateral canthoplasty, lateral canthal sling, and upper lid lowering using an anterior approach to disinsert the levator aponeurosis are additional procedures that were used to reduce the palpebral aperture.In the second group, one should exclude and treat any underlying infection. Therefore taking swabs from the graft should be performed on a routine basis. Following successful treatment of an underlying infection a mucoplasty should be performed. This involves movement of the thick buccal mucosal graft from the periphery to the centre by using rotational flaps followed by regrafting of the peripheral donor site with fresh tissue. Failing that a new free graft or a pedunculated graft can be used. Finally the anterior lamella of the upper lid can be undermined and pulled down over the optical cylinder on to de-epithelialised buccal mucous membrane graft and an opening can then be made for the optical cylinder.In the third group, one of our patients required reduction of a bulky nasal septal cartilage graft from the upper lid through a skin crease incision. The nasal septal cartilage graft was implanted previously because of scarring associated with the primary disease.

Conclusion Challenging oculoplastic complications may occur following OOKP surgery, which may require the input of an oculoplastic surgeon. The surgical results have been satisfactory, although more than one attempt may be necessary.

EVER-2004-abstractbook.indd 119 8/19/04 12:26:42 PM

■ 1365

Surgery of the vitreous and retina in cases operated for osteo-odonto keratoprosthesis

BARRAQUER J, NADAL J
Instituto Barraquer, Barcelona

Purpose One of the complications after osteo-odonto-keratoprosthesis is the access to the eye fundus if an intervention is indicated. To improve the prognosis for osteo-odonto-keratoprosthesis patients affected with retinal detachment or other vitreo-retinal pathologies a special contact lens, made of polymethylmetacrylate, has been developed.to facilitate vitrectomy under microsurgical control in these cases.

Methods The lens has a diameter of 12 mm and a central fenestration of 4 mm. Its curvature is similar to the radius of the cornea. After application of the lens on the eye a space similar to the physiologic anterior chamber is created. The convex surface of the lens has a radius which adapts perfectly to the large-field lenses, permitting indistinct use of 68º, 130º or 156º lenses. Visibility of the surgical field is obtained to approach even extremely complicated situations such as advanced vitreo-retinal proliferation requiring multiple complex microsurgical maneuvers.

Results The visual prognosis of osteo-odonto-keratoprosthesis patients with vitreous and/or retinal pathologies is definitely improved.

Conclusion This lens is definitely a valuable contribution extend the indications for vitrectomy in the management of vitreo-retinal pathology in keratoprosthesis patients. It is also useful for implantation of valvular drainage devices, adequately modified for insertion in the pars plana in the management of refractory glaucoma.

■ 1366

Developing a visual function questionnaire for OOKP patients

TANDON R (1, 2), LEE E (3), PAUL B (3), HEROLD J (4), LIU CSC (3)
(1) R P Centre for Ophthalmic Sciences, All India Institute of Medical Sciences, New Delhi
(2) formerly Commonwealth Fellow, Sussex Eye Hospital, Brighton
(3) Sussex Eye Hospital, Brighton
(4) Royal Sussex County Hospital, Brighton

Purpose To devise a visual function questionnaire for OOKP patients, keeping in view the complex nature of their eye disease and the possibility of coexistent posterior segment pathology limiting their visual potential. To try to design the questionnaire to be of relevance to patients of different socioeconomic, ethnic and racial backgrounds.

Methods Patients who had undergone OOKP surgery at the Sussex Eye Hospital in Brighton, UK were interviewed informally when they attended the clinics or were admitted for the management of complications (RT). They were asked a wide range of questions pertaining to their subjective assessment of vision after surgery, ability to perform daily chores such as housework, navigate independantly, read, write, engage in recreational activities, interact socially and so on. An objective measurement of their visual acuity, refractive error and visual fields was made. A formal questionnaire was framed based on questionnaires that had been validated in cataract and corneal graft patients (EL). Based on the results of the informal interviews, this questionnaire was further modified and adapted to what was believed to be suitable for OOKP patients to suit a wide range of functional outcomes and backgrounds.

Results The questionnaire includes 4 sections which assess the patient's perception of functional level of distance vision, near vision, ability to perform activities of daily living and ability to navigate. The questions are designed to cover different grades of vision. Each question is assigned a score ranging from 0 to 3.

Conclusion The questionnaire now needs to be validated which will be done by a repeat interview to be conducted formally in the same cohort of patients following a structured pattern.

■ 1367

The psychology of blindness and sight restoration

LEE E, TANDON R, PAUL B, THORP S, HEROLD J, LIU C
Sussex Eye Hospital, Brighton

Purpose To consider our approach in the preparation of patients for OOKP surgery. The assessment of these patients warrants special attention in view of not only the nature of the operation, but also the population group for whom it is considered.

Methods Our experience in assessing patients for, and counselling them regarding, OOKP surgery is reviewed. In addition, two questionnaires were used to assess the potential visual function following, and psychological implications, of successful OOKP surgery, and hence better inform our patients.

Results Where an improvement in acuity is seen following surgery patients have evidence of good visual function; limitations of the surgery, such as field of vision, glare and cosmetic appearance have a limited impact where the acuity is good, and need not prevent dramatic improvements in visual function. We have not found evidence of significant difficulty in dealing with, and adapting to, a sudden improvement in sight, even after many years of blindness.

Conclusion OOKP surgery has the potential to dramatically improve the visual function of patients registered blind. Adverse psychological reactions to sudden improvements in vision following surgery have been reported in other contexts; however, we have not found evidence of this being a significant problem following OOKP surgery.

■ 1368

BioKPro II results at Moorfields Eye Hospital

WATSON S, HOLLICK EJ, DART JKG, ALLAN BD
Moorfields Eye Hospital, London

Purpose The Legeais BioKpro III (FCI Ophthalmics, Marshfield Hills, MA) is one of 2 fully synthetic Kpros currently commercially available for implantation in the UK; the other device is the AlphaCor (Argus Biomedical, Perth, Australia). In a clinical trial at Moorfields Eye Hospital the Legeais BioKpro III was inserted in 7 patients with corneal scarring from a variety of diagnoses (OCP, measles keratitis, molten metal injury, SJS, aniridia with microcornea, chemical injury, and congenital rubella). The average age at the time of keratoprosthesis surgery was 53.7 years (range 20 to 84). Six patients had hand movement's vision in the eye, and one perception of light. The vision was the same or worse in the fellow eye. The maximum follow up was 36 months and the mean 23.4 months. The keratoprosthesis failed in 6 of the seven patients, due to extrusion of part of the haptic in 5 and complete extrusion of the KPro in one at between 2 and 28 months postoperatively. A retroprosthetic membrane occurred in 3 patients and one patient suffered endophthalmitis. The one patient that retained the Kpro but did not achieve an improvement in vision due to previously undiagnosed optic atrophy. In addition to the two stages of the KPro procedure, all patients required between 1 or 3 further surgical procedures.

EVER-2004-abstractbook.indd 120 8/19/04 12:26:43 PM

1411
Anatomical and histological aspects of the sclera; Classification of scleritis

MOSCHOS MM
Department of Ophthalmology, University of Athens, Athens

Purpose The diagnosis, clinical course and pathology of different types of scleritis are more easily explained if there is a basic knowledge and understanding of scleral anatomy and histology. The scleral anatomy, histology, vascularisation and classification of scleritis are described.

Methods The sclera has 3 layers: the episclera, the stroma and the lamina fusca. The stroma is composed of branching, interlacing bundles of type I, II and III collagen mixed with ground substance along with a few fibroblasts. Fibroblasts have a very low metabolic requirement, supplied by vascularized adjacent structures. The vascular supply of the sclera is divided into the bulbar conjunctival vessels, the superficial episcleral vessels and the deep vascular plexus. The superficial and deep plexi of episcleral vessels consist of fenestrated capillaries, which gives to the scleral vessels their high permeability to fluorescein.

Results Evaluation of the depth of inflammation can be ascertained by observing the relationship of blood vessels to one another. During systemic diseases, inflammatory mediators are produced in the proximity of episcleral and scleral vessels. The anatomical classification of scleritis is based on the primary anatomical site of inflammation and associated vascular changes: anterior scleritis represents the most benign form and can be non-necrotizing (diffuse or nodular) or necrotizing (with or without inflammation). Posterior scleritis (chronic or acute) represents the rarest form of scleritis.

Conclusion It is essential for the ophthalmologist to know and understand the scleral anatomy and histology, in order to classify the scleritis and to establish the correct diagnosis. This is the only way to evaluate and manage a scleritis patient.

1412
Orbit and inflammatory diseases

HAMEDANI M
Hopital Ophtalmique Jules Gonin, Lausanne

Purpose The term of pseudotumor is sometimes confusing and could delay the diagnosis. Orbital inflammations have various clinical aspects and different etiologies. The main differential diagnoses are orbital tumors. The purpose of this presentation is to provide better understanding of orbital inflammatory diseases and their management.

Methods Different clinical aspects of orbital inflammations and their histopathological characteristics are presented. The relevance of orbital biopsy and therapeutic perspectives are discussed.

Results Orbital Inflammations could be considered as specific or non specific based on the knowledge of their etiology. Systemic investigations and orbital biopsies are the key elements of the management. Steroids remain the major therapy followed by differents immunosuppressive drugs.

Conclusion a better knowledge of the etiologies of orbital inflammations will guide the ophthalmologist for the best patient management and outcome.

1413
Rheumatismal diseases and scleritis

VALIDAUX J (1, 2)
(1) Jules Stein Eye Institute, David Geffen School of Medicine at UCLA, Los Angeles
(2) Hôpital Ophtalmique Jules Gonin, Service Universitaire d'Ophtalmologie, Lausanne

Purpose 1. To review epidemiologic data pertaining to the association between scleritis and rheumatic diseases, including risk factors for such an association2. To describe rheumatic diseases associated with scleritis3. To describe and discuss medical and laboratory workup in patients presenting with scleritis, with its therapeutic and prognostic implications

Methods Review of the literature

Results Rheumatic diseases account for the majority of systemic disorders associated with scleritis; 37-50% of patients diagnosed with scleritis have an associated rheumatic disease. Rheumatoid arthritis and systemic vasculitides are the most frequent associated conditions. Wegener granulomatosis represents 28%-50% of associated systemic vasculitides. Other associated disorders are systemic lupus erythematosus, inflammatory bowel disease, and seronegative spondylarthropathies. Risk factors for an associated rheumatic disease in patients diagnosed with scleritis include female sex, bilaterality, and scleritis of the diffuse anterior type. Medical and laboratory workup includes thorough history and clinical examination, as well as individualized laboratory and radiologic evaluation, depending on the clinical presentation. The diagnosis of rheumatoid arthritis or systemic vasculitis in a patient with scleritis carries a poorer ocular prognosis.

Conclusion Identifying any associated systemic disease when a patient presents with scleritis, or diagnosing scleritis in patients with known rheumatic disease may have substantial therapeutic and prognostic implications. Thorough medical and laboratory workup tailored to the clinical presentation of scleritis will help the clinician identify that subset of patients who will require prompt and aggressive management to influence both ocular and systemic prognoses.

1414
Anterior segment ICG and imaging

GUEX-CROSIER Y
Jules Gonin Eye Hospital, University of Lausanne, Lausanne

Purpose Scleritis is a rare inflammatory disorder of the sclera. It is associated with intense ocular pain, decrease in vision and can lead to a loss of sight. Episcleritis is a benign inflammatory disease characterized by cellular infiltration of the episclera. Till now grading of the severity of the disease was mostly based on clinical criteria. Indocyanine green dye is highly protein bound molecule. In the presence of inflammatory lesions an increase of vascular permeability produces a protein exudation that becomes visible by indocyanine green angiography. Anterior segment indocyanine green angiography appears as a perfect tool to follow inflammatory lesions in scleritis.

Methods After injection of a bolus of 25mg of Indocyanine Green diluted in 7.5 ml of 0.9% NaCl external frames of the anterior segment were taken. The following time points were considered: early (up to 3 minutes), intermediate 10 to 12 minutes and late phase (after 30 to 35 minutes). Indocyanine green leakage was evalutated during the late time points (after 30 minutes) and was scored from 0=none, 1 = slight, 2 = moderate, 3 = severe.

Results Indocyanine green leakage was present in scleritis while it was almost absent in episcleritis. A good correlation could be seen with the severity of disease. Severe leakage (score = 3) was seen in patients with scleritis associated with systemic disease. In necrotizing scleritis indocyanine green angiography could show the presence of ischemia and leakage in the zones affected by vasculitis (Ophthalmology 2003, 110;1756-63)

Conclusion Indocyanine green angiography of the anterior segment appears as an useful tool in the diagnosis and the follow-up of severe scleritis.

EVER-2004-abstractbook.indd 121 8/19/04 12:26:43 PM

■ **1415**

Scleritis in Ocular Sarcoidosis

MORA P
Insitute of Ophthalmology, University of Parma, Parma

Purpose To describe the prevalence and the clinical aspects of scleritis in ocular sarcoidosis and to report one case.

Methods Anterior segment pathology is the most common ocular manifestation of sarcoidosis and is seen in 85% of patients. We report the case of a 48 year old caucasian man referring for an impairment of visual acuity. Ophthalmological examination revealed an anterior scleritis of the right eye associated to a choroidal granuloma in the underlying temporal quadrant, and a severe papillitis.

Results Sarcoidosis was suspected basing on negative tuberculin skin test, negative serology for granulomatous infectious diseases, a slightly elevated ACE and an enhanced gallium captation in the right orbita and lacrimal gland. The patient underwent a systemic immunosuppressive therapy combined with topical steroids. Visual acuity recovered to 20/20 after a 1 week regimen, while scleritis and the choroidal granuloma disappeared after a 3-week treatment.

Conclusion The present case describes a "presumed" ocular sarcoidosis with severe scleritis, choroidal granuloma and papillitis at presentation. Scleritis should be considered a rare but well described first sign of ocular sarcoidosis, possibly associated to other visual threatening manifestations such as chorioretinal granulomatosis and optic nerve head inflammation with cerebral involvement.

■ **1416**

Immunosuppressive therapy

DOAN S
Hopital Bichat and Fondation Rothschild, Paris

Purpose To summary the principles of immunosuppressive therapy in scleritis

Results Treatment of scleritis is systemic, based on NSAIDS, corticosteroids and immunosuppressors. Immunosuppressive treatments may be required in several situations : 1- resistance to steroids; 2- systemic steroid dependence; 3- systemic vasculitis requiring immunosuppression like Wegener granulomatosis; 4- necrotizing scleritis, for which immunosuppressive drugs improve the ocular outcome and decrease the mortality from associated systemic disease. Drugs usually used are azathioprine, cyclophosphamide, chlorambucil, methotrexate and cyclosporine. Because of the severe potential side effects, a close collaboration between the ophthalmologist and the internist is required.

Conclusion Immunosuppressive therapy is often required for the treatment of scleritis. Systemic adverse effects should be balanced with the risk of permanent visual loss.

EVER-2004-abstractbook.indd 122 8/19/04 12:26:44 PM

■ 1431

Changes of the human lens capsule thickness between 30 and 100 years of age

MICHAEL R (1), ABREU R (1), TRESSERRA F (2), BARRAQUER R I (1)
(1) Institut Universitari Barraquer, Barcelona
(2) Institut Universitari Dexeus, Barcelona

Purpose To verify the anterior peripheral thickening of the human lens capsule (Fincham 1937) and the change in thickness with age (Fisher 1988).

Methods Altogether 25 human donor lenses (age between 30 and 100 years) were fixed in 3.6 % buffered formaldehyde and paraffin embedded. Sagittal sections were stained for collagen with periodic acid-Schiff (PAS) stain. Images of the lens border were taken with a Zeiss Photomicroscope, a 25x objective and a digital camera. Capsule thickness was measured every 250 µm along the sagittal lens border and the data was evaluated by regression analysis.

Results Capsular thickness at the posterior pole (2 µm), posterior periphery (4 µm) and equator (7 µm) is not changing with age. There was an increase in the thickness at the anterior pole from the youngest to the oldest lenses (10 to 15 µm). Anterior peripheral thickening of the lens capsule was seen in all age groups and was increasing with age (13 to 16 µm).

Conclusion The human lens capsule shows an anterior peripheral thickening at the age of 30 years. This thickening is increasing with age. There is no change in capsular thickness at posterior pole, posterior periphery and equator for the investigated age groups. Anterior peripheral thickening of the lens capsule was found to be very similar to that described by Fincham 1937, but less pronounced changing with age as described by Fisher 1988. However, the posterior peripheral thickening was found minor as described by Fincham, comparable to Fisher 1988. Interesting is the steep increase of capsular thickness between the equator and the anterior periphery.

■ 1432

Investigation of the long-term safety of the *Acri.Tec AR-1 PC/IOL in rabbit eyes: an intraocular lens with reversibly adjustable optical power

KAMPPETER BA (1), FROMBERG I (2), FESSER N (2), ALLGOEWER I (2), JAHN CH (3), WAKILI NS (3), HOFMANN-RUMMELT CR (3), HOLBACH LM (3), JAHN CE (4)
(1) Departement of Ophthalmology, Faculty of Clinical Medicin Mannheim, University of Heidelberg, Mannheim
(2) Acri.Tec GmbH, Hennigsdorf, Germany, Hennigsdorf
(3) Universitäts-Augenklinik Erlangen, Germany, Erlangen
(4) Augenpraxisklinik Dr. Jahn, Kempten, Germany, Kempten

Purpose To examine the long-term safety of the *Acri.Tec AR-1 intraocular lens (PC/IOL) after implantation into rabbit eyes and to optimize surgical technique as well as surgical instruments used to adjust the PC/IOL with reversibly adjustable refractive power.

Methods Implantation of the *Acri.Tec AR-1 PC/IOL into eyes of rabbits after removal of the lens by phacoemulsification and as control-IOL implantation of *Acri.Tec 11 C PC/IOL into the second eye of the rabbit. Manipulation of the lens 8 weeks after implantation in order to change the refractive power. Slitlamp and IOP control for up to 5 months after implantation. Histo-pathologic examination of the eyes.

Results Implantation and mechanical adjustment of the PC/IOL was possible without any problem. Eyes healed normally. No difference between eyes containing the *Acri.Tec AR-1 PC/IOL and eyes containing the control-PC/IOL could be detected with respect to signs of inflammatory reaction, corneal transparency, IOP and histopathologic appearance. Histopathologic examination of the eyes showed that the *Acri.Tec AR-1 PC/IOL did not cause any damage in rabbit eyes.

Conclusion The *Acri.Tec AR-1 PC/IOL is well tolerated in rabbit eyes for extended periods of time suggesting that implantation of this PC/IOL is safe for the long-run. Surgical adjustment of the adjusting element can be performed with little effort several weeks after implantation.

■ 1433

Implantation of an intraocular lens with reversibly adjustable optical power: *Acri.Tec AR-1 PC/IOL

JAHN CE
Augenpraxisklinik Dr. Jahn, Kempten

Purpose Purpose: To examine the short-term safety of the *Acri.Tec AR-1 intraocular lens (PC/IOL) after implantation into adult human eyes and to optimize surgical technique as well as surgical instruments used to implant the PC/IOL with reversibly adjustable refractive power.

Methods Methods: Implantation of the *Acri.Tec AR-1 PC/IOL into six human eyes after removal of the lens through phacoemulsification and as control the implantation of a conventional PC/IOL into the second eye of five patients. Clinical examination after implantation.

Results Results: Implantation was possible without any problem. Eyes healed normally. No difference between eyes containing the *Acri.Tec AR-1 PC/IOL and eyes containing conventional PC/ IOLs could be detected with respect to visual acuity, stabilization of refractive error, signs of inflammatory reaction, corneal transparency, IOP.

Conclusion Conclusion: Our results suggest that the *Acri.Tec AR-1 PC/IOL can be implanted safely into the capsular bag of adult human eyes. Good short-term safety suggests that further exploration of the potential usefullness of this type of reversibly adjustable PC/IOL is reasonable.

■ 1434

The role of case mix in the relationship between volume and outcome in phacoemulsification surgery.

HABIB MS (1), BUNCE CV (2), FRASER SG (1)
(1) Sunderland Eye Infirmary, Sunderland
(2) Moorfields Eye Hospital, London

Purpose We have previously demonstrated a relationship between volume and outcome in phacoemulsification surgery -with a decrease in complication rate with an increase in volume of cases. Many studies of volume and outcome are hampered by the issue of case mix i.e. surgeons doing more complex cases will have higher complication rates. This study was designed to assess the influence of case mix.

Methods Retrospectively, we randomly selected one month per year for each consultant for the same period between 1996 and 2001. Within this month all patients who had phacoemulsifiaction were identified, 20 were randomly selected and their case-notes retrieved. The complexity of cases was assessed using pre- and intra-operative notes and calculated using a standard scoring system. The least complex cases had a score of 1 while the most complex had a maximum score of 11.

Results 81.7 % of requested notes were retrieved. The mean score for case complexity was 1.467 for high volume surgeons versus 1.694 in low volume surgeons. This was not statistically significant. The difference of mean scores between individual surgeons were also not significant, with low volume surgeons scoring slightly higher but this can be attributed to the lower number of cases.

Conclusion This further study suggests that our previous results showing the trend between higher case volume and less complications rates in phacoemulsification surgery cannot be attributed to differences in case mix between the participating surgeons.

EVER-2004-abstractbook.indd 123 8/19/04 12:26:44 PM

■ 1435

Outcome of Phacoemulsification in Patients with Uveitis

ELGOHARY MA (1, 2, 3), MCCLUSKEY P (4), TOWLER H (1), SINGH R (4), OBIKPO R (1), OKHRAVI N (1), DOWLER JF (1), LIGHTMAN S (1)
(1) Ophthalmology, London
(2) Ophthalmology, Colchester
(3) Ophthalmology, Tanta, Egypt
(4) Ophthalmology, Sydney

Purpose To report the visual outcome and complication rate after phacoemulsification (PE) and intraocular lens implantation in patients with uveitis.

Methods A retrospective case-note review of 101 eyes of 101 patients undergoing PE and followed postoperatively for a minimum of 3 months was carried out.

Results Postoperative and final visual improvement of > 2 Snellen's lines occurred in 64% and 71% of patients, respectively. Early rise of IOP occurred in 6%, postoperative uveitis in 22%, macular edema in 21% and PCO requiring YAG capsulotomy in 33% of the patients. Within 3 months postoperatively, the development of uveitis was more likely in female patients (OR=6.21; 95% confidence interval (CI)(1.41, 27.43); p=0.016) and in the presence of synechiae (OR=8.43; 95%CI (1.09, 65.41); p=0.04), and was associated with increased risk of developing macular edema (OR=7.45, 95%CI (1.63, 34.16), p=0.0097). YAG capsulotomy rate was significantly higher in patients with hydrogel IOLs (HR=4.27; 95%CI (1.19, 15.33), p=0.026) and lower with the use of prophylactic steroids (HR=0.24; 95%CI (0.10, 0.58); p=0.001) and in those who had plate-haptic (HR=0.23, 95%CI=(0.08, 0.62); p=0.004) and 3-piece silicone IOLs (HR=0.17, 95%CI=(0.08, 0.62); p=0.004) in comparison with PMMA IOLs.

Conclusion Phacoemulsification results in improved visual acuity in the majority of uveitis patients. Postoperative uveitis may be more likely in female patients and in the presence of synechiae and could increase the risk of macular edema. The use of prophylactic steroids and implantation of silicone IOL appear to decrease the risk of PCO, whereas hydrogel IOL increases it in comparison with PMMA IOLs.

■ 1436

Intraocular Lens movement under ciliary contraction can be enhanced

GALAND A, HUA MT
Dept. Ophtalmologie, Centre Hospitalier Universitaire, Liège

Purpose To incorporate in the design of an implant all features likely to allow a forward movement of the optic when the ciliary muscle contracts.

Methods In accommodation, the capsular bag fornix is anteriorly displaced: to get a 360° transmission of this force, the haptic is ring shaped and has 4 cardinal connections to the optic. In accommodation, the vitreous is anteriorly displaced: to take advantage of it, the optic has more surface area than conventional implants. Implant diameter larger than the capsular bag and haptic vaulting are counter productive features for optic shift : therefore the implant diameter is less than an average capsular bag and there is no haptic angulation.

Results Thirty-four patients who received the new implant in one eye and a classic (North-South configuration) implant in the follow eye, were examined 3 months following the last surgery. The mean spherical addition needed to read Parinaud 2 tests was + 1.50 diopters (range + 0.75 to 2.25) with thenew implant. It was + 2.25 diopters (range + 1.50 to 2.75) with the classic implant. The difference between the 2 groups is significant (P<0.05).

Conclusion Like other "accommodative" implants, the model here described provide a partial accommodation, better than classic pseudophakic implants.The amplitude of the optic movement is not sufficient for reading without addition. However, this partial accommodation leads to a reduction in the spherical addition for near vision and to an improvement in the intermediary uncorrected vision.

EVER-2004-abstractbook.indd 124 8/19/04 12:26:44 PM

■ 1441

Expression of J-chain in the Normal Human Conjunctiva and Ocular Adnexa

KNOP E (1, 2)
(1) Research Laboratory, Dept. of Ophthalmology, Charité – University School of Medicine, Berlin
(2) Dept. of Cell Biology in Anatomy, Medical School Hannover, Hannover

Purpose The ocular surface contains an Eye-Associated Lymphoid Tissue (EALT) as a part of the mucosal immune system and secretory IgA represents a major defence mechanism. Joining chain (J-chain), an accessory peptide in plasma cells is an important co-factor. J-chain was only observed in the lacrimal gland (LG) by immunohistochemistry but has not been verified by RT-PCR and is not reported in the conjunctiva.

Methods Specimens were obtained from different regions of the conjunctiva and from the LG of 10 eyes from five macroscopically normal body donors. Primers for J-chain mRNA were constructed according to published sequence data. Reverse transcriptase (RT-) PCR was performed with standard reagents and compared to histological sections.

Results In all LG tissues, PCR products of the expected size were observed as a single broad band. The same was true in the tissues of the peri-tarsal orbital conjunctiva where a high density of plasma cells is seen in histology. In order to exclude the theoretical possibility of a contamination of the specimens with accessory LG tissue (although it is normally not present in this location) we also analysed bulbar conjunctiva with the same results. Appropriate tissue and methodological controls were performed such as investigation of muscle tissue with an expected absence of RT-PCR products for J-chain but presence of a house-keeping enzyme.

Conclusion J-chain in the lacrimal gland was verified here by the respective mRNA and newly described in the conjunctiva. This verifies, together with the previously shown presence of IgA and SC, that the normal human conjunctiva contributes to the specific immune defence at the ocular surface together with the LG and lacrimal drainage system as a functional unit for ocular surface immune protection.

■ 1442

Ultrastructural features and quantitative analysis of proteoglycans and collagen fibres of in keratoconus corneal stroma

AKHTAR S (1), BRON AJ (2), SALVI SM (3), TUFT S (4), HAWKSWORTH NR (3), MEEK KM (1)
(1) Optometry and Vision Sciences, Cardiff
(2) Nuffield Laboratory of Ophthalmology, Oxford
(3) Royal Glamorgan Hospital, Llantrisant
(4) Moorefield Hospital, London

Purpose To compare collagen fibril (CF) diameters and proteoglycan (PG) area distribution in keratoconus and normal corneas.

Methods One normal (age 24 years) and four keratoconus (age 24-47 years) corneas were fixed in 2.5% glutaraldehyde containing 0.05% cuprolinic blue dye and processed in a standard manner for electron microscopy. Collagen diameter and proteoglycan area were analysed in anterior, mid- and posterior zones of the stroma. Approximately 34,000 collagen fibres and 66,000 proteoglycan structures were analysed using the SIS soft imaging programme. Statistics were performed using the SPSS programme

Results In all keratoconus corneas, the epithelium and basement membrane were thick while Bowman's layer was thin and intact in the regions examined. Most of the stromal lamellae were undulating. In mild keratoconus, for all zones, CF diameters, but not PG area distribution, were significantly reduced ($p<0.000$). In advanced keratoconus, CF diameters were again significantly reduced ($p<0.000$) and PG area was increased ($p<0.000$). In both mild and advanced keratoconus cases, keratocytes were degenerate and contained large amounts of PG.

Conclusion Keratocyte degeneration is found at an early stage of keratoconus, associated with reduced fibril diameter and an alterred PG metabolism. With progression, the PG content of the stroma increases. The alterred stromal content of PG could influence both fibril diameter and organisation in keratoconus.

■ 1443

Effect of native wild type and mutant recombinant keratoepithelin on corneal cells

GLAVINI A (1), KHAN I (2), ALBON J (1), CAI J (1), BLACK GCM (3), BOULTON ME (1)
(1) Cell and Molecular Biology Unit, School of Optometry and Vision Sciences, Cardiff University, Cardiff
(2) Connective Tissue Biology Research Group, Cardiff School of Biosciences, Cardiff University, Cardiff
(3) Academic Unit of Medical Genetics and Regional Genetic Service, St Mary's Hospital, Manchester

Purpose Keratoepithelin is an extracellular matrix protein, the exact role of which has not yet been elucidated. It is expressed systemically, but has attracted significant attention due to its implication with corneal pathology. A number of anterior stromal corneal dystrophies with an autosomal inheritance pattern have been associated with defective keratoepithelin. The aim of this study is to express and purify native wild type and mutant recombinant keratoepithelin and study its effects on primary human corneal cells.

Methods The corresponding gene, beta ig-h3, was subjected to in vitro mutagenesis and was subsequently cloned in a prokaryotic expression vector and transformed in E.Coli, which expressed the recombinant protein tagged to a 10-His repeat. Purification was mediated with Ni-NTA His-bind resin. The effects of the immobilised recombinant proteins on the adhesion, migration and proliferation of corneal keratocytes and epithelial cells were assessed.

Results Mutagenesis gave rise to R555Q and R555W clones, which correspond to Thiel Behnke and granular corneal dystrophies respectively. The recombinant proteins were expressed both in the soluble and insoluble part of the cellular extract, as determined by SDS-PAGE and Western blotting. Purification took place under native conditions and the resulting average concentration was 1mg/ml. Both the wild type and mutant recombinant proteins promoted corneal cell adhesion and migration as well as proliferation, in a concentration dependent way.

Conclusion The in vitro studies on human primary corneal cells indicate that native recombinant keratoepithelin can provide a useful insight into the pathology of the anterior corneal dystrophies.

■ 1444

Laminins in normal, keratoconus, bullous keratopathy and scarred human corneas

BYSTRÖM B (1, 2), PEDROSA-DOMELLÖF F (1, 2)
(1) Dept of Clinical Sciences, Ophthalmology, Umeå
(2) Dept of Integrative Medical Biology, Section for Anatomy, Umeå

Purpose To examine the distribution of different laminin (Ln) chains in normal and diseased adult human corneas.

Methods Eleven corneas were obtained from patients, three normal, three keratoconus, four bullous keratopathy (BKP) and one with a scar after previous deep lamellar keratoplasty (DLKP). The samples were collected with the approval of the Ethical Commitee of the Medical Faculty, Umeå University. Sections were processed for immunocytochemistry with specific antibodies (abs) against Ln a1, a2, a3, a4, a5, b1 and b2 chains.

Results The normal corneas were stained in a similar pattern; the epithelium with abs against Ln a3, b1 and b2 chains; the basement membrane (BM) of the epithelium with Ln a3, a5 and b2 chains and the Descemets membrane (DM) with a3, a5 and b2 chains. The keratoconus corneas showed novel expression of Ln a5 chains in the epithelium. The BKP corneas with Fuch´s dystrophy prior to cataract surgery showed absence of a3 and b2 in the DM, whereas one cornea with pure BKP lacked a3 in the epithelium and DM. The BKP corneas were additionaly stained by b1 at the level of DM. The scarred cornea showed novel expression of Ln a1, a2 and b1 chains in the DM.

Conclusion We show differences in the staining patterns of diseased corneas both in the BM and in the basal epithelial cells indicating a regenerating process. The scarring at the level of DM in the DLKP cornea may be due to an excessive accumulation of Ln chains compared to both normal and other diseased corneas.

EVER-2004-abstractbook.indd 125 8/19/04 12:26:45 PM

■ 1445

Corneal Connexin expression in Connexin 43 Knockout Mice

GICQUEL JJG (1, 2, 3), MILINCHEVITCH SM (4), SALAMA BS (2, 1), BALAYRE SB (1), MESNIL MM (3), DIGHIERO PLD (1, 2)
(1) Ophthalmology, Poitiers
(2) Ophthalmology, Saint Jean d'Angély
(3) Cellular Biology, Poitiers
(4) Pathology, Poitiers

Purpose To describe corneal anomalies induced by functional lack of Cx43; as well as it's expression in newborn and adult mice corneas.

Methods Eyes from wild-type mice and Cx43 (Cx43-/- and Cx43+/-) deficient mice were collected and analysed structurally by light, confocal and electron microscopy. Immunohistochemical study is performed using connexin-specific antibodies in order to assess the presence and localization of CX43.

Results Anatomical anomalies are present in both Cx43 -/- and Cx43-/+ mice corneas. These are major in Cx43-/- newborn mice and minor in Cx43-/+ newborn or adult mice (Cx43-/- mice cannot become adults due to lethal cardiovascular defects). Cx43 is expressed in basal cells of the corneal epithelium as well as between endothelial cells. Cx43 is expressed in different patterns in Cx 43+/+ wild type and Cx43+/- mice in the epithelium; endothelium as well as in keratocytes.

Conclusion These preliminary results indicate that the functional properties of Cx43 are required for normal corneal development in mice.

■ 1446 / 160

Cytokine Regulation of Extracellular Superoxide Dismutase Expression in Keratocytes from Human Corneas with Keratoconus or Bullous Keratopathy

ÅSTRÖM EM (1), MARKLUND SL (2), BEHNDIG A (1)
(1) Department of Clinical Sciences/Ophthalmology, Umeå University Hospital, Umeå
(2) Department of Medical Sciences, Clinical Chemistry, Umeå University Hospital, Umeå

Purpose Extracellular Superoxide Dismutase (SOD3) forms a major physiological defence against superoxide radicals released to the extracellular space. Expression of SOD3 occurs for instance in fibroblasts and smooth muscle cells, and different cytokines and growth factors regulate the expression of SOD3 in these cells. In this study we investigated the effect of different cytokines on the expression of SOD3 in keratocytes from diseased corneas.

Methods Keratocytes obtained from patients with keratoconus (KC) and bullous keratopathy (BKP) undergoing surgery, were cultivated. Platelet-derived growth factor (PDGF), basic fibroblast growth factor (bFGF), interleukin-1α (IL-1α), transforming growth factor-β (TGF-β) and interleukin-6 (IL-6) were added and SOD3 protein was determined with an ELISA, in culture media at 24h, 48h, 72h and 96h and also in cell homogenates. Keratocytes without any added cytokines were used as controls.

Results PDGF down regulated SOD3 expression in both BKP ($p = 0.003$) and KC ($p < 0.001$) compared to the controls. IL-1 ($p = 0.003$) and IL-6 ($p = 0.013$) gave a lower expression of SOD3 in KC keratocytes compared to BKP keratocytes.

Conclusion These findings suggest a general down regulating role for PDGF in SOD3 expression in keratocytes, but also a lower SOD3 expression in KC, than in BKP keratocytes, in response to IL-1 and IL-6.

■ 1447 / 161

Surfactant Protein-D detected in corneal and conjunctival epithelium

SUNDARAM V (1), BRON AJ (1), MCDONALD B (2), CLARK H (3), KNOP E (4)
(1) Nuffield Laboratory of Ophthalmology, Oxford
(2) Department of Neuropathology, Oxford
(3) Department of Biochemistry, Oxford
(4) University Eye Clinic Research Lab, Berlin

Purpose Surfactant Protein-D (SP-D) is a member of the Collectin family of proteins and a component of the lung surfactant complex (eg. SP-A and SP-D). SP-A and SP-D are known to act in first line host defence against microorganisms and modify the inflammatory response to microbial antigens via innate and adaptive mechanisms. SP-D is expressed at extra-pulmonary mucosal sites including the human lacrimal gland, tears and ocular surface. In this study we examined the expression of SP-D in human eye using immunohistochemistry.

Methods We used a Vectastain Elite ABC kit, with polyclonal antibodies against the recombinant fragment of human SP-D, to study the immunohistochemical expression of SP-D in two exenterated human eyes: 1. An 82-year-old male with a baso-squamous carcinoma of the orbit, and 2. A 15-year-old female with recurrent meningioma and proptosis.

Results In case 1 there was strong cytoplasmic staining for SP-D in clusters of basal epithelial corneal cells, sometimes involving more superficial layers, with diffuse conjunctival epithelial staining. In case 2, where central epithelium was missing, there was diffuse staining of conjunctival and peripheral corneal epithelium. There was also scattered positive staining of cells in the conjunctival sub-mucosa and corneal stroma and weak, variable staining of the non-pigmented ciliary epithelium and neuroretina. Negative controls showed no immunoreactivity for SP-D.

Conclusion This is the first immunohistochemical evidence of SP-D localisation in the human corneal and conjunctival epithelium. SP-D may play an immundefensive role at the ocular surface as it does at other mucosal surfaces.

EVER-2004-abstractbook.indd 126 8/19/04 12:26:45 PM

■ 1451

Pneumatic Retinopexy in Patients with Pseudophakic Retinal Detachment

YILMAZ G, GEDIK S, AYNACI B, AKKOYUN I, AKOVA Y
Başkent University Faculty of Medicine, Department of Ophthalmology, Ankara

Purpose To report the management and results of pseudophakic retinal detachment by pneumatic retinopexy using intravitreal perfluoropropane (C3F8) and sulfurhexafluoride (SF6) gas.

Methods Ten patients with pseudophakic retinal detachment were treated by pneumatic retinopexy. All eyes had preoperative ocular examinations including visual acuity and intraocular pressure measurements, slit-lamp examination with a special attention to posterior capsule anatomy and indirect ophthalmoscopy. We used 0.3 ml of 100% C3F8 and 0.5 ml of 100% SF6. Early postoperative intraocular pressure was measured by pneumotonometry. The demarcation laser photocoagulation procedure included at least three rows of confluent green argon laser treatment, each encircling anterior and posteriorly along the entire extent of the detachment was applied postoperatively in all cases. On the first day, all eyes were examined for vitreus hemorrhage, endophthalmitis, subretinal gas and proliferative vitreoretinopathy development. All patients had at least 6 months of follow-up, and mean follow up was 10 months.

Results The mean time interval between cataract surgery and pneumatic retinopexy was 18 months, (range; 3-42 months). In six eyes, posterior capsule rupture was observed. Preoperative visual acuities ranged from hand motions to 0.7. Visual acuity improved in all patients. The overall success rate for reattachment with one operation was 90%. One patient underwent vitrectomy and silicon tamponade procedure. No glaucoma, vitreus hemorrhage, or endohthalmitis developed in any of the eyes.

Conclusion Pneumatic retinopexy is an effective alternative in the treatment of rhegmatogenous retinal detachment. It can also be used in selected psudophakic retinal detachment cases.

■ 1452

Pars plana vitrectomy, retinotomy, subretinal injection of tissue plasminogen activator and gas, for the drainage of submacular hemorrhage in age-related macular degeneration

BETIS F, DARMON J, LEGUAY JM, GASTAUD P
Ophthalmology, Nice

Purpose This pilot study evaluated the safety and efficacy of a new procedure for drainage of submacular hemorrhage in patients with age-related macular degeneration.

Methods In a prospective study, 17 consecutive eyes of 17 patients with small and massive submacular hemorrhage (SMH) secondary to age-related macular degeneration were treated with vitrectomy, retinotomy, subretinal injection of tissue plasminogen activator (25µg, 100µl) by the retinotomy, and gas (C3F8 0,4 cc). Outcome mesasures included subretinal drainage of hemorrhage, best and final visual acuity. ETDRS chart was used.

Results Mean postoperative follow-up was 5,8 months (range, 2-15 months). In 16 of 17 eyes, the procedure result in complete drainage of subretinal hemorrhage in the vitreous. Mean time of complete intravitreal hemorrhage resorption was 13,8 days (range, 1-36 days). Best visual acuity improved by 16,4 letters in all SMH, by 26,4 letters in small SMH (8/17, mean area 11,5 DP, range 4-16 DP), and by 6,5 letters in massive SMH (9/17, mean area 38,1 DP, range 24 – 82 DP). A statistically significant difference was found between preoperative and postoperative visual acuity (best and final) in small SMH (p=0,0078) but not in massive SMH (p=0,37), and between small and massive SMH postoperative visual acuity (p=0,02). Factors associated with poor visual outcome included massive submacular hemorrhage, hemorrhagic pigment epithelial detachment and RPE tear.

Conclusion This technique lead to spontaneous drainage of subretinal clot into vitreous of small and massive submacular hemorrhages and can improve vision in patients with age-related macular degeneration.

■ 1453

Enzymatic lysis and pneumatic displacement of subfoveal hemorrhage: Intravitreal rTPA and SF6

HENRICH PB (1), KONO-KONO JO (1), KLOPFER M (1), PFEILER T (1), KLAEßEN D (2)
(1) Klinikum rechts der Isar der Technischen Universität München, Munich
(2) Gemeinschaftspraxis für Augenheilkunde, Eichstätt

Purpose To assess the effect of intravitreal application of rTPA and SF-6-gas on bleeding size and on visual outcome in patients with subfoveal hemorrhage. Subfoveal bleedings present, typically, as a sudden and dramatic loss in visual acuity. The natural course of the disease is characterized by the formation of a thrombus and a progressive fibrotic transformation. Retinal receptor damage is inflicted and, clinically, the natural course is commonly marked by permanent loss of visual acuity. ARMD as underlying condition is associated with a particularly poor visual prognosis with 80% of patients retaining severe visual impairment.

Methods A case series of 11 consecutive subfoveal hemorrhages treated with intravitreal application of 50micrograms of rTPA and 0.5ml of pure SF-6-gas were retrospectively evaluated for the reduction of bleeding size and visual outcome. Mean follow-up was 53 days (7-224).

Results Bleeding size reduction occurred in 81% of cases. In 63% visual acuity increased between 1 and 8 lines, in 17% there was no alteration. ARMD was the underlying condition in 45%. None of the ARMD Patients improved more than 1 line. The duration of symptoms before presentation had been between 2 and 9 days. The duration of symptoms showed no correlation with visual recovery.

Conclusion Intravitreal rTPA and SF-6 application is capable of reducing bleeding size. Partial or complete visual recovery is observed in the majority of patients. ARMD patients show a relatively unfavorable visual recovery, but the displacement of the bleeding may allow further therapy. Within the first 9 days, the duration of symptoms does not seem to alter the course.

■ 1454

ET-1 immunoreactivity of human idiopathic and proliferative vitreoretinopathy epiretinal membranes

ROLDAN-PALLARES M (1), ROLLÍN R (2), MEDIERO A (2), MARTINEZ-MONTERO JC (3), FERNANDEZ-CRUZ A (4), BRAVO-LLATA C (5), FERNANDEZ-DURANGO R (6)
(1) Ophthalmology. Univ. Complutense. Hospital Clinico, Madrid
(2) Medicina Interna III (Unidad de Investigacion). Hospital Clinico, Madrid
(3) Anatomia Patologica. Instituto Oftalmico. Hospital Gregorio Marañon, Madrid
(4) Medicina Interna III. Hospital Clinico. Univ Complutense, Madrid
(5) Matematicas. Univ. Complutense, Madrid
(6) Medicina Interna III.(Unidad de Investigación).Hospital Clinico, Madrid

Purpose ET-1 is a vasomodulator peptide that play a role on ocular blood flow, glial proliferation and collagen matrix contraction by retinal pigmented epithelial (RPE) cells. Both glial and RPE cells have been involved in the formation of epiretinal membranes (ERMs). The aim of this study was to determine whether ET-1 may be associated to ERMs, either idiopathic (IER) and/or from proliferative vitreoretinopathy (PVR).

Methods Plasma and vitreous samples were collected from seventy-five patients candidates to first vitrectomy and classified as control (n=25, eleven of them with IERMs), retinal detachment (RD, without PVR, n=25) and PVR (grade C3 or worse, n=25). IR-ET-1 was measured in plasma and vitreous by radioimmunoassay. Epiretinal tissue was obtained in sixteen cases. IR-ET-1 was localized in IERMs and PVR membranes immunohistochemically.

Results IR-ET-1 levels in plasma and vitreous were higher ($p<0.0001$) in patients with PVR and in patients with RD than in those of the control group. Eyes with IERMs showed also higher ($p<0.0001$) levels of IR-ET-1 than the other cases of the control group. IR-ET-1 levels of eyes with PVR were higher ($p<0.0001$) than those of eyes with IERMs. IR-ET-1 levels of eyes with RD were also higher ($p<0.001$) than those of eyes with IERMs. IR-ET-1 was localized in the cellular and stromal components of both IERMs and PVR membranes.

Conclusion IR-ET-1 in human vitreous is elevated in PVR, RD and IERMs. IR-ET-1 is localized in epiretinal tissue of both idiopathic (glial cells) and PVR (glial and RPE cells) membranes. These data suggest an involvement of ET-1 in epiretinal membranes.

EVER-2004-abstractbook.indd 127 8/19/04 12:26:46 PM

1455

Safety testing of infracyanine green using retinal pigment epithelium and glial cell cultures

EL-AMIR AN (1, 2), JACKSON TL (2), VOTE B (3), KNIGHT B (2), STANFORD M (2), MARSHALL J (4)
(1) Department of vitreo-retinal surgery, Moorfields Eye Hospital, London
(2) The Rayne Institute, St. Thomas' Hospital, London
(3) Moorfields Eye Hospital, London
(4) The Rayne Institute, St Thomas' Hospital, London

Purpose To undertake safety testing of infracyanine green (IFCG) using a cell culture model.

Methods Experiments were undertaken using a cell culture model used previously to perform safety testing of indocyanine green (ICG). Human retinal pigment epithelium (RPE) and Müller cells were exposed to IFCG for 5 minutes, over a range of concentrations up to 0.5%. Experiments were repeated using double staining with trypan blue. Cell viability was measured at day 1, 5 and 15 using a mitochondrial dehydrogenase assay and fluorescent live dead probe containing calcein and ethidium homodimer-1. Viability was measured following exposure to 0.5% IFCG and five minutes illuminations from a vitrectomy endolight powered by a Xenon light source.

Results RPE viability was not reduced over the range of concentrations and follow-up intervals. Those exposed to IFCG and illumination had reduced viability relative to the negative control (cells exposed to saline), but not relative to those exposed to saline and illumination. Glial cells showed reduced viability at day 1 and 5, but not day 15. Illumination did not further reduce viability.

Conclusion IFCG has been advocated as a safer alternative to ICG. These experiments suggest that it is less likely to produce phototoxicity, but despite being nearly iso-osmolar, IFCG also produces damage in cultured glial cells.

EVER-2004-abstractbook.indd 128 8/19/04 12:26:46 PM

■ 1461

Keratoprosthesis at Bascom Palmer Eye Institute clinical experience and research advances

FERNANDEZ V (1), STOIBER J (1, 2), LAMAR PD (1, 3), KAMINSKI S (4), LACOMBE E (5), DUCHESNE B (6), ACOSTA C (1), OROZCO M (1), HERNANDEZ E (1), ALFONSO E (1), PAREL JM (1, 7)

(1) Ophthalmic Biophysics Center, Bascom Palmer Eye Institute, Univ. of Miami, Miami, FL
(2) Dept. of Ophthalmology, Paracelsus Private Medical University Salzburg, Salzburg
(3) Rudolf Foundation Hospital Dept. of Ophthalmology and Ludwig Boltzmann Institute for Retinology and Biomicroscopic Laser Surgery, Vienna
(4) Dept. of Ophthalmology, Univ. of Vienna, Vienna
(5) Rothschild Foundation Eye Hospital, Paris
(6) CHU Sart-Tilman, Dept. of OPhthalmology, Liege
(7) CHU Sart-Tilman, Liège

Purpose Analyze the Boston (Dohlman) keratoprosthesis outcome at BPEI and experimentally assess a non-perforating synthetic cornea (supraDescemetic Synthetic Cornea, sDSC).

Methods 1980-2004 retrospective chart review of 10 Dohlman KPro cases (11 eyes). Over 100 rabbits and 20 human cadaver eyes received a sDSC made of 4 polymers, intrastromally (~90% depth) in 59 rabbits, on denuded DM in 17 rabbits, and in a 3rd group (15 rabbits), ~45 days after the application of 1-heptanol and limbus surgical removal. The corneal surface was covered with a conjunctiva-Tenon flap which was trephined ~63 days later. Support: European project BMH4-CT97-9507, Florida Lions Eye Bank, Research to Prevent Blindness, FWF Austrian Science Fund, Henri and Flore Lesieur Foundation, NIH P30 EY14801.

Results Anatomical success was achieved in 10 of 11 Boston KPro eyes. 3 had an uncomplicated postoperative course. sDSC implanted in deep stroma developed opacities in the DM-KPro optic interface while it rarely occurred with a sDSC placed directly on DM. In burned eyes, 5 animals needed conjunctival flap repair. 60% of the PMMA and 60% of the HEMA-NVP75 implants retained central transparency, the others had developed neovascularisation in the DM-KPro optic interface. 100% of the HEMA-MMA34 sDSC displayed a clear DM. None of these eyes had epithelium downgrowth. The Eye Bank eye experiment confirmed implantation to be feasible even in cases of microperforation (3 eyes) but not with macroperforation (1 eye). Histological evaluation displayed a very thin layer of stroma (<2um) remaining on DM in 5 eyes and a minimally thin layer (<10µm) in the others.

Conclusion The functional success in our Dohlman KPro patient series was shown to be function of the preoperative corneal diagnosis, supporting previously published findings regarding factors affecting final outcome. supraDescemetic Synthetic Cornea made of HEMA-MMA34 showed the most promising results. As opening of the anterior chamber is not required, the sDSC theoretically offers less risks and complications than penetrating KPros.

■ 1462

Glaucoma Following Keratoprosthesis Surgery

DOHLMAN C
Massachusetts Eye and Ear Infirmary, Boston, MA

Purpose Glaucoma is a frequent and often severe complication after keratoprosthesis surgery. To protect such eyes we have implanted standard glaucoma shunts (Ahmed S-2 valve shunt) in about 150 cases, with initially good results. In eyes with chronic inflammation and cicatrizing tendencies such as after chemical burn or in autoimmune diseases, a dense capsule forms around the shunt plate, obstructing the flow and causing the intraocular pressure to rise. We have tried to develop shunts that can divert aqueous to epithelialized cavities where an obstructing capsule is less likely to form.

Methods We have asked Dr. Ahmed (New World Medical, Inc.) to make shunts where the valve is enclosed and a distal tube added, the latter for diverting the aqueous to distant sites. The distal tube has been led to the lacrimal sac (2 cases), to the ethmoid sinuses (6), to the maxillary sinus (12), and to the lower lid fornix (6) – a total of 26 patients. Dr. Peter Rubin, a plastic surgeon, has helped with the distal insertions. The patients have been followed from 3 months to 3 years.All patients receive topical antibiotics.

Results No endophthalmitis has occurred – the valve shunt is unidirectional. Two valve housings eroded and were replaced. Obstruction of the system (at unclear levels) have occurred in four instances, but in the remaining cases the intraocular pressure has stayed in the low teens without glaucoma medication.

Conclusion On a short term basis it seems that implanting tubing to divert aqueous humor from a glaucoma valve shunt to distant epithelialized cavities will not necessarily result in ocular infection in keratoprosthesis patients. Further studies are necessary to determine the long term effect of such shunts on the intraocular pressure.

■ 1463

Sudden, Presumed Sterile, Vitritis in Patients with Keratoprosthesis

NOURI M, DURAND ML, DOHLMAN CH
Mass. Eye and Ear Infirmary, Harvard Medical School, Boston, MA

Purpose To report an event presumed to be sterile vitritis in association with a PMMA Keratoprosthesis.

Methods Between 1990 and 2003, 218 patients underwent an all-polymethylmethacrylate, collar button-shaped KPro surgery. Preoperative diagnoses were multiple graft failures, chemical burn, Stevens-Johnson Syndrome (SJS) or Ocular Cicatricial Pemphigoid (OCP). All patients were maintained on prophylactic topical ofloxacin 0.3% or polymyxin-B/trimethoprim, as well as prednisolone acetate 1% (in two cases medroxyprogesterone 1%), at least twice daily. Vancomycin (14mg/ml) was also given twice daily in two patients.

Results Vitritis occurred in eight patients (12 episodes), 2 to 23 months postoperatively. All patients presented with sudden, marked decrease in vision with minimal or no pain, tenderness, conjunctival redness or discharge. Eight of the twelve events were subjected to vitreous tap and injection of antibiotics and steroids upon presentation. Cultures grew Staphylococcus epidermidis only in liquid (broth) media, in 3 cases, the other five showed no growth. The vitritis episodes resolved after two to nine weeks. Full recovery to pre-episode status of a quiet eye with clear vitreous was seen in all patients. Visual acuity recovered almost completely, or completely (mental debilitation in one patient made accurate assessment uncertain).

Conclusion This phenomenon of sudden vitritis after KPro, with complete recovery, is unlikely to have been caused by microorganisms. It may rather be an immune phenomenon.

■ 1464

An update on the Coralline / Hydroxyapatite KPro

LEON CR (1), BARRAQUER JI (2)
(1) Instituto de Cirugia Ocular, Clinica Leon, Guatemala City
(2) Instituto de Cirugia Ocular, Clinica Barraquer, Bogota

Purpose The ideal prosthesis will let the tissue grow into the supporting material and have a similar curvature as the recipient cornea.

Methods We developed a new support for keratosthesis made of hydroxyapatite. They were implanted unilaterally in the eyes of 12 New Zealand rabbits for 12 months (1995) before the first six human cases.

Results We observed good vascularization. There were no signs of infection or extrusion, epithelial downgrowth, or any adverse tissue reaction. Human cases are presented individually some with good results with follow up of 6 to 9 years. An Update of new models and results are presented.

Conclusion This biocompatible keratoprosthesis with a biointegrable, nonbiodegradable and colonizable haptic can help many people to see again.

EVER-2004-abstractbook.indd 129 8/19/04 12:26:47 PM

1465
AlphaCor artificial cornea data: An update

HICKS CR
Lions Eye Institute, Nedlands

Purpose To report current AlphaCor outcome data.

Methods AlphaCor is a hydrogel biointegratable artificial cornea implanted in cases where a donor corneal graft would be expected to fail. Prospective data are collected pre-operatively and every 3 months post-operatively on all AlphaCor cases and the dataset is re-analysed monthly.

Results Data are given current to the end of the previous month. To date of abstract submission, data complete to end May 2004, 150 devices had been implanted and the probability of 1-year retention for non-herpetic cases receiving topical 1% medroxyprogesterone postoperatively is 86%. The mean gain in visual acuity is 2 lines, with best corrected post-operative VA ranging from HM to 6/6.

Conclusion AlphaCor data compare favourably with data for high risk grafts. The procedure does not require immunosuppression, other than a brief course of steroids, generally topical only, and is reversible in the event of complications. Surgical techniques are evolving to shorten and simplify the procedure. Post-operative management remains under review and the optimum methods of refractive correction remain to be determined. Contact lens wear over AlphaCor is becoming more common but fitting may be difficult.

1466
Keratocyte integration in biomimetic materials

MEHTA JS (1, 2), FUTTER C (1), ALLAN B (1, 2)
(1) Moorfields Eye Hospital, London
(2) Institute of Ophthalmology, Bath Street, London

Purpose The successful integration of keratoprostheses (KPros) within the cornea depends on the skirt host keratocyte adhesion to anchor the implant and prevent epithelial downgrowth. Currently available artifical KPros use either PMMA, p(HEMA) or PTFE as a skirt but are prone to complications e.g. implant extrusion and retroprosthetic membranes. The aim of this study was to assess the suitability of different materials as possible keratoprosthetic skirts.

Methods Keratocytes were seeded on to discs made of Hydroxyapatite (HA), p(HEMA), PTFE and glass. The cells were incubated for 4 hours, 24 hours and 1 week at 37°C with triplicate discs for each time point. Assays for viablility / cytotoxicity cell adhesion were performed using solutions of calcein-AM and ethidium homodimer-1. Cells were then counted using 5 fields of view on each disc.

Results The viability/cytotoxicity assays indicated increased cell viability on HA/glass/PTFE with increasing duration of incubation. pHEMA had the lowest cell counts. However, cytotoxicity assays were higher in PTFE>pHEMA.

Conclusion HA was the most viable material for keratocyte integration. Currently used materials e.g. PTFE, pHEMA either had low cell counts or high numbers of cell cytotoxicity. Newer polymers may need further modification before development as a skirt may be considered.

1467
The effect of atmospheric plasma surface treatment of poly(methyl methacrylate) PMMA on corneal epithelial cell growth and protein absorption

MOORE JE (1, 2), SMALL D (1), FRAZER DG (2), MEENAN BJ (3), LIU C (3), ATKINSON SD (1), GRAHAM JE (1), DOWNES CS (1), MOORE CBT (1)
(1) Centre for Molecular Biosciences, School of Biomedical Sciences, University of Ulster, Coleraine
(2) Department of Ophthalmology, Royal Victoria Hospital, Belfast
(3) Northern Ireland Bio Engineering Centre (NIBEC), University of Ulster, Jordanstown

Purpose The success rate of poly(methyl methacrylate) (PMMA) derived Kpro has been compromised by complications leading to eventual extrusion. The use of surface modifications has re-focused attention to PMMA derived Kpros with the aim of using induced changes in surface properties to encourage healthy growth and proliferation of corneal epithelium over the PMMA optic.

Methods Surface modifications were performed on 14mm PMMA discs using an atmospheric pressure dielectric discharge methodology. Time course studies were performed to confirm the stability of such modifications after contact with air and/or liquid. Both immortalised conjunctival & explant corneal epithelial cells grown on modified PMMA discs and cell adhesion and protein absorption was analysed via Western Blots and immunohistochemical analysis.

Results Time course studies confirmed the stability of all modifications after contact with air and/or liquid. Corneal and conjunctival epithelial cells displayed varying levels of adhesion onto the modified PMMA surfaces with maximum adhesion noted on PMMA treated at a power of 500W for a total exposure time of less than 30s. A significant difference in protein absorption between treated and untreated PMMA was also noted.

Conclusion This preliminary study has demonstrated that surface modification of PMMA increases conjunctival and corneal epithelial cell adhesion to the polymer and also affected protein absorption. Further studies are on going to investigate this effect in more detail with respect to controlling the potential host response in vivo.

1468
Update on tissue engineered bio-synthetic corneas

GRIFFITH M (1), LIU Y (2), CARLSSON DJ (2), LOHMANN CP (3), GAN L (4), LI F (1)
(1) University of Ottawa Eye Institute, Ottawa
(2) ICPET, National Research Council Canada, Ottawa
(3) University of Regensburg, Regensburg
(4) Ophthalmology Department, Linköping University, Linköping

Purpose Our objective is to tissue engineer corneal replacements that will act as scaffolds to allow corneal tissue repair and nerve regeneration.

Methods Corneal matrix substitutes were fabricated from extracellular matrix molecules such as collagen and reinforced with synthesized polymers. These bio-synthetic synthetic corneas were implanted into rabbits, pigs and dogs, primarily by lamellar keratoplasty (LKP). Clinical examination (including in vivo confocal microscopy, topography, aesthesiometry) and histopathology was performed.

Results All TE corneas showed very good integration with the host tissue. Epithelial coverage over the implant was restored. In addition, there was in-growth of corneal cell, engraftment and the host corneas. Epithelial cells covered the implant surface within the first week. At later time points, the host keratocytes migrated into the implants and re-innervation of the operative site occurred with restoration of touch sensitivity. Most of the transplants were transparent after 4 months, and no immune rejection observed. Histology showed good biocompatibility and host integration.

Conclusion Bio-synthetic corneas were successfully transplanted into animal models with no immune or inflammatory reaction. The smooth repair and regeneration corneal tissues within the hosts show that tissue engineered corneal constructs that promote regeneration are possible in the future.

EVER-2004-abstractbook.indd 130 8/19/04 12:26:47 PM

1469

Novel composite materials for the fabrication of artificial corneae

LLOYD AW (1), FRANKLIN V (2), ROSE S (1), MORRIS C (1), TIGHE BJ (2), LIU C (3)
(1) Biomedical Materials Group, University of Brighton, Brighton
(2) Aston Biomaterials Group, University of Aston, Birmingham
(3) Sussex Eye Hospital, Brighton

Purpose There is increasing demand to develop high performance biofunctional, biomimetic, anisotropic materials which will provide biointegrative skirt materials and bioinert optics Various studies have shown that calcium phosphate salts provide a useful substrate for tissue integration, the success of the OOKP being a testimony to this in the cornea. This paper describes a novel approach to achieve a calcium phosphate coating on polymeric Kpro skirt materials and evaluates their in vitro potential to encourage keratocyte adhesion and proliferation.

Methods Novel porous, hydrogel-based biomimetic materials described previously were synthesised and coated with calcium phosphate salts using a proprietary technique. The adhesion and proliferation of keratocytes on these materials was investigated using standard techniques.

Results The modification of the material surface using calcium phosphate modified the biological properties of the implant materials whilst still providing the ability to engineer the underlying polymer to achieve appropriate mechanical properties.

Conclusion Future single piece, polymeric, keratoprosthetheses, with appropriate biological, optical and mechanical properties, many be improved by the use of calcium phosphate coatings to enhance tissue integration.

EVER-2004-abstractbook.indd 131 8/19/04 12:26:48 PM

2111
Novel modes of topical drug delivery

WILSON C
Department of Pharmaceutical Sciences, Strathclyde University, Glasgow

Purpose To review novel methods of topical drug delivery to the eye.

Methods Personal research and a review of the literature.

Results Conventional topical dosing results in the inefficient transfer of drug across the cornea with 3-7% of the dose being absorbed into the anterior segment. To prolong exposure or to increase flux, formulation approaches or chemical modification are possible strategies. Although reduction of drop volume promotes higher bioavailability, this is difficult to achieve except by a spray. Other technologies are more invasive and interest in iontophoresis has waxed and waned over the years, since damage to the sclera may alter function.Scleral delivery is an interesting alternative which may move molecules as large as 70 kDa across the sclera. The central problem is whether a significant proportion of the drug is lost via the choroid. Lowenstein et al. (Ophthalmology 108: 759-764 2001) showed that a subconjunctival injection of gentamicin into the surgically-thinned rabbit sclera causes retinal damage. This suggests that a system able to deliver drugs to the target in a controlled manner might be valuable by reducing toxicity.Recent work in our laboratory has exploited these observations, using a two photon correlation spectrometer, to follow the rapid movement of tazoretenic acid through the sclera. Movement occurred particularly along collagen fibres at a depth of 100µm in the isolated, perfused bovine eye. The material was applied to the surface of the sclera in a PVA patch and the data suggests that the distribution occurs faster at this level in the sclera than laterally through the episclera.

Conclusion Novel methods of drug delivery can enhance the delivery of drugs into the anterior and posterior segments of the eye.

2112
Steroid Action at the cellular level

BRON AJ
Nuffield Laboratory of Ophthalmology, Oxford

Purpose To review current knowledge of glucocorticoid (GC) actions in the context of ophthalmic therapy.

Methods Literature review.

Results Within the cell GCs are activated and then complex with the alpha receptor. The complex translocates to the nucleus where action is modulated by the beta receptor. This inhibitory protein can cause steroid resistance.Many anti-inflammatory GC effects results from repression of pro-inflammatory genes, activated by transcription factors such as NFkB, AP-1, and by NF-AT, which transcribes the IL-2 gene. Cyclosporin and FK506 also block the NF-AT pathway, explaining their steroid-sparing effect. GCs, by blocking IL-2 and IL-4 JakSTAT signalling, inhibit T-cell proliferation and Th2-mediated humoral responses. NFkB blockade inhibits genes important to Th1 and Th2 responses, white cell chemoattraction and several CAM expression. Steroids induce histone de-acetylation, which restricts the access of pro-inflammatory transcription factors to the nucleus.Bone demineralisation and Cushing's syndrome and certain important anti-inflammatory effects, are due to direct gene activation. GC-induced annexin-1 inhibits leucocyte adhesion, causes inflammatory cell apoptosis and inhibits eicosanoid formation by restricting the action of PLA2 on membrane lipids. GCs also inhibit prostaglandin synthesis by shortening COX2 mRNA survival. Annexin-1 is part of the pituitary-adrenocortical feed-back loop responsible for GC suppression of ACTH release.

Conclusion Glucocorticoids are powerful anti-inflammatory agents whose varied physiological role explains their therapeutic diversity. A recognition of their mode of action is the basis for the development of steroid analogues with greater potency and fewer side effects.

2113
Selecting and Monitoring Corticosteroid Use

EASTY D
Ophthalmology, Bristol

Purpose To determine selection and management of corticosteroids in treatment of certain external eye diseases.

Methods Literature Survey.

Results Literature Survey.Results. Corticosteroids, used cautiously, can be potent and effective modalities in the treatment of inflammatory conditions of the external eye. Examples of diseases that may respond to topical corticosteroid are allergic and atopic conjunctivitis, herpes simplex and herpes zoster keratitis, scleritis, Stevens-Johnson syndrome, Thygeson's keratitis, keratoconjunctivitis sicca, Sjogren's disease, and treatment for immunological rejection following keratoplasty. Nevertheless they can produce adverse ocular and systemic events. To minimise systemic adverse effects, an array of local ophthalmic preparations and delivery techniques have been developed. Ocular penetration depends upon drug concentration, chemical formulation, and composition of the vehicle. Small modifications can increase intraocular drug concentration. Corticosteroid-induced ocular hypertension and glaucoma continue to be significant risks. Posterior subcapsular cataract is thought to be due to covalent binding of corticosteroid to lens protein with subsequent oxidation. Use of topical treatment in the presence of corneal infections remains controversial. Other risks include tear-film instability, epithelial toxicity, crystalline keratopathy, decreased wound strength, orbital fat atrophy, ptosis, limitation of ocular movement, and reduction in endogenous cortisol.

Conclusion The prudent use of topical corticosteroid preparations are effective in management of many inflammatory diseases of the external eye, yet require rigorous monitoring to avoid the complications that continue to afflict our patients.

2114
Mechanisms and Management of Ocular Allergy

LEONARDI A, MOTTERLE L
Ophthalmology, Padova

Purpose The immunopathogenic mechanisms of ocular allergic diseases involve a combination of IgE-mediated and T celll-mediated responses. Increased expression of IL-4 and IL-13 has been shown in seasonal allergic conjunctivitis (SAC), where mast cell degranulation products such as histamine and Th2-type cytokines are thought to orchestrate the early- and late-phase reaction. However, other cell types and multiple cytokine production are likely to be involved in the complex pathogenesis of seasonal and chronic allergic eye diseases.

Methods Studies have been conducted on tears, conjunctival impression cytology material and on conjunctival biopsies.

Results Different patterns of cytokine and chemokine profile can be described in patients affected by SAC, vernal (VKC), atopic keratoconjunctivitis (AKC) and giant papillary conjunctivits (GPC) using a multiplexed bead analysis. A Th2-like profile is typical of VKC, a shift towards a Th1-like profile can be found in AKC and a non-polarized cytokine profile is found in GPC. Tissue remodeling may be driven by cytokines, growth factors and proteases released by activated inflammatory cells and by activated resident cells, such as fibroblasts and epithelial cells. In fact, both epithelial cells and fibroblasts exposed in vitro to Th2-type cytokines express and produce multiple pro-inflammatory factors such as IL-6, IL-8, RANTES and MCP-1, while only only fibroblasts produce eotaxin.

Conclusion The treatment of ocular allergy must deal with the complex pathogenesis of these disorders. New topical drugs have multiple actions and may benefit the diverse features of these conditions.

EVER-2004-abstractbook.indd 132 8/19/04 12:26:48 PM

■ 2115

Newer Horizons in Ophthalmic Anti-infectives for Therapy of External Ocular Infections

O'BRIEN T
Ocular Microbiology Laboratory, The Wilmer Eye Institute, Johns Hopkins University School of Medicine, Baltimore, Maryland

Purpose Epidemiologic data disclose trends toward increasing incidence of ocular infection with a preponderance of gram-positive bacterial pathogens. Laboratory susceptibility data indicate the emergence and spread of antimicrobial resistance among ocular pathogens.To review the latest information on newer antimicrobial agents and their potential role in therapy of external ocular infections.

Methods Analysis of recent reports in the ophthalmic literature assessing antimicrobial agents for treatment of external ocular infections.

Results No single agent or class is universally omnipotent against all potential ocular pathogens causing external infection. Fluoroquinolone antibiotic agents possess many of the favorable properties of the ideal antibiotic agent. Gatifloxacin, moxifloxacin and gemifloxacin are potent new generation fluoroquinolones with an expended spectrum of activity including most gram-positive ocular pathogens, such as Staph and Strep species, while maintaining excellent activity against gram-negative ocular pathogens, comparable to ciprofloxacin. Non-fluorinated quinolones, ketolides (telithromycin), newer glycopeptides, oxazolidinones (linezolid), peptide deformylase inhibitors (PDF), efflux pump inhibitors and cationic peptides represent newer approaches to be explored for their potential in treating external ocular infections. Modifications of traditional approaches in order to discourage development of antimicrobial resistance among ocular pathogens will also be discussed.

Conclusion Gram-positive pathogens are frequent causes of external ocular infection. Emergence and spread of antimicrobial resistance among these ocular isolates is of international concern. Newer strategies to effectively treat and prevent resistance for external ocular infection are necessary.

■ 2116

Coping with Complex Ocular Surface Disease

CURSIEFEN C
Schepens Eye Research Institute, Boston, MA

Purpose Disturbances at the interface of ocular surface and tear film can cause a plethora of potentially sight-threatening diseases. Especially persistent epithelial healing problems in combination with or caused by a dysfunctional tear film/dry eye, reduced epithelial healing capacity, limbal stem cell defects, lack of neurotrophic growth factors and corneal neovascularization can be devastating.

Methods Review of the literature and of own unpublished studies.

Results Novel treatment options for some aspects of persistent epithelial defects are outlined. Both clinically established therapeutic options as well as strategies under experimental/preclinical investigation are evaluated. Treatment options which are discussed include amniotic membrane transplantation, replacement of limbal stem cells, topical delivery of serum eye drops and antiangiogenic treatment strategies.

Conclusion The availability of several novel therapeutic options has the potential to markedly improve the prognosis of severe and complex ocular surface diseases.

EVER-2004-abstractbook.indd 133 8/19/04 12:26:49 PM

■ 2121

Risk factors for visual loss in an italian population- based cohort of patients with giant cell arteritis

CIMINO L (1), SALVARANI C (2), CAPPUCCINI L (3), BOIARDI L (4)
(1) Ocular Immunology Unit, Arcispedale S.M. Nuova, Reggio Emilia, Italy
(2) Rheumatology Unit, Arcispedale S.M. Nuova, Reggio Emilia, Italy
(3) Ocular Unit, Arcispedale S.M. Nuova, Reggio Emilia, Italy
(4) Rheumatology Unit, Ospedale S.M. Nuova, Reggio Emilia, Italy

Purpose Evaluate the frequency of visual manifestations at presentation in an Italian population-based cohort of patients with biopsy-proven giant cell arteritis (GCA) and examine predictors for the development of permanent visual loss.

Methods 136 Reggio Emilia (Italy) residents with biopsy-proven GCA diagnosed between 1986-2002. Medical records, demographic, clinical and laboratory data were collected.

Results 26 patients (19.1%) had permanent partial or total visual loss, 24 of these had anterior ischemic optic neuropathy and 2 had central retinal artery occlusion. 19/26 patients had unilateral and 7/26 bilateral visual loss.In 25 patients the visual loss developed before glucocorticoid therapy ; in only one patient it occurred 14 months after diagnosis.The age at onset of disease was significantly higher in patients with permanent visual loss compared with those without. The frequency of systemic signs/symptoms and ESR and CRP values at diagnosis were significantly lower in patients with permanent visual loss. By multivariate logistic regression the best predictors for the development of permanent visual loss included the absence of high levels of ESR at diagnosis (tertile 2: OR = 0.08; tertile 3: OR = 0.11), an older age at onset of disease (OR = 5.60), the presence of elevated platelet level at diagnosis (OR = 4.99) and the absence of systemic manifestations (OR = 0.24).

Conclusion The proportion of italian patients with GCA who developed visual loss was similar to that reported in other countries. The patients with low inflammatory response had a higher risk of visual loss.

■ 2122

Sudden loss of visual acuity in children and youth - diagnostic problems

POJDA-WILCZEK D, HERBA E, POJDA SM
Department of Ophthalmology and Eye Clinic Division Medical University of Silesia, Bytom

Purpose The aim of this study is to present our diagnostic way and algorithm of examinations in patients with sudden loss of visual acuity.

Methods Pattern visual evoked potentials were done in all patients suffered from visual acuity loss for verification. When verification was positive and visual problems were confirmed the other diagnostics procedures were used (other electrophysiologic examinations, CT, MRI, fluorescein angiography, lab tests, etc.). When the verification was negative and the VEP results have indicated that visual acuity should be normal or at least better than was actually found it was necessary to distinguish the psychological or psychiatric problems.

Results Some patients are malingerers or hysteric, the others have deep psychological or psychiatric disorders and should be treated by specialists. Among our young patients we have found optic neuritis, amblyopia, brain tumors, hysteria, psychosis, depression but some of them were malingerers and jokers.

Conclusion Visual acuity loss in children sometimes is very difficult to confirm and diagnosis requires a lot of tests. Among them PVEP in our opinion should be done in the first order.

■ 2123

Inflammation of ciliar ganglion with retrobulbar optic neuritis symptoms - case report

HERBA E, POJDA-WILCZEK D, POJDA SM, MAKOWIECKA-OBIDZINSKA K
Department of Ophthalmology and Eye Clinic Division Medical University of Silesia, Bytom

Purpose The aim of this study is to present diagnostic problems with patient who has complained of low visual acuity and was previously treated because of retrobulbar optic neuritis.

Methods Pattern VEP, MRI, CT.

Results 19-year-old woman had periodical symptoms in left eye such as: lowering of visual acuity from 1,0 to 0,4, pain during eye movements, mydriasis, problems with accommodation. Because of this clinical signs the patient was during two years four times hospitalized with diagnosis of retrobulbar optic neuritis, put on unsuccessful steroid therapy and suspected of sclerosis multiplex. From 2000 to 2004 this painful syndrom occurred twelve times and gone with or without therapy. The first "attack" took place just before the menarche. We have done pattern VEP three times in active stage and during the remission. VEP were normal with no signs of optic nerve disease or demyelinisation. CT and MRI were done twice during 6 months and revealed no pathology. Neurologist has found no neurological deficits. Finally the diagnosis of ciliar ganglion inflammation was made.

Conclusion The VEP study is fundamental for making a proper diagnosis of optic neuritis before steroid therapy beginning.

■ 2124

Management of pseudotumor cerebri during pregnancy

EL SHEHA H (1), EMARA E (2)
(1) Ophthalmology, Saudi German Hospital, Jeddah
(2) Neurosurgery, Saudi German Hospital, Jeddah

Purpose To emphasize the management of Pseudotumor Cerebri (PTC) during pregnancy and make the physician familiar with the features that may lead to the diagnosis of PTC.

Methods Review of literature and case reports.Modern imaging techniques have facilitated the differential diagnosis of PTC. Various therapeutic options are available to prevent irreversible visual loss. Optic nerve sheath fenestration (ONSF) was performed as a new treatment modality in two pregnant women; presented with bilateral papilledema and severe visual loss due to (PTC).

Results Optic nerve sheath fenesteration was successfully treated PTC during pregnancy and led to rapid resolution of symptoms and visual field defects. Papilledema was totally regressed in 4 weeks.Visual acuity,Contrast sensitivity,Color vision,Pupillary reaction, Visual field testing and Fundus photography are of special importance in follow up. No postoperative complications were detected during the follow up period.

Conclusion Pseudotumor cerebri occurring during pregnancy is not an indication for termination of the pregnancy. Weight loss, acetazolamide, and steroids are not an option in pregnant patients. ONSF is usually well tolerated and should not be delayed, if optic nerve damage is occurring.

EVER-2004-abstractbook.indd 134 8/19/04 12:26:49 PM

2125
Airbag-induced eye injuries using eyewear

MUNOZ MORALES AM, RUIZ LAPUENTE CR
Ophthalmology, Seville

Purpose To acquire better understanding about airbag-induced eye injuries using eyewear and to concern medical community about this problem.

Methods A review of the medical literature using Medline was performed. We acquire information from ´Dirección General de Tráfico´ in Spain. All reports involving ocular injuries secondary to airbags were included in this study. We design a study where the dynamics of ocular trauma induced by a car-crash with airbag using eyeglasses are reproduced.

Results Although a protective effect of glasses is recognised in order to avoid contact with gases and foam from the airbag they significantly increase the risk of an ocular trauma. Injuries caused by airbag using eyeglasses transform the severity of ocular trauma into a high severe degree.They are almost open-eye injuries. In moderate/minor accidents 5 % of the eyes ends in legal blindness. Wearing eyeglasses the percentage reaches the 60%. Risk factors are: women, LASIK, cataract surgery, left eye and myophia. Injuries caused are hyphaema, retinal haemorrhage, detachment ,endothelial cell loss, corneal abrasion, macular scars, etc.

Conclusion Polycarbonate lenses are less likely to shatter than glass lenses. Central thickness must be at least 3 mm. Improvements in safety design in airbags is necessary to prevent ocular trauma. A proposal is made in order to reduce severe trauma related to eyewear.

2126 / 216
Glaucoma and optic nerve drusen

KAWA P, NOWOMIEJSKA K, BIALEK M, HASZCZ D, CZOP DC, MANKOWSKA A, KRUKOWSKI J, ZAGÓRSKI Z
1 st. Eye Hospital & Lublin University School of Medicine, Lublin

Purpose To present 28 patients with optic nerve drusen. Ten of them had glaucoma. We tried to evaluate if there was any correlation between clinical picture of OND and the visual field defects and whether glaucoma made any of the clinical parameters worse in these patients.

Methods Basic clinical examination, Goldmann applanation tonometry, 30-2 threshold visual field – Humphrey perimeter, HRT, Ischihara color testing, pupil reaction , central corneal thickness (CCT) measurement, endothelial cell count in specular microscopy, VER and lab tests were performed in 28 patients with OND.

Results There was an abnormal retinal nerve fiber layer thickness, mean and maximum cup depth in 25 patients (90 %) in HRT. In 25 patients (90 %) patients visual field defects were present. There was no correlation between clinical picture of OND and the visual field defects.

Conclusion The optic nerve drusen cause significant RNFL thickness thinning and visual field defects, which might be due to coexisting glaucoma.

2127 / 217
Doppler Velocities in Retrobulbar Arteries in Normal Pregnancy and Postpartum. A Longitudinal Study

VIGANDER K (1), TAKSERMAN A (2), HAUGEN G (3), KERTY E (4)
(1) Ophthalmology, National Univ. Hospital, Oslo
(2) Cardiology, Aker Univ. Hospital, Oslo
(3) Obstetrics and Gynaecology, National Univ. Hospital, Oslo
(4) Neurology, National Univ. Hospital, Oslo

Purpose To estimate the changes in retrobulbar blood flow throughout pregnancy and postpartum by means of Colour Doppler Velocimetry (CDV) and to evaluate the influence of general hemodynamic changes on ocular blood flow.

Methods Blood flow was measured by means of CDV at five intervals from week 12 to week 36 in normal pregnancy and day two and month six postpartum in the ophthalmic artery (OA), central retinal artery (CRA) and posterior ciliary artery (PCA). Peak systolic (PSV) and end diastolic (EDV) flow velocities were measured and the resistivity index (RI) was calculated. Mean blood pressure (MAP), heart rate (HR) and intraocular pressure (IOP) were measured. ANOVA test, Bonferroni post hoc test and Pearson correlation analyses were performed.

Results Twenty-nine healthy women (mean age: 30.3+3.5 years) were recruited. CRA EDV was lower in the first half of pregnancy ($p<0.001$) and showed a strong increasing trend in the second half of pregnancy ($p<0.001$). PCA PSV decreased in the second half of pregnancy ($p=0.032$). For CRA and PCA the RI was higher in the first half of pregnancy compared to month 6 postpartum ($p<0.001$ in both cases) and showed a strong decreasing trend in the second half of pregnancy ($p<0.001$ in both cases). No significant correlations between the Doppler velocities and IOP, MAP or HR were observed.

Conclusion We found hemodynamic changes in the retrobulbar arteries during pregnancy compared to month 6 post partum. The most marked findings were in the CRA. The decreased vascular resistance could be interpreted as orbital vascular vasodilation. Estrogen may play a role due to the multifold increase throughout pregnancy and the known vasodilatative effects of this hormone.

2128 / 218
Influence of papilloedema on globe shape

MADILL SA, CONNOR S
King's College Hospital, London

Purpose We investigated how globes are deformed by papilloedematous optic discs by studying globe shape in patients with Idiopathic Intracranial Hypertension (IIH).

Methods 5 IIH patients and 10 age-matched normals were studied. 0.6mm section CT scans were reformatted on a workstation to create sagittal and axial sections through the globes of each patient along the respective visual axes. The reformats were magnified and the globe length and width measured for axial reconstructions and globe length and height measured for sagittal reconstructions. A single masked observer took all the measurements.

Results The mean difference between globe length and height in sagittal sections in the IIH patients was 1.9mm (SD=1.0mm) for right eyes and 2mm (SD=0.7mm) for left eyes compared to 0.2mm (SD=1.2mm) for right eyes and 0.1mm (SD=1.2mm) for left eyes in controls. For all 5 IIH patients globe height was greater than length in both eyes. Using a 2-tailed T-test for independent samples this gives a significance of $p=0.005$ for right eyes and $p=0.003$ for left eyes when comparing the length to height differences of eyes of IIH patients to controls. Considering the difference between globe length and width on axial sections, there was no significant difference between IIH patients and controls.

Conclusion There is a highly significant distortion of globes in patients with IIH compared to controls but manifesting only in sagittal sections.

EVER-2004-abstractbook.indd 135 8/19/04 12:26:50 PM

■ 2131

Comparative morphology of the inner retina and optic nerve head in animals used for glaucoma research

MAY CA
Anatomy II, Erlangen

Purpose Various animal models exist to study the development and progression of glaucoma. This overview focuses on the morphological differences of these animals in respect to the retina and optic nerve head which has to be kept in mind when using the different models.

Methods Descriptions of the fine structure of the inner retina and optic nerve head from the literature and from own studies were collected for different species including mouse, rat, dog, pig, monkey, and human.

Results Profound differences exist in the formation of the optic nerve lamina cribrosa (LC): mice do not have a LC, rats show species differences in the formation of a LC, dog, pig, monkey and human have a well developed LC. Differences also exist in the blood supply of the optic nerve head and in the location of the retinal vessels. In the retina, the ganglion cell layer shows also differences regarding the number and type of neurons in the different species examined.

Conclusion The specific morphological peculiarities of the selected species have to be taken into consideration when using animal models to study glaucomatous changes.

■ 2132

Does glial cell malfunction precede ganglion cell death in glaucoma?

OSBORNE NN, CHIDLOW G, WOOD JPM
Nuffield Laboratory of Ophthalmology, Oxford University, Oxford

Purpose Glaucoma is an optic neuropathy characterised by morphological changes in the optic disc and retinal ganglion cell loss. It is a neurodegenerative disease because ganglion cell loss is gradual. The factor(s) that initiate the disease and determine the rate of ganglion cell loss remain(s) unknown. Various theories exist to explain how glaucoma is initiated to induce differential ganglion cell death. One idea is based on the suggestion that the quality of the blood supply is affected in the optic nerve head for any of a number of reasons (vasospasm, insufficient regulation, hypotension, hypertension, haemorrhage) to cause an ischaemic-like insult and this results in glaucoma. Considerable interest has therefore focussed on trying to understand how ischaemic-like insults to the optic nerve head can lead to a differential rate of ganglion cell death with other retinal neurones appearing to be little affected. We have concluded, from published studies on pathological glaucoma eyes and experimental studies, that Müller cells, microglial and astrocytes play an important part in the pathogenesis of glaucoma (British Journal of Ophthalmology 2001, 85 pp1252-1259) and participate in the progressive loss of ganglion cells. Evidence for this view will be presented and the suggestion made that pharmacological agents directed at maintaining retinal glial function as well as protecting against ganglion cell apoptosis is necessary for effective clinical neuroprotection in glaucoma.

■ 2133

Expression of metabotropic glutamate receptors and associated proteins under elevated intraoccular pressure in a mouse model for secondary angle-closure glaucoma

ENZ R (1), MAY CA (2), DYKA FM (1)
(1) Institut für Biochemie, Friedrich-Alexander-Universität, Erlangen-Nürnberg
(2) Anatomisches Institut, Friedrich-Alexander-Universität, Erlangen-Nürnberg

Purpose Glaucoma is a leading cause of blindness, ultimatively resulting in the apoptotic death of retinal ganglion cells. However, molecular mechanisms involved in ganglion cell death are poorly understood. Whereas the involvement of ionotropic glutamate receptors, especially of the NMDA-type, has been extensively studied, virtually nothing is known about the relation between metabotropic glutamate receptors (mGluRs) and retinal degeneration.

Methods We compared the retinal gene expression of mGluRs and mGluR-binding proteins in eyes with normal and elevated intraocular pressure of DBA/2J mice, a model for secondary angle-closure glaucoma.

Results Elevated intraocular pressure in DBA/2J mice significantly increased retinal gene expression of most mGluR types when compared to C57BL/6 control animals, as detected by RT-PCR. In contrast, the mRNA concentration encoding for mGluR-binding proteins was less affected. Specific antibodies for mGluR1a and mGluR5a/b showed increased expression of the proteins in synaptic and ganglion cell layers of the retina. Because ganglion cell death in DBA/2J mice occurs most likely by apoptotic mechanisms, we also studied the gene expression of mGluRs in neurons undergoing apoptosis.

Conclusion Our data support the idea that the specific gene regulation of mGluRs is a part of the glaucoma-like pathological process that develops in the eyes of DBA/2J mice.

■ 2134

Morphological diversity in human glaucomatous optic nerves

LÜTJEN DRECOLL E, MAY CA
Anatomy II, Erlangen

Purpose To investigate the degeneration of the optic nerve in human glaucomatous eyes.

Methods Optic nerves of 25 eyes with POAG and of 19 eyes with PEXG were investigated. Clinical data and axon counts of Epon-embedded semithin sections were used to determine the stage of the disease. Ultrathin sections were performed of selected areas and studied with an electron microscope. Immunofluorescence staining using antibodies against GFAP and N-CAM detected astro- and oligodendroglia.

Results In glaucomatous eyes there are degenerative changes which differ significantly from those described for the white matter in the brain. There was little staining for GFAP in the center of the degenerating nerve fiber bundles indicating nearly no astrocytosis. Instead, fibrosis of the connective tissue septae with loss of capillaries within these septae were found.

Conclusion In the brain, degeneration of the white matter is mainly caused by ischemia and followed by astrocytosis. The fact that the morphology of the optic nerve degeneration in glaucoma differs from that seen in the brain could be explained by the fact that not ischemia alone but other factors are causative for the changes.

EVER-2004-abstractbook.indd 136 8/19/04 12:26:50 PM

■ 2141

Incidence of familial retinoblastoma: the experience of the Italian Referral Center

HADJISTILIANOU T (1), DE FRANCESCO S (1), MARCONCINI S (2), MARTONE G (1), BATISTI C (1), MENICACCI F (1)
(1) Dept of Ophthalmology, Retinoblastoma Referral Center, Siena
(2) Dept of Pediatrics, Siena

Purpose The objective of the current study is to determine the incidence, clinical and pathologic characteristics and outcome of patients with familial retinoblastoma.

Methods A retrospective study was conducted on 353 retinoblastoma patients from our Center (1952-2003).

Results 33 cases who had a family history of retinoblastoma have been identified; there were 22 bilateral and 12 unilateral cases, 24 males and 10 females.Paternal origin was detected in 23 cases and maternal in 11.The age at diagnosis was between 0 and 12 months in 23 cases and between 13 and 29 months in 11 cases.Among the 34 cases, 4 had one of the parents affected by unilateral (1 case) and bilateral (3 cases) retinoma.5 children out of 34 died for a second tumor; all of them had received external radiotherapy and developed the second tumor in the field of irradiation.

Conclusion Familial retinoblastoma represents 10 - 15 % of all cases. A positive family history leads to an early diagnosis but there are still cases diagnosed in delay because of poor information and knowledge of the heredity of the disease. Familial cases, because of the germinal mutation of the RB1, are predisposed to second malignant tumors. Fundus routine examination of the parents is important to detect retinoma usually not diagnosed before. Retinoma and retinoblastoma both carry the same genetic implications.

■ 2142

Malignant lymphoma of the lacrimal sac. An EORTC study.

SJÖ LD (1), AUW-HAEDRICH C (2), DELBOSC B (3), DUCREY N (4), JUHL BR (5), KANTELIP B (3), KEMENY JL (6), KIVELÄ T (7), LUTHERT P (8), MEYER P (9), PRAUSE JU (1), RALFKIAER E (5), SJÖ NC (1), HEEGAARD S (1)
(1) Eye Pathology Institute, Copenhagen
(2) Department of Ophthalmology, Freiburg
(3) Department of Ophthalmology, Besancon
(4) Department of Ophthalmology, Lausanne
(5) Department of Pathology, Copenhagen
(6) Department of Pathology, Clermont-Ferrand
(7) Department of Ophthalmology, Helsinki
(8) Division of Pathology, London
(9) Department of Ophthalmology, Basel

Purpose Malignant lymphoma of the ocular region is predominantly of the small B-cell type. A few single case reports have indicated that lymphoma of the lacrimal sac contains a higher proportion of large cell B-cell lymphoma than encountered elsewhere in the eye region. In order to investigate this pattern we collected specimens from all primary lacrimal sac lymphomas in Europe and classified them according to the WHO lymphoma classification, and correlated the findings with the clinical data.

Methods Ophthalmic pathologist from Europe and Israel were contacted to review their files for lacrimal sac lymphomas. From each case clinical data, a copy of the histo-pathological description, and 20 slides of unstained paraffin sections were collected. The specimens were stained with HE, CD20, CD79a, CD3, CD5, CD23, CD43, CD10, Cyclin D1, BCL-2, BCL-6, MIB1 and MUM1 and classified by two individual experienced haemato-pathologists in accordance with the WHO classification. Clinical data were correlated to the histological types.

Results 16 lacrimal sac lymphomas were collected. Twelve of sixteen lymphomas were classified as diffuse large B-cell lymphoma (DLCL). Other histological types identified were: MALT lymphoma (2), CLL (1) and Mantle cell lymphoma (1). 11 of 16 patients were female and the median age for the whole group was 69 (range 44 to 95). No statistical significant differences concerning clinical parameters were identified.

Conclusion Primary lacrimal sac lymphomas are extremely rare. The majority of primary lacrimal sac lymphomas are diffuse large B-cell lymphomas. This is in opposition to primary lymphomas of the ocular adnexa that most frequently are MALT lymphomas.

■ 2143

Lesions of the lacrimal drainage system. A clinicopathological study of 643 biopsy specimens of the lacrimal drainage system in Denmark 1910-1999.

LINDEGAARD J (1, 2), MARTHIN JK (1), PRAUSE JU (1, 2), HEEGAARD S (1)
(1) Eye Pathology Institute, University of Copenhagen, Copenhagen
(2) Department of Ophthalmology, Rigshopitalet, Copenhagen

Purpose To determine the frequency of histologically verified lesions of the lacrimal drainage system in Denmark between the years 1910 and 1999. Furthermore, to correlate the clinical diagnosis with the pathology diagnosis.

Methods Retrospective review of all pathology reports at the Eye Pathology Institute, University of Copenhagen, from 1910 to 1999 describing a lesion of the lacrimal drainage system. In addition, a retrospective review of all reports describing a lesion of the lacrimal drainage system from the Danish Pathology Database. All specimens were re-evaluated, except cases with a primary diagnosis of dacryocystitis. In these cases a sample of 25 percent was re-evaluated.

Results A total of 643 lesions were collected and dacryocystitis was the most frequent lesion, constituting 508 cases (79%). The remaining part were diagnosed as dacryolithiasis 62 (7.9%), tumour 29 (4.5%), trauma 19 (3.0%), congenital malformation 9 (1.4%), canaliculitis 8 (1.2%) and granulomatous inflammation 8 (1.2%). Seventeen tumours were malignant, of which B-cell lymphoma was the most common (6 cases). In 0.6% of cases with a clinical diagnosis of dacryocystitis/lithiasis a non-suspected malignant tumour was diagnosed. Microorganisms were uncommon in dacryocystitis (9%) but frequent in cases with dacryolithiasis (87%).

Conclusion Dacryocystitis is by far the most frequent lesion of the lacrimal drainage system referred for histopathological evaluation. Dacryolithiasis is often associated with microorganisms, especially Gram positive rods. Tumours of the lacrimal sac are rare, and most often suspected prior to the histopathological evaluation.

■ 2144

Is Proton radiotherapy an alternative to radical surgery in the management of extended conjunctival melanoma?

ANASTASSIOU G (1), MELLER D (1), SCHUELER AO (1), WUESTEMEYER H (1), SAUERWEIN W (2), CHAUVEL P (3), STEUHL P (1), BORNFELD N (1)
(1) Ophthalmology University of Essen, Essen
(2) Radiation Therapy University of Essen, Essen
(3) Centre Antoine Lacassagne, Nice

Purpose Primary conjunctival melanomas may be diffuse and involve several parts of the conjunctiva. Diffuse patterns of conjunctival melanomas can be hardly managed by eye salvaging methods and often exenteration is indicated. The purpose of this study was to evaluate the usefulness of proton radiotherapy in these complex cases.

Methods Twenty patients with conjunctival melanoma were treated between 1992 - 2002 with proton beam irradiation. All cases were not assessable for brachytherapy with a plaque. Sixteen cases were recurrences after various pre-treatments. 31Gy were applied in 6 fractions to a target volume including all areas of the conjunctiva with risk of microscopic disease. "High risk" areas were treated with an additional boost of 2 fractions up to 45Gy.

Results The mean follow-up time is 3.2 years. Recurrent disease occurred in 6 cases (30%); 2 of them outside the radiation field, 3 within the field treated with 31Gy, and a single one in the boost-field of 45Gy. An exenteration followed only in two patients (10%). Visual acuity remained within one line of change in 12 cases (66.6%); in 14 patients the visual acuity was 0.25 or better. A sicca syndrome developed in 19/20 patients. However, only 8/20 patients use artificial tears more than 5x/d. A focal cataract developed in 7 patients (35%). Metastatic disease occurred in 6 patients (30%) and so far 4 (20%) of them died. There was no association between the occurrence of local recurrence and the development of metastases.

Conclusion For cases of complicated and diffuse conjunctival melanomas proton beam irradiation offers an alternative to exenteration.

EVER-2004-abstractbook.indd 137 8/19/04 12:26:51 PM

2145
Exfoliative cytology in conjunctival melanoma

KEIJSER S (1), LUIJK VAN CM (1), MISSOTTEN GS (1), VESELIC-CHARVAT M (2), WOLFF-ROUENDAAL DE D (1), KEIZER DE RJW (1)
(1) Ophthalmology, Leiden
(2) Pathology, Leiden

Purpose For the ophthalmologist conjunctival pigmented lesions are often difficult to classify clinically. Exfoliative cytology can be helpful, but good reliable data are lacking. We performed a large-scale study for exfoliative cytology from pigmented conjunctival lesions.

Methods All records with an exfoliative cytology performed in patients with a pigmented conjunctival lesion between 1975 and 2003 at the Leiden University Medical Center were studied. Of 182 patients, 294 exfoliations were screened for a histologically confirmed conjunctival melanoma within six months after exfoliative cytology. Exfoliations were classified into the following categories: grade 0: insufficient material for diagnosis, grade 1: normal conjunctival cells with or without melanin pigment, reactive conjunctival cells as seen in inflammation, grade 2: melanocytes with mild atypia, grade 3: melanocytes with moderate atypia, and grade 4: melanocytes with severe atypia.

Results 71.8% of the patients with a grade 4 atypia had a histologically confirmed conjunctival melanoma. The sensitivity, specificity, positive predictive value, and negative predictive value of exfoliative cytology were 84.7%, 78.4%, 58.7%, and 93.4%, respectively.

Conclusion Exfoliative cytology is a fast, easy, noninvasive, and reliable technique to consider or exclude a conjunctival melanoma in patients with a pigmented conjunctival lesion. Cytology can also be a helpful tool in the therapeutical management of pigmented lesions.

2146 / 201
Human papillomavirus - cause of epithelial lacrimal sac neoplasia?

SJO NC (1), BUCHWALD C (2), FLAMANT P (3), HEEGAARD S (1), LINDEBERG H (4), NORRILD B (5), PRALISE JU (1), ORTH G (3)
(1) Eye Pathology Institute, Copenhagen
(2) ENT department, Copenhagen
(3) Papillomaviruses Unit, Paris
(4) Oral Pathology Laboratory, Aarhus
(5) Protein Laboratory, Copenhagen

Purpose Tumours of the lacrimal sac are rare but important entities that may carry a grave prognosis. The purpose of the study was to investigate papillomas and carcinomas of the lacrimal sac for the presence of human papillomavirus (HPV)

Methods Five lacrimal sac papillomas and six lacrimal sac carcinomas (four transitional cell carcinomas and two squamous cell carcinomas) were investigated for presence of HPV with polymerase chain reaction (PCR) technique, DNA in situ hybridisation (ISH) and mRNA ISH. HPV positive specimens were investigated by PCR with type specific probes for HPV types 6/11, 16 and 18. Furthermore, ten specimens of dacryocystitis were included in the PCR reactions as control of HPV prevalence in inflamed, vulnarable lacrimal sac mucosa.

Results HPV was present in five of five lacrimal sac papillomas and in four of six lacrimal sac carcinomas. All transitional cell carcinomas were HPV positive, whereas the squamous cell carcinomas were HPV negative.The analysis with type specific probes identified HPV type 6/11 in the papillomas and both HPV types 6/11 and 16 in the lacrimal sac carcinomas. All specimens of dacryocystitis were HPV negative. DNA ISH and mRNA ISH was positive in three specimens; two papillomas and one transitional cell carcinoma.

Conclusion We demonstrated human papillomavirus in all lacrimal sac papillomas suitable for PCR analysis and in four of six carcinomas of the lacrimal sac using PCR technique. Thus our investigation found a strong association between HPV and lacrimal sac papillomas and –carcinomas.

2147 / 202
Erdheim-Chester disease: severe orbital involvement treated by Vinblastin associated to Interferon

TONINI M (1), SARROT-REYNAUD F F (2), BERNAL DESCOUR F (1), MOUILLON M (1), ROMANET JP (1)
(1) Ophthalmology, Grenoble
(2) Internal medecine, Grenoble

Purpose To describe a patient with Erdheim-Chester disease and to outline treatment. Erdheim-Chester disease is a xanthogranulomatos disease which can involved orbital, bone, neural, pulmonary and cardiac tissues.

Methods Case report:We report a case of a 62-year-old female with hypophyse, bone, and orbital involvement. She experienced a severe proptosis, with elevated intraocular pressure and optic nerve compression. Several treatments were used and their efficacy were assessed.

Results Systemic steroids were used first, and resulted in an incomplete recovery of the orbital findings and a lot of side effects. So steroids were discontinued and replaced by Vinblastin associated to Interferon. After a 10 month follow up, the patient had no more proptosis, bone and hypophyse involvement remained stable. No side effect occured.

Conclusion Vinblastin associated with interferon is an effective therapeutic modality in patients with severe or steroid-resistant Erdheim-Chester disease.

2148 / 203
Pilomatrixoma: A Reminder (Clinical &Histopathological Similarity to Basal Cell Carcinoma)

TAHHAN M (1), BENSKIN S (2), ASHWIN P (3), KASMIYA M (3)
(1) Sandwell and West Birmingham Hospitals, West Browmich
(2) Sandwell Hospital, West Browmich
(3) Dudley Gest Hospital, Dudley

Purpose Pilomatrixoma is a relatively benign skin neoplasm. Eyelid pilomatrixoma derived from hair follicles are rare and frequently misdiagnosed as basal cell carcinoma. Three cases of Pilomatrixoma have been studied for the similarity with Basal cell carcinoma and how can we avoid that and what is the best surgery for it.

Methods three cases of pilomatrixaoma been studied for the clinical presentaion and histological apperance similaraty with BCC.what is the best histopathology methods can be used.

Results Eyelid pilomatrixomafrequently misdiagnosed as basal cell carcinoma,if evaluation is based on clinical evidence alone due to the tumour presenting as a hard nodule with possible erosion through the skin. Histologically, especially in partial biopsies they can be confused with basal cell carcinoma.

Conclusion The pilomatrixoma may be safely excised with a narrow margin of clearance. Whereas a macroscopic clearance of 3 to 5 mm or surgery with frozen section histological control is desirable for excision of basal-cell carcinoma. Therefore in suspicious cases, wide excision can be avoided if the diagnosis of pilomatrixoma is confirmed on incisional biopsy.

EVER-2004-abstractbook.indd 138 8/19/04 12:26:51 PM

■ **2149 / 204**

Orbital involvement in multifocal fibrosclerosis

HEEGAARD S (1), KYHN M (1), HERNING M (2), PRAUSE JU (1)
(1) Eye Pathology Institute, University of Copenhagen, Copenhagen
(2) Danish Research Centre for Magnetic Resonance, University Hospital Hvidovre, Hvidovre

Purpose To present the clinical and histopathological findings in a patient with sclerosing, idiopathic orbital inflammation and retroperitoneal fibrosis.

Methods A 40-year-old Caucasian woman presented with diplopia, swelling and erythema of her right eye region. An orbital CT scan showed thickening of the lateral rectus muscle and of the lacrimal gland. During the following 6 months the patient developed right flank- and abdominal pain. Abdominal CT images revealed a retroperitoneal tumor shredding the aorta and the ureteres. An explorative laparatomy disclosed retroperitoneal tumour masses and a biopsy was performed. Systemic treatment with prednisolone was initiated, resulting in regression of symptoms. When prednisolone was discontinued the orbital symptoms recurred and a lateral orbitotomy was performed.

Results Histopathological examination of the tissue from the orbit and the retroperitoneum demonstrated the same morphology with masses of dense, hyalinised fibrous tissue. Areas with moderate, diffuse lymphocyte and plasma cell infiltration were seen. A heterogeneous lymphocytic cell population was identified.

Conclusion We present a case of multifocal fibrosclerosis with similar histopathological morphology of the two involved regions. Aetiology and treatment of the disease is discussed.

EVER-2004-abstractbook.indd 139 8/19/04 12:26:52 PM

■ 2151

The Opto-kinetic test and funduscopy as a primary screen for vision in the mouse

HART A, MCKIE L, MORGAN J, THALING C, CROSS SH, JACKSON IJ
MRC Human Genetics Unit, Comparative and Developmental Genetics, Edinburgh

Purpose Retinal degeneration, denoted rd1, has been observed in the C3H mouse strain for many years. Here we show data from 3 new mouse lines denoted atypical retinal degeneration 1, 2 and 3 (atrd1, 2 and 3). The aim of this study was to validate the optokinetic response (OKR) test using mutant animals that present with retinal degeneration and to better characterise the timing of photoreceptor loss in atrd mice compared with rd1 mice.

Methods The visual tracking drum is a motorized drum that rotates. Its inner walls can be lined with different cards on which are vertical stripes of known frequency. Mice are placed on a stationary platform in the centre of the drum and filmed from above while the drum is stationary or moving.

Results OKR testing did not identify any C3H mouse showing positive head movement. In contrast congenic sighted C3H mice (the wild type Pde6b gene bred into the C3H background), showed positive response at all ages. Slower onset homozygote atrd1-3 mice at 3-4 wk presented with near normal fundus although visual acuity was impaired; atrd3 did not respond in the drum. As the mice aged, retinal degeneration became more noticeable and was accompanied by further reduction in visual acuity. This was also observed in atrd1-3/rd1 mice; increasing age accompanied by extensive retinal degeneration and reduced visual acuity. By 10 wk all mice failed to score a positive OKR test.

Conclusion The OKR test can be used to measure visual acuity in a mouse with slower onset retinal degeneration. However, there is still a level of variability in the results requiring further study. These data validate earlier work that shows the OKR test can distinguish between mice that have vision and those that are blind. Physical examination of the fundus of atrd1, 2 and 3 mice reveals a slower, progressive degeneration of the retina with time compared with C3H mice. The combination of these tests provides a good primary screen for eye phenotypes in the mouse. The atrd mice may prove useful in the study of therapies for retinal degeneration.

■ 2152

Intraocular pressure measurements in mice

REITSAMER H

Purpose The Tonopen® is a commercially available hand help applanation tonometer for human use. However, Moore and co-workers proved its validity in a rat model of ocular hypertension (Invest Ophthalmol Vis Sci. 1993;34(2):363-9) providing the impetus for this study to standardize a method of non-invasive measurement of intraocular pressure (IOP) in mice. Two studies were performed: In the cannulated-eye study IOP was measured simultaneously with a Tonopen® and by direct cannulation of the vitreous compartment while pressure was manipulated in steps between 10 and 45 mmHg by a saline reservoir via a second vitreal cannula (five mice, one rat). In a second study Tonopen and servo-null measurements were performed in independent groups (48 mice) to verify Tonopen measurements in non-cannulated-eyes. Topical brimonidine (0.15%) was used to decrease IOP. In the rat, there was a similar relationship between Tonopen readings and direct measurements via cannulation of the eye as previously reported. Although readings from mice eyes were higher in variability than those obtained from the rat, the measurements were reproducible and the correlation between the invasive and the non-invasive methods was good ($r = 0.97$). The IOP lowering effect of brimonidine was detected with Tonopen as well as servo-null measurements ($p < 0.001$) and the results with both techniques were similar. The Tonopen can be used for rapid and reproducible measurements of IOP in mice. The method can provide a useful means for IOP measurement in mouse models of induced ocular hypertension, in knock-out and transgenic mice, or in pharmacological studies.

■ 2153

The ERG (Electroretinogram) is a suitable test for retinal function in mice

DALKE C, GEKELER F, ZRENNER E, GRAW J

Purpose Aim of the study was the development of a quick screening method for a reliable functional assessment of the mouse retina.

Methods The dark-adapted mice (6 to 11 weeks old) were anaesthetized (Ketamin/Xylazin) and the pupils were dilated with atropine before the ERG examination. The mouse is fixed on a special sled (High Throughput Mouse ERG setup, Steinbeis Transfer Centre for Biomedical Optics and Function Testing, Tuebingen, Germany) while it is exposed to a Ganzfeld flash stimulus (Espion Color Burst, Diagnosis LLC, Littleton, MA). The scotopic ERG response is recorded at the cornea with gold wires as active electrodes. A reference electrode is placed between the eyes and a subcutaneous needle in the tail served as a reference electrode.For screening purposes, two luminance intensities (500 and 12,500 cd/m_) were chosen:- 500 cd/m_ induces nearly no a-wave, but a well discernable b-wave amplitude mainly stemming from the rod system is induced;- 12,500 cd/m_ induces an a-wave and a maximally developed b-wave response (coming presumably from rods and cones).Routinely, we record 20 - 25 mice in 4 hours for such ERG protocolls.Healthy wild-type mice have b-wave amplitudes of 100-300 µV; for screening purposes of individual mice from mutagenesis screens, we set a cut-off level for the b-wave at 50 µV. Moreover, we use this method also to decide whether heterozygous or homozygous mice from particular mutant lines have retinal function different from their wild-type littermates (consistent significantly different a- and b- wave amplitudes or latencies).

Conclusion The ERG is a quick, robust and reproducible in-vivo test of retinal function.

■ 2154

Light scattering measurements in mouse lenses

WEGENER A
Department of Ophthalmology, Rheinische Friedrich-Wilhelms-Universität, Bonn

Purpose A variety of mouse mutants has become available with different genetic changes affecting the transparency of the cornea and lens. In order to evaluate the penetration and stability of expression of such mutations optical densitometry according to the Scheimpflug principle has been performed on the eyes of selected mutant anumals.

Methods Scheimpflug photography in vertical and horizontal slit position has been performed under standardized conditions after mydriasis induction with atropin 1% on both eyes of each animal. The optical sections obtained were analysed by linear densitometry in multiple scans parallel to the optical axis of the eye.

Results Densitometric data evidenced characteristic light scattering patterns in distinct layers of the lenses which characterized not only the development of distinct typs of cataracts but more importantly changes in light scattering in precataractous stages. The lens density data also allowed to distinguish between heterozygous and homozygous animals of the same mutant strain.

Conclusion Light scattering measurement based on the Scheimpflug principle provided a precise characterization of precataractous changes in light scattering and of a specific cataract type. The density profile of the lenses proved to be a suitable marker for stability and penetration of a mutation affecting the transparency of the anterior eye segment.

EVER-2004-abstractbook.indd 140 8/19/04 12:26:52 PM

2155

Screening Mice for Vision: Slit lamp and open questions

GRAW J (1), LÖSTER J (2), FAVOR J (3)
(1) Institute of Developmental Genetics, GSF, Neuherberg
(2) Institutte of Developmental Genetics, GSF, Neuherberg
(3) Institute of Human Genetics, GSF, Neuherberg

Purpose Aim of the study is the development of a test battery to pick up mice with ocular defects for detailed characterization.

Methods Pupil reflex is transiently stopped by a drop of atropin (1%). Mice are examined biomicroscopically with the aid of a slit lamp. Small-eye mice are identified by ocular inspection. Mode of inheritance is characterized by classical genetic breeding.

Results Screening for mouse mutants suffering from cataracts and microphthalmia is performed at the GSF-Research Center at Neuherberg since 1979 (Kratochvilova and Ehling, Mutat. Res. 63, 1979, 221-223) and more than 200 mutant lines have been established. Slit-lamp screening is fast (100 mice per 4 hours), and the opacities at the cornea or the lens can be well documented.Severe microphthalmia can be detected by visual inspection of the mice; however, there is no method established to quantify the eye size in the living mouse. Therefore, the actual test batteries lack milder phenotypes (which might be of more clinical relevance). Moreover, a quantitative method for measurement of the eye size would allow also detecting larger eye balls (buphthalmos) and could dissect genetically quantitative trait loci (QTL).

Conclusion Slit-lamp analysis is a fast and robust method to detect lens and cornea opacities in the mouse, however, a quantitative method for the determination of the eye size in the living mouse is lacking.

EVER-2004-abstractbook.indd 141 8/19/04 12:26:52 PM

■ 2161

Evidence for the Participation of Inflammation and Immune-mediated Pathways in the Etiology of Age-related Macular Degeneration

HAGEMAN G
Department of Ophthalmology and Visual Sciences, University of Iowa Center for Macular Degeneration, Iowa City

Purpose The molecular pathogenesis of AMD is poorly understood, but there is a widespread view that it is a complex disorder which is attributable to the convergence of multiple genetic and acquired risk factors.The cellular and molecular events leading to the clinical development of age-related macular degeneration (AMD), are poorly understood. A new paradigm is emerging that may help to explain the etiology of AMD. There is evidence that implicate a major role for local inflammatory and/or immune-mediated processes at the level of the RPE-choroid interface in the development of drusen and the pathobiology of AMD. Our studies have also lead to the observation that dendritic cells, potent antigen-presenting cells, are intimately associated with drusen development and that complement activation is a key pathway active both within drusen and along the RPE-choroid interface. Moreover, we generated evidence that these pathways may be directly or indirectly related to other diseases, including Alzheimer's disease and atherosclerosis.In the severest form of AMD, choroidal neovascular membranes breach the macular Bruch's membrane and gain access to the sub-RPE and subretinal spaces. The biological pathways associated with the predilection of the macula toward atrophic and exudative degeneration have not been elucidated. Recent morphometrical analyses revealed a statistically significantly difference in the integrity ($p<0.00001$) and thickness ($p<0.00001$) of the elastic lamina between the macula and extramacular regions. Importantly, donors with a clinical history of AMD have a significantly lower mean integrity in the macula, as compared to that of age-matched donors without AMD ($p=0.0015$). These same studies have documented a significant association between the amount of macular sub-RPE-associated basal lamina deposit and AMD development ($p<0.00001$). These structural and compositional differences may help to explain why the macula is more susceptible to degenerative changes in AMD. A working model of AMD pathobiology that encompasses these findings has been advanced. Although clearly a paradigm shift in our understanding of the biological processes involved in AMD, the downstream consequences of active, immune-mediated pathways may induce significant damage to macular cells and tissues, and thereby contribute to choroidal neovascularization and severe vision loss.

■ 2162

The Eyetech Anti-VEGF Study

DEUTMAN A F (1), HOYNG C B (1), MEULENDIJKS C F M (1), SCHLINGEMANN R O (2)
(1) Department of Ophthalmology, UMC St Radboud, Nijmegen
(2) Department of Ophthalmology, AMC, Amsterdam

Purpose Vascular endothelial growth factor (VEGF) is a growth factor that probably plays an important role in the development of angiogenesis and vascular leakage in CNV. Macugen is a pegylated anti-VEGF aptamer, which selectively binds to VEGF, and therefore inhibiting the effect of VEGF on the bloodvessels. The purpose of this study was to assess the safety and efficacy of Macugen, a selective vascular endothelial growth factor-165 antagonist in the treatment of neovascular age-related macular degeneration (AMD).

Methods Two pivotal phase II/III multi center, randomized, double-masked trials in patients with occult, classic and mixed type CNV were performed. Wide vision and entry criteria were established. Intravitreal Macugen (0.3, 1.0, or 3 mg) or sham injection was given every 6 weeks for 54 weeks. The proportion of patients losing < 15 letters of visual acuity by week 54 was the primary efficacy endpoint.

Results After 12 months, the patients in the three treatment groups had significant less visual acuity loss than sham patients. The 0.3 mg dose was the lowest effective dose. A larger proportion of patients treated with 0.3 mg Macugen compared with sham lost less than 3 lines of vision (70% versus 55%; $p<0.05$). Macugen was beneficial for all lesion subtypes in analyses of the 0.3 mg and sham groups. Macugen was well-tolerated at all three doses, and most adverse events were mild to moderate in severity and were attributed to the injection procedure rather than to study drug.

Conclusion With wide entry criteria for vision and lesion size, Macugen appears to be an effective treatment for all subtypes of AMD, with a favorable safety profile. Inhibition of CNV by anti-VEGF is a new therapeutic option in development.

■ 2163

Lucentis in the Treatment of AMD

LEYS A
University Hospital St. Rafael, Leuven

Purpose Vascular endothelial growth factor (VEGF) is a glycoprotein that plays a critical role in the signalling pathways that stimulate new blood vessel growth (angiogenesis). Choroidal neovascularization (CNV) in age-related macular degeneration (AMD) is characterized by rapid growth of new blood vessels under the retina, with accompanying leakage. VEGF has been observed at elevated levels in patients with AMD, suggesting that blocking the VEGF pathway could diminish the stimulus for neovascular growth. Lucentis™ (rhuFab V2, ranibizumab, Genentech Inc.) is a recombinant humanized therapeutic antibody fragment that binds VEGF with high affinity, and inhibits angiogenesis. Lucentis™ may have potential in the treatment of AMD because it penetrates all retinal layers and hence may act on all relevant sites of VEGF production in the eye to inhibit angiogenesis and leakage in AMD. The aim of current trials is to explore the safety, tolerability and efficacy of intravitreal Lucentis™ when administered monthly to patients with AMD with CNV. In a phase I/II study, patients (n=29) received one of three dose-escalation regimens. The regimens comprised doses in the 300 µg to 2000 µg range, and these doses were administered intravitreally as frequently as every 2 weeks for 5 months. At month 5, vision improved by at least 3 lines in 44% of patients and was stable or improved in 93% of patients. In a phase I/II study, patients received either 300 µg (n=25), 500 µg (n=28), or "usual care" (n=11) every 4 weeks for 6 months. Vision improved by at least 3 lines in 42% of patients receiving Lucentis™ and was stable or improved in 98% of those patients at month 6. Vision decreased by at least 3 lines in 2% of treated patients. The most frequent adverse event was mild, reversible inflammation. Three serious adverse events were reported; a case of recurrent iridocyclitis that resolved, a case of endophthalmitis that was successfully treated, and a case of central retinal vein occlusion in which visual acuity returned to the baseline level. Multiple injection regimens of Lucentis™ were well tolerated for up to 6 months and associated with stable or improved visual acuity. Phase III trials are currently under way.

■ 2164

Anecortave Acetate in the Treatment of AMD

DE SMET MD (1), VERBRAAK FD (1), MICHAUD JE (2)
(1) Dept of Ophthalmology, University of Amsterdam, Amsterdam
(2) Alcon Labs and The Anecortave Acetate Clinical Study Group, Ft Worth

Purpose Anecortave Acetate is an angiostatic cortisene administered as a posterior juxtascleral depot every six months. In a 24 month clinical trial, Anecortave Acetate 15 mg was superior to placebo treatment for stabilizing vision and suppressing choroidal neovascularization (CNV) growth. No clinically relevant safety issues have been seen so far. Only dietary supplementation with antioxidants and zinc has thus far shown some success, in patients with dry AMD who are at a high risk of significant vision loss from exudative AMD and choroidal neovascularization (CNV). Anecortave Acetate is being evaluated for arresting progression of dry AMD to exudative AMD in these at-risk patients.

Methods 100 research sites worldwide will enroll 2500 patients in two Phase III studies with identical protocols. Eligibility criteria include past or current exudative AMD in the fellow eye. The study eye must have multiple intermediate/large soft and/or confluent drusen, hyperpigmentation, and no evidence of exudative AMD or geographic atrophy. Patients will be randomized equally to receive juxtascleral Anecortave Acetate (15 or 30 mg) or a sham procedure every 6 months for 4 years. Primary efficacy will be the development of "sight-threatening" CNV, defined as classic/occult CNV or subretinal hemorrhage within 2500 microns of the foveal center

Results Patients are presently being enrolled in this study.

Conclusion The angiostatic cortisene Anecortave Acetate has shown effects in stabilizing vision and suppressing CNV growth. Its mechanism of action, safety profile, and dosing interval suggest that it may be a good candidate for reducing the risk of CNV and vision loss in eyes with "at risk" dry AMD.

EVER-2004-abstractbook.indd 142 8/19/04 12:26:53 PM

2165
Photodynamic Therapy (PDT) in AMD. New Aspects

SOUBRANE G
Hopital Intercommunal de Créteil, Créteil

Purpose Photodynamic therapy (PDT) with verteporfin (Visudyne®, Novartis Pharma AG, Basel, Switzerland) remains the only approved pharmacological treatment for eyes with choroidal neovascularization (CNV) secondary to age-related macular degeneration (AMD) and other causes. Recently published data discussing the effect of lesion size on treatment benefit of PDT show that baseline lesion size in minimally classic and occult with no classic lesions is an important predictor of the magnitude of treatment benefit, and should be a critical factor in the treatment decision (Am J Ophthalmol 2003;136:407–418). Further, 2-year results from the Verteporfin In Minimally classic (VIM) Trial (n=117) have suggested that PDT with verteporfin using either reduced light fluence (25 J/cm2 at 300 mW/cm2) or standard light fluence (50 J/cm2 at 600 mW/cm2) safely reduces the risk of visual acuity loss in eyes with minimally classic lesions no larger than 6 MPS disc areas. No statistical difference was observed between the two light fluence treatment groups. PDT with verteporfin was also shown to reduce the risk of progression to predominantly classic CNV in this study. Therefore, the VIM Study Group recommends standard light fluence application for PDT with verteporfin in the treatment of eyes with subfoveal minimally classic CNV. Based on all previous results, PDT with verteporfin is recommended for the treatment of all choroidal neovascular lesion types (predominantly classic, minimally classic and occult with no classic CNV) secondary to AMD. Approval has been granted for treatment of all lesion types in several countries. Results from the Verteporfin Early Retreatment (VER) Trial, to determine whether early treatment intervals (every 6 weeks during the first 6 months) improve treatment outcomes in eyes with predominantly classic CNV due to AMD, did not show a significant treatment benefit compared with standard treatment intervals (every 3 months). Application of verteporfin treatments at 3-monthly intervals remains the standard of care.The management of CNV due to AMD is a fast-moving field. There has been recent interest in the use of adjunctive treatments to PDT (for example intravitreal triamcinolone acetonide, anti-angiogenesis therapies, feeder vessel laser photocoagulation) to further enhance treatment outcomes. Further randomized clinical trials are warranted to determine the potential benefit of these adjunctive approaches. It is expected that PDT with verteporfin combined with other treatments will continue to evolve over the next few years to potentially improve vision outcomes for patients.

2166
Macular Translocation in AMD

CORCOSTEGUI B

Purpose Age related Macular Degeneration (AMD) is the most frequent cause of Choroidal Neovascular Membranes (CNV).We analize the results of limited retinal translocation with scleral imbrication on 39 eyes of 39 patients with a minimum follow-up of 2 years. All patients were unable to read a 12 point Arial letter 33cm away. The average preoperative visual acuity was 20/160. Bilateral CNV in 31 patients (79.5%). The average age was 73.3 between 52-89 years old.Surgical procedure includes suture placement, three-port pars plana vitrectomy and hyaloid separation. Remove of CNV througout previous retinotomy. Subretinal infusion of BSS with a 40 gauge cannula, creating a temporal retinal detachment. Fluid/Air exchange and posterior shift of the retinal detachment. Scleral unfolding and tied the preplaced sutures. Retinal mechanical movilizations inferiorly using a silicone tip cannula and fluid/air exchange. Post-operatory positioning to achive retinal shift with spontaneous reattachment. Reading capability was achieved in 23% in the first year decrasing to the 20.5% at 18 months. Mean of displacement was 1910 micras. Recurrences of CNV appears in 31% of the cases, retinal detachment in 4 and macular fold in 21.

2167
Acute Human Trial for Retina Implant Technology. Results of a Multicenter Study

RICHARD G (1), FEUCHT M (1), LAUBE T (2), BORNFELD N (2), WALTER P (3), VELIKAY-PAREL M (4), HORNIG R (5)
(1) Universitäts-Augenklinik Hamburg-Eppendorf, Hamburg
(2) Universitäts-Augenklinik Essen, Essen
(3) Universitäts-Augenklinik Aachen, Aachen
(4) Universitätsklinik für Augenheilkunde und Optometrie, Vienna
(5) IIP-Technologies GmbH, Bonn

Purpose To explore the visual perceptions evoked by acute electrical stimulation of the human retina with regard to the development of a chronic epiretinal implant.

Methods A multicenter study with 20 subjects suffering from retinitis pigmentosa has been initiated considering strict inclusion and exclusion criteria. 15 subjects with visual acuities from 1/50 to no light perception and a mean age of 54 years underwent acute stimulation until abstract submission. Stimulation procedure is done during a pars plana vitrectomy with a maximum duration of 30 minutes. For stimulation a microcontact film with IrOx-electrodes connected by cable to a current generator is positioned epiretinally in the macular area. After repeated stimulation, the microcontact film is removed. Standardized interviews are performed 15 and 90 minutes after operation.

Results 14 of 15 subjects reported pleasant and not flashy perceptions of coloured objects ranging in size from a head of a match to a football as seen from a distance of one meter. Perceptual brightness was described as clearly visible, comparable to the light of a candle. Even a patient who has been blind since 25 years experienced relevant and reproducible percepts. Threshold charges needed to generate visual perceptions proved to be different between individual patients. Except for retinal detachment in one patient (reattached), no other side effects were observed during the 3-month follow-up.

Conclusion Acute electrical stimulation of the human retina using microcontact films may create useful visual perceptions even in totally blind patients. It can be performed without damaging the macula. Results are encouraging with regard to the implantation of a chronic epiretinal implant.

EVER-2004-abstractbook.indd 143 8/19/04 12:26:54 PM

2211
Classification and Nomenclature

DUA HS
Division of Ophthalmology and Visual Sciences, University of Nottingham, Nottingham

Purpose The term dry eye is too simplistic and does not reflect the pathology, clinical features or prognosis of the condition. It is a symptom as well as a diagnosis. Our purpose was to rationalise the nomenclature and classification of Dry eye disease.

Methods Review of the literature and report of the Delphi panel on dry eye, meeting held at Baltimore, USA in April 2003 (chairman Dr. Peter J McDonnell MD).

Results The term Dysfunctional tear syndrome (DTS) was felt to be more accurate and proposed as an alternative to 'Dry eye.' The current classifications are varied and the divisions within them often overlapping. The NIH classification into 'evaporative' and 'Tear deficient' was proposed over 10 years age and does not take into account any underlying inflammatory pathology. Etiological classification systems are extensive, elaborate and cumbersome for routine clinical usage. A more rational classification system is proposed: 1. DTS without associated lid margin disease 2. DTS with associated lid margin disease and 3. DTS with disturbance of distribution of tears. To guide treatment, it is imperative to further divide DTS within each class, in to levels of severity. Severity levels are determined primarily on the symptoms and clinical features. Each symptom and clinical feature is scored and four levels of severity determined. Treatment can be progressively tailored to match severity.

Conclusion The new proposed nomenclature 'Dysfunctional Tear Syndrome' takes into account the diversity in etiology and presentation within 'Dry eye disease' and the classification incorporates all recent knowledge on the disease. Together they present a practical, clinical approach to documentation, diagnosis and treatment of the condition.

2212
Clinical Pathology of dry eye

GOMES J
Federal University of Sao Paulo, Sao Paolo

Purpose The maintenance of a stable tear film involves complex hormonal, neuronal and immune regulatory mechanisms. In this presentation, the author will detail each of these mechanims and will correlate them with dry eye syndrome.

Results Sex hormones, particularly the androgens, seem to modulate important functions of the lacrimal and meibomius glands. Parasympathetic, sympathetic, and sensory innervation play important roles on the hydrodynamic as well as compositional components of the lacrimal function. Chronic dryness of the ocular surface results in inflammatory reactions and gradual destruction of the lacrimal glands and conjunctival epithelium, which affects the stability of the tear film establishing a vicious cycle with the damage on the ocular surface. In immunologic diseases such as Sjögren, a chronic inflammatory process destroys the lacrimal gland initiating the dry eye process.

Conclusion Dry eye has multifactorial causes that involves changes in regulatory mechanisms, such as hormonal, neuronal and immunemediated.

2213
Dry Eye tests: How useful are they?

NIRANKARI VS (1, 2)
(1) Cornea Service, Eye Consultants of Maryland, Owings Mills, Maryland
(2) Deptartment of Ophthalmology, University of Maryland, Baltimore, Maryland

Purpose To assess commonly used clinical tests to diagnose and follow patients with dry eye disease

Methods Tests used include:1. Careful assessment of patients history including symptoms of foreign body sensation, blurred vision, photophobia, itching and redness2. Break up time using fluorescein dye3. Evaluation of tear film meniscus4. Schirmer tests both with and without anesthesia5. Corneal and conjunctival staining using fluorescein dye, lissamine green and rose bengal6. Evaluation of lid margin disease7. Completion of the ocular surface disease index (OSDI) to track progression or improvement of dry eye symptoms8. History of autoimmune disease, previous surgery i.e. LASIK or corneal transplants

Results All the clinical tests, used in combination with patient's symptomatology, can provide a useful indicator of the severity of the disease and response to treatment

Conclusion A better understanding of the signs and symptoms of dry eye disease, in addition to clinical testing and the OSDI can help better assess the severity at the time of initial diagnosis and the response to treatment

2214
Treatment Options in Dry Eyes

PFLUGFELDER SC
Cullen Eye Institute, Baylor College of Medicine, Houston, TX

Purpose to review the treatment options for dry eye

Methods Evidenced based review of literature

Results A multi-pronged strategy should be used to treat dry eye. Aqueous tear deficiency and elevated tear film osmolarity can be treated with punctal occlusion, artificial tears, secretogouges and cyclosporine. The ocular surface inflammation associated with dry eye can be treated with cyclosporine, steroids, oral tetracycline and nutritional supplements containing essential fatty acids. Accelerated apoptosis in the ocular surface epithelia can be treated with cyclosporine. Dry eye associated corneal ulceration can be treated with oral tetracycline and systemic TNF-alph antagonists.

Conclusion Effective treatment of dry eye requires aqueous enhancement, suppression of inflammation and inhibition of accelerated apoptosis.

EVER-2004-abstractbook.indd 144 8/19/04 12:26:54 PM

■ 2221

Tadpole pupil during bimedial recession correction of esotropia

WEIR RE (1, 2), ZAIDI FH (3), GREAVES BG (4), BREMNER F (5)
(1) Institute of Ophthalmology, London
(2) William Harvey Hospital & Kent and Canterbury Hospital, Ashford Kent
(3) Ophthalmology Dept. Imperial College, London
(4) William Harvey & Kent and Canterbury Hospitals, Ashford Kent
(5) The National Neurology and Neurosurgery Centre, Queens Square London

Purpose Irritational peri-operative left medial segmental pupil dilation occuring during bimedial rectus recession correction of esotropia.

Methods The case of a two and half year old child with segmental irritational pupil dilation noted during bimedial recession for moderate esotropia is presented with photographic documentation. This case is presented alongside a comprehensive review of published literature on other non strabismus surgery related causes of tadpole pupils. The anatomical and neurophysiological mechanisms of irritational tadpole pupils are summarised.

Results The segmental pupil dilation was noticed after completion of a single medial rectus recession of esotropia. The pupil was seen before closure of the conjunctiva without the use of topical local anaesthesia perioperatively. Surgery was uncomplicated without obvious bruising of the eye either peri or postoperatively. The pupil dilation had returned to normal at review three hours later. The child made an uneventful recovery from the anaesthetic acheiving excellent strabismus correction. Comprehensive systemic examinations of the child have remained normal throughout.

Conclusion Esotropia surgery related pupil dilation is not documented in the literature although clinical anecdotal reports were recalled by the consultant squint specialist. This case resolved spontaneously and a neurophthalmic analysis is presented together with a comprehensive literature review of other tadpole pupils.

■ 2222

Pupil constriction to red vs. achromatic light permits differentiation of macula-on from macula-off retinal detachments using pupillometry

ZAIDI FH (1, 2), WEIR RE (3, 4), MOSELEY MJ (1)
(1) Visual Neuroscience, Imperial College London, London
(2) Ophthalmology, St Marys and The Western Eye Hospital, London
(3) Visual Science, Institute of Ophthalmology, UCL, London
(4) Vitreoretinal Surgery, Moorfields Eye Hospital, London

Purpose To assess whether macula status in retinal detachment can be differentiated using red versus achromatic light stimuli.

Methods Non-randomised trial involving dynamic binocular infrared pupillometry of 24 eyes with unilateral retinal detachments and healthy fellow eyes. Topography of retinal detachment was macula-on (n=5) and macula-off (n=7). Full-field achromatic stimuli (22 x 14 deg) were presented to each eye alternately at 7 intensities within a range of 1-2 log cd.m-2 for 1100 ms, and repeated with red light.

Results Inter-eye comparison of pupil constriction amplitude with macula-on status showed reduction with achromatic stimuli but not with long wavelength light of an equal stimulus intensity ($p<0.05$). However macula-off status was associated with significant reduction in pupillary constriction to both achromatic and red light.

Conclusion Inter-eye comparison of pupillary responses to red versus achromatic stimuli can be used to differentiate macula status in retinal detachment. The distinct changes are suggested to be due to L-cone dysfunction. This suggests potential for clinical application of dynamic pupillometry to diagnosis of significant macula pathology in cases of ocular media opacities as an adjunct to ocular ultrasound e.g. vitreous haemorrhage, cataract - the pupil light reflex continues to function in these situations and is even augmented by cataract.

■ 2223

Selective ETB1 stimulation relaxes the iris sphincter muscle

ROCHA DE SOUSA A (1, 2), SARAIVA J (1), FALCÃO-REIS F (3), LEITE-MOREIRA AF (1)
(1) Physiology Faculty of Medicine, University of Porto, Porto
(2) Ophthalmology, S João Hospital, Porto
(3) Ophthalmology, S João Hospital, Faculty of Medicine, University of Porto, Porto

Purpose Endothelin–1 (ET-1) effects are mediated by two different receptors (ETA and ETB). The later include ETB1 (endothelial) and ETB2 (muscular) subtypes. ETB1 stimulation promotes NO release and Pg production. The present study investigated, in rabbit iris sphincter muscles, the effects of selective ETB stimulation.

Methods Rabbit iris sphincter muscles (n=46) were dissected and attached to a force transducer, on a vertical organ bath containing a modified Krebs-Ringer solution (1.8 mM Ca2+; 35ºC).The effects of ETB stimulation by Sarafotoxin (SRTX; 2*10e-7 M) were studied alone (n=10) or in presence of: (i) a selective ETA receptor antagonist, (BQ-123; 10e-5 M ; n=7); (ii) a selective ETB2 antagonist, (BQ 788; 10e-5 M; n=7); (iii) a NOS inhibitor (LNA; 10e-4 M; n=7) (iv) and a COX inhibitor (Indomethacin; 10e-5 M; n=7). Finally the effects of a selective ETB1 agonist (IRL-1620 10e-6 M; n=8) were evaluated. All effects were recorded and analysed after an isometric contraction elicited by Carbachol (10e-4 M). Only significant results (mean±SE, $p<0.05$) are given, expressed as % changes from control.

Results When compared to control, SRTX promoted a 4,8±1,6% decrease in isometric tension, 2' 30" after its addition to the bathing solution, an effect that disappeared at 10'. This effect was not affected by BQ-788 (tension decreased 4.0±1.7%), BQ-123 (4.3±0.8%) or L-NA (5.6±1.5%), but was slightly but not significantly attenuated by INDO (3.5±0.9%); yet it was increased by selective ETB1 stimulation with IRL-1620 (tension decreased 6.9±1.6%).

Conclusion ETB stimulation relaxes the iris sphincter muscle, an effect that seems to be mediated by the ETB1 subtype.

■ 2224

Achromatic Contrast Sensitivity in Parkinson's Disease

FARIA P (1), SILVA M (1), CASTELO-BRANCO M (1, 2), JANUARIO G (3), MASSANO J (3), REGATEIRO F (3), JANUARIO C (4), FREIRE A (4)
(1) IBILI, Center of Ophtalmology, Universidade de Coimbra, Coimbra
(2) Departament of Biophysics, Faculdade de Medicina, Coimbra, Portugal
(3) Departament of Biophysics, Faculdade de Medicina, Coimbra
(4) Departament of neurology, HUC, Coimbra

Purpose Testing the retinal magnocellular M-y system in Parkinson Disease (PD) patients. Deficits both on a wide range of visual psyhcophysical and electrophysiological tests have been documented in PD. Dopamine is found in the retina, in the cortex and may play a role in subcortical circuits important for vision.

Methods All the patients (n=18) and controls (n=15) underwent an ophthalmological and neurological examination. The magnocellular pathway was tested by means of a custom-made frequency doubling (FD) technique. This method uses low spatial frequency sinusoidal grating achromatic targets that flicker rapidely in counterphase at a high temporal rate, so that contrast detection (CD) thresholds are measured across the visual field.

Results CD thresholds were significantly higher in the PD group, especially for the temporal inferior quadrant (Mann-Whitney, $p = 0.0024$). A global index per eye was obtained for the perifery and the foveal region and it was also significantly different between the two groups even when splitted across eyes ($p < 0.03$ for the fovea and $p < 0.015$ for the periphery).

Conclusion The poor performance of the PD patients indicates the existence of an important involvement of the retinal magnocellular pathway in Parkinson's diease.

EVER-2004-abstractbook.indd 145 8/19/04 12:26:55 PM

■ 2225 / 219

Pupillometry reveals increased inter-eye pupil escape ratio in the eye with a subretinal membrane

ZAIDI FH (1, 2), MOSELEY MJ (1)
(1) Visual Neuroscience, Imperial College London, London
(2) Ophthalmology, St Marys and The Western Eye Hospital, London

Purpose To ascertain if macula dysfunction in subretinal neovascular membranes (SRNs) is associated with the phenomenon of pupil escape by comparing healthy eyes with those with SRNs.

Methods Non-randomised trial of dynamic binocular infrared pupillometry of 24 eyes with unilateral SRNs and healthy fellow eyes. Full-field achromatic stimuli (22 x 14 deg) were presented to each eye alternately at 7 intensities within a range of 1-2 log cd.m-2 for 5 s. Recordings were undertaken after 20 minutes of dark adaptation. Aetiology of SRN was age-related macular degeneration (n=9), inflammatory (n=2) and infective (n=1).

Results Inter-eye comparison of pupillary responses showed that eyes with subretinal membranes have a statistically greater reduction in sustained contraction as a proportion of the phasic component ($p<0.05$).

Conclusion Inter-eye comparison of pupil escape ratio differentiates normal eyes from those with significant retinal pathology in the form of subretinal membranes. This observation is consistent with reports of pupil escape in patients with central field loss (Bergamin O, Kardon RH. Ophthalmology 2002;109:771-80). Changes in the pupil waveform suggest potential for clinical application of dynamic pupillometry to diagnosis of significant macula pathology and investigation of retinal function in cases of ocular media opacities. Unlike most other investigations the pupil light reflex continues to function in this situation, and is often enhanced.

■ 2226 / 220

Eye velocities during static fixation in patients with central scotoma

MACEDO AF (1), GOMES AOS (2), NASCIMENTO SMC (1)
(1) Department of Physics, University of Minho, Braga
(2) Department of Electrical Engineering and Computers, Faculty of Engineering, University of Porto, Porto

Purpose The aim of this work was to study eye velocities during static fixation in patients with central visual field defects.

Methods Eye-position data were recorded from 10 patients and 10 controls with a modified infra-red xy-gaze-tracking device using the pupil and corneal reflection (iView, SensoMotoric Instruments GmbH; sampling rate 60 Hz; angular resolution 0.2 deg). The patients had visual acuity in the range 0.7-1.0 Log MAR. The task consisted in fixating a static white cross of 2.5° against a black background during 60 sec. Data were analyzed offline and such that outliers, blinks and saccadic movements were removed. Mean eye velocities were then computed for the period of fixation.

Results It was found that the mean eye velocity was significantly higher for patients.

Conclusion During static fixation patients with central field defects have faster eye movements than controls, suggesting that central visual field defects may impair slow control of eye movements.

■ 2227 / 377

Clinical pathways in glaucoma elaborated by a new pupillographic test (patent pending)

KANDEL GL (1), KABACK M (2), SANCHEZ R (2)
(1) Bioinstco Lab Troy, New York
(2) Glaucoma Consultants Slingerlands, New York

Purpose To identify the clinical pathways disclosed by pupillary reflex perturbations examined with a new test of optic nerve function. (See ISOPT 2004).

Methods This test administers a fixed set of stimuli to each eye, and concurrently records the pupillary responses evoked by them with a binocular recording device. The stimuli produced by LEDs generate red, yellow, green or blue lights at two photopic levels to a central or a fixed peripheral visual location. The resulting direct and consensual reflexes for each eye are separately recorded. Using the differences in reflex amplitudes as indicators of optic nerve asymmetry, unique patterns of afferent optic neuropathy are postulated for several groups having the same clinical diagnosis. The patterns of a limited standardization group were studied by Discriminant Analysis.

Results The test correctly classified 90 % of the patient's eyes according to their prior categories of glaucoma, glaucoma suspect, family history of open angle glaucoma, retinal pathology or normal examination. The clinical pathways to glaucoma, consisting of a family history of open angle glaucoma, of glaucoma suspect associated with elevated intra ocular pressure and steroid sensitivity, and pseudo exfoliation, were identified.

Conclusion The test results, even with this small sample of patients seems unaffected by concurrent cataracts, surgical retraction of the iris during cataract extraction, or to iridectomy, and to the ocular co-morbidities of ARMD, diabetic retinopathy, central retinal vein occlusion, retinal tears, central serous retinopathy or to mild stroke affecting the brainstem or the parietal lobe. The test's high sensitivity and specificity make it a serious contender as a screening instrument for glaucoma and when suitably calibrated, as a means of assessing glaucoma progression.

EVER-2004-abstractbook.indd 146 8/19/04 12:26:55 PM

■ 2231

Age-related Changes of the Rodent Optic Nerve

MAY CA
Dept. of Anatomy II, FAU, Erlangen

Purpose Animal models are important tools to enhance the understanding of diseases like glaucoma, a chronic age-related disease, where tissue samples of different stages are often impossible to obtain. To estimate the influence of age in this pathological process, the phenomenon of age-related alterations has to be investigated in the animal models, too.

Methods The eyes of adult (2 months old) and senescent (20-26 months old) mice and rats were immunohistochemically stained with antibodies against collagen I, III, IV, VI, laminin, GFAP, connexin 43. In addition, semi thin and ultrathin sections were performed.

Results While the interstitial collagens type I and VI showed a clear increase in the old vs. the young animals, the basal membrane components appeared less affected. Most pronounced changes of the glial cells occured in their gap-junction formation. The cytosceletal marker GFAP showed no difference between old vs. young.

Conclusion Age-related changes in the rodent optic nerve region correlate with changes described in other species and differ substantially from changes described in glaucoma.

■ 2232

Visually-Evoked Hemodynamical Response and Neurovascular Coupling in the Human Optic Nerve

RIVA CE (1, 2), LOGEAN E (1), FALSINI B (3)
(1) Institut de Recherche en Ophthalmologie, Sion
(2) Faculty of Medicine, Lausanne
(3) Istituto di Oftalmologia, Università Cattolica S. Cuore, Rome

Purpose The optic nerve represent a highly valuable tissue for studies of the intrinsic physiological mechanism postulated more than 100 years ago by Roy and Sherrington, by which neural activity is coupled to blood flow and metabolism. This paper explores the changes in hemodynamics and oxygenation in the optic nerve in response to increased neural activity induced by visual stimulation, as well as the mechanisms underlying these changes. The characteristics of the flicker-induced hemodynamical response, the effect on this response of varying the stimulus parameters (such as modulation depth, frequency, luminance, color ratio, area of stimulation, site of measurement and others) as well as the data on activity-induced intrinsic reflectance and oxygenation signals all lead to the undeniable conclusion that visual stimulation is a powerful modulator of optic nerve blood flow and that a tight neurovascular coupling is present in this tissue. We will review studies aimed at identifying potential mediators and modulators of the hyperemic response, the conditions susceptible to alter it and key questions that remain to be answered to improve our understanding of the neurovascular coupling and its role in the in the diagnosis and management of ocular diseases.

■ 2233

Protecting the optic nerve from injury

OSBORNE NN, WOOD JPM, CHIDLOW G
Nuffield Laboratory of Ophthalmology, Oxford University, Oxford

Purpose Experimental studies have yielded a wealth of information related to the mechanism of ganglion cell death following injury either to the mylinated ganglion cell axon or to the ganglion cell body. No suitable animal models exist where injury can be directed to the optic nerve head region, particularly the unmylinated ganglion cell axons. Thus the process of relating the data from the various animal models to the many different types of optic neuropathies in man must be cautious. Extensive studies on the isolated optic nerve have nevertheless yielded valuable information on the way white matter is affected by ischaemia and how certain types of compounds can attenuate the process. As a consequence, the molecular mechanisms involved in ganglion cell death in animals are fairly well understood and different pharmacological agents have been shown to blunt the process in animal studies when delivered before or shortly after the insult. Whether this information can be applied for use in patients remains a matter of debate, and major obstacles need to be overcome before the laboratory studies may be applied clinically. This information will be briefly reviewed with the view that a neuroprotectve strategy may be applied to treat optic neuropathies like glaucoma in the future.

■ 2234

Aquaporin water channels in optic nerve astrocytes: A role in homeostasis

PATIL R
Dept. of Ophthalmology & Visual Sciences, University of Nebraska Medical Center, Nebraska, Omaha

Purpose Aquaporins (AQPs) are membrane protein water channels, and eleven related AQPs have been identified in mammals. Aquaporins are involved in water transport in many fluid-transporting tissues. Recent studies indicate a key role of aquaporins in astrocyte swelling and brain edema and suggest that AQP inhibition may be a new therapeutic way for reducing cerebral water accumulation. Primary open-angle glaucoma (POAG), a common form of optic neuropathy, is characterized by irreversible and progressive loss of axons from the retinal ganglion cells and optice nerve, usually in response to abnormally elevated intraocular pressure (IOP). Although the mechanism of axonal loss is unknown, the mechanical stress due to increased IOP might initiate the axonal damage, based on the hypothesis that these cells are sensitive to mechanical stress. Our preliminary studies indicate that hypoxia regulates expression of AQP4 in the cultures of optice nerve head astrocytes. Therefore, we hypothesize that astrocytes may respond to stress due to elevated intraocular pressure in glaucoma by regulating water flux that leads to the maintaince of the astrocyte cell volume. The relationship between the expression of aquaporins and cell volume regulation will be discussed. These studies are important for the retinal ganglion physiology and may provide new insights into the molecular mechanisms of water handling in the optic nerve astrocytes.

EVER-2004-abstractbook.indd 147 8/19/04 12:26:56 PM

2241
Malignant uveal versus conjunctival melanoma: which is worse?

KUJALA E, TUOMAALA S, ESKELIN S, KIVELÄ T
University of Helsinki, Department of Ophthalmology, Helsinki

Purpose To compare frequency of dissemination and overall survival of patients with uveal and conjunctival melanoma.

Methods Survival status of 240 consecutive patients with a choroidal and ciliary body melanoma diagnosed in the district of Helsinki University Central Hospital in 1967-1981, and of 85 patients with conjunctival melanoma diagnosed in Finland from 1967-2000, was audited. The latter data were additionally compared with 91 patients with disseminated uveal melanoma diagnosed in 1985-2000. Time to first metastasis was compared with cumulative incidence analysis, and overall survival with Kaplan-Meier analysis.

Results The median time from diagnosis of primary tumor to diagnosis of metastasis was 4.3 years (range, 0.2-27.2) for uveal and 2.3 years (range, 0.5-15.8) for conjunctival melanoma (P=0.13). This interval was 2.3 years for those with regional and 3.4 for those with systemic metastases (range 0.5-15.8 and 1.2-9.8, respectively, P=0.46) from conjunctival melanoma. The 10-year cumulative incidence of metastasis was 34% (95% CI 28-40) for patients with uveal melanoma and 29% (18-41) for patients with conjunctival melanoma (P=0.35). The median time from metastasis to death was identical, 8 (range 0-38) and 8 (range 2-33) months for patients with intial systemic metastasis from uveal and conjunctival melanoma, respectively. Median time to death was significantly longer, 30 months (range 2-42; P=0.012), after initial lymph node metastasis.

Conclusion Cumulative incidence of metastasis after uveal and conjunctival melanoma does not differ. Survival after systemic metastases from these two malignancies is also comparable. Survival after lymph node metastases is longer, but these metastases also occur somewhat earlier, indicating lead time bias.

2242
A review of metastatic uveal melanoma

DESJARDINS L (1), LUMBROSO L (1), LEVY C (1), PIPERNO-NELIMAN S (2), DORVAL T (2), DENDALE R (3), SALMON R (4), MARIANI P (4), SASTRE X (5), ASSELAIN B (6), PLANCHER C (6)
(1) Ophtalmology, Institut Curie, Paris
(2) Oncology, Institut Curie, Paris
(3) Radiotherapy, Institut Curie, Paris
(4) Surgery, Institut Curie, Paris
(5) Pathology, Institut Curie, Paris
(6) Biostatistics, Institut Curie, Paris

Purpose We have performed a retrospective study on the incidence ,managment and survival of metastatic uveal melanoma.

Methods Information concerning patients with uveal melanoma were registered in Curie institute since 1983The registered data includes initial findings, treatments used and follow up data. Patients were treated by enucleation, proton beam radiation or brachyterapy with cobalt and iodine plaques. Follow up was continued for ten years or more with ultrasonography of the liver every 6 months during ten years and once a year thereafter.

Results 2938 patients were treated in Curie institute for uveal melanoma between may 1983 and december 2003. 91,4% of patients had conservative managment with radiotherapy (63,5% with proton beam)2176 patients are alive (73,%) and 113 are lost to follow up (3,8 %). The median follow up is 65 months. 511 patients (17,4 %) presented metastatic disease with a median delay of 14 months after initial treatment. 82,3% of metastasis were in the liver only; median survival after diagnosis of metastasis was 9 months. The treatments used for metastatic disease were registered for 231 patients and will be described. monosomy 3 was studied for 47 enucleated patients during the past 3 years: The presence of monosomy 3 seems to be a significant risk factor for metastasis (p 0,13)

Conclusion The median survival of metastatic uveal melanoma remains low despite efforts for early detection. More active treatments have to be found and adjuvant therapy should be explored.

2243
Survival of patients with choroidal melanoma: correlation with histopathological features and monosomy 3

SANDINHA MT (1), FARQUHARSON M (2), MCKAY I (3), ROBERTS F (2)
(1) University Department of Ophthalmology, Glasgow
(2) University Department of Pathology, Glasgow
(3) University Department of Microbiology, Glasgow

Purpose To correlate survival in choroidal melanomas with monosomy 3 and various histopathological parameters and to assess whether monosomy 3 is related to time to death from tumour histology.

Methods Eighty-six cases of archival choroidal melanomas were retrieved from the pathology department; 47 patients had died from metastatic melanoma and 39 were alive or had died from other causes after a minimum period of 1 year (mean 17.3 years, range 1 to 30 years). The presence or absence of monosomy 3 was assessed by chromosome in situ hybridization. The following histopathological parameters were assessed: tumour size, cell type, intrascleral and extraocular spread, mitotic activity, presence of vascular loops and necrosis.

Results Monosomy 3 was detected in 35 of the 47 cases of metastasizing melanoma; all 39 non-metastasizing tumours were balanced for chromosome 3. Monosomy 3, tumour size> 15mm, the presence of epithelioid cells and large areas of necrosis were all significantly associated with metastases-related death ($p<0.0001$, $p<0.001$, $p<0.0001$, $p=0.026$ respectively). The combination of epithelioid cells, vascular loops and absence of balloon cells were statistically significant predictors of monosomy($p<0.0001$). There was no significant difference in time to death for tumours with monosomy 3 compared with those balanced for chromosome 3 in patients with metastasizing melanoma ($p=0.65$) but survival of patients with tumours displaying monosomy 3 was generally short.

Conclusion Monosomy 3 is a significant predictor of death from metastatic melanoma but not of time to death. In this study, large tumour size, presence of epithelioid cells, and large areas of necrosis correlated with death from metastatic melanoma.

2244
Cytogenetics of uveal melanoma

DAMATO B (1), CAMPBELL I (2), HOWARD P (3)
(1) Royal Liverpool University Hospital, Liverpool
(2) IC Statistical Services, Wirral
(3) Department of Cytogenetics, Womens Hospital, Liverpool

Purpose The aims of the present study were to determine the rates of chromosome 3 and 8 abnormalities, and to correlate these with survival.

Methods Fluorescence in situ hybridization of uveal melanomas for abnormalities in chromosomes 3 and 8.

Results In 232 patients, the tumour diameter had a median of 15.0 mm and a median height of 8.4 mm. Cytogenetics showed no monosomy 3 and no polysomy 8 in 95 (40.6%), polysomy 8 in 23 (9.8%), monosomy 3 in 55 (23.3%) and monosomy 3 and polysomy 8 in 61 (26.1%). Tumours with both monosomy 3 and polysomy 8 were more common with older age ($\chi2$ test, $p=0.019$), ciliary body involvement ($\chi2$ test, $p<0.0001$), large basal tumour diameter ($\chi2$ test, $p<0.0001$), epithelioid cellularity ($\chi2$ test, $p<0.0001$), closed connective tissue loops ($\chi2$ test, $p<0.0001$) and increased mitotic rate ($\chi2$ test, $p=0.004$). After a median follow-up of 1.97 years, no patients with only polysomy 8 died of metastatic disease, as compared with one patient with no monosomy 3 or polysomy 8, one patient with monosomy 3, and nine patients whose tumour showed both chromosome 3 and chromosome 8 abnormalities (Actuarial 4-year mortality, 40%) (Log Rank Analysis, $p=0.0006$).

Conclusion Cytogenetics have enabled us to inform patients of a good survival prognosis, targeting specialised oncological care to those with high-grade tumours. We now treat small tumours more aggressively, because some have lethal chromosomal changes. In future, cytogenetics on fine needle aspiration biopsies may profoundly influence management, with some patients receiving only palliative ocular treatment and others considered for systemic adjuvant therapy

EVER-2004-abstractbook.indd 148 8/19/04 12:26:56 PM

■ 2245

S100B, S100 dimers and melanoma-inhibitory activity in uveal melanoma screening

MISSOTTEN GS (1), KEUNEN JEE (1), BONFRER JGM (2), JAGER MJ (3)
(1) Ophthalmology, Leiden University Medical Center, Leiden
(2) The Netherlands Cancer Institute, Amsterdam
(3) Dept Ophthalmology, Leiden University Medical Center, Leiden

Purpose To determine whether S100, its dimers or MIA were present in the serum of patient with a large uveal melanoma, and whether their concentrations were related to any clinical and histopathological parameters or to survival in these patients. We furthermore studied whether S100 or MIA may be a better indicator of micrometastases than liver function tests.

Methods S100B, S100A1B, S100BB and MIA concentration were measured in sera from 107 patients with uveal melanoma obtained prior to enucleation from 40 uveal melanoma patients with metastases, and in sera from 50 controls. S100B Liaison, an Immunoluminometric assay and S100B, S100A1B, S100BB and MIA ELISAs were used to quantify S100 and MIA concentrations in serum. Results were compared with liver function tests (AP, LDH, ASAT, ALAT, and GGT).

Results S100B, S100 dimers and MIA were not significantly increased in sera from uveal melanoma patients at the moment of enucleation and were not related to clinical or histopathological parameters. There was, however, a significant difference between S100 and MIA in uveal melanoma patients with metastases compared to controls and patients without metastases. Both S100 and MIA showed a correlation with the presence of metastatic disease than liver function tests.

Conclusion In our study on uveal melanoma patients, S100B and MIA serum concentrations were not correlated with any tested tumour parameter and were not of prognostic value themselves, in contrast with findings in cutaneous melanoma. S100B and MIA were more sensitive thatn LDH and AP in identifying the presence of melanoma metastases. A prospective study is needed to evaluate S100B and MIA in identifying early micro-metastases in uveal melanoma

■ 2246

Phase I/II study of frequent and prolonged immunization with NA17 and differentiation peptides in HLA-A2 patients with metastatic uveal melanoma : preliminary results

PIPERNO-NEUMANN S (1), DORVAL T (1), LANTZ O (2), DESJARDINS L (3), SALMON R (4), POUILLART P (1), BRICHARD V (5)
(1) Medical Oncology, Institut Curie, Paris
(2) Immunology, Institut Curie, Paris
(3) Ophtalmology, Institut Curie, Paris
(4) Surgery, Institut Curie, Paris
(5) GSKbio, Rixensart

Purpose To define safety and document tumor response with a multipeptide vaccine in 44 metastatic uveal melanoma patients in a prospective phase I/II trial promoted by Institut Curie from sept 1999 to dec 2003

Methods 44 HLA-A2 metastatic patients underwent hepatic biopsy to confirm by RT-PCR the expression of NA 17 antigen on melanoma cells.On each injection day,they received SC and ID 300 µg of NA17 nonamer and decamer combined with differentiation antigens Tyrosinase and Melan-A. Treatment schedule included a first cycle of 9 injections in 13 weeks.Additional cycles of 6 bi-weekly injections were given to pts showing a tumor response or stable disease for a total period of 2 years.According to the study protocol,the first 6 pts were evaluated for toxicity:no major toxicity was recorded,so the study accrual continued.

Results No grade III-IV toxicity was observed in 44 pts.Mild and transient local reactions were frequently reported.To date,30 pts are evaluable for tumor response,with a median follow-up of 1 year.We observed 2 clinical tumor responses and 7 stabilizations(8 to 23+months) Immunomonitoring is ongoing in stable and responder pts using the tetramer and Elispot methods on PBMC collected by cytapheresis before and after cycle 1.Updated clinical and immunological data will be presented.

Conclusion Peptide-based immunization against NA17,Tyrosinase and Melan-A was well-tolerated and showed clinical benefit in 9/44 pts.We just start a prospective trial combining peptides and CpG oligonucleotide adjuvant to enhance the immune and clinical responses to the vaccine in metastatic uveal melanoma patients.

■ 2247 / 205

Effects of Glivec®/STI571 in human uveal melanoma cell

MOURIAUX F (1, 2), LEFEVRE G (2), CALIPEL A (2), GLOTIN AL (2), MASCARELLI F (2)
(1) Service d'Ophtalmologie, Caen
(2) INSERM U598, Institut Biomédical des Cordeliers, Paris

Purpose c-Kit is expressed in 75% of primary choroidal melanomas. The pharmacological compound Glivec® inhibits the tyrosine kinase activity of c-Kit activation. We investigated the potential therapeutic role of Glivec®, in controlling uveal melanoma cell tumorigenesis.

Methods Six Melanoma cell lines were used in this study. Cells were treated with various concentrations of Glivec®, and cell proliferation was analyzed by the MTT method. The efficiency of Glivec® to affect the ability of cells to proliferate under anchorage-independent conditions and to form colonies in soft agar was also tested. Apoptotic cell death was analyzed with the annexin-V-EGFP and PI double-staining method. The percentages of apoptotic (annexin V-positive) and necrotic (IP-positive) cells were determined by flow cytometry.

Results Glivec® reduced cell proliferation in a concentration-dependent manner, but with various efficiencies. The efficiency of Glivec® depended on c-Kit levels in the uveal melanoma cell lines. SP6.5, Mel270, TP31 and 92.1 were the most sensitive to Glivec® treatment. Flow cytometry analysis showed that Mel270 underwent massive apoptosis after 48 hours of treatment, with cell death rates increasing by a factor of nine. Conversely, treatment with Glivec® did not induce cell death in the c-Kit-negative melanoma cell line, OCM-1. Glivec® greatly reduced the number of colonies of the c-Kit-positive melanoma cell line, Mel270, in methylcellulose whereas it had only a minor effect on the c-Kit-negative melanoma cell line, OCM-1.

Conclusion We provide the first evidence that Glivec®/STI571 could be used to treat uveal melanoma cell in vitro.

■ 2248 / 206

A tale of two diagnoses : A case of ocular and intracranial tumors

MISSOTTEN GS (1), LAAN LA (2), DE WOLFF-ROUENDAAL D (1), DE KEIZER RJW (1)
(1) Dept Ophthalmology, Leiden University Medical Center, Leiden
(2) Dept Neurology, Leiden University Medical Center, Leiden

Purpose To present a patient with multiple congenital ocular surface tumours, cerebral calcifications and hypertrophic cerebral blood vessels. The report demonstrates the diagnostic difficulties in neurocutaneous syndromes.

Methods Case report

Results A one month old girl was presented at Leiden University with a conjunctival and subconjunctival mass in the right eye. Additionally, there were two dermoid-like corneal tumours. Further ocular examination showed no retinal or orbital anomalies. Paediatric examination revealed an idiopathic dismatury. No cutaneous lesions or ear appendages were found. The ocular masses were excised and sent for pathological examination. Histology showed a dermoid-like lesion, suggestive for neurofibroma. Staining was positive for CD34 and almost entirely negative for S100. Lack of S100 is uncommon for neurofibromatosis. The CD34 positivity is more characteristic for an angiofibromatous lesion. A tentative diagnosis of dermoid tumour with neurofibromatous characteristics' was made. Afterwards the child had a normal psychomotor development. At the age of three, the child developed convulsions. No indications for intracranial neurofibromatosis were found. Two months later a vascular anomaly typical for Sturge-Weber was found by a repeated CT scan. No ocular glaucoma, facial angioma, or other Sturge-Weber sign was found.

Conclusion The patient was diagnosed with an intracranial Sturge-Weber syndrome concomitant with congenital ocular neurofibromatosis/angiofibromateous tumours. To our knowledge this is the first report of this association. Histological differentiation of clinical neurocutaneous syndromes remains difficult. Repeated imaging may reveal unexpected associated conditions.

EVER-2004-abstractbook.indd 149 8/19/04 12:26:57 PM

■ 2251

Revival of inactivated enzymes from the human cataract lens

HARDING JJ (1), RACHDAN D (1), LOU MF (2)
(1) Nuffield Laboratory of Ophthalmology, Oxford
(2) Veterinary and Biomedical Science, Lincoln

Purpose Glyceraldehyde 3-phosphate dehydrogenase activity from human lens homogenates is lowered in cataract. As the glyceraldehyde 3-phosphate dehydrogenase of human cataracts may have been partly inactivated by disulphide formation we attempted to revive some activity by use of the different reducing systems.

Methods Glyceraldehyde 3-phosphate dehydrogenase from human cataract homogenates was incubated with and without a variety of reducing agents for 20 minutes before activity was assayed spectrophotometrically.

Results Glyceraldehyde 3-phosphate dehydrogenase from human cataract homogenates was re-activated by incubation with glutathione, dithiothreitol and captopril, all thiol compounds, showing that part of the inactivation of this important enzyme was by disulphide formation. Disulphide bond formation is a non-specific posttranslational modification of proteins, which leads to a loss of function of the affected protein. When an enzyme is targeted, this harmful effect can be easily detected by monitoring the change of activity.

Conclusion In this study, endogenous as well as synthetic reducing systems were shown to reduce the disulphide bonds formed in glyceraldehyde 3-phosphate dehydrogenase, an important glycolytic enzyme previously reported to have lost its activity in human cataract lenses resulting in reviving the activity of this enzyme. Endogenous reducing systems are responsible for breaking these bonds and returning the protein (enzyme) to its natural state, when these mechanisms fail to do so, the loss of enzyme activity will be permanent.

■ 2252

The superoxide radical: relevance to photochemical and glucose induced cataractogenesis

BEHNDIG A, ÅSTRÖM E
Department of Clinical Science/Ophthalmology, Umeå University, Umeå

Purpose To summarize our studies on in vitro photochemical and glucose-induced cataract formation in lenses from mice lacking the cytosolic copper-zinc superoxide dismutase (SOD1) or the inducible nitric oxide synthetase (iNOS).

Methods Lenses from wild-type mice, CuZn-SOD null mice or iNOS null mice were studied in various organ culture models with exposure to visible light, elevated glucose or elevated nitric oxide (NO) contents. Quantification of cataract formation and/or tissue damage involved digital image analysis, masked ocular staging, lactate dehydrogenase leakage, 86Rubidium uptake, and water contents determination. Determinations of the formation of superoxide radicals (lucigenin-derived chemiluminescence) and the formation of stable nitric oxide reaction products will be presented, along with some immunohistochemical staining for SOD1 and Nitric oxide synthetases performed on the murine lens.

Results Generally, SOD1 null lenses exposed to light or high glucose develop more cataract and more signs of tissue damage, than controls. Nitric oxide synthetase inhibition appears to protect against the damage induced by glucose. Preliminary results on NO formation and exposure, and its possible roles in this aspect will be presented.

Conclusion Our findings so far suggest a role for the superoxide and nitric oxide radicals in the formation of both photochemical and glucose-induced cataract. SOD1 may have a protective function in the complex biochemical mechanisms underlying these types of cataract formation. Possible biochemical mechanisms will be discussed.

■ 2253

Role of ubiquitin in lens protein quality control: degradation versus repair

SHANG F (1), GUO W (1), MARQUES C (1, 2), TAYLOR A (1)
(1) Human Nutritin Research Center, Boston
(2) Center of Ophthalmonlogy, Coimbra

Purpose The objective of this work is to define the role the ubiquitin-proteasome pathway (UPP) in selective removal or repair of damaged protein proteins

Methods Len epithelial cells were treated with H2O2 and levels of oxidatively modified proteins in the cells were monitored in the presence or absence of proteasome inhibitors. To study the role of the UPP in protein repair, heat-denatured luciferease was used as a model substrate and the UPP was reconstituted.

Results Exposure of lens epithelial cells to physiologically relevant levels of H2O2 resulted in an increase in levels of protein carbonyl, a marker of oxidized proteins. The carbonyl-containing proteins disappeared rapidly upon removal of H2O2. However, if the proteasome activity was inhibited, carbonyl-containing proteins accumulated in the cells. Furthermore, carbonyl-containing proteins isolated from H2O2-treated cells were ubiquitinated and isolated ubiquitin conjugates were enriched with oxidized proteins. In addition, we demonstrated that denatured proteins were preferentially ubiquitinated and that the UPP has a chaperone activity. The ubiquitinating machinery recognizes denatured proteins and brings them to the 19S regulatory complex of the 26S proteasome, where they are renatured. Inhibition of the intrinsic isopeptidase of the 19S complex abolished the chaperone activity, indicating that deubiquitination is required for the refolding of denatured proteins.

Conclusion These data demonstrate that the UPP is an important protein quality control machinery in the lens, which selectively recognizes proteins with abnormal conformations and targets them for refolding or for degradation. Dysfunction of this protein quality control mechanism may related to cataract formation.

■ 2254

Oxidative damage and intercellular communication

PEREIRA P, FERNANDES A, FERNANDES R, CATARINO S, GIRAO H
IBILI-Centre of Ophthalmology, University of Coimbra, Coimbra

Purpose The purpose of this study is to establish the effect of oxidative stress and high glucose in intercellular communication through gap junctions (GJIC) and Cx43 degradation in lens epithelial cells and retinal endothelial cells.

Methods Primary cultures of lens epithelial cells or retinal endothelial cells were exposed to oxidative stress or high glucose in the presence or absence of proteasome inhibitor MG132. The levels of Cx43 were assessed by western blot. The contribution of the proteasome for the degradation of Cx43 upon exposure to oxidative stress or high glucose was evaluated by metabolic labeling of Cx43 with [35S]-methionine. Subcellular distribution of Cx43 was determined by confocal microscopy. GJIC was evaluated by transfer of the dye Lucifer yellow.

Results The levels of Cx43 in cell cultures exposed to oxidative stress or high glucose decreased as compared to controls as did the half-life of the protein. The proteasome inhibitors prevented the loss of Cx43 induced by oxidative stress or high glucose and extended Cx43 half-life. The amount of phosphorylated Cx43 increased both in high glucose and following oxidative stress, while GJIC decreased. Significantly, this reduction can be reverted by proteasome inhibitors. The decreased GJIC is apparently associated with loss of Cx43 from the plasma membrane as demonstrated by immunofluorescence and biotinylation of cell surface proteins.

Conclusion Both oxidative stress and high glucose lead to a decrease of GJIC presumably by a similar mechanism, that involves hyperphosphorylation of Cx43 and targeting of membrane Cx43 for degradation by a proteasome-dependent mechanism. Moreover, the mechanism whereby hyperglycaemia leads to reduced GJIC is al least in part associated with increased oxidative stress.

EVER-2004-abstractbook.indd 150 8/19/04 12:26:57 PM

■ 2261

Current Concepts in the Pathogenesis of Retinal Vein Occlusions. Goals of Treatment

POURNARAS CJ
Department of Ophthalmology, University Hospitals, Geneva

Purpose To discuss the pathogenesis based rational for various new therapeutic approaches for the management of retinal veins occlusions.

Methods The physiopathogenic mechanisms and the various treatment modalities of RVO having been in the center of clinical and experimental research. Venous stasis induces both changes in the blood-retina barrier leading to formation of extracellular retinal edema and arteriolar vasoconstriction leading to tissue hypoxia, intracellular retinal edema and neuronal cell death. Work up and laboratory evaluation of patients requires the clinician to rule out systemic diseases affecting the retinal vessels wall, those inducing hemodynamic modifications of the retinal blood flow and primary and secondary thrombophilias.Current treatment of acute BRVO aims to restore venous circulation.

Results Isovolemic hemodilution leading to an increase in ocular blood flow and regression of tissue hypoxia constitute currently available modalities of acute RVO. Grid photocoagulation, through to improvement of the retinal oxygen distribution and retinal blood flow changes, improves visual prognosis in eyes with macular edema following BRVO and decreases the risk of neovascularization in eyes with ischemic retinal areas. Pilot studies have evaluated the efficacy of fibrinolytic treatment or surgical decompression and separation of the artery and the vein are approaches currently under evaluation.

Conclusion Although various new therapeutic approaches have been developed in the past few years for the management of retinal veins occlusions, existing therapeutic approaches are subject of controversy and available data, except those confirmed by randomized studies, are to some extend inconsistent.

■ 2262

Hypercoagulable States and Retinal Vein Occlusions: Coagulation Status and the Necessary Laboratory Tests

HATTENBACH LO (1), KUHLI C (2), OHRLOFF C (2)
(1) Klinik für Augenheilkunde, Klinikum der Johann Wolfgang Goethe-Universität, Frankfurt am Main
(2) Klinik für Augenheilkunde, Klinikum der JWGoethe-Universität, Frankfurt am Main

Purpose Since thromboembolism is multicausal, resulting from the interaction between genetic and acquired risk factors, it seems plausible that screening for coagulation disorders in affected individuals should be selective. Based on the results of a prospective study, we provide guidelines for the identification of thrombophilic defects in patients with retinal vein occlusion.

Methods A cohort of 184 patients with RVO and a control group of 130 subjects matched for age, sex and several risk factors were screened for thrombophilic defects. Both cohorts were divided into two subgroups (</=45 or >45 years), depending on the patients' age by the time of the RVO or a previous thromboembolic event. Laboratory tests included platelet count, PT, aPTT, APC (F.V Leiden mutation), AT III, factor VII, factor XII, protein C and S, heparin cofactor II, plasma homocystein level, lupus anticoagulant, anticardiolipin antibodies, plasminogen, t-PA and PAI antigen, fibrinogen, and histidine-rich-glycoprotein.

Results The proportion of individuals with thrombophilic defects was higher in the patient group (63 of 184; 34.2%) when compared to controls (15 of 130; 11.5 %). Patient age </=45 yrs by the time of the RVO or a previous thromboembolic event was associated with a high prevalence of coagulation disorders (55%). Among those young patients with no known cardiovascular risk factors, the prevalence was 81.5%. Coagulation disorders were less frequent in the patient group >45 yrs (24.2%).

Conclusion Our results indicate that thrombophilic disorders are highly prevalent in RVO patients </=45 years of age and/or a history of thrombosis at this age. Selective screening may be helpful in identifying RVO patients with thrombophilic defects.

■ 2263

Experimental retinal vein occlusion

PAQUES M (1, 2, 3)
(1) INSERM U 592, Paris
(2) Fondation OPhtalmologique Rothschild, Paris
(3) Centre Hospitalier National des Quinze-Vingts, Paris

Purpose To describe our experience with rodent models of retinal vein occlusion

Methods We performed branch retinal vein occlusions in rodents by photocoagulation. SLO imaging, confocal microscopy and histology were then used to analyse the subsequent modifications in retinal vessels and in neural tissue.

Results Laser photocoagulation leads to a transitent vein occlusion, that lasts during 2 to 6 days. A slight retinal detachment accompanies BRVO, due to immediate rupture of the blood-retina barrier. Upward of the occlusion site, capillary closure was observed predominantly in the intermediary layer, which is likely due to the anatomical disposition of capillary connections. Despite reperfusion, capillaries do not repermeate completely. Neural lesions associates various degree of retinal atrophy, starting from disapearance of the external plexiform layer to severe atrophy. Occlusion of two veins leads to more severe retinal detachment and retinal atrophy. In this model no newvessels were detected. There is a significant variability between rodent strains and species.

Conclusion The rat model of retinal vein occlusion is a convenient model to study in vivo the consequences of sectorial retinal ischemia, and may be of interest to evaluate neuroprotective strategies.

■ 2264

Acute phase medical treatment (hemodilution)

HANSEN LL
Universitaetsaugenklinik, Sektion Retin. Erkrankungen, Freiburg

Purpose The acute phase treatment has to aim at the immediate improvement of retinal circulation. If the thrombus, which certainly plays the chief part in the development of retinal vein occlusion (RVO), cannot be dissolved, an improvement of the fluidity of the blood should be the method of choice.

Methods The blood fluidity can best be increased by reducing the hematocrit. This can be induced by infusion of Hydroxyethylstarch alone or an additional blood letting. Hemodilution to a hematocrit of 0,32-0.35 enhances the passage times by 30 to 50% in areas of diseased microcirculation and hence offers a better oxygen supply despite providing less oxygen carriers.

Results Hemodilution has been proven safe and effective in randomised studies with CRVO (Hansen 85, 89; Wolf 91) and RBVO (Hansen 88; Chen 98). It does not prevent the development of neovascular glaucoma or retinal neovascularisation, but nearly doubles the number of eyes with a more than 2 line visual improvement. It can well be combined with acute surgical treatment modalities (AV-Dissektion, RON) and allows for more patients to be treated than does systemic clot-lysis with rtPA.

Conclusion We feel that isovolemic hemodilution still should remain the basic treatment in RVO.

EVER-2004-abstractbook.indd 151 8/19/04 12:26:58 PM

■ 2265

Assessment and follow-up of CME by OCT in retinal vein occlusions. The role of intravitreal steroids

KARACORLU M
Istanbul Retina Institute, Inc., Istanbul

Purpose Assessment and follow-up of cystoid macular edema by optical coherence tomography-OCT in retinal vein occlusions and to evaluate the effect of intravitreal triamcinolone acetonide for macular edema secondary to the retinal vein occlusions.

Methods Macular edema occurs in a wide variety of ocular diseases and it is the most common cause of vision loss in patients with diabetic retinopathy and in other ischaemic retinopathies such as branch retinal vein occlusion and CRVO. Although there are many possible causes for vision loss associated with RBVO &CRVO, many of the reports dealing with the treatment of vision loss from RVO have focused on macular edema. OCT & Heidelberg Fluorescein Videoangiography were used in this group of studies.

Results Intravitreal steroids might play a role in the treatment of macular edema due to retinal vein occlusions

Conclusion Intravitreal triamcinolone acetonide is a rapid and effective therapeutic method for macular edema secondary to the branch and central retinal vein occlusion. Recurrences and secondary glaucoma are the major problems in this treatment.

■ 2266

Endovascular Surgery and tPA in Retinal Vein Occlusions

FELTGEN NF, HERRMANN JH, HANSEN LH
Universitaets-Augenklinik, Freiburg

Purpose A new therapeutic option for eyes suffering from ischemic central retinal vein occlusion (CRVO) is the retinal endovascular lysis (REVL) with tissue plasminogen activator (rtPA) .r-tPA has been employed successfully for the treatment of different types of vascular occlusion. The advantage of this new method is the direct infusion of r-tPA into a retinal vein to avoid systemic side effects and hence include more patients. Before the cannulation of the retinal vessel a standard pars plana vitrectomy has to be performed. The method was first described by Weiss and Bynoe who found a remarkable postoperative improvement of the visual acuity in about 50% of their patients. We will compare the results of our 8 patients to those given in literature and focus on complications. Inclusion criteria for suitable patients and the feasibility of the method will be discussed.

■ 2267

Current status of surgical decompression in retinal vein occlusions

POURNARAS CJ (1), KARACORLU M (2)
(1) Deparment of Ophthalmology, University Hospitals, Geneva
(2) Istanbul Retina Institute, Inc., Istanbul

Purpose Current treatment of acute BRVO aims to restore venous circulation. The purpose of this presentation is to discus the current status of surgical decompression either by adventisectomy leading to the separation of the retinal artery and the vein or neurotomy.

Methods Three port pars plana vitrectomy, removal of the internal limiting membrane and arteriovenous crossing sheathotomy or optic disc rim neurotomy are the current approaches of decompression to the retinal branc veins or central retinal vein respectively. High speed ICG videoangiography was used to understand the optic nerve head and opto-ciliary collateral circulation.

Results Vitrectomy and sheathotomy seems to be of benefit in the management of BRVO, in particular in eyes with no previous posterior vitreous detachement resulting to a decrease of the macular edema, allthough the aspect of the vein at the arteriovenous crossing remains in most of the cases unchanged. Retinal choroidal collateral circulation after radial optic neurotomy correlated with the lessening of macular edema.

Conclusion Although various new therapeutic approaches have been developed in the past few years for the management of retinal veins occlusions, available data, except those confirmed by randomized studies, are to some extend inconsistent, supporting the need for further randomized trials for the evaluation of the surgical procedures.

EVER-2004-abstractbook.indd 152 8/19/04 12:26:58 PM

■ 2311

Effect of Human Tears on Cationic Antimicrobial Peptide Activity In Vitro

MCDERMOTT AM, HUANG LC, NARAYANAN S
College of Optometry, Houston

Purpose Ocular surface epithelia express a variety of cationic antimicrobial peptides including human beta-defensin-2 (hBD-2) and LL-37. We investigated the effect of human tears on the activity of these peptides against Pseudomonas aeruginosa (PA).

Methods Un-stimulated human tears were collected using glass capillary tubes. Mid-log phase PA (ATCC 27853 or clinical isolates) were incubated with hBD-2 or LL-37 (0.05-100 ug/ml) in the absence or presence of tears (17.5, 35 and 70% v/v) for 2 hours at 37oC. Plates were inoculated with samples of each reaction mixture, incubated for 24hrs at 37oC then the number of colonies was counted. In some experiments tears were heat-inactivated (65oC, 30 minutes) or filtered (50kDa cutoff) before use. Other experiments were carried out in the presence of SB-3CT (an MMP-2/9 inhibitor) or active rMMP-9.

Results hBD-2 and LL-37 inhibited PA growth with complete inhibition being seen at 100ug/ml. Human tears did not affect the activity of LL-37 (n = 3), however the activity of hBD-2 was markedly reduced (39 – 90% depending upon tear concentration, n=5). Heat-inactivation attenuated (35%, n=2) and filtration (n=3) completely destroyed the ability of tears to reduce hBD-2 activity. The inhibitory effect of tears on hBD-2 activity was completely eliminated by SB-3CT (n=2) whereas rMMP-9 reduced hBD-2 activity by 80% (n=3).

Conclusion hBD-2 but not LL-37 antimicrobial activity is sensitive to the presence of human tears. The loss of hBD-2 activity is, at least in part, due to MMP-2/9. These data call in to question the effectiveness of some cationic peptides expressed at the ocular surface and indicate the need for careful choice when selecting peptides for further investigation of their therapeutic potential.

■ 2312

Tear meniscus radius and tear film formation in healthy and dry eye states

OWENS H (1), SUGITA J (2), YOKOI N (3), TIFFANY J (4), PHILLIPS JR (1), BRON AJ (4)
(1) Optometry & Vision Science, Auckland
(2) Ophthalmology, Nagoya
(3) Ophthalmology, Kyoto
(4) Ophthalmology, Oxford

Purpose To examine the relationship between tear volume and distribution.

Methods Tear volume and distribution were examined non-invasively in 19 dry eye and 10 normal subjects. Volume was inferred from measurements of tear meniscus radius (TMR) at the centre of the lower eyelid, using a video-meniscometer. Tear distribution parameters [particle initial velocity (PIV) post-blink and particle stabilization time (PST)] were calculated from video recordings of the naturally occurring particles present in the tear film lipid layer. Dry eye subjects were evaluated on one occasion, whereas healthy subjects were investigated pre- and post-manipulations of the tear film, using a high viscosity agent and, separately, a mucolytic agent.

Results There was no correlation between TMR and PIV (r=-0.07; p=0.67) for either group. A significant correlation was evident between TMR and PST in the dry eye group (r=-0.7; p=0.015), but not in the healthy group (p=0.29). The addition of 20ul of sodium hyaluronate 0.2% diminished PIV by 30.7% while increasing TMR by 100%. Benoxinate instillation increased PIV by 30% while increasing TMR by 9.7% but subsequent introduction of acetylcysteine 5% produced no further change.

Conclusion In healthy eyes, tear spreading parameters are not correlated with a tear volume index whereas in dry eye states, PST is negatively correlated with TMR. Artificially increasing tear film viscosity significantly slows tear film distribution and delays stabilisation time while increasing the volume of tears held in the conjunctival sac. 20ul of acetylcysteine 5% has no appreciable effect on tear film spreading under local anaesthesia. Qualitative and quantitative changes in tear particles were observed in different dry eye states.

■ 2313

Tear-film dynamics after incomplete blinking

ERDELYI B, NEMETH J
Ist Dpt of Ophthalmology, Semmelweis University, Budapest

Purpose To observe the tear-film dynamics after incomplete blinking in healthy individuals.

Methods Fifteen healthy subjects (27.8±5.1 years) were examined using a high-speed videotopographic instrument introduced by our work-group earlier. Series of topographic images were recorded at a speed of 2 images per second for 30 seconds. For each subject the examination was performed in two subsequent situations: after a complete blink and after an incomplete blink. Eyelid fissure width was measured for the incomplete blink.

Results The ocular surface was more regular (surface regularity index: SRI p<0,05) after blinks with complete eye closure than after incomplete blinking. Tear-film build-up process could be registered in 11 cases after a complete blink and also in 11 cases after incomplete blinking. The time to reach the minimum SRI value was similar (p=0.680) in the two situations (average 7.1 and 6.7 seconds, respectively). Later in the examined time period tear-film rupture was seen in 7 and 10 subjects, respectively at on average 16.6 and 19.5 seconds after blinking (p=0.907).

Conclusion Literature data show that tear-film dynamics depends on the characteristics of blinking. However in our study, incomplete blinking was not found to induce rapid tear-film instability after opening the eye, which is important, as blinking is overwhelmingly incomplete in everyday life. Though the initial formation of the trilaminal tear-film is not perfect in this case, there might exist a compensating mechanism, which maintains the optical function of the tears.

■ 2314

Vitamin A-responsive xerophthalmia

MANGANELLI C, TURCO S, SCULLICA L
Dept. Ophthalmology, Catholic University of Sacred Heart, Roma

Purpose To report 3 cases of persistent xerophthalmia that regressed after vitamin A therapy in patients operated on for obesity.

Methods We examined 3 patients (2 females and 1 male aged 56, 48 and 47 years) who had undergone biliopancreatic diversion (BPD) 12, 7 and 8 years previously. The patients complained of persistent bilateral eye burning and foreign body sensation resistant to antibiotics and artificial tears. They did not follow the prescribed vitamin supplemention. Eye examination showed bilateral xerophthalmia with superficial punctate keratitis. Serum levels of vitamin A were low.

Results Xerophthalmia disappeared after massive dose intramuscular vitamin A therapy followed by periodic supplementation.

Conclusion Malnutrition xerophthalmia, common in developing countries, is rare in industrial countries. In cases of persistent xerophthalmia it is important to consider as differential diagnosis vitamin A deficiency secondary to malabsorption (obesity surgery) or intake deficiency. A correct diagnosis and prompt treatment can avoid long term ocular complications.

EVER-2004-abstractbook.indd 153 8/19/04 12:26:59 PM

2315

Dry Eye and Corneal Sensitivity after High Myopic LASIK

TUISKU ISJ, LINDBOHM N, TERVO TMT
Department of Ophthalmology, University of Helsinki, Helsinki

Purpose To assess subjective symptoms and objective clinical signs of dry eye and to investigate corneal sensitivity after > 10 D myopic LASIK.

Methods Twenty eyes of 20 patients, who had undergone > 10 D myopic LASIK two to five years earlier, were enrolled in the study. Clinical objective signs of dry eye, and subjective dry eye questionnaires were used to harvest data. The central corneal mechanical sensitivity was assessed with modified Belmonte Non-Contact Esthesiometer.

Results The mean preoperative refraction (spherical equivalent; SE) was -11.4+-1.4 D and the intended correction SE was –10.4+-1.1 D. Postoperatively, the mean manifest refraction was –1.9 +- 1.6 D. The refractive outcome was satisfactory, the mean UCVA was 20/10 and BCVA 20/20. The Schirmer´s test score was 14.4 +- 8.9 mm and BUT was 15.9 +- 11.2 s. The majority of patients reported dry eye symptoms (60%) and glare and halos (80 %) under scotopic conditions. However, almost all the patients (95 %) were satisfied with the outcome and would have chosen the operation again. The mean corneal sensitivity (threshold) was 73.5 +- 29.6 ml/min in LASIK patients and 74.0 +- 23.0 ml/min (p=0.97) in controls. Ocular surface disease index (OSDI) score, indicating degree of dry eye symptoms, was significantly higher in LASIK patients (9.0 +- 6.4) compared to normal controls (2.5 +- 3.7;p = 0.006).

Conclusion Unlike at earlier time points, corneal mechanical sensitivity threshold values did not differ from controls two to five years following LASIK. Interestingly, the majority of patients reported dry eye symptoms, although objective clinical signs of dry eye were not demonstrable. We assume that these symptoms may be derived from abnormally regenerated corneal innervation.

2316 / 318

Ocular & Dermal Hydration: The Role of Hydrogels in the Control of Moisturisation

TIGHE B (1, 2), BAHIA R (1, 2)
(1) Biomaterials Research Unit, CEAC
(2) Aston University, Birmingham UK

Purpose Inadequate hydration of the cornea and skin can result in unacceptable symptoms of dryness associated with these body organs. The presence of a contact lens presents additional complications. Nature often uses similar control mechanisms in related body sites. This poster considers the tissue hydration control mechanisms that operate in the anterior eye and the skin, together with the potential for exploitation of techniques from one field in the other.

Methods Model substrates representing lipoidal and aqueous delivery pathways to cellular layers are prepared. Hydrogels are prepared loaded with species known to be important in promoting skin hydration (natural moisturising factors – NMFs). Examples include: - 2-pyrrolidone-5-carboxylic acid- amino acids (e.g. glycine)- alpha hydroxy acids (e.g. lactic and lactobionic acids)- Vitamins (especially B5, A, B6, E).

Results The study illustrate that it is possible to release NMFs from a polymer matrix through both aqueous and lipoidal routes. Release data will be presented. Biphasic hydrogel technology allows control of the release the release of both hydrophilic and hydrophobic NMFs.

Conclusion The eye is dominated by the aqueous environment and the skin is dominated by the lipoidal environment. Nonetheless dry skin and dry eye are both induced by inadequacies in lipid and moisture levels and control mechanisms. It seems logical to investigate treatment of early stages of dry eye, particularly contact lens induced dry eye, by delivery of selected natural moisturising factors. The use of the contact lens as a delivery matrix offers great potential in this respect, provided that the subtleties of the release mechanisms are properly utilised.

2317 / 319

Correlation of Schirmer test score and tear break up time with Ocular surface staining in Dry Eye disease

SUNDARAM V, EVERY S, BRON AJ, SAMARASINGHE S, PRABHAKARAN E, VATHESATOGIT C
Nuffield Laboratory of Ophthalmology, Oxford

Purpose Controversy exists as to the value of diagnostic tests in the dry eye diagnosis. Questions remain as to the relation between test parameters and disease severity. This study aims to evaluate correlations between the Schirmer test, tear break up time (TBUT) and ocular surface staining in patients with dry eye disease.

Methods A retrospective review of dry eye patients was performed. Patients with the diagnosis of dry eye were retrieved from the Oxford Eye Hospital database. Of the 98 patients located, 20 were identified with a Schirmer test score of less than 10 mm, who had a full record of both inter-palpebral and extra-palpebral ocular surface staining with the Oxford Grading Scheme. There were 19 females and 1 male, with a mean age of 50.9 years (range 20-83 years). For statistical analysis, correlation coefficients were calculated for right and left eyes using the Spearman rank correlation test with SPSS version 10.

Results TBUT was significantly correlated with total ocular surface staining ($p<0.01$), staining in the inter-palpebral region ($p<0.01$) and temporal conjunctival region staining ($p<0.05$), in both eyes. In the left eye, TBUT was also significantly correlated with nasal conjunctival ($p<0.05$) and corneal ($p<0.05$) staining. The Schirmer test did not correlate significantly with any areas of ocular surface staining in either eye. Also there was no correlation between the Schirmer test and the TBUT.

Conclusion TBUT showed significant correlation with degree of ocular surface staining and may reflect the severity of ocular surface inflammation more accurately than the Schirmer test in patients with dry eye disease.

EVER-2004-abstractbook.indd 154 8/19/04 12:26:59 PM

■ 2321

Intravitreal levofloxacin monotherapy in endophthalmitis experimental model

FERRER RODRIGUEZ C (1), FERNANDEZ CANILLAS J (2), RODRIGUEZ AE (3), ABAD LOZANO JL (2), ALIO JL (2, 4)
(1) Molecular Biology, VISSUM, Alicante
(2) VISSUM, Alicante
(3) Microbiology, VISSUM, Alicante
(4) Patologia y Cirugia, Universidad Miguel Hernandez, Alicante

Purpose To evaluate the efficacy of intravitreal levofloxacin 1.5% monotherapy versus combined therapy in an experimental model of endophthalmitis due to Gram positive microorganisms.

Methods 50 New Zealand rabbits received injections of either Staphylococcus aureus (40 CFU/0,1 ml) or Staphylococcus epidermidis (40.000 CFU/0,1ml) into the vitreous cavity of right eye. Three subgroups were formed; treatment with 0.1 ml levofloxacin 1.5% (10 rabbits), treatment with 0.1 ml of vancomycin 1% and 0.1 ml of ceftazidime 2% (10 rabbits), and an untreated control subgroup (5 rabbits). The Peyman classification was used to assess the severity of endophthalmitis. Eye examination were performed until day 8 from inoculation. The microbiological status of vitreous and aqueous humor samples was tested at day 2, 3, 5 and 8.

Results In the S. aureus group both treatments (combined and monotherapy) showed the same results, 90% did not develop severe endophthalmitis. In the S. epidermidis group the result was effective in 100% of cases with both therapies, monotherapy and the combined treatment

Conclusion This dose of levofloxacin (1.5%) was considered as effective as the combination of vancomycin and ceftazidime in treating Gram-positive (Staphylococcus) infections.

■ 2322

Evaluation of Retinal Leukocyte Adhesion in a Mouse Model of Diabetes

WADDELL JM (1), MANIVANNAN A (2), COTTER MA (2), FORRESTER JV (1)
(1) School of Medicine, Aberdeen
(2) School of Medical Sciences, Aberdeen

Purpose To investigate the effect of Rosuvastatin, a lipid lowering drug recently reported to have vasculoprotective effects independent of its lipid lowering properties, on leukocyte-endothelial interactions in the streptozotocin diabetic mouse model.

Methods Four groups of animals were used: untreated normal mice, untreated diabetic mice, treated normal mice and treated diabetic mice. Leukocytes were isolated from spleens of syngeneic mice and labelled with the fluorescent tag calcein-AM. Cells were transferred to same group syngeneic mice and imaged in the retina using a scanning laser ophthalmoscope (SLO). After imaging animals were killed and retinas flat mounted for examination of cells using confocal microscopy.

Results Leukocyte adhesion was assessed both in vivo by SLO and ex vivo in retina whole mounts. The total number of cells adhering to the retinal vasculature of diabetic mice was significantly greater than the number of cells that adhered in normal mice ($p<0.01$). The largest difference was observed in those cells with the shortest transient arrest time ($p<0.001$). Treatment with Rosuvastatin restored leukocyte adherence in the diabetic mouse to normal values ($p<0.005$). Similar trends were observed in flat mount preparations of excised retinas.

Conclusion These results confirm previous reports indicating that leukocyte adhesion is, in part at least, responsible for the capillary occlusions that occur in diabetic retinopathy. In addition, rosuvastatin may be effective in the treatment of diabetic retinopathy by preventing leukocyte adhesion to the vascular endothelium in retinal vessels.

Supported by Astra Zeneca.

■ 2323

Upregulation of ubiquitin proteasome pathway (UPP) in retinal endothelial cells in response to oxidative stress

FERNANDES A, FERNANDES R, RAMALHO J, PEREIRA P
IBILI-Center of Ophthalmology, Coimbra

Purpose Oxidative stress has been implicated in the development of diabetic complications. The purpose of this study is to establish whether oxidative stress up-regulates the UPP leading to increased protein degradation in diabetes.

Methods Retinal endothelial cells were exposed to 40 or 100 uM of hydrogen peroxide. Endogenous ubiquitin conjugates were detected by Western Blotting. The ubiquitin conjugating activity assays was determined usind radiolabeled ubiquitin or a-lactalbumin. The 20S proteasome activity was determined by degradation of the fluorogenic substrate, Z-Leu-Leu-Leu-MCA. Levels of mRNA were determined by radioactive Northern Blot.

Results The exposure of endothelial cells to physiological concentrations of hydrogen peroxide leads to an increase on ubiquitin conjugating activity to endogenous and exogenous substrates. Moreover, levels of mRNA for a particular ubiquitin gene (UBA) are increased in response to oxidative stress, whereas proteolytic activity (20S proteasome) decreases by about 31%.

Conclusion Oxidative stress up-regulates the UPP by increasing expression of UBA and leads to proteasome inhibition. Impaired proteolytic activities may account for retinal endothelial cell damage associated with diabetes or other pathologies involving increased production of oxidants.

■ 2324

Aldose reductase inhibition counteracts diabetes-induced retinal nitrosative stress and poly(ADP-ribose) polymerase (PARP) activation

OBROSOVA IG (1), SZABO C (2), STEVENS MJ (3), PACHER P (4)
(1) Louisiana State University, Baton Rouge, LA
(2) Inotek Corp., Beverly, MA
(3) Internal Medicine, University of Michigan, Ann Arbor, MI
(4) NIH/NIAAA, Rockville, MD

Purpose Aldose reductase inhbitors (ARIs), antioxidants, and, recently, PARP inhibitors were found to prevent diabetic retinopathy in animal models. We studied the relation among three mechanisms, by evaluating the potent and specific ARI fidarestat (F) on retinal nitrosative stress and PARP activity in STZ-diabetic rats and high glucose-exposed endothelial cells.

Methods We used control and STZ-diabetic rats treated with or without F (16 mg kg-1 d-1) starting from induction of diabetes. The duration of experiment was 6 wks. Sorbitol pathway metabolites were assessed by enzymatic spectrofluorometric methods, and nitrotyrosine and PARP activity by immunohistochemistry. In in vitro studies, endothelial cells were cultured in 5 mM glucose, 30 mM glucose and 30 mM glucose plus 1 microM F. Oxidative-nitrosative stress was evaluated using CM-D2CFDA-flow cytometry and PARP activity by CELISA.

Results Retinal nitrotyrosine and poly(ADP-ribose) immunoreactivities were increased in diabetic rats vs controls. F treatment resulted in 1) normalization of sorbitol pathway activity (manifested by both sorbitol and fructose concentrations), without affecting retinal glucose concentrations; 2) suppression of nitrosative stress and PARP activity, in the retina of diabetic rats. In vitro, F decreased CM-D2CFDA fluorescence (a marker of intracellular oxidative-nitrosative stress) and poly(ADP-ribose) accumulation in high glucose-exposed endothelial cells. F did not affect poly(ADP-ribose) formation in cell-free system containing PARP and NAD.

Conclusion Aldose reductase inhibition counteracts nitrosative stress and PARP activation, two phenomena implicated in the pathogenesis of diabetic retinopathy.

EVER-2004-abstractbook.indd 155 8/19/04 12:27:00 PM

■ 2325

Ghrelin relaxes the iris sphincter muscle through a GHSR-1A independent pathway

ROCHA DE SOUSA A (1, 2), SARAIVA J (1), GONZAGA S (3), CORREIA-PINTO J (3), FALCÃO-REIS F (2), LEITE-MOREIRA AF (1)
(1) Physiology, Faculty of Medicine University of Porto, Porto
(2) Ophthalmology, S Joao Hospital, Faculty of Medicine, Porto
(3) Development Unit, Health and Life Sciences Institute, School of Health Sciences, University of Minho, Braga

Purpose To characterize production and contractile effects of Ghrelin on iris sphincter muscle and the role of GHSR-1a in its mediation.

Methods Cumulative doses of Des-octanoil 1-5 Ghrelin (Des-Ghr, 10e-9 to 6*10e-5M; n=10) or 1-5-Ghrelin (Ghr, 10e-9 to 6*10e-5M; n=54) to generate concentration-response curves were tested on precontracted (Carbacol; 10e-4M) rabbit iris sphincter muscles. Ghr was added in the absence (n=14) or presence of i) L-nitro-arginine (L-NA, 10e-4M; n=14); ii) indomethacin (10e-5M; n=14); iii) D-Lys-GHRP6, a selective GHSR-1a inhibitor (10e-4M; n=12). Results are expressed as % changes from control. Ghrelin production was assessed by "in situ" hybridization for detection of Ghrelin mRNA in Wistar rat eyes (n=7).

Results Ghr and Des-Ghr promoted a concentration-dependent relaxation of the muscle maximal at 10e-5M, which relaxation of 34.1±12.1 % and 37.1±2.6 %. This was recorded 1.5-3 minutes after its addition to the bath and disappeared 10 minutes later. Although not statistically significant, there was a trend for L-NA to exacerbate and for indomethacin to attenuate Ghr's relaxing effect (muscular tension decreased 58.0±10.5% and 20.3±12.1%, respectively). D-Lys3-GHRP6 significantly increased the relaxing effect of Ghr (118.1±21.1%). Ghrelin mRNA was identified in the posterior epithelium of the iris.

Conclusion Ghrelin therefore is a novel, locally produced, relaxing agent of iris sphincter muscle. This effect has rapid onset, is transient and seems, to some extent, to be modulated by NO and prostaglandins. Its potentiation when GHSR-1a is inhibited and the similar effect of des-octanoil-ghrelin suggest a mediation through another type of GHS receptor.

■ 2326 / 236

Retinal endothelial cell dysfunction caused by hyperglycemia and oxidative stress

CASTILHO A, SERRA A, LEAL EC, AVELEIRA C, AMBRÓSIO AF
Center of Ophthalmology of Coimbra, IBILI, Coimbra

Purpose Hyperglycemia plays a major role in diabetic retinopathy, and oxidative stress injury appears to be involved in this pathology. In this work, we investigated whether retinal endothelial cells exposed to hyperglycemia are more susceptible to oxidative stress.

Methods Rat retinal endothelial cell line - TR-iBRB2 - was exposed to high concentration of D-glucose (30 mM) or mannitol (24.5 mM), an osmotic control, for 7 days, and to NOC-18 (NO donor) or H2O2 for 24 hours. In addition, high glucose treated cells (7 days) were also exposed to NOC-18 or H2O2 during the last 24 hours. Cell viability, cell proliferation and the identification of apoptotic cells was assessed by MTT assay, [methyl-3H]-thymidine uptake and Hoechst assay, respectively.

Results Long-term exposure of retinal endothelial cells to high glucose concentration decreased cell viability and increased the number of apoptotic cells. Cell viability was not affected by mannitol. Furthermore, high glucose and mannitol decreased endothelial cell proliferation. Short-term exposure (24 h) of endothelial cells to NOC-18 or H2O2 also decreased cell viability and increased the number of apoptotic cells. The effect of both high glucose (7 days) and NOC-18 or H2O2 (24 h) either on cell viability or programmed cell death was significantly higher than the effect of high glucose, NOC-18 or H2O2 alone.

Conclusion These results demonstrate that hyperglycemia decrease the proliferation and increase the degeneration of retinal endothelial cells. In addition, endothelial cells exposed to hyperglycemia may become more susceptible to stress conditions.

■ 2327 / 237

Metipranolol is the only ophthalmic beta-blocker to counteract oxidative stress-induced death to cultured human RPE cells

WOOD JPM, OSBORNE NN
Nuffield Laboratory of Ophthalmology, Oxford

Purpose To investigate the influence of known ophthalmic beta-blockers on cultured human RPE cells subjected to different oxidative stresses.

Methods Cultured human RPE cells (passage 3-5), in medium lacking serum, were insulted with a range of concentrations of either zinc sulphate (ZnSO4), t-butylhydroperoxide (t-BH) or buthionine sulphoxamine (BSO) for 24 hours. Cells were analysed for the appearance of DNA breakdown by the terminal deoxynucleotidyl transferase UTP-linked nick-end labelling (TUNEL) reaction, by viability determination using the MTT reduction assay and by electrophoresis/immunoblotting for the appearance of cell death-associated protein changes. In some instances, incubations were carried out in the presence of a range of ophthalmic beta-blockers, to determine whether such compounds could counteract the detrimental changes seen after oxidative stress.

Results Each of the oxidative insults caused concentration-dependent reductions in cell viability and the appearance of markers that were suggestive of apoptotic cell death (positive TUNEL reactivity in cell nuclei, cleavage of PARP, increased levels of active caspase-3). Of the beta-blockers tested (metipranolol, carteolol, timolol, betaxolol, levobunolol), only metipranolol was able to significantly counteract the effects of oxidative stress to the RPE cells and this compound was effective against all oxidants. The effect of metipranolol was comparable with that of vitamin E and trolox, which are known antioxidants.

Conclusion Oxidative stress to cultured human RPE cells causes death that is characteristic of apoptosis. Metipranolol, like the known antioxidants Vitamin E and trolox, is able to counteract such oxidative insults to these cells.

■ 2328 / 238

Expression of Monocarboxylate Transporters in the Rat Retina: Effects of Retinal Degenerations

CHIDLOW G (1), WOOD JPM (1), GRAHAM M (2), OSBORNE NN (1)
(1) Nuffield Laboratory of Ophthalmology, University of Oxford, Oxford
(2) AstraZeneca R&D, Loughborough

Purpose Monocarboxylate transporters (MCTs) are expressed in the retina but the cellular localisation of the individual isoforms is still unclear. The purpose of this study was to investigate the expression of MCTs in the normal rat retina and in the retinas of rats which had undergone specific retinal degenerations to kill particular cell types.

Methods In order to kill neurons within the inner retina, Wistar rats were injected intravitreally with kainate and killed after 3 or 7 days. To induce degeneration of photoreceptors two experimental approaches were taken: (1) Wistar rats were exposed to bright light (approximately 2000 lux) for 48h and allowed to recover for 5 days, (2) Dystrophic Royal college of Surgeons' rats were killed at 3 time points: prior to, at the mid point of, and post-degeneration of photoreceptors. Levels of MCTs were determined by real-time RT-PCR, while immunohistochemical localization of MCTs was performed using isoform-specific peptide antibodies.

Results RT-PCR experiments showed that MCTs 1,2 and 4 are all expressed in the normal retina. Rats which had undergone photoreceptor degeneration expressed a lower level of MCT1 but higher levels of MCTs 2 and 4 mRNAs. In contrast, rats treated with kainate expressed reduced levels of MCTs 2 and 4 mRNAs. Immunohistochemistry of control and experimental retinas revealed that MCT1 labelling, although widespread, is concentrated in photoreceptor inner segments, while labelling for MCTs 2 and 4 is highly expressed by inner retinal neurons.

Conclusion MCTs 1, 2 and 4 are specifically and differentially expressed within the retina and altered expression of MCTs following inner or outer retinal degenerations reflects the loss of particular neuronal populations.

EVER-2004-abstractbook.indd 156 8/19/04 12:27:00 PM

2329 / 239

Aqueous humour formation is inhibited by bradykinin via production of cyclic GMP

WILSON WS, ALMALKI W, MARTIN W
Biomedical & Life Sciences, University of Glasgow, Glasgow

Purpose Arterial perfusion of the bovine isolated eye allows resumption of aqueous humour (AH) formation. We have studied the effect and mechanism of bradykinin (BK) on AH formation.

Methods AH formation rate was measured by perfusing bovine eyes through a ciliary artery with Krebs solution (2.5ml/min). AH formation was estimated by fluorescein dilution in a circuit that recycled AH from the cannulated anterior chamber via a fluorimeter. The slope of the regression line (loge [fluorescein] vs time) was taken as the rate constant for AH formation (Kout/min). Drugs were added to the arterial perfusate. Data were subjected to one-way ANOVA and expressed as mean +/- s.e. mean (n = 8 to 17). Once fluorescence values were stable, the starting value for AH formation rate was calculated over 40min. These values were somewhat variable among eyes, but for a given eye, remained stable for at least 120min.

Results Continuous infusion of BK produced a slow, concentration-dependent suppression of AH formation. BK at 1nM inhibited AH formation by 23 +/- 7%. When UK114542 (an inhibitor of phosphodiesterase V; 100nM) was infused simultaneously with BK (1nM), this inhibition was 32 +/- 7%. The effect of BK was mimicked in a concentration-dependent manner by perfusion of 8-bromo cyclic GMP (10pM to 1microM) and was abolished by KT-5823 (an inhibitor of protein kinase G; 10nmol injected every 15min).

Conclusion In the bovine eye, BK inhibits AH production by stimulating synthesis of cyclic GMP.

EVER-2004-abstractbook.indd 157 8/19/04 12:27:01 PM

■ 2331

An introduction into Ocular Dendritic Cells

KNOP E
Research Laboratory, Dept. of Ophthalmology, Charité – University School of Medicine, Berlin

Purpose Dendritic cells are a special class of professional antigen presenting cells that are important for the activation of antigen-specific lymphocytes and the regulation of immune responses. Their precursors derive from the bone marrow and immigrate into almost all organs of the body including the eye. Since DC have a relatively low number and are difficult to isolate from tissues, bone marrow precursors can be obtained and artificially matured under cell culture conditions in order to study DC-biology and function.DC mature after antigen uptake and contact with pathogens and develop into key regulators of antigen presentation. They determine the direction of the resulting immune answer by the stimulation of different subtypes of T-helper cells that in turn govern immune responses by their specific subsets of cytokines. Thereby DC are important factors in processes such as ocular inflammation, autoimmunity, ocular allergy, immune answer to pathogens and corneal graft rejection.At the ocular surface, similar to the skin, Langerhans cells are the predominant class of DC. Several studies have compared the number of Langerhans cells in the human and different animal species and usually reported that they predominated in the conjunctiva and peripheral cornea whereas the central cornea appeared almost devoid of these cells. Recent results using new markers however showed that immature DC are also present in the central cornea and can importantly contribute to processes such as corneal graft rejection etc.. Also in other regions of the eye there is increasing indication for the presence of DC with similar morphology and function. Ongoing research will deepen our insight into ocular immune regulation and probably offer new therapeutic approaches to eye diseases.

■ 2332

Characteristics of DC in culture

FORRESTER J
Department of Ophthalmology, Aberdeen

Purpose Dendritic cells were discovered as a rare subset of spleen myeloid cells about 30 years ago during studies on spleen macrophage populations. However, detailed research on their function and properties was not possible until techniques for bulk culture of these cells was established. Currently, several subtypes of dendritic cells are recognised and culture of these cells from non lymphoid as well as lymphoid tissues is possible. Since dendritic cells are recognised as the initiators of immune responses to foreign antigens as well as the guardians of immunological tolerance to self antigens, there importance cannot be overemphasised. Here we describe the culture of dendritic cells from the ciliary body / choroid of the eye and consider their relevance to a variety of ocular conditions.

■ 2333

What have we learned from corneal transplantation about corneal APC?

DANA R
Schepens Eye Research Institute and Mass. Eye & Ear Infirmary, Harvard Medical School, Boston, MA

Purpose Corneal APC comprise a diverse population of CD45+ bone marrow-derived cells and include epithelial Langerhans cells, stromal dendritic cells, and stromal monocytes — each with distinctive cell surface markers. Regardless of exact lineage, they share the universal constitutive feature of lacking expression of MHC class II antigens as well as CD40, CD80, CD86 costimulatory molecules. Our studies in the mouse model of corneal transplantation have shown that corneal inflammation, in addition to leading to accumulation of APC from the limbus, also leads to several important phenotypic changes by these cells, including their acquisition of (i) class II antigen, (ii) costimulatory molecules, and (iii) vascular endothelial growth factor receptor (VEGFR)-3, the tysosine kinase receptor that also mediates lymphangiogenesis. The upregulated capacity of these APC to present antigen in the context of both signal 1 (MHC-TCR) and signal 2 (CD80/86-CD28) accounts for their ability to prime naïve T cells. However, induction of adaptive immunity requires intimate contact between antigen-bearing APC and naïve T cells in the environment of the lymphoid tissues to which APC traffic through lymphatics. We have recently discovered that acquisition of VEGFR-3 by corneal DC is responsible for the chemotactic responsiveness of these cells to VEGFR-3 ligand including VEGF-C — which itself can induce lymphatic growth. Blockade of VEGFR-3 suppresses induction of graft-derived APC to draining lymph nodes, induction of alloreactivity by the host, and rejection of corneal transplants.

■ 2334

Are there really no dendritic cells in the retina?

DICK A
Clinical Sciences, University of Bristol, Bristol

Purpose To define the evidence for antigen presenting cells (APC) in the retina, given the arguably false assumption that because microglia and perivascular macrophages conform to a dendritic morphology they therefore are APC.

Methods Morphological and phenotypic charateristics of freshly isolated microglia and the retinal macrophages from man, rat and mouse and behavioural characteristics in vitro will be discussed. This will be compared to evidence from CNS

Results Despite phenotypic characteristics that conform to an ability to present antigen there is limited evidence for APC function within retina comparable to dendritic cells elsewhere.

Conclusion Whilst there is some evidence that perivascular macrophages and microglia are weak APC, their main role is to regulate tissue damage in consort with other cellular retinal components as a consequence of conditioning and tuning of myeloid-resident cell response by the retinal environment.

EVER-2004-abstractbook.indd 158 8/19/04 12:27:01 PM

■ 2335

Unusual Phenotype of Dendritic Cells in the Mouse Conjunctiva

ONO S, MANZOURI B, OHBAYASHI M
Institute of Ophthalmology, Bath Street, London

Purpose Professional antigen presenting cells (APCs) are involved in the initiation and control of the immune response to antigens and are mainly divided into two systems: the dendritic cells (DCs, including Langerhan's cells) and the monocyte-macrophage system. DC subpopulations are usually found at the interface with the environment where they capture foreign antigen and then migrate to the draining lymphoid organs to prime naïve T-cells. The migration of DCs to lymphoid organs is tightly regulated by the expression of chemokines in the different anatomical sites as well as the coordinated expression of chemokine receptors on the surface of DCs. At least two distinct dendritic cell precursor cells have been identified: the myeloid DC (DC1) and the lymphoid DC (DC2). In humans, DC1 cells are responsible for inducing T-H1 cells whereas the DC2 subset of cells induces T-H2 differentiation. Atopic individuals show an inherited tendency towards TH2 responses. As it is known that DCs play a critical role in the regulation of TH cell responses via the secretion of various soluble factors and the expression of membrane associated co-stimulatory molecules, we have used double colour immunohistochemical staining for cell surface markers and the MHC class II molecule to demonstrate the distribution of the two subclasses of DCs in the eyelid and conjunctival fornix of the normal A/J mouse eye. We have shown the presence of cells expressing myeloid DC markers but not lymphoid DC markers in the various layers of the eyelid, with these myeloid DCs also showing variable expression of the MHC class II molecule. Interestingly, we have also identified a group of cells in the substantia propria of the conjunctiva that failed to express either lymphoid or myeloid markers but which do express the MHC class II molecule. Hence, we are performing ongoing studies to try to elucidate the nature of these cells and as well as studies to determine how the antigen-immunoglobulin-receptor interaction can be altered to influence the initiation and propagation of allergic disease via these DC subsets identified in the eye.

EVER-2004-abstractbook.indd 159 8/19/04 12:27:02 PM

■ 2341

Ocular Hypertension Masquerading Uveal Melanoma

BIANCIOTTO C (1, 2), SAORNIL MA (3, 4), BLANCO G (5), MUIÑOS Y (1, 2), MENDEZ MC (3), FRUTOS BARAJA J (1, 6), LOPEZ LARA F (7), ESTEBAN R (8), FERNANDEZ N (9)

(1) Instituto Universitario de Oftalmobiologia Aplicada (IOBA), Valladolid
(2) Fundación Carolina, Madrid
(3) Registro de Patologia ocular Miguel N Burnier, Instituto Universitario de Oftalmobiologia Aplicada (IOBA), Valladolid
(4) Unidad de Oncologia Ocular, Hospital Clinico Universitario, Valladolid
(5) Unidad de Oncologia y Oculoplastica, Instituto Universitario de Oftalmobiologia Aplicada (IOBA), Valladolid
(6) Servicio de Radiofisica, Hospital Clinico Universitario, Valladolid
(7) Servicio de Oncología y Radioterapia, Hospital Clinico Universitario, Valladolid
(8) Servicio de Radiodiagnóstico, Hospital Clinico Universitario, Valladolid
(9) Registro de Patología Ocular Miguel Burnier, Instituto Universitario de Oftalmobiologia Aplicada (IOBA), Valladolid

Purpose To present a series of patients with ocular hypertension masquerading uveal melanoma.

Methods Patients with the diagnosis of uveal melanoma were reviewed selecting the cases that presented initially as secondary unilateral glaucoma. Clinical and histopathological data with prognostic value was registered, such as anterior border localization, size and shape of the tumor, associated ocular pathology, cell type and degree of extraocular extension.

Results Seven patients out of a total of 160 diagnosed with uveal melanoma presented with ocular hypertension (4.3% of the total). Six tumors were large, with only one of them being middle-size. All cases had ipsilateral associated asymmetric cataract with visual acuity lower than 0.1. Four cases had neovascular glaucoma, two pseudophacolytic glaucoma and the remaining one had invasion of the anterior chamber angle. All cases were unresponsive to medical glaucoma treatment, due to the unsuspected tumor they harbored. Only one case had extrascleral extension. The histopathologic exam performed in six cases showed that 3 tumors had epithelioid celularity and also 3 had varying degrees of extrascleral extension.

Conclusion In patients presenting with the association of unilateral glaucoma and asymmetric cataract, it is mandatory to perform imaging studies, such as ultrasound, in order to rule out the presence of an intraocular tumor, to achieve an early diagnosis, improving the patient's prognosis and the morbidity of treatments.*Partially funded by grant "Jose Maria Aguilar Bartolomé"

■ 2342

Iodine Brachytherapy (IBT) for Large Ciliochoroidal Melanoma: Modeling Dose Distribution

PUUSAARI I (1), HEIKKONEN J (2), KIVELÄ T (1)
(1) Univerity of Helsinki, Department of Ophthalmology, Helsinki
(2) Univerity of Helsinki, Department of Oncology, Helsinki

Purpose To retrospectively model dose distribution as a predictor of ocular complications after iodine brachytherapy for large uveal melanoma (UM) and to design a modified plaque to reduce doses to ocular tissues.

Methods 96 patients with a large UM underwent primary IBT. Median tumor height and diameter were 10.7 mm (range, 4.5-16.8) and 16.5 mm (range, 7.3-25.0), and median follow-up was 3.5 years (range, 0.3-10.4). Each IBT was retrospectively modeled with the Bebig Plaque Simulator to calculate doses and dose rates to ocular tissues. A sensitivity analysis was used to allow for displacement of the plaque in the model, and Cox regression to assess the association of dose with time to complications and vision loss. A collimating plaque design was tested by replacing the actual plaque with the modified one in each model.

Results Median modeled dose and dose rate to tumor apex was 81 Gy (range, 40-158) and 53 cGy/h (range, 11-204). Median dose to the lens, macula, and optic disc was 69 Gy (range, 20-141), 79 Gy (range, 12-632), and 83 Gy (range, 10-377), respectively. Doses to the lens, macula and optic disc were found to deviate a median of 8-12% with 2 mm plaque displacement while dose to tumor apex was practically unaffected. Dose to the lens was associated with cataract, dose to the optic disc with optic neuropathy, and dose to the macula with low vision and blindness. Collimating round plaques (outer ring of 6 or 8 seeds in slots, central cross of 4 seeds on surface) improved median tumor:macula and tumor:disc dose ratios from 0.99 to 1.81 and from 0.94 to 1.61, respectively.

Conclusion Modeled dose distribution, which predicts key complications and vision loss, is a valuable aid in minimizing radiation dose to normal ocular tissues.

■ 2343

Complications following plaque radiotherapy for uveal melanoma

ROMANOWSKA DIXON B, MARKIEWICZ A, STARZYCKA M
Collegium Medicum of Jagiellonian University, Krakow

Purpose To evaluate treatment complications following brachytherapy and brachytherapy combined with transpupillary thermotherapy (TTT) for choroidal and ciliary body melanoma.

Methods 572 eyes (572 patients aged 14-96 years) with choroidal or ciliary body melanoma were treated with brachytherapy between 1998 – 2002. All patients received treatment using 125I or 106Ru or "sandwich method". Apex dose was 80-120 Gy. The clinical data regarding patient features, tumor features and treatment modalities were analyzed for their effect.

Results After therapy the melanomas decreased in thickeness in 91.6% of cases. Treatment-related complications included neovascular glaucoma (14%), cataract (48%), optic neuropathy (21,5%), retinopathy (21,6%), maculopathy (30,8%), vitreous haemorrhagies (8 %), and retinal detachment (1,8 %).

Conclusion Complications were most common after iodine and their number correlated with tumor size. Anterior segment complications were more common in ciliary body tumors.

■ 2344 / 207

Treatment of uveal melanoma near to the optic nerve or macula by strontium-90 brachytherapy

VAN GINDERDEUREN R (1), SPILEERS W (1), VAN LIMBERGEN E (2)
(1) oogziekten, Leuven
(2) radiotherapy, Leuven

Purpose Uveal melanomas localised near to the macula or the optic nerve are difficult to treat by brachytherapy because of the devastating radiation effect on the surrounding tissue. Strontium-90 has a limited penetration depth and very few radiation effects outside the treated area.

Methods Study of 6 clinical cases with uveal melanoma localisation in the area of the macula or nearer than 3 mm of the optic nerve. All patients were followed for at least 3 years and the visual acuity, visual fields and retinal and choroidal changes are investigated.

Results No optic nerve atrophy or radiaton retinitis was found after 3 years. All patients could retain good central vision and no loss of vision outside the treated area could be detected.

Conclusion Strontium-90 brachytherapy is favourable for the treatment of difficult uveal melanomas in the vicinity of the macula and the optic nerve without complications in the surrounding tissues

EVER-2004-abstractbook.indd 160 8/19/04 12:27:02 PM

2345
Intraocular seminoma mestatases

ROMANOWSKA DIXON B, ORLOWSKA-HEITZMAN J
Collegium Medicum of Jagiellonian University, Krakow

Purpose To present 2 cases with choroidal metastases of germinal tumors arising from the testes.

Methods Males aged 25 and 34 years were affected by intraocular tumor with consecutive glaucoma. The eyes were blind and painful, filled by the tumor mass. Patients were treated by enucleation. After histopathological examination both patients admitted presence of primary tumor, they identified 4 and 6 months before the visual symptoms. They noticed a painless enlargement of the left (younger patient) and right scrotal contents. Patients were treated with orchiectomy and chemotherapy.

Results Histopathological examinations revealed: 1. in the eyeball: metastasis neoplasmatica oculi (neoplasma malignum germinale- chorioepithelioma), and in the testis: Neoplasma germinale mixtum-teratoma immaturum, carcinoma embrionale et chorioepithelioma (diam.16 cm); 2. in the eyeball: Neoplasma germinale mixtum (seminoma, carcinoma embrionale et choriocarcinoma) metastaticum oculi, and in the testis: Choriocarcinoma testis (diam. 6 cm).

Conclusion Abdominal ultrasound, chest X-ray and MRI showed several liver, retroperitoneal site, kidney, lungs and brain metastases. Both young patients died, 9 and 4 months after enucleation.

2346
Conjunctival nevus or malignant melanoma in a child

BOGDANICI C (1), CARUNTU I (2), COZMA L (3)
(1) University of Medicine and Pharmacy, Dept. Ophthalmology, Iasi
(2) University of Medicine and Pharmacy, Dept. Histology, Iasi
(3) Institute of Public Health, Iasi

Purpose Difficulties in diagnosis of a pigmented conjuctival tumor in a child.

Results To our knowledge, there have been only seven previously report cases of conjunctival malignant melanoma arising in children.Our report presents a case of 7 years-old boy that was treated in Eye Clinic of University of Medicine, Iasi, Romania for a pigmented conjunctival mass located temporally in his right eye. The history was difficult because the child is from an orphanage. After excision, imunohistochemical tests (Ac HMB 45) give the diagnosis of conjunctival malignant melanoma.

Conclusion Imunohistochemical tests are important for diagnosis of a conjunctival mass.

2347
Conjunctival Rhabdomyosarcoma

MENDEZ MC (1), BLANCO G (2), SAORNIL MA (1), SARASA JL (3), FERNANDEZ N (1)
(1) Registro de Patologia Ocular Miguel N. Burnier. Instituto Universitario de Oftalmobiologia Aplicada (IOBA), Valladolid
(2) Unidad de Oncologia y Oculoplastica. Instituto Universitario de Oftalmobiologia Aplicada (IOBA), Valladolid
(3) Departamento de Anatomía Patológica. Fundacion Jimenez Diaz., Madrid

Purpose To present a clinico-pathological correlation of an unusual case of conjunctival rhabdomyosarcoma.

Methods A 4 year-old patient with a history of fast growing (one month) nodular vascularized lesion in the caruncule of his left eye underwent to complete ocular examination and excixional biopsy.

Results Slit lamp examination showed a vascularized nodular lesion in the left eye. Otherwise ocular examination was unremarkable. Excisional biopsy showed undifferenciated cells composed of loosely coherent spindle-shaped cells, some of them with red-staining cytoplasms and a hiogh proliferative rate (60-70%). On immunohistochemistry many tumor cells showed strong reactivity with vimentine, muscle-specific actin and desmin antibodies and with anti Myo-D1. Diagnosis of embryonal rhabdomyosarcoma, botryoid type was made.

Conclusion Although rhabdomyosarcoma is the most common soft tissue sarcoma in childhood is very rare arising in conjunctiva. The initial clinical manifestation may be a non inflamed fast growing pedicle of soft tissue. Rhabdomyosarcoma should be included in the differential diagnosis of this type of conjunctival lesions.* Partially funded by grant "Jose Maria Aguilar Bartolome"

2348
Wegener`s granulomatosis confirmed after bilateral proptosis

MENDEZ MC (1), BLANCO G (2), HERRERAS JM (3), MUIñOS Y (4, 5), PIGAZO JM (6)
(1) Registro de Patologia Ocular Miguel N. Burnier. Instituto Universitario de Oftalmobiología Aplicada (IOBA)., Valladolid
(2) Unidad de Oncologia y Oculoplastica.Instituto Universitario de Oftalmobiología Aplicada (IOBA)., Valladolid
(3) Unidad de Superficie Ocular. Instituto Universitario de Oftalmobiología Aplicada (IOBA)., Valladolid
(4) Instituto Universitario de Oftalmobiología Aplicada (IOBA), Valladolid
(5) Fundacion Carolina, Madrid
(6) Registro de Patologia Ocular Miguel N. Burnier. Instituto Universitario de Oftalmobiología Aplicada (IOBA), Valladolid

Purpose To present a case of Wegener`s granulomatosis with bilateral orbital involvement and emphasize the role of the histopathological diagnosis.

Methods A 46-year old men with 10-year history of sinusal pathology, including surgery, presented with ocular inflammation, pain and diplopia. He underwent to complete ocular examination, CT Scan and systemic studies including p and c-ANCA and orbital biopsy.

Results Ocular examination showed the presence of bilateral proptosis, ophthalmoplexia in the OD and ocular motility restriction in the OS. Visual acuity was 1.o in the OD and 0.1 in the OS. The CT Scan revealed the presence of bilateral diffuse intra and extraconal masses with bone destruction and paranasal sinuses infiltration. Systemic studies were negative. Findings of the orbital biopsy were consistent with a necrotizing small vessel vasculitis with granulomatous inflammation confirming the diagnosis of Wegener`s granulomatosis.

Conclusion Wegener`s granulomatosis is a multiorganic disease that can involve the eye and adnexal structures in 50% of cases. Biopsy of the affected ocular tissues may lead to the definitive diagnosis and prompt treatment of the disease.* Partially funded by grant "Jose Maria Aguilar Bartolome"

EVER-2004-abstractbook.indd 161 8/19/04 12:27:03 PM

■ 2349

Local chemotherapy with interferon-alfa as alternative treatment to radiotherapy in conjunctival malt lymphomas

SAORNIL MA (1, 2), BLANCO G (3), MENDEZ MC (2), MUIñOS Y (4), SARASA JL (5), FERNANDEZ N (6)
(1) Unidad de Oncologia Ocular, Hospital Clinico Universitario, Valladolid
(2) Registro de Patologia Ocular Miguel N Burnier, Instituto Universitario de Oftalmobiologia Aplicada (IOBA), Valladolid
(3) Unidad de Oncologia y Oculoplastica, Instituto Universitario de Oftalmobiologia Aplicada (IOBA), Valladolid
(4) Instituto Universitario de Oftalmobiologia Aplicada (IOBA), Fundacion Carolina
(5) Servicio Anatomia Patologica, Fundacíon Jimenez Diaz, Madrid
(6) Registro de Patologia Miguel N Burnier, Instituto Universitario de Oftalmobiologia Apllicada (IOBA), Valladolid

Purpose To present two cases of conjunctival mucosa-associated lymphoid tissue lymphoma (MALT) treated with subconjunctival and/or topical interferon-alfa

Methods Two female patients with histologically proven diagnosis of conjunctival MALT lymphoma without orbital or systemic disease were treated with Interferon-alfa (Roferon-A). Patient 1: subconjunctival intralesional injection of 1.500.000 international units (IU) was given three times a week for four weeks; 1.000.000 IU three times a week for four weeks, and 1.000.000 IU once a week for four weeks, followed by topical administration in drops (Roferon 6.000.000IU/cc) until complete resolution of the lesion. Patient 2 received only topical administration. Patients were followed including complete ocular exam every three months and systemic non invasive examination yearly.

Results Complete regression was obtained in both patients: case 1 after 5 months, case 2 after 2 months. After 26months and 16 months of follow up respectively, patients did not showed local recurrence or presence of systemic lymphoma.

Conclusion Local chemotherapy with INF-alfa have shown to be an effective therapeutic alternative therapy to radiotherapy in conjunctival MALT lymphomas.*Partially funded by grant "Jose Mª Aguilar Bartolome"

■ 234a

Cavitary uveal melanoma

SAORNIL MA (1, 2), BECERRA E (3, 4), MENDEZ MC (1), BLANCO G (5), MUIÑOS Y (6, 4), PIGAZO JM (7)
(1) Registro de Patologia Ocular Miguel N Burnier, Instituto Universitario de Oftalmobiologia Aplicada (IOBA), Valladolid
(2) Unidad de Oncologia Ocular, Hospital Clinico Universitario, Valladolid
(3) Instituto Universitario de Oftalmobiologia Aplicada (IOBA), Valladolid
(4) Fundacion Carolina, Madrid
(5) Unidad de Oncologia y Oculoplastica,Instituto Universitario de Oftalmobiologia Aplicada (IOBA), Valladolid
(6) Insituto Universitario de Oftalmobiologia Aplicada (IOBA), Valladolid
(7) Registro de Patologia Miguel N Burnier, Instituto Universitario de Oftalmobiologia Apllicada (IOBA), Valladolid

Purpose To present an unusual case of cavitary choroidal melanoma

Methods Ocular examination including ophthalmoscopy, B-scan ultrasound, Computed tomography, Magnetic resonance, microscopic and immunohistochemical studies are performed in a 38 year-old-female with decreased vision in the left eye.

Results Ocular exam showed cataract and extensive retinal detachment. B-scan ultrasound revealed a posterior choroidal tumor with intratumoral cavitation. CT scan and MR disclosed retinal detachment over a round choroidal tumor without extraocular extension. Systemic studies were negative for metastatic disease and other unkown primary tumor. Enucleation was performed and light microscopic examination and immunohistochemical studies showed a fusiform choroidal melanoma with intratumoral cavitations.

Conclusion Cavitary malignant melanomas are very rare and may represent a clinical diagnostic challenge when occur in the posterior choroid. As the present case illustrates, uveal melanoma should be included in the differential diagnosis of choroidal cavitary lesions. *Partially funded by grant "Jose Maria Aguilar Bartolomé"

■ 234b

Enophthalmos as first manifestation of systemic spread of breast adenocarcinoma

BIANCIOTTO C (1, 2), BLANCO G (3, 4), SAORNIL MA (5, 4), MENDEZ MC (6), PIGAZO JM (6)
(1) Instituto Universitario de Oftalmobiologia Aplicada (IOBA), Valladolid
(2) Fundacion Carolina, Madrid
(3) Unidad de Oncología y Oculoplastica, Instituto Universitario de Oftalmobiologia Aplicada (IOBA), Valladolid
(4) Registro de Patología Ocular Miguel Burnier, Valladolid
(5) Servicio de Oncología Ocular HCUV, Valladolid
(6) Registro de Patología Ocular Miguel Burnier, Instituto Universitario de Oftalmobiologia Aplicada (IOBA), Valladolid

Purpose To present a clinico-pathological correlation of a patient with an orbital metastasis arising 17 years after the primary breast adenocarcinoma was treated.

Methods In a patient presenting with unilateral restrictive enophthalmos and ptosis, a complete clinical examination was performed, along with imaging studies (CT scan and MRI) and a biopsy to confirm the diagnosis through inmunohistochemical stains.

Results The patient had restriction of all extraocular movements of the left eye, in addition to 3 mm of enophthalmos and an intraconal mass on the same affected side. A biopsy of the mass was carried out through the upper eyelid crease, confirming the diagnosis of metastatic breast adenocarcinoma to the orbit through inmunohistochemical stains.

Conclusion The presence of restrictive enophthalmos in a patient with a background of breast adenocarcinoma, should prompt the suspicion of an orbital metastasis. In case the enophthalmos is the only clincal finding, a biopsy is necessary to confirm the diagnosis and to initiate specific treatment.*Partially funded by grant "Jose María Aguilar Bartolomé".

■ 234c

Pleomorphic adenoma arising in an accessory lacrimal gland of Wolfring

ALYAHYA GA (1), SKJODT K (2), PRAUSE JU (1), SALINTE JP (2), HEEGAARD S (1)
(1) Eye Pathology Institute, University of Copenhagen, Copenhagen
(2) Department of Ophthalmology, Frederiksberg Hospital, Copenhagen

Purpose To report a case of pleomorphic adenoma of an accessory lacrimal gland of Wolfring in the lower lid with a 20-year history.

Methods A 62-year-old man presented with a palpable, painless, slowly growing mass at the temporal part of the right lower eyelid. The mass was excised. Histological and immunohistochemical analyses of the tumour were performed.

Results Histological examination showed many glandular elements embedded in a myxoid ground substance. The tumor was found under an area of normal lacrimal gland tissue in close association with a normal Meibomian gland. Epithelial cells and myxoid ground substance in the tumor stained strongly with antibody against GFAP (glial fibrillary acidic protein), whereas this antigen could not be identified in normal lacrimal gland tissue indicating that GFAP could be a tumour-associated antigen.

Conclusion Benign pleomorphic adenoma of the accessory lacrimal gland is exceedingly rare. This is the first reported case of pleomorphic adenoma of the accessory lacrimal gland of Wolfring in the lower lid.

EVER-2004-abstractbook.indd 162 8/19/04 12:27:03 PM

234d

Uveal melanoma as a third malignant tumour

ALJAMAL RT, KUJALA E, KIVELÄ T
Helsinki UInviversity Central Hospital, Helsinki

Purpose To report uveal melanoma as a third malignancy and to assess the frequency of such an association.

Methods Case report, database and literature review.

Results A 50-year-old female had primary breast cancer without regional lymph node metastasis resected after a positive screening mammography. It was an intraductal carcinoma (T1N0M0, grade III, hormone receptor negative, several aneuploid cell clones, high S fraction). She had no family history of cancer. She recived adjuvant radiotherapy and tamoxifen. Eight months later 2 liver and 1 pulmonary metastasis were treated with epiadriamycin. At the age of 54, years a small tumour was detected in the left kidney. With in the next 2 years it grew to 3.6 cm, and when it was removed 4 years later its size was 5.6 cm. Histopathology showed a clear cell renal carcinoma (T2N0M0, grade II). At the age of 61, while under review for glaucoma, an MRI detected an asymptomatic choroidal and ciliary body tumour. It was amelanotic, 10.4 mm by diameter and 4.4 mm thick without subretinal fluid (T2N0M0). It was also visible in a CT, taken 7 months earlier, when it was 7 mm in diameter and 3 mm thick. A through review for metastasis failed to reveal any new ones. The tumour was treated with ruthenium brachytherapy (100 Gy). At last review it had shrunken to 1.2 mm and had become rather heavily pigmented with regression. In a database of about 1000 patient at least 4 other patients with a tripple malignancy including a uveal melanoma were found (with colon and breast, bladder and biliary, glioma and thyroid, labial and lung cancer). In Medline, at least two additional patients were mentioned (with breast and ovarian, meningioma and mesothelioma).

Conclusion A triple malignancy with uveal melanoma is rare, but not necessarily a rapidly fatal association.

EVER-2004-abstractbook.indd 163 8/19/04 12:27:04 PM

2351
PAX6 and SOX2 in eye disease and development

VAN HEYNINGEN V
MRC Human Genetics, Edinburgh

Purpose PAX6 and SOX2 are transcription factors with major roles in neural cell determination and eye development. PAX6 has two DNA-binding domains: a paired domain and a paired-type homeodomain; while a high mobility group HMG-box is the DNA binding entity in SOX2. Heterozygous mutations in PAX6 and SOX2 cause developmental eye anomalies in humans. PAX6 haploinsufficiency leads to aniridia, while missense mutations are associated with a broader spectrum of variant phenotypes. The Small eye mouse, with several known Pax6 mutations, provides a good model for human disease spectrum and also allows us to investigate in considerable detail how eye development deviates from normal in both heterozygous and homozygous animals. The homozygotes die neonatally, in mice as well as in rare human cases, so mice can be studied up to E18.5. Pax6 is normally expressed throughout the developing eye, in derivatives of both the neural ectoderm and surface ectoderm. In homozygous mutant mice, eye development commences normally, but is abrogated by an abnormal interaction between the evaginating optic vesicle and the surface ectoderm. No lens placode thickening and invagination takes place, although abnormal retinal development continues for a while and optic nerve remnants are later seen in the anophthalmic embryos. Heterozygous mice show iris hypoplasia, cataracts and corneal opacities, as well as reduced overall globe size. Cataracts are also seen in humans with PAX6 mutations, sometimes present congenitally. Rare PAX6 missense mutations have been associated with severe microphthalmia which may be the result of abnormal lens development. SOX2 heterozygous loss of function mutations lead to bilateral anophthalmia or anophthalmia/microphthalmia in humans, but not in heterozygous knockout mice. All the human mutations seen so far, were shown to have arisen de novo in the affected individual. Sox2 is also expressed both in the neuroectoderm and the surface ectoderm and early lens. The patients often have optic tracts and chiasms. It is therefore again tempting to speculate that eye development is initiated and then stops. The eye and associated anomaly phenotypes seen with SOX2 mutation are variable.PAX6 and SOX2 proteins, which are co-expressed in transformed lens epithelial cell lines, were shown by the Kondoh lab to interact in regulating the chicken delta crystallin promoter. They also work synergistically to activate the mouse surface ectoderm enhancer upstream of the Pax6 gene. Natural mutations in either protein prevent the interaction with the delta crystallin element in a luciferase reporter transfection system.The full role of Pax6 and Sox2 in eye development remains to be elucidated, but it is clear that both transcription factors fulfil several distinct roles, and this functional diversity is reflected in the presence of several long range control elements regulating different spatiotemporal expression patterns. Changing function of these elements is major mechanism for evolution.

2352
Control of proliferation and differentiation in the developing retina

WITTBRODT J
EMBL, Developmental Biology Programme, Heidelberg

Purpose The vertebrate eye emerges from an epithelial Anlage by inductive interactions beginning at late gastrula stages. Under the influence of midline signalling during neurulation the single retina Anlage is split into two retinal primordia localised in the lateral wall of the prosencephalon.Subsequent evagination of the primordia results in the formation of optic vesicles that differentiate to the seven cell types of the neural retina, the retinal pigmented epithelium and the optic stalk respectively. In anamniotes, the ciliary margin of the neural retina contains a stem cell population that gives rise to all retinal cell types and facilitates live long growth of the eye.

Methods We investigate vertebrate (medaka, zebrafish) eye development following three complementary experimental strategies.Functional studies involving large scale mutagenesis screens and mutant analysis.Functional analyses involving gain- and loss-of-function analysis by ectopic expressing of transgenes in the developing eye or by blocking gene function using the morpholino knock-down technique.In vivo analysis of retinal morphogenesis and differentiation using 4D microscopy on transgenic lines stably expressing green fluorescent protein (GFP) in different substructures of the retina.

Results Here we present the role of the homedomain containing transcription factor Six3 in coordinating the balance between proliferation and differentiation in the developing and adult retina. Proliferation has been speculated to be involved in optic vesicle evagination during which the homebox protein Rx plays a key role.

Conclusion We address and and describe the genetic, molecular and cell biological basis for optic vesicle evagination in anamniotes in vivo and present a model that illustrates the process.

2353
Natural antisense transcripts (NATs) associated to genes involved in eye development

BANFI S, ALFANO G, VITIELLO C, CACCIOPPOLI C, CARAMICO T, AURICCHIO A
Telethon Institute of Genetics and Medicine (TIGEM), Naples

Purpose Natural antisense transcripts (NATs) represent an intriguing class of genes whose role in controlling gene expression is becoming more and more relevant. We decided to determine the extent of their distribution in the vicinity of transcription factor genes that play an important role in eye development and function.

Methods We carried out a bioinformatic analysis of public sequence databases, including the Mouse Genome Browser at UCSC and Expressed Sequence Tag (EST) databases to identify putative NATs associated to transcription factor genes involved in eye development.

Results We identified eight putative mouse NATs associated to eye transcription factors. These newly-identified NATs undergo extensive alternative splicing, overlap with the mature processed mRNAs or with the primary unprocessed transcript of their corresponding sense genes, and are predicted to represent either protein coding or non-coding RNAs. Expression studies, by RT-PCR and RNA in situ hybridization, demonstrate that most of these NATs, similar to their sense counterparts, display a specific or predominant expression in the retina, particularly at postnatal stages. Preliminary studies suggest that the overexpression of one of these NATs, CrxOS (Crx opposite strand), in mouse adult retina, is able to significantly decrease the expression levels of the corresponding sense gene, Crx, further suggesting that these transcripts are functionally related to their sense counterparts.

Conclusion This subgroup of NATs may play an important role in the control of the molecular mechanisms underlying eye development and function both in health and disease.

2354
Role of AP2 transcription factor in lens development

WEST-MAYS J (1), ASHERY-PADAN R (2), WILLIAMS T (3), GRUSS P, PONTORIERO GF (1)
(1) McMaster University, Ontario
(2) Tel Aviv University, Israel
(3) University of Colorado, Colorado

Purpose AP-2α KO mice exhibit severe ocular defects including disruption in lens vesicle formation. However, the phenotype in the AP-2α KO mice is complex and we can not rule out the possibility that tissue-tissue interactions have contributed to the observed defects.

Methods Our recent creation of a conditional knockout of AP-2α in the lens placode (Le-AP-2α mutant) using the Cre/LoxP approach has provided us with a model for examining the specific requirement of the AP-2α gene in early lens development.

Results Embryonic Le-AP-2α mice exhibit a persistent adhesion of the lens to the temporal cornea (lens stalk). PCNA and TUNEL staining revealed no significant alteration in Le-AP-2α mutant lenses suggesting that changes in cellular proliferation and death were not responsible for the lens stalk phenotype. Expression patterns of Pax6, FoxE3 and Pitx3, the mutations of which in mice results in a lens stalk phenotype, were also examined to determine whether they are downstream of AP-2α transcriptional regulation. Pax6, FoxE3 and Pitx3 expression was maintained in the Le-AP-2α mutant lens suggesting no role for AP-2α in feedback regulation of these genes. Since previous studies from our lab have shown a correlation between AP-2α expression with that of members of the cell adhesion molecules, the cadherins, we examined E-cadherin expression in the conditional mutants. E-cadherin expression was substantially reduced in the Le-AP-2α mutant lens.

Conclusion These findings suggest that AP-2α regulation of cell adhesion is a key event controlling separation of the lens vesicle. Whether this is due to direct loss of AP-2α binding to the E-cadherin promoter in the mutant lens will be determined using CHIP analyses. NIH EY11910 (JWM);DE-12728 (TW).

EVER-2004-abstractbook.indd 164 8/19/04 12:27:04 PM

■ 2355

Aspects of eye development regulation in the aphakia mouse

MUENSTER D (1), HORSCH M (2), DROBYSHEV AL (2), BECKERS J (2), GRAW J (1)
(1) Institute of Developmental Genetics, GSF-National Research Center for Environment and Health, Neuherberg
(2) Institute of Experimental Genetics, GSF-National Research Center for Environment and Health, Neuherberg

Purpose The mouse mutant aphakia (ak) is characterised by two deletions in the Pitx3 promoter resulting in Pitx3 loss-of-function and finally to a stop in lens and eye development. The aim of the work is a functional analysis of the Pitx3 gene.

Methods Gene expression profiles from ak and wild-type (wt) embryos during embryonic stages E9.5 - E13.5 were compared using DNA Microarray Technology. Selected results were confirmed by Real Time PCR, in situ hybridisation (ISH) and reporter gene assay.

Results 45 genes show significant differences in their expression patterns between ak and wt. Sequence alignments identified them as blood related genes (like apolipoproteins), enzymes (like ribosomal kinases) and genes involved in eye development (like crystallins). The most interesting results revealed the upregulation of Pax6 and the downregulation of AP2 in ak. Using ISH at E9.5, Pax6 shows a stronger expression in eye and nose region of ak. To test the hypothesis of a mutual regulation, we mated Pax6 -/+ and ak -/- mice, but we could not see a dose-dependent difference in the Pax6 phenotype. In a promoter assay, Pax6 activated the Pitx3 promoter.The downregulation of the transcription factor AP2 in ak at E11.5 was confirmed by ISH's, showing altered expression areas in lens and brain: AP2 expression is limited to the anterior part of the wt lens, whereas it has an even distribution in the remaining lens of ak. In the wild-type hindbrain, AP2 shows a well-defined expression, but only a diffuse one in ak.

Conclusion The loss of Pitx3 activity in the homozygous ak mutants leads to changed expression patterns of AP2 and Pax6. In the absence of Pitx3, AP2 is down-regulated. Pitx3 and Pax6 regulate one another: Pax6 activates Pitx3 which, in return, inhibits Pax6
.

EVER-2004-abstractbook.indd 165 8/19/04 12:27:04 PM

2361
Autofluorescence measurements in ARMD

FITZKE FW
Institute of Ophthalmology, University College London, London

Purpose Imaging fundus autofluorescence due to lipofuscin provides a new means of seeing abnormal changes in the retinal pigment epithelium (RPE) which are intimately related to the metabolically demanding photoreceptor outer segment renewal mechanisms. This is particularly interesting in ARMD where this may be the crucial site of pathology and since this can be easily imaged in patients allows new investigative opportunities. The findings that early abnormalities of autofluorescence can evolve into later cell death suggest that a window for intervention is possible. Further it has now been shown that cone and rod photoreceptors overlying the areas of RPE with early abnormalities of autofluorescence can still be functional. Recent developments in fundus autofluorescence imaging and its role in phenotyping age related macular degeneration will be reviewed.

2362
Multimodal macula mapping in ARMD

BERNARDES R (1), SILVA R (2)
(1) Centre of New Technologies for Medicine, AIBILI, Coimbra
(2) Ophthalmology Department, Coimbra University Hospital, AIBILI, Coimbra

Purpose To determine the location and characterization of chorioretinal lesions of patients with exudative ARMD applying multimodal macula mapping techniques.

Methods Initial observations of ARMD patients show that multimodal imaging of the macula is particularly helpful for determining relative participation of the retina and choroidal circulations in situations of suspected chorioretinal anastomoses.

Results Topographic information provided by the RLA may complement the one obtained by FA, ICG and OCT mainly in chorioretinal anastomoses.

Conclusion The process of multimodal data integration provides new insights into the changes occurring in the retina in ARMD patients and is expected to contribute to improved phenotype characterization.

2363
Electrophysiology in AMD and its relation to retinal imaging techniques

ZRENNER E (1), SCHOLL HPN (2, 1)
(1) Department of Pathophysiology of Vision and Neuroophthalmology, University Eye Hospital, Tübingen
(2) Department of Ophthalmology, University of Bonn, Bonn

Purpose To apply multifocal electroretinography (mfERG) in patients AMD in order to determine the functional significance of fundus lesions revealed by various fundus imaging techniques such as fundus autofluorescence (FAF). Very recently, it has been shown in a psychophysical study that areas of abnormal FAF in AMD have a functional correlate (Invest Ophthalmol Vis Sci. 2004;45:574-583).

Methods With the mfERG, scores of focal ERG responses can be obtained in a matter of minutes. Although this technique is relatively new, it has already provided insights into the mechanisms of retinal disease. The mfERG responses derive from relatively local regions of the retina and are comprised of the same components as the full-field ERG providing a significant diagnostic advantage to the full-field ERG. A standard for mfERG is now available (www.iscev.org).

Results Recent investigations have shown that in Stargardt macular dystrophy and AMD functional deficits can be detected that are restricted to focal areas of the posterior pole (Vision Res. 1998;38:3817-3828). In patients with Best macular dystrophy, central responses in the mfERG were significantly reduced and correlated with visual acuity loss and with funduscopic staging (Vision Res. 2002;42:1053-1061).

Conclusion The mfERG technique allows to objectively assess macular function with sufficient topographical resolution. In order to determine the functional significance of morphological abnormalities in AMD, mfERG data must be compared with data obtained by retinal imaging techniques. Such correlation between abnormalities revealed by FAF imaging and functional loss determined by the mfERG has been achieved very recently in maternal inherited diabetes and deafness (MIDD; Invest Ophthalmol Vis Sci. 2004;45:2355-2360).

2364
Challenges for clinical trials

SAHEL J (1, 2, 3)
(1) CHNO des XV-XX and Rothschild Ophthalmology Foundation, Paris
(2) Universite Paris VI and Inserm U 592, Paris
(3) Institute of Ophthalmology- UCL, London

Purpose This talk will emphasize on the importance of establishing at the European level standards and registries for the identification of cohorts of patients being enrolled in clinical trials

Methods Issues to address are, among many others- the major variations and habits and criteria used for phenotyping retinal degenerations accross Europe- the new Europaen regulations on clinical trials- the necessity to protect patient confidentiality ....

Results Within the European Vision Institute, we aim at providing a frame for clinician-scinetists willing to work colectively on these issues. The recent selection of the Integrated project : functional genomics of the retina in the FP6, provides a unique opportunity to set such standards and databases on monogenic diseases and ARMD.

Conclusion There is a need for integration and coordination at the European level of clinical research on retinal degenerations. EVI foundation represents a major step towards this objective.

EVER-2004-abstractbook.indd 166 8/19/04 12:27:05 PM

2411
Current trends in glaucoma medical therapy

HEIJL A
Dept of Ophthalmology, Malmö University Hospital, Malmö

Purpose To discuss modern trends in glaucoma medical therapy, and to suggest managment principles based oncurrent evidence of treatment effects and risk factors for progression.

Methods Short review of: a. current new trends as reflected, e.g., in the new EGS guidelines and in drug prescriptionsb. results from randomized, prospective trials, with particualr emphasis on trials with untreated controls.

Results The medical therapy of glaucoma has undergone large changes, partly as a consequence of the development of new drugs and classes of drugs, partly because of new knowledge from large, randomized, prospective trials. Some of the new drugs are more potent than those that have been previously available, yet the side effects have been mild or moderate. Controlled trials have demonstrated the effectiveness of lowering of intraocular pressure in decreasing the rate of progression of damage in patients with manifest glaucoma, or the incidence of damage in patients with ocular hypertension. Trials results have also provided new knowledge on risk factors for progression.

Conclusion In this presentation I will discuss the conclusions that can be drawn from the trials and the impact of these trials on our current thinking on glaucoma management. An effort will be made to translate the impact of our new therapeutic armamentarium and the trials results into some simple rules for practical patient management where risk factors are taken into account to provide individualized patient care. This will be illustrated by patient examples.

2412
Adjunctive options to PGA therapy

AREND O (1, 2)
(1) Augenzentrum Alsdorf, Alsdorf, Germany
(2) Augenklinik Aachen, Aachen, Germany

Purpose Glaucomatous optic neuropathy most likely represents a multifactorial disease of mechanical and vascular factors leading to glaucomatous damage. Compression due to intraocular pressure (IOP) increase and/or extracellular matrix alterations in tandem with an ischemic insult are important factors. Astrocytes are sensitive to biomechanical stress and can induce alterations of the lamina cribrosa matrix. An understanding of these factors should lead to a better medication strategies.The first choice medications (EGS 2003) include alpha agonists, betablockers, carbonic anhydrase inhibitors (CAI), and prostaglandins/prostamids. The treatment success by lowering IOP should aim reductions of peak pressure, as well as diurnal variations to reduce biomechanical stress. Prostaglandins/ prostamids proved to be most effective to lower the pressure and normalize the diurnal variations.Adjunctive therapeutic options to prostaglandins/ prostamids include beta blockers, alpha agonists and CAI. With respect to additional IOP reducing efficacy the CAI seemed most effective (O´Connor D. J. et al. Am J Ophthalmol 2002;133:836-837) in vombination to PGA therapy.Considering circulatory alterations to be important glaucoma medications should improve ocular perfusion. Until now a number of studies showed that CAI improve retinal, optic nerve head and retrobulbar circulation. In the presence of optic nerve head non perfusion diastolic perfusion pressure should not decrease below 70 mmHg (Egna Neumarkt study 2003). Therefore, the medication strategies should avoid additional hypotensive effects. In conclusion, when considering a multifactorial approach as important the therapeutic regimen should include drugs with good IOP lowering activity, minimal side effects and potential vaso/ or neuroprotective activity.

2413
Switch, add or both

GANDOLFI S
University Eye Clinic, Parma

Purpose The EGS guidelines are offering a therapeutic step-ladder according to (a) achievement of the "guess"timated target IOP and (b) efficacy of the chosen drug(s). The choice of (a) switching from one drug to another or (b) adding one drug on top of another one is based upon several factors:(a) expected efficacy(b) individual response(c) mechanism of action(d) compliance to treatmentThis presentation will discuss the most recent evidences that may help in addressing each of the above listed issues.

2414
Overview of Travoprost/Timolol Fixed Combination Phase lll Trial Results

DENIS P
Ophthalmology, Hopital Edouard Herriot, Lyon

Purpose To compare the IOP-lowering efficacy and safety of travoprost 0.004%/ timolol 0.5% fixed combination (TravTim) ophthalmic solution to either travoprost 0.004% or timolol 0.5% monotherapy or to the concomitant administration of the two compounds.

Methods In three Phase III clinical studies, 407 patients with ocular hypertension or glaucoma were randomized to receive TravTim in the morning and vehicle in the evening; 86 patients were treated with vehicle in the morning plus travoprost 0.004% in the evening; 176 patients received timolol 0.5% bid and 313 patients were treated with timolol 0.5% in the morning plus travoprost 0.004% in the evening.

Results The 3-month results showed that mean IOP reduction following treatment with TravTim was greater at all time points than either travoprost (1.1 to 2.4 mmHg) or timolol (2.0 to 3.3 mmHg) bid alone. TravTim achieved statistical superiority ($P < 0.01$) versus timolol at all time points and versus travoprost ($P < 0.05$) at all time points except the 4:00 PM time points at week 6 and month 3. The difference in IOP reduction from baseline between TravTim and travoprost at the 8 AM visits was between 2.0-2.4 mmHg. In concomitant studies, TravTim reduced IOP 6.8-9.4 mmHg compared to 7.3-9.4 mmHg with Trav+Tim and to 4.6-7.0 mmHg with timolol bid. The difference in the mean IOP reduction between TravTim and Trav+Tim was 0.0-0.3 mmHg at the 8 AM visit. TravTim combination was safe and well-tolerated.

Conclusion Administration of TravTim fixed combination reduced mean diurnal IOP more than travoprost or timolol monotherapies. TravTim solution was similar in IOP-lowering efficacy to concomitant travoprost and timolol therapy and significantly better than timolol bid alone.

EVER-2004-abstractbook.indd 167 8/19/04 12:27:05 PM

2421

Interactions between visual attention and illusory motion perception

KOZAK LR (1, 2), FORMISANO E (3), GOEBEL R (3), CASTELO-BRANCO M (1)
(1) IBILI, Center of Ophthalmology, University of Coimbra, Coimbra
(2) Institute for Psychology, Hungarian Academy of Sciences, Budapest
(3) Faculty of Psychology, Universiteit Maastricht, Maastricht

Purpose It has been proposed that enhanced activity in hMT+/V5 underlies the perception of an illusory motion aftereffect (MAE). Recent studies have however argued that this observed increase is due attention/arousal effects rather than to the perception of the MAE itself. Accordingly, it has been reported that no net increase of activity occurs in hMT+ upon MAE eliciting motion adaptation if the subjects are required to report on a motion property of the test stimulus. It has also been shown that selective attention to non-independent motion signals can have a profound effect on global motion perception. These findings raise the question whether it is possible to disentangle MAE-related activity in area hMT+ from motion specific selective attention.

Methods In order to clarify this issue, we have analyzed responses in visual area hMT/V5 to stationary test patterns under both adapting and non-adapting conditions. During non-adapting conditions the pattern-motion direction changed in every 2 seconds. The attentional task required that the subject tracked speed changes of an apparent motion stimulus superimposed on the stationary test pattern.

Results We have found strong MAEs upon adapting and no MAEs upon non-adapting (mixed motion) conditions. No clearcut difference in activity could be observed in the motion selective areas during testing upon adapting and non-adapting conditions.

Conclusion These results suggest that the net increase of activity in hMT+ occurring after motion adaptation cannot be found when attention is controlled for with a motion task that does not influence adaptation per se. Future experiments should address the possibility that a canceling effect might occur when motion adaptation and spatial attention are superimposed.

2422

Complex motion processing in schizophrenia

CASANOVA C (1), DUMBRAVA D (1), BILOTTO L (1), LACHAPELLE P (2), STIP E (3), PTITO M (1)
(1) Optometry, Universite de Montreal, Montreal
(2) Ophthalmology, McGill, Montreal
(3) Centre de recherche Fernand-Seguin, Montreal

Purpose Visual perception is altered in schizophrenic patients. Motion integration requires a local motion stage and an integration stage where selectivity to coherent motion is established. The present study aimed to identify whether or not these two stages of motion processing are differentially affected in schizophrenia.

Methods For schizophrenic (SZ) patients (n=10) and control subjects (n=12) we measured (1) the perceived plaid-defined coherent motion, a task that requires higher-order motion processing, and (2) the threshold for detecting the motion direction of simple and complex RDKs requiring both first and higher-order motion processing. The plaid (consisting of two moving gratings) can be seen as twoalternative percepts: transparency or coherency.

Results Our data indicate that these two percepts depend on the component gratings directions (plaid angle) in both tested groups. However, this angular dependency could be better described by sigmoid functions (R2 = 0.99) in the SZ group and by linear functions (R2= 0.989) in the control group, suggesting then that the processing to perceive plaid-defined coherent motion differs between SZ and non-SZ observers. Furthermore, RDKs experiments revealed that SZ patients showed elevated coherence thresholds particularly for complex RDKs (mean thresholds of 26.5 5.4% compared to 19.1 8.9% for controls).

Conclusion Overall, this ongoing study indicates that higher-order motion processing is affected in SZ. This finding is likely to be attributed to a different type of information processing in schizophrenia rather than a dysfunction of the neural networks mediating visual integration.

2423

The photopic light adaptation effect results from a gradual release of inhibition exerted on the off retinal pathway

LACHAPELLE P (1, 2), GARON M-L (3), CASANOVA C (3), RUFIANGE M (1)
(1) Ophthalmology, McGill University-Montréal Children's Hospital, Montréal
(2) School of Optometry, Université de Montréal, Montréal, Québec, Canada
(3) School of Optometry, Université de Montréal, Montréal

Purpose Cone ERGs evoked at the onset of light adaptation (after a period of dark-adaptation) show a gradual increase in amplitude (most prominent for the b-wave and OP4) which culminates after some 10-15 minutes, a phenomenon known as the Light Adaptation Effect (LAE). In order to better understand the LAE, we examined how it varied along the Photopic Hill which identifies the cone ERG luminance response function where the amplitude of the ERG b-wave first increases (Phase 1), reaches a maximum value or Vmax (Phase 2) and then gradually decreases (Phase 3) to reach a final plateau (Phase 4).

Methods Ten normal subjects aged 17 to 26 participated in this study. Photopic ERGs (background: 30 cd.m-2; intensities: –0.8 to 2.84 log cd.sec.m-2) were recorded prior (control) to and at 0 (t0) 5 (t5) and 10(t10) minutes following a 30 minutes of dark-adaptation.

Results The gain in amplitude measured for the a-wave (average: 26±8%; p>.05) did not follow a particular intensity-related trend. In contrast, that measured for the b-wave gradually increased from 25% (p>.05) measured at the onset of phase 1 to a maximum of 110%(p<.05) obtained at the beginning of phase 3 which was then followed by a return to 24% (phase 4, p>.05).

Conclusion Previous studies linked the descent of the Photopic Hill with the inhibition of the ERG OFF component. Our findings thus suggest that the powerful reduction in the amplitude of the cone ERG noted at the onset of the LAE is due to a powerful inhibition of the ERG OFF component which is prompted by the prior period of dark-adaptation and gradually released by light-adaptation. The retinal circuitry involved is yet to be determined. Supported by CIHR and Reseau Vision du FRSQ.

2424

Contributions from lateral interaction mechanisms to the human ERG

MEIGEN T, PRUEFER R, REIME S
Department of Ophthalmology, University of Wuerzburg, Wuerzburg

Purpose To separate a pure lateral interaction component (liERG) from local luminance responses in the human ERG by applying a new double frequency method.

Methods ERGs to horizontal sinusoidal gratings of 6 different spatial frequencies (0.07, 0.15, 0.30, 0.59, 1.2, and 2.4cpd) were recorded binocularly in 18 normal subjects. The gratings were modulated sinusoidally with different temporal frequencies (f1=8.3Hz and f2=6.7Hz) for neighbouring half cycles of the gratings. The Fourier components at the intermodulation frequencies f1-f2=1.7Hz and f1+f2=15Hz indicate a nonlinear interaction between the half cycles and were used to define the liERGs. The harmonics of f1 and f2 were used to estimate local flicker responses. We analysed the effect of spatial frequency on liPERG and local flicker responses by applying a repeated measures ANOVA with post-hoc Scheffé test to the corresponding Fourier magnitudes.

Results Significant liERG responses were found at f1+f2, but not at f1-f2. The liERGs were not induced by technical or stray light artefacts as validated by two control conditions. The liERG magnitude at f1+f2 increased with spatial frequency (ANOVA, p<0.0001). A similar but less pronounced low spatial frequency attenuation was found for 2f1 and 2f2.

Conclusion The new double frequency method can be used to isolate lateral interaction components in the human ERG. Significant liERGs without intrusions from local luminance flicker can be recorded mainly for higher spatial frequencies. The neural origin of the li ERGs is yet unknown, but the dissection of ERG responses in luminance and lateral interaction subcomponents may help to develop more specific electrophysiological tools for the diagnosis of retinal disorders in the future.

EVER-2004-abstractbook.indd 168 8/19/04 12:27:06 PM

■ 2425

Chromatic properties of natural scenes from hyperspectral imaging

NASCIMENTO SMC (1), FOSTER DH (2), AMANO K (2)
(1) Department of Physics, Minho University, Braga
(2) Visual & Computational Neuroscience Group, University of Manchester Institute of Science and Technology, Manchester

Purpose To investigate the chromatic properties of natural scenes by analysis of hyperspectral imaging data.

Methods A high-spatial-resolution hyperspectral imaging system was used to acquire data from natural scenes in the Minho region of Portugal. The system was a low-noise Peltier-cooled digital camera with a spatial resolution of 1344 x 1024 pixels (Hamamatsu, C4742-95-12ER) coupled with a fast-tuneable liquid-crystal filter (VariSpec, model VS-VIS2-10HC-35-SQ, Cambridge Research & Instrumentation, Inc., MA, USA) mounted in front of the lens. Spectral-radiance and spectral-reflectance functions at each pixel were estimated from white references located in the scene and calibration data from a telespectroradiometer. Images were analyzed in relation to luminance and chromaticities distributions, mean radiance and spectral reflectance, colour gamut and cone signals.

Results The colour gamut of the scenes was found to be highly constrained to a central region of the chromaticity diagram and the mean spectral reflectance was found to be non-neutral with chromaticities close to the daylight locus. Changes of cone signals due to changes in the spectral composition of daylight were found to be highly correlated for different points of scene.

Conclusion Natural scenes are chromatically more constrained than commonly assumed and their properties may be difficult to represent with synthetic psychophysical stimuli.

■ 2426

The influence of cognitive content in detecting spatial changes of the illuminant colour in real three-dimensional scenes

DE ALMEIDA VMN (1), NASCIMENTO SMC (2), FIADEIRO PT (1)
(1) Remote Sensing Unit, Department of Physics, University of Beira Interior, Covilhã
(2) Department of Physics, Gualtar Campus, University of Minho, Braga

Purpose The aim of this work was to test the influence of cognitive content of three-dimensional (3D) scenes on the ability of observers to detect spatial illuminant gradients in real 3D scenes.

Methods Observers viewed a 3D scene consisting of several coloured man-made and natural objects. The 4 scenes tested were manipulated by means of their cognitive content without changes in the physical chromatic content. Each scene subtended 10 deg of visual angle and was illuminated by a computer-driven LCD projector driven by a colour-graphics card. Light of correlated colour temperature (CCT) of 25,000 K always illuminated the left side of the scene and the right side could be illuminated by any of 6 different illuminants with CCT in the range 25,000 K–3333 K. The 6 illuminants were equally spaced in CIE 1976 (u',v') colour space with constant luminance 300 cd/m2. Spatially, the scene was therefore illuminated by a variable gradient. In each trial, observers viewed the scene for 90 sec. The task was to decide if the illuminant was uniform across the scene. There were 100 observers, who performed each a maximum of 3 trials, 1 trial per week to avoid colour-memory effects.

Results The ability of human visual system to detect a spatial illuminant gradient was affected by the cognitive content of the scene ($p = 0.001$). The cognitive content induced by scene configuration or composition was identical ($p = 0.29$), but triplicate when we combine the two.

Conclusion Although remarkably insensitive to spatial changes in the CCT of the illuminant, performances were strongly influenced by the cognitive content of the scene suggesting an important role of colour memory in colour constancy.

■ 2427 / 255

Adaptive Optics: a new in vivo in situ non-invasive method toward a high resolution image of retinal photoreceptors

SALAMA BS (1, 2, 3), GLANC MG (4), GICQUIEL JJG (1, 5, 3), LE GARGASSON JFL (6)
(1) Ophthalmology, Saint Jean d'Angély
(2) Saint Jean d'Angély, Poitiers
(3) Ophthalmology, Saintes
(4) Astronomy, Meudon
(5) Ophthalmology, Poitiers
(6) Laboratoire de Biophysique de la Vision, Paris

Purpose To expose our experience in visualizing retinal photoreceptors of human eye in vivo with a non-invasive method in order to test the difference in image resolution obtained with and without Adaptive Optics (AO).

Methods The essential component of AO system is Shack-Hartmann wavefront sensor SH. This sensor analyzes the retinal wavefront, determines its deformations, and calculates in real time the corrections to be applied on. SH output is transmitted to an adaptive optical element: the deformable mirror DM composed of 13 actuators. It cancels wavefront aberrations by applying an opposite distortion that is the exact reverse of that measured by SH. The resulting wavefront is nearly plane.

Results First subject has aberration limited eyes: with AO we obtained a sharper retinal image. The difference of retinal photoreceptors distinction with and without AO is obvious.Second subject has post radial keratotomy higher order aberrationsthat exceeded the capacity of our DM.AO increase retinal image sharpness. It may specify the pathogenesis of different macular degenerations. It may better analyze the mechanism of functional recovery failure after macular surgery.In addition, with AO we may trace photoreceptors' development and functioning during amblyopic occlusion therapy.

Conclusion AO system was already used in refractive surgery: it decreases the post-operative higher order eye aberrations, with superior post operative vision. In retinal field, obtaining a low-cost AO that could be easily integrated to different diagnostic and surgical instruments will be a great challenge to achieve remarkable progress in visual science.

■ 2428 / 256

A method of retaining LogMAR visual acuity data in a "loss-less" fashion

ANDERSON OA, FERNANDO FI, DAVIES NP
Chelsea and Westminster Hospital, London

Purpose LogMAR charts are usually scored via the chosen method at the time of reading. It is not possible to retrospectively alter the scoring method unless data is stored in a "loss-less" fashion. The purpose of the study is to design a data storage method accurately retaining LogMAR data for scoring via any method. We subsequently go on to compare data obtained by each scoring method.

Methods A simple and novel scoring grid was designed. The grid represents the LogMAR chart and allows the number of correct responses at each visual angle to be recorded. Data was recorded as a frequency of seeing curve. Twenty healthy volunteers read the LogMAR chart and the responses were recorded.

Results Three visual acuity scoring methods were performed, namely single letter scoring, line assignment, and logistic regression. Logistic regression consistently resulted in higher scores when compared to single letter scoring. Logistic regression, compared to line assignment, consistently scored higher, but only for visual acuities of less than 0.1 LogMAR.

Conclusion This 'loss-less' scoring grid provides accurate data storage, which allows choice, even at a later date, in scoring technique. This is important as visual acuity results may vary depending on the scoring methods adopted.

EVER-2004-abstractbook.indd 169 8/19/04 12:27:06 PM

2431
Ocular surface biology: lessons from the clinic

PELLEGRINI G, DI IORIO V, DE LUCA M
Laboratory of Epithelial Stem Cells, Venice

Purpose The proliferative compartment of stratified squamous epithelia consists of stem and transient amplifying (TA) keratinocytes. Human keratinocyte stem and TA cells,isolated in culture, give rise to holoclones and paraclones. Clonal evolution (generation paraclones from precursor holoclones) is promoted by the s isoform of the 14-3-3 protein family. Some polypeptides are more abundant in putative epithelial stem cells than in TA cells, but no polypeptide is able to clearly identify holoclones.

Methods We showed that the p63 transcription factor distinguishes human keratinocyte holoclones from their TA progeny. In Western blot analysis, p63 is highly expressed in holoclones, but is barely detectable in paraclones. Within the cornea, nuclear p63 is found in the basal cells of the limbus, but not in those of the corneal epithelium.

Results Here we show mutually exclusive expression of p63 and 14-3-3s in the limbus and corneal epithelium in vivo. We also show that limbal holoclones express high levels of p63 but no 14-3-3s, while corneal TA cells in culture express high levels of 14-3-3s but no p63. High levels of p63 are expressed in limbal stem cells. Only the DNp63 isoforms were detected by RT-PCR analysis on cultures established from limbal biopsies taken from freshly harvested and resting corneas. Keratinocytes with down-regulation of 14-3-3s remain in their stem cell compartment and express high levels of p63. Finally several conditions affecting the expression pattern of p63 and 14-3-3 s are shown, by immunohystochemistry and RT-PCR, in case of dehydration of donor corneas or prolonged preservation time after donor death.

Conclusion These data suggest that p63++/s-keratinocytes identify cells of the human corneal epithelium endowed with stem cell properties.

2432
Epithelial stem cells on ocular surface

MAJO F (1, 2, 3), ROCHAT A (1, 2), HOANG-XUAN T (4, 5), BARRANDON Y (1, 2)
(1) Laboratory of Stem Cells Dynamics, Swiss Federal Institute of Technology, Lausanne
(2) Department of Experimental surgery, Lausanne Medical School, Lausanne
(3) Jules Gonin Ophthalmic Hospital, Lausanne
(4) Ophthalmic Fondation A. de Rothschild, Paris
(5) Bichat-Claude Bernard Hospital Medical School, Paris

Purpose In mammals corneal stem cells thought to be localized in the limbus.

Methods Using a mouse model and a surgical approach we demonstrated that the central cornea has extension self renewal capacities in complete absence of limbus. We also demonstrated the central cornea of several mammals contains clonogenic epithelial cells with extensive self renewal capacities.

Results Those out results indicate that the central cornea of all mammals use in experimental ophthalmology can self renew.

Conclusion This implies that the corneal renewal in human may be an exception in mammals or should be revisited.

2433
Clinical significance of limbal corneal stem cells

DUA HS
Division of Ophthalmology and Visual Sciences, University of Nottingham, Nottingham

Purpose To provide an overview of the clinical significance of the corneo-scleral limbus in corneal would healing, regeneration, repair and reconstruction of the corneal surface.

Methods Review of the literature and authors own clinical and research experience.

Results The limbus has an anatomically unique architecture. Clinical observations substantiate the notion that the limbus has a special role in the physiological regeneration and repair of the corneal epithelium and in corneal epithelial wound healing. In both health and disease, centripetal migration of cells from the limbus, as columns or sheets, is characteristic. This process is highlighted and rendered 'visible' by accumulation of pigment, iron or abnormal substances and other intra cellular abnormalities. Corneal epithelial wound healing patterns differ depending on whether the limbus is intact, partially involved or totally denuded. Diseases or external insults affecting the limbals result in clinical 'limbal deficiency' leading to conjunctivalisation and vascularisation of the cornea with visual impairment. Treatment of limbal deficiency can be successfully accomplished by limbus transplantation, either directly using explants or indirectly by ex-vivo expansion of limbus derived cells on different carrier membranes. The source of limbus cells can be the unaffected other eye (auto graft) or from a living related or cadaver donor (allo graft).

Conclusion The limbus is the repository of corneal epithelial progenitor or stem cells. It acts as a barrier to conjunctival ingress on to the corneal surface. Although direct identification of limbal stem cells has yet not been achieved the success of limbal transplants in limbal deficiency provides evidence that the limbus provides the niche for such cells.

2434
Neural stem cells in the vertebrate eyes: types and regulation

AHMAD I
Ophthalmology, Omaha

Purpose Neural stem cells/progenitors have been identified in different regions of the brain, including the embryonic retina. Recently, such cells have been reported to be present, in a mitotically quiescent state, in the ciliary epithelium (CE) of the adult mammalian eye. The use of these cells for therapeutic puposes requires understanding of mechanisms that regulate their maintenance and specification.

Methods Neural stem cells/progenitors were enriched as neurospheres.

Results The proliferating cells in the embryonic retina and the mitotically quiescent cells in the adult CE may represent two distinct neural stem cells/progenitor populations. Considering their respective niche, relative self-renewal and retinal potential, the question remains, whether the latter is antecedent to the former or farther removed from the retinal lineage. Both use multiple signaling pathways for their regulation and it is likely that these pathways act in concert, complementing each other, towards the maintenance of the proliferation and uncommitted state. This is an emerging theme in the regulation of stem cells in general. For example, disparate signaling, such as those involving Wnt, FGF2, EGF and SCF, may positively influence signaling mediated by Notch, which perhaps represents the hub of regulation. Evidence is also emerging that the role of these regulators does not remain confined to the maintenance of stem cells, but they are re-employed towards different ends, as exemplified by Notch signaling that is recruited to facilitate cell differentiation and maturation.

Conclusion The next important steps, towards understanding the biology of stem cells, will be to decipher the cross-talk between the disparate signaling pathways and tease out the mechanisms underlying their context-dependent roles.

EVER-2004-abstractbook.indd 170 8/19/04 12:27:07 PM

2435

Generation of retinal neurons from mouse and human retinal stem cells

ARSENIJEVIC Y (1), ANGENIEUX B (1), MICHAULT L (2), GEHRING W (3), SCHORDERET DF (4), MUNIER FL (1)
(1) Unit of Oculogenetics Jules Gonin Eye Hospital, Lausanne
(2) Dept Cell Biology Biozentrum, Basel
(3) Dept. Cell Biology Biozentrum, Basel
(4) Institut de Recherche en Ophtalmologie, Sion

Purpose In vitro generation of retinal cells should be a promising tool to screen protective drugs and to provide an unlimited cell source for transplantation studies in different animal models. We investigated whether expanded mouse retinal stem cells (mRSCs) can produce retinal neurons in a defined medium and if such procedure can be applied on adult human RSCs.

Methods We isolated and expanded mRSCs from newborns. To induce differentiation, we transferred cells onto laminin in the presence of EGF.

Results All the cells expressed markers of undifferentiated state during cell expansion. Addition of EGF to these cells caused the expression of an early neuronal protein, b-tubulinIII, in 15% of the cells, and acquisition of mature neuronal morphology. The cells also expressed transcription factors of retinal ganglion cell such as math5 and Brn3b, as revealed by RT-PCR. However, the apparition of neurons under the stimulation of EGF was not a consequence of proliferation. Then, we analyzed whether EGF conserved its role in human cells. We isolated retinal stem cells from the pars plana and the pars plicata of adults as previously reported for mRSCs. In the presence of EGF and in absence of serum, hRSCs generated neuron-like cells with a bright soma and long processes. Nonetheless, various neuronal phenotypes were identified with the human cells after EGF incubation. Microarray characterization of the expression pattern of the human differentiated cells versus proliferating cells confirmerd the expression of specific genes related to either stem cells or differentiated cells.

Conclusion We showed that mouse RSCs can be used to identify factors implied in human retinal neurogenesis and that hRSC can generate several neuron types.

EVER-2004-abstractbook.indd 171 8/19/04 12:27:07 PM

■ 2451

Effectiveness of antioxidants against human cataract

CHYLACK LT (1, 2)
(1) Department of Ophthalmology, Harvard Medical School, Boston, MA
(2) Department of Surgery, Brigham & Women's Hospital, Boston, MA

Purpose To discuss recent data relevant to the use of oral antioxidants as means of preventing, or delaying the progression of, human age-related cataract (ARC).

Methods The Age-related Eye Disease Study, Report No. 9 (Arch Ophth, 2001), reported no apparent effect of high-dose Vit C & E on the 7-year risk of development or progression of ARC. The Roche European-American Cataract Trial (REACT) (Ophth Epid, 2002) reported a small, statistically significant decelleration of rate of development of ARC in patients on higher doses of Vits C & E than used in AREDS. Since then there has been uncertainty regarding the benefit of high-dose antioxidant vitamin supplementation as cataract treatment. Since these two publications additional reports have added important data bearing on this issue.

Results Christen WG et al. in (Arch Ophthalmol, 2003) reported that male US physicians 40-84 yrs. old given beta-carotene (50 mg on alternate days or placebo for 12 years) did not manifest any benefit or harm on the rate of cataract or cataract extraction. In current smokers at baseline, however, beta-carotene attenuated the excess risk of cataract by about one-fourth.In (Ophthalmology, 2004) McNeil JJ et al. reported that daily use for 4 years of 500 IU of natural Vit E in soybean oil encapsulated with gelatin did not reduce the incidence or progression of nuclear, cortical, or posterior subcapsular ARC. At ARVO, 2004 R. Milton presented an analysis of cataract incidence and progression in the subset of the AREDS population that used Centrum (low-dose Vit C&E) supplementation. He showed a modest beneficial effect.

Conclusion High-dose Vit C & E supplementation appears not to be an effective means of decreasing the incidence or progression rate of ARC. The effect of low-dose supplementation remains ambiguous.

■ 2452

Strategies in Cataract Prevention: Efficacy of Nutritional and Endogenously Derived Antioxidants and Metabolites

HEGDE KR (1, 2), VARMA SD (1, 2)
(1) Ophthalmology, Baltimore
(2) Biochemistry, Baltimore

Purpose Cataract is one of the most common visual disabilities of the aging eye. Several laboratories including ours demonstrate that an intraocular generation of superoxide and its derivatives (ROS) play a dominant role in its pathogenesis. One of our objectives therefore is to determine its preventability by appropriate ROS scavengers such as pyruvate and α-ketoglutarate using animal models.

Methods In one model, cataract was induced by administration of sodium selenite to rat pups. In another model cataract was induced by rendering the animals diabetic by streptozotocin. The progress of cataract was followed morphologically and biochemically, the latter by measurements of membrane transport activity and the maintenance of ATP and GSH levels.

Results Administration of keto acids prevented cataract formation in both models, apparent by better clarity of the lenses, as well as the levels of metabolites such as ATP and GSH. In diabetes, it was also demonstrable by maintenance of the active transport mechanisms. Histological aberrations including apoptosis were also prevented. The anti-apoptotic effect of pyruvate has been demonstrated for the first time.

Conclusion The results are in accordance with the hypothesis that oxidative stress plays a dominant role in the etiology of cataracts. However, in diabetes, other factors such as decline in tissue metabolism induced by high levels of sugars are also involved. The effectiveness of the keto acids is attributable not only to ROS scavenging but also to their favorable effects on tissue metabolism promoting bioenergetic processes as indexed by ATP generation. The results are considered potentially useful for further development of pharmacological strategies.

■ 2453

Prevention of ultraviolet radiation cataract

SÖDERBERG PG (1), LÖFGREN S (1), AYALA M (2, 1), DONG X (1), KAKAR M (1), MODY V (1), MEYER L (1)
(1) St. Erik's Eye Hospital, Karolinska Institutet, Stockholm
(2) Örebro University Hospital, Örebro

Purpose To review potentials for nutritional and therapeutical prevention of ultraviolet radiation (UVR) cataract

Methods The review is based on epidemiological and experimental investigations related to UVR induced cataract.

Results Most of UVR, that reaches the eye comes from the sun. Only UVR that penetrates to the crystalline lens may cause cataract. UVR hitting the lens excites primary targets and photosensitizers. Secondarily, biologically important molecules in the lens are oxidized. The oxidation leads to changes in cellular structure and function. It thus is possible to prevent UVR induced cataract by avoiding high exposure situations, especially in high risk groups. Young individuals are considerably more sensitive to UVR than old. High damage exposure patterns should be avoided. There is experimental evidence that a one time dose may be less damaging for the lens than the same dose split in two with 2-3 three days in between. Further, UVR impinging on the eye should be attenuated, either with filters or maybe with an aqueous absorber. If the UVR reaches into the eye and excites molecules, the oxidation of important biomolecules could be quenched with antioxidants. Peroral administration of antioxidants have no yet yielded strong support for anticataractous effect. Vitamin E has been shown to experimentally protect against in vivo UVR cataract. The potential for Vitamin C to protect against in vivo UVR cataract is not yet clear. If the biomolecule has already been oxidized, the only remaining option is to promote reversal of the oxidation with reduction.

Conclusion UVR induced oxidation of the crystalline lens may be prevented by avoiding high exposure, identifying high risk groups, optimizing the exposure pattern, shielding, and or use of antioxidants.

■ 2454

Vitamins E, C, REACT or Beverage and Food Antioxidants to Reduce Risk of Cataract?

TREVITHICK JR (1), PRICKETT C (1), COLLINS M (1), BANTSEEV V (2), HIRST M (3)
(1) Biochemistry, London
(2) School of Optometry, Waterloo
(3) Physiology & Pharmacology, London

Purpose To review some possible strategies for reduction of cataract risk.

Methods There are multifactorial causes involved in formation of cortical cataracts:- oxidative damage appears to be an important contributory factor at a common stage of cataract pathogenesis.

Results Antioxidants such as vitamin E or ascorbate can prevent mitochondrial damage leaking to calcium release, calpain activation, spectrin/fodrin proteolysis, and lens fiber cell globulization resulting in opacification. The prospective REACT study showed a significant risk reduction for a cocktail of mixed antioxidants including vitamins E, C, and betacarotene. Many human case-control epidemiological studies have indicated a protective role for antioxidants. Cataract risk reduction, for example, is associated with moderate consumption of alcoholic beverages, as well as of fruits and vegetables. Polyphenols and flavonols these dietary components contain are probably the protective factors. In model astronaut cataracts(radiation-induced), both Vitamin E and cell-permeable precursors of cysteine reduce risk of cataract. They may contribute by potentiating the synthesis of glutathione, the major intracellular antioxidant. Other antioxidants which show potential utility in reducing cataract risk are taurine, lutein, and zeaxanthin.

Conclusion Further studies are needed to clarify the potential contribution of antioxidants in reducing risk of cataract: in the interim several antioxidants and antioxidant cocktails such as REACT appear to be safe and potentially beneficial in reducing cataract risk.as well as risk of early cataract progression.

EVER-2004-abstractbook.indd 172 8/19/04 12:27:08 PM

■ 2455

Structural Analogs of the Sorbitol Dehydrogenase Inhibitor 4-[4-(N,N-Dimethylsulfamoyl)piperazino]-2-hydroxymethylpyrimidine Delay Diabetic Cataract Formation

KADOR P (1), INOUE J (2), BLESSING K (1)
(1) College of Pharmacy, University of Nebraska Medical Center, Omaha, Nebraska
(2) Kobe Creative Center, Senju Pharmaceutical Co., Ltd., Kobe

Purpose It is well established from experimental studies with normal and transgenic animals that diabetic cataracts are caused by the aldose reductase catalyzed accumulation of sorbitol in the lens. The accumulation of sorbitol initiates both osmotic and oxidative stress, both of which can be prevented by the administration of aldose reductase inhibitors. Furthermore, studies with sorbitol dehydrogenase deficient mice and sorbitol dehydrogenase inhibitors demonstrate that sugar cataract formation is enhanced if sorbitol is unable to be converted to fructose by sorbitol dehydrogenase. In our studies with the sorbitol dehydrogenase inhibitor 4-[4-(N,N-dimethylsulfamoyl)piperazino]-2-hydroxymethylpyrimidine (SDI-1) we have observed that SDI-1 while enhancing the initial stages of diabetic cataract formation slightly delays the formation of advanced stage of the cataract. To determine whether this apparent anti-cataract activity can be separated from sorbitol dehydrogenase inhibition, two analogs of this inhibitor have been synthesized.

Methods Two analogs of SDI-1 were synthesized according to standard procedures. In one analog, the 4-(2-hydroxymethyl)pyrimidine ring was replaced with a 4-(2,6-dimethoxy)-pyrimidine ring and in the other analog with a 2-pyrimidine ring. The two analogs were added to rat chow at a concentration of 0.6% and administered to young, streptozotocin-induced diabetic rats.

Results Neither compound, 2-[4-(N, N-dimethylsulfamoyl)piperazino]-pyrimidine or 4-[4-(N,N-dimethylsulfamoyl)piperazino]-2,6-dimethoxypyrimidine demonstrated significant sorbitol dehydrogenase or aldose reductase inhibition. Oral administration of these compounds to streptozotocin diabetic rats delayed cataract formation without reducing the levels of hyperglycemia or lens polyol.

Conclusion Cataract formation appears to be delayed in diabetic rats by a mechanisms independent of aldose reductase inhibition.

■ 2456

Modulation of the chaperone function of alpha-crystallin by dicarbonyl compounds

NAGARAJ RH
Ophthalmology, CWRU, Cleveland

Purpose Alpha-crystallin and heat shock protein 27 (Hsp27) are stress-inducible small heat shock proteins (sHSPs) in the lens. In a recent study, we demonstrated that these sHSPs become better chaperones after modification by methylglyoxal (MGO). This prompted us to investigate whether they become better anti-apoptotic proteins after modification by MGO.

Methods Human lens epithelial cells (HLE B-3) were cultured in MEM. Native and MGO-modified α-crystallin or Hsp27 were treated with BioPORTER and incubated with cells for 3 hrs in the absence of serum. Apoptosis was induced by incubating cells with 1 μM staurosporine (SP) and was measured by flow cytometry. Effect on caspase-3 activity, caspase-8 mediated activation of capase-3, formation of reactive oxygen species (ROS) and cellular glutathione (GSH) content were investigated.

Results Transfer of α-crystallin and Hsp27 offered ~17 and 20% protection against SP-induced apoptosis. Under similar conditions MGO modified α-crystallin and Hsp27 provided 36 and 23% protection. Cells treated with SP showed increased caspae-3 activity; native proteins blocked to some extent this activity, and the effect was more pronounced with MGO-modified proteins. SP-treatment resulted an increase in ROS content and a decrease in GSH content. These were mildly corrected by native proteins, but strongly by MGO-modified Hsp27. Caspase-8 mediated activation of caspase-3 was inhibited more effectively by MGO-modified α-crystallin than native α-crystallin.

Conclusion These results suggest that MGO-modification of sHSPs may provide lens with better tolerance to cope with apoptotic stresses by enhancing their ability to inhibit caspase-3 activation, reduce ROS accumulation and prevent GSH loss.

EVER-2004-abstractbook.indd 173 8/19/04 12:27:08 PM

■ 2461

Pars plana vitrectomy with intravitreal triamcinolone for diabetic macular oedema

OCKRIM ZK, HYKIN P, EZRA E, GREGOR Z
Moorfields Eye Hospital, London

Purpose The aim of this study was to determine whether pars plana vitrectomy combined with intravitreal triamcinolone reduces macular thickness and volume, as measured by optical coherence tomography (OCT) and improves visual acuity in patients with clinically significant macular oedema (CSMO)

Methods A prospective pilot study of 11 patients undergoing pars plana vitrectomy with intraocular triamcinolone for diabetic macular oedema. Inclusion criteria were patients with persistent CSMO following at least one prior macular laser treatment. Best corrected visual acuity (BCVA) in the study eye was between 19 and 59 ETDRS letters (Snellen equivalent of 3/60 and 6/18). Moderate - severe macular ischaemia and co-existing ocular disease were exclusion criteria. Patients had baseline examinations of BCVA, OCT, macular stereo photographs and fundus fluorescein angiography. Pars plana vitrectomy with intravitreal triamcinolone (4mg) performed and all patients were re-examined at 1 week, 1 month, 4months, 8 months.

Results At one month the central macular thickness had dramatically reduced, decreasing from a preoperative median of 498.5 microns (285-591) to 183 microns (160-583). At 4 months the retinal thickness had increased but did not return to baseline levels 354 microns (176-458) and this remained stable at the 8 months 304 microns (160-446). Median visual acuity improved by at least 1 line on the ETDRS chart.

Conclusion In this pilot study combined pars plana vitrectomy with intravitreal triamcinolone substantially reduces diabetic macular oedema and improves visual acuity

■ 2462

Optical Coherence Tomography Analysis Of The Macula After Successful Surgery For Retinal Detachment.

BENSON S E, SCHLOTTMAN P, CHARTERIS DG
Vitreoretinal Research Unit, Moorfields Eye Hospital, London

Purpose Optical coherence tomography assessment of persistent subretinal fluid after anatomically successful surgery for retinal detachment.

Methods Prospective recruitment of primary retinal detachment repairs with minimum three months post-operative follow-up. OCT 3000 scan of the macula was performed.

Results 52% of patients (39 of 74) who underwent scleral buckle surgery had abnormalities on OCT associated with incomplete visual recovery. Nine had a single discrete bleb of subretinal fluid, nine had multiple blebs and 13 had persistent diffuse subretinal fluid at the fovea on OCT. 11% of patients (three of 27) who underwent vitrectomy surgery for retinal detachment had subretinal fluid on OCT. Two patients had subfoveal single blebs, and one patient had diffuse subretinal fluid on OCT scan. Persistence of subretinal fluid was associated with symptoms of distortion and micropsia.

Conclusion OCT is useful in evaluating persistent subretinal fluid following anatomically successful retinal detachment surgery. Three main patterns of persistent subretinal fluid were identified on OCT: single bleb, multiple blebs, and diffuse fluid at the fovea. The results suggest that persistent subretinal fluid occurs both following vitrectomy for retinal detachment and scleral buckle surgery. The findings are a factor to consider when predicting visual recovery following retinal detachment surgery.

■ 2463

Improved Resolution Retinal Thickness Mapping Using the Stratus OCT

BERNARDES R (1), VARANDAS J (1), LOBO C (1), CUNHA-VAZ J (1, 2, 3)
(1) AIBILI - Association Biomedical Research and Innovation on Light and Image, Coimbra
(2) Center of Ophthalmology, Coimbra University Hospital, Coimbra, Portugal
(3) Faculty of Medicine, University of Coimbra, Coimbra, Portugal

Purpose To improve lateral resolution of retinal thickness maps using the Stratus Optical Coherence Tomography.

Methods Raw data from B-scans and their respective retinal thickness measurements are exported from the Stratus OCT. A data driven registration allows for the registration of the set of B-scans without the need for any fundus reference or user intervention. This registration procedure takes into account eventual saccadic eye movements.

Results The new retinal thickness maps present an increased resolution when compared to the original ones, thus allowing for a detailed mapping of the posterior pole by allowing any number of line-scans to be brought into the final retinal thickness map. This increased resolution thickness map allows therefore for a better definition of edematous areas.

Conclusion This new method for retinal thickness mapping using the Stratus OCT, offers more detailed mapping of the retinal edema and reliable measurements of the volume changes in the edema or cysts.

■ 2464

Abnormal leakage mapping using the retinal leakage analyzer

VARANDAS J (1), BERNARDES R (1), CUNHA-VAZ J (1, 2, 3)
(1) AIBILI - Association for Biomedical Research and Innovation on Light and Image, Coimbra
(2) Center of Ophthalmology, Coimbra University Hospital, Coimbra, Portugal
(3) Faculty of Medicine, University of Coimbra, Coimbra, Portugal

Purpose To earmark sites of increased retinal leakage using the Retinal Leakage Analyzer (RLA).

Methods Retinal leakage maps are obtained through the RLA using a modified Heidelberg Retina Angiograph (HRA - Heidelberg Engineering, Dossenheim, Germany). Initially two types of corrections were made: correction for different time-after-injection acquisition and correction for different gains. Making use of the above corrections, a intensity dependent threshold was established by plotting leakage vs. fundus intensity and by finding a best fit model. Leakage maps from diabetic patients were checked against these threshold values to decide whether a leakage value represents an increase in the leakage, therefore making possible to earmark both on fundus reference and on the leakage map areas of increased retinal leakage.

Results The procedures mentioned above makes possible to extract a set of new parameters from leakage maps, such as the number of clusters, their sizes as well as the average cluster size, expressed either on absolute area values or percentage of imaged area.

Conclusion Sites of increased leakage can be earmarked both on the leakage map and on fundus reference. Moreover, a number of variables indicating the severity of changes in the leakage map are made available to be correlated to other systemic variables.

EVER-2004-abstractbook.indd 174 8/19/04 12:27:09 PM

■ 2465

The Retina Thickness Analyzer as a tool to evaluate drug efficacy in nonproliferative retinopathy in type 2 diabetic subjects

NUNES S (1), BERNARDES R (1), LOBO C (1, 2, 3), CUNHA-VAZ J (1, 2, 3)
(1) AIBILI - Association Biomedical Research and Innovation on Light and Image, Coimbra
(2) Center of Ophthalmology, Coimbra University Hospital, Coimbra, Portugal
(3) Faculty of Medicine, University of Coimbra, Coimbra, Portugal

Purpose To assess the Retinal Thickness Analyzer as a methodology to evaluate in a randomized pilot study the effect of an oral drug compared to a placebo on retinal edema.

Methods Forty-eight eyes from 24 type 2 diabetic patients, age ranged from 44 to 65 years old (mean / SD: 57 / 6 years old) were followed every 3 months for a period of 9 months performing RTA at each visit. Retinal thickness performed by the RTA was analyzed by specific software developed for this purpose, consisting of 25 values of average thickness, % of increase, maximal thickness and maximal % of increase, and also the area of increase, maximal % of increase and average thickness, maximal thickness and average % over the 1DD centered on the fovea.

Results One hundred and thirty-one parameters for each RTA scan were defined in order to characterize of the retinal edema. Of these, average of the 25 values, based on the difference from baseline and values of the product maximal % of increase and area of increase showed statistically significant differences between drug and placebo (respectively $p<0.04$ and $p<0.05$).

Conclusion This study shows that the RTA analyzer, which is non-invasive and is rapidly performed, may be sensitive enough to justify its to evaluate efficacy of a drug in randomized studies. It may be concluded that the results obtained in this exploratory trial are promising and the variables analyzed, may be appropriate for comparison between drug and placebo groups.

■ 2466

Automatic establishment of macular coordinates

BAPTISTA P (1, 2), BERNARDES R (1), DIAS J (3), CUNHA-VAZ J (1, 4, 5)
(1) AIBILI - Association for Biomedical Research and Innovation on Light and Image, Coimbra
(2) ISR - Institute of Systems and Robotics, University of Coimbra, Coimbra, Portugal
(3) ISR - Institute of Systems and Robotics, University of Coimbra, Coimbra
(4) Center of Ophthalmology, Coimbra University Hospital, Coimbra, Portugal
(5) Faculty of Medicine, University of Coimbra, Coimbra, Portugal

Purpose To automatically establish retinal coordinates on high-resolution fundus images.

Methods High-resolution color fundus images (50 degrees retinographies) were taken using a Zeiss fundus camera (Carl Zeiss, Germany), with a Hiko h10 digital camera of 3192x2656 pixels. A template matching algorithm allows to determinate the center of the fovea on a multi-resolution approach. A first step to determine the optic disk (OD) center and contour consists in determining a point inside the OD. This is also achieved using a template matching algorithm. Afterwards, the brightness along a set of radial lines crossing at this point are analyzed to determine the location of the OD contour and an ellipse is fitted to that set of points that also acts as a starting point to the active contour algorithm. Based on these set of points along the OD contour, a new center of the OD is computed and a line connecting it to the center of the fovea establishes the x-axis of the macular coordinates system. This process allows to extract the scaling factor as defined by the 2 OD diameter from the center of the fovea to the OD contour.

Results These procedures were tested in a series of both normal and diseased eyes. The fovea was completely detected in all cases, while the OD detection failed on 8,7% of the cases. OD contour showed large failures in 13% of the cases while for the remaning 78,3% the detection was sucessfull. For the sucessfull cases, the RMS error was of 16,9 pixels when compared to the contour drew by a human grader on a computer monitor.

Conclusion The procedure herewith reported allows for automatic determination of the major retinal features and thus to establish absolute macular coordinates corrected for differences in scaling.

■ 2467

Optical coherence tomography in patients with achromatopsia

VARSANYI B, SOMFAI GM, FARKAS Á
2nd Department of Ophthalmology, Semmelweis University, Budapest

Purpose Congenital achromatopsia is a rare, autosomal recessively inherited disorder of the retina, caused by the lack of functioning cones. Since there is very little published data on histological changes in these cases, our aim was to examine in vivo the anatomical structure of the retina of achromats.

Methods 9 eyes of 8 patients with congenital achromatopsia and 11 eyes of 7 control subjects were examined by optical coherence tomography (OCT2). Six 6 mm radial scans were taken of the macula, centred on the fovea. Three scans in each eye were selected and the thickness of the photoreceptor layer and the inner layers of the neuroretina was manually measured at A-scans Nos. 1, 25, 50 (foveola), 75 and 100. Total macular volume and the thickness of the retina in the 9 ETDRS-regions was calculated by the built-in software of the device.(The OCT equipment used is not able to fully distinguish between the various layers of the retina. When identifying and measuring the photoreceptor layer in the OCT images, we had to take into account the literature on the subject).

Results We found statistically significant reductions in total macular volume and in the thickness of all parts of the central retina except for the foveola and the inner layer at A-scan No. 1 and 100. In these areas there was no difference between the thickness of the retina of the achromats and that of the control patients.

Conclusion The overall structure of the macula in achromats differs from that in normal subjects. Our measurements show thinning of the photoreceptor layer in the macula with the disappearance of the foveal rim. A possible reason for this could be the qualitative and/or quantitative disorder of the cone photoreceptors, but further investigation is needed.

EVER-2004-abstractbook.indd 175 8/19/04 12:27:09 PM

■ 3111

Possible functional collapse of Schlemm's canal under the influence of ciliary muscle and iris. Biomechanical considerations.

KOTLIAR KE (1), SMOLNIKOV BA (2), LANZL IM (1), KOSHITZ IN (3)
(1) Ophthalmology, Munich University of Technology, Munich
(2) Mechanics and Control Processing, State Technical University, St.Petersburg
(3) Petercom/MS Consulting group.Ltd, St.Petersburg

Purpose The geometric form of the cross-section of Schlemm's canal (SC) is influenced by the action of the ciliary muscle and iris. It might differ considerably between individuals. Consequently one can assume, that by individual variants of the drainage system structure, outflow resistance of the canal could be changed even at normal IOP level. Until now is has not been possible to prove this hypothesis in vivo. Based on mathematical modeling we attempt to estimate theoretically a possible influence of the biomechanical and biometrical parameters of the anterior chamber angle on outflow parameters of aqueous along the conventional pathway.

Methods A biomechanical model of the process was developed considering analytical solutions. Hydraulical part of the problem was modeled according to R. Moses (1979). The computer simulation was performed applying Mathlab 6.1.

Results The value and direction of the resultant muscular force of the iris and ciliary muscle relative to SC, initial width of SC and rigidity of tissues were considered to be the main model parameters. Dependences of the aqueous outflow facility through the system "SC-trabecular meshwork" on the model parameters were derived and analyzed.

Conclusion According to our theoretical estimations there is no sufficient influence of ciliary muscle and iris on the physiological outflow through SC at the normal IOP levels and average physiological dimensions of the SC. However, if the IOP increases or SC is narrow initially, the influence of the resultant muscular force relative to SC- cross-section might be enough to change conventional aqueous outflow.

■ 3112

Membrane models of aqueous humor formation

MOISEEVA IM
Institute of Mechanics, Moscow University, Moscow

Purpose An optimal aqueous flow level must be maintained for the normal functioning of the eye. The intraocular pressure is determined by the dynamic balance between the aqueous humor formation (inflow) and the drainage from the eye (outflow) through the trabecular meshwork and the uveoscleral pathways. To analyze the role of the hydrodynamic pressure in aqueous humor formation two mathematical models with different numbers of barriers between blood in the ciliary capillaries and the eye posterior chamber are developed.

Methods The models are based on the analysis of the experimental data available and represent the fluid and ions movement through the capillary wall and epithelial layers as transport processes through the equivalent membrane.

Results The models presented give a simplified mathematical description of the aqueous humor formation mechanisms and contain a number of unknown parameters. For some of them, like the membrane hydraulic conductivity, the same values as in the choroid vessels can be used. The others can be found by analyzing the experiments with animal eyes. The models can be used as a tool for the numerical simulation of the interaction between the inflow parameters, like the blood protein and solute concentrations, and the outflow parameters and for testing different hypothesis of ciliary stroma properties and outflow characteristics, which may also include a dependence on the metabolic exchange with the avascular tissues of the eye.

Conclusion The mathematical description and the numerical simulation can be used for testing different hypotheses concerning the active solute transport and the fluid drainage from the eye , estimation of passive ultrafiltration and active ion transport contribution to the aqueous humor formation and for studying the regulatory processes.

■ 3113

Biomechanical Evaluation of the Intraocular Pressure and its Deviations in Glaucomatous Eyes

ZASEEVA MV (1), SVETLOVA OV (1), SMOLNIKOV BA (2), KOSHITZ IN (3)
(1) Medical Academy of Post Graduate Education, St. Petersburg
(2) State Polytechnical University, St. Petersburg
(3) Petercom /MC Consulting Group, St. Petersburg

Purpose The important consequence of the new dynamic theory of outflow proposed by us in 2001, is the necessity to take into account age-dependent increase of the scleral rigidity , which results in the recustomizing the "sclera breathing" biomechanics. The natural age-dependent increase of the stationary "working" intraocular pressure (IOP) level occurs even in healthy eyes. Theoretical estimation of experimental results on scleral rigidity has shown, that the scleral rigidity in young healthy and glaucomatous eyes ranged between 2 and 6 MPa.

Methods According to the mentioned data we can explain the intraocular pressure jumps in healthy and glaucomatous eyes found by Kozlov (1967). For the calculations we use the formula: $\Delta D=(1-\mu)*D*\Delta P/4hE$, where h =0,6mm - scleral thickness, E - Young's modulus, μ=0,45 - Poisson's coefficient, D=24 - diameter of the eye , ΔV - the meta-volume, ΔP - corresponding changes in IOP.

Results Experimental and derived amplitudes of the IOP change:
Young's modulus, MPa....2,0(normal) ...|. 4,5(preglaukoma)..|. 6,0(glaucoma)ΔP. mmHg (experiment)...2,1 +/- 1,6...|.....3,4 +/- 2,7.....|...5,3 +/- 3,7ΔP, mm Hg (calculated)....2,5 +/- 0,75.|.....5,1 +/- 1,5.....|...7,5 +/- 2,5

Conclusion Less rigid scleral shell of a normal eye (2 MPa) deforms more than more rigid scleral shell of glaucomatous eye (6 MPa), when being inflated to an additional meta -volume ΔV. This results theoretically from the mentioned formula and coincides with the clinical data. Reduced scleral "sensitivity" to changes of the internal volume of the eye leads to IOP -disbalance, and consequently to the IOP-increase.

■ 3114

Age related changes of elastic properties of the sclera in human eyes

SVETLOVA OV (1), ZASEEVA MV (1), SOURJIKOV AV (2), SHLIKHAEV SV (3)
(1) Ophthalmology, Medical Academy of Postgraduate Education, St. Petersburg
(2) Polytechnic University, St. Petersburg
(3) St.Petersburg Branch of the Fedorov Eye Microsurgery Center, St. Petersburg

Purpose Even now, there is no unified standpoint, concerning pathogenesis of glaucoma (elevated intraocular pressure, which causes blindness). A glaucoma theory that we created is based on mechanism of sclera ageing, which is essential in glaucoma pathogenesis (Svetlova, 2001). In the result of sclera ageing its rigidity increases causing corresponding intraocular pressure rise. This is primary mechanical issue of intraocular pressure growing (Zatulina, 1987). We also consider it as a cause of age related intraocular pressure increase in healthy eye because sclera becomes more rigid with an age.

Methods Necessary caculations were made on the base of the shell theory

Results According to our calculations process of sclera getting thinner in different areas under the influence of increasing intraocular pressure rates 3-7% every decade since the age of 45 years in healthy eyes. This value meets an experimental one (Zatulina, 1987, 1976). Second by relevance and physiological by nature, the reason of IOP elevation is the development of age related far sightedness and reverse (horizontal) astigmatism. These disorders make ciliary muscle work harder and harder (causing it to fatigue), which increases aqueous humor production rate. Obviously, this leads to intraocular pressure increase as well.

Conclusion Preliminary results of our research show that intraocular pressure increase due to abnormalities of refraction can reach up to 5-8 mmHg depending on sclera rigidity, which plays its part in making sclera thinner. Definitely, it must be considered when planning refraction surgeries on sclera and cornea in order to avoid long-term negative consequences.

EVER-2004-abstractbook.indd 176 8/19/04 12:27:10 PM

■ 3115

Improving Elastic and Tensile Properties of the Sclera by UVA and Riboflavin Treatment

IOMDINA EN (1), WOLLENSAK G (2), MUKHAMEDJAROW F (3), SPOERL E (3)
(1) Helmholtz Research Institute of Eye Diseases, Moscow
(2) Berlin Eye Clinic, Berlin
(3) Dresden Eye Clinic, Dresden

Purpose A reduction in the level of scleral cross linkage is an important factor of the derangement of supportive properties of the sclera in progressive myopia. Purpose: to develop an adequate technique of increasing biomechanical stability of the sclera with the help of UVA and riboflavin (used as photosensitizer agent) treatment.

Methods Sclera of 4 porcine eyes and 6 eyes of Chinchilla rabbits were treated with riboflavin and irradiated with UVA using two double UVA diodes (370 nm, 3 mW/cm2) for 45 minutes (rabbit eyes were treated in vivo). After treatment, the scleral samples were mechanically tested using a microcomputer-controlled biomaterial tester MINIMAT 2000. The rupture load, tensile strength, the Young´s modulus and the ultimate deformation of the samples were measured or calculated.

Results As a result of the treatment, Young´s modulus of porcine sclera showed an average increase of 15%, the tensile strength grew 2.4 times, and the rupturing load increased by 3.5 times. A comparison of the biomechanical parameters of experimental and intact (control) samples of rabbit sclera shows that significant changes occurred in all the characteristics tested. The rupturing load increased by 164% (P=0.04), the tensile strength by 228% (P=0.01), Young´s modulus by 465% (P=0.02), and the extensibility showed a decrease by 179% (P=0.04).

Conclusion The proposed method of sclera reinforcement enables a substantial improvement of the stress-strain parameters of the sclera. Since the treatment brings about the formation of a more stable internal structure of the sclera, it becomes possible to create an entirely new and promising technique of prevention and treatment of progressive myopia.

■ 3116

Change in optical refraction after scleral buckling - a biomechanical model

LANZL IM (1), BAUER SM (2), KOTLIAR KE (1), MAIER M (1)
(1) Ophthalmology, Munich University of Technology, Munich
(2) St. Petersburg State University, St. Petersburg

Purpose Scleral buckling and encircling band are surgical procedures to treat retinal detachment. Especially the encircling band leads to elongation of the optical axis and ensuing changes in refraction. We applied mathematical modeling to describe the effects on globe deformation and refraction after encircling band surgery. Goal of the model is to better predict post surgical refractive outcomes.

Methods A biomechanical model of the process was developed applying principles described by A. Mironov & S. Bauer (2002). The numerical simulation was performed applying Mathlab 6.1.

Results Analysing the stress-strain state of the eye shell, the shell deformation consists of several elements, namely the displacement of scleral components according to scleral rigidity, position and force of the encircling band and presence or absence of vitreous. The ensuing deformation defines the change in axial length, corneal curvature and thus refraction.

Conclusion According to our theoretical estimations refractive change after encircling band surgery depends on factors defined by the individual eye such as scleral rigidity and surgeon defined factors such as placement of the band in relation to globe equator and encircling band diameter.

■ 3117

Static analysis of the crystalline lens accommodation

ISPOLOVA EA (1), SMOLNIKOV BA (2), SVETLOVA OV (3), KOSHITZ IN (4)
(1) Department of Mechanics and Control Processing, Saint-Petersburg State Polytechnical University, St. Petersburg
(2) Department of Mechanics and Control Processing, Saint-Petersburg State Polytechnical University,, St. Petersburg
(3) Department of Ophthalmology, Medical Academy of Postgraduate Education, St. Petersburg
(4) "Petercom/MS Consulting group" Cl.corp., St. Petersburg

Purpose The purpose of the present work is the development of some biomechanical models of the crystalline lens accommodation, taking into consideration the modern data on a structure and functioning of the human eye, and also their possible analysis and comparison.

Methods It was constructed different models: structural (plane and axisymmetrical), optical and computer model using the Finite Element Method (FEM).

Results The model of lens accommodation in which optical and mechanical properties are taken into account has been considered. Thus, it was possible to connect optical and mechanical characteristics of the eye at the lens accommodation, and to derive the dependence of the optical power of the eye on zonular forces. At the modeling a forward surface of the crystalline lens capsule by various environments of the second order rotation, it was found out, that a hyperboloid has the minimal value of internal pressure and the minimal range of change of zonular forces to maintain the necessary range of change of the optical power of the eye. The parameters of accommodation received at FEM, correspond to the data available in the literature. The FEM model confirms the important role of the vitreous during accommodation.

Conclusion For the analytical models the formulas describing geometry of the crystalline lens depending on parameters have been derived. On the basis of the deduced dependences of the optical power of the eye on zonular forces we found that a substantial increase of the sensitivity of the optical power of the eye to the change of the zonular forces is established at the maximum of accommodation. The constructed FEM model possesses the high adequacy. All the models developed during this research confirm the Helmholtz's theory of accommodation.

■ 3118

Quantitative biomechanical estimation of functional ambits in the main and additional mechanisms of eye accommodation

KOSHITZ IN (1), KOTLIAR KE (2), SVETLOVA OV (3)
(1) Petercom/MS Consulting Group Ltd, St. Petersburg
(2) Ophthalmology, Munich University of Technology, Munich
(3) Ophthalmology, Medical Academy of Postgraduate Education, St. Petersburg

Purpose In human eye there are several extraocular and intraocular accommodation mechanisms. Since the accommodation theory is still incomplete in ophthalmology, the ranking contribution of all existing mechanisms of the accommodation in the process of changing of eye refraction should be quantitatively evaluated.

Methods On the base of physical optics and biomechanics the contribution of each accommodation mechanism in the physiological change of eye refraction was theoretically estimated for young healthy eyes. The corresponding mechanisms were ranked by their contribution in the process of the accommodation.

Results The main contribution is made by the mechanism of lens rounding (Helmholtz, 1855). 8-13 dpt of accommodation amplitude in young healthy eyes. The second by its effectiveness is the mechanism of pupil narrowing: 0,7-1,5 dpt. Mechanism of lens capsule antero-posterior movement: 0,5-1,3 dpt. Mechanism of changing of corneal curvature during accommodation: 0,2-1,3 dpt. Newly discovered mechanism of "stationary retina positioning" changes the choroid blood satiation, which actually alters the tonus of ciliary muscle: 0,1-1,0 dpt. Mechanism of the influence of extraocular muscles: 0,3-0,9 dpt. Mechanism of local antero-posterior movement of the retina: 0,2-0,5 dpt. Mechanism of luminous energy reduction by narrowing the lid: 0,2-0,5 dpt.

Conclusion Applying biomechanics and physical optics principles allowed us to offer a new interpretation of Helmholtz theory as well as to find out the effective ways to investigate the ergonomics of the eye as a biological detection system. This is especially important for the development of robotics.

EVER-2004-abstractbook.indd 177 8/19/04 12:27:11 PM

■ 3121

OCT in daily management: comparison with FA in analysis of leakage in subfoveal CNV.

VERBRAAK FD (1, 2), VAN VELTHOVEN MEJ (3), SCHLINGEMANN RO (2), MAGNANI M (4), DE SMET MD (2)
(1) Laser Center, Amsterdam
(2) Ophthalmology, Amsterdam
(3) Opthalmology, Amsterdam
(4) Opthalmology, Bologna

Purpose The interpretation of FA following PDT treatment of AMD patients with subfoveal CNV to decide whether to retreat a patient or not is sometimes difficult. The differentation between leakage or staining is ambiguous, especially following several PDT treatments. OCT allows for a more objective measurement of leakage reulting in a thickened retina and/or intra - or subretinal fluid accumulations. We have have compared OCT and FA analysis for the presence of leakage in AMD patients with subfoveal CNV treated with PDT.

Methods Twentyfive patients were analysed. OCT was performed immediately before FA in all patients. The FA was interpreted by 3 observers and analysed for the presence of leakage or no leakage. The OCT was interpreted by 2 observers and analysed for the presence of thickened retina, subretinal fluid, intraretinal fluid, or fibrosis. The agreement between observers and between FA an OCT were analysed with the use of kappa (SSPS 11.5).

Results Agreement between the 3 different observers in interpretation of FA was poor to moderate (κ between 0.05, and 0.57). The agreement between the 2 OCT observers was much better (κ between 0.59, and 0.93) for the presence of leakage phenomena. As could be expected the agreement between FA and OCT for the overall presence of leakage was also poor ($\kappa = 0.294$).

Conclusion The very poor agreement in the interpretation of FA between different observers underscores the difficulty in the differentiation between staining and leakage in patients following PDT treament. The much better agreement in the OCT interpretation could perhaps improve decision making in the treatment of these patients.

■ 3122

OCT in clinical research in diabetes

PEREIRA FIGUEIRA J, BERNARDES R, CUNHA-VAZ J
Department of Ophthalmology, University Coimbra Hospital, Coimbra

Purpose To assess the importance of increased resolution of retinal thickness map based on Stratus OCT in diabetic clinical research.

Methods New thickness map were obtained by developed software using raw data provided by the Stratus OCT. This software takes into account positional differences as well as eventual saccadic eye movements, thus correcting for these sources of errors relatively to the original mapping system. Moreover, more scans can be brought into the final map covering specific areas of interest as defined by clinical evaluation. This technique was applied to diabetic patients at different stages of diabetic retinopathy.

Results This new system provides better resolution and therefore allows a better follow-up of retinal thickness in a series of patients with diabetic macula edema.

Conclusion This system seems to be useful to test new therapies for diabetic maculaedema.

■ 3123

Errors and misinterpretations of OCT examination

HAOUCHINE B
Hopital Lariboisière, Université Paris VII, Paris

Purpose OCT imaging is a dynamic form of examination of the fundus. The images seen on the monitor during an OCT examination may vary, depending on the eye movements or eye fixation. The orientation and location of the scans will also give different profiles for the same lesion. It is therefore often hazardous to base a diagnosis on a single scan, as it might not be representative of the entire lesion. Familiarity with retinal, and especially macular pathology, is essential to obtain the correct diagnosis with OCT. Understanding the genesis of artifacts encountered during OCT examination can avoid misinterpretation and aid diagnosis. OCT may be falsely interpreted in several retinal pathologies such as macular holes, lamellar macular holes and choroidal newvessels. OCT certainly constitutes a major improvement in retinal imaging, and provides many new and exciting images. However, the recording of these images requires some knowledge of the retinal diseases suspected, and their appearance in the fundus must be examined.

■ 3124

Media opacities and their effect on the OCT signal and interpretation

VAN VELTHOVEN MEJ (1), VAN DER LINDEN MH (1), FABER D (2), VERBRAAK FD (1, 2), DE SMET MD (1)
(1) AMC - Ophthalmology, Amsterdam
(2) AMC - Laser Center, Amsterdam

Purpose Optical Coherence Tomography (OCT) is a quantitative, non-invasive method to measure retinal thickness and to evaluate retinal morphology. The StratusOCT uses an SLD with a central wavelength of 820nm. Media opacities are presumed to negatively influence the quality of the obtained images. In this study we focused on patients undergoing cataract surgery to measure the influence of lens opacities on the OCT image quality.

Methods Thirty patients at the AMC (Amsterdam) were scanned with the StratusOCT, before and after cataract surgery. Both the fast - (FMT) and macular thickness (MT) protocol were used. Preoperatively the cataract was classified by an independent observer using LOCS III. The Signal-to-Noise Ratio (SNR) was used as a measure for quality of the OCT scan (SNR > 25 dB = good quality). Differences in retinal thickness before and after surgery were analysed, as well as differences between the two scanning protocols.

Results In one patient no preoperative scan could be obtained. In two patients the SNR was < 25dB. There were 12 nuclear, 10 cortical and 7 posterior capsular cataracts. SNR was overall significantly better postoperatively ($p<0.001$). In general, SNR was inversely related to the severity of the cataract. Posterior capsular and cortical cataracts affected the SNR more than nuclear cataract. The MT protocol showed an significant increase in retinal thickness postoperatively ($p=0.028$).

Conclusion In conclusion, even in patients with moderate to severe cataract a reliable analysis of the macular area with OCT is possible. In only a few patients the measurements are unreliable. It is however necessary to evaluate the individual OCT scans also, as poorer image quality can influence the software analysis.

EVER-2004-abstractbook.indd 178 8/19/04 12:27:11 PM

■ 3125

Pattern recognition in multiplanar OCT

ROSEN R (1, 2), PODOLEANU A Gh (3, 1, 2), GARCIA P M (1, 2), WEITZ R (4)
(1) The New York Eye and Ear Infirmary, New York
(2) New York Medical College, Valhalla, NY
(3) Applied Optics Group, Department of Physics, Univ of Kent, Canterbury
(4) Ophthalmic Technologies Inc, Toronto

Purpose The multiplanar OCT Ophthalmoscope (Ophthalmic Technologies, Inc., Toronto, Canada and University of Kent, Canterbury, UK) acquires simultaneous coronal(C scan) OCT and confocal images permitting precise correlation of retinal surface features with subsurface anatomy. in the living eye. C-scan OCT images are challenging at first glance because they reveal details of inner retinal structure that until now has only been looked at in cross-section or B-scan perspective. This study was a first attempt to sytematically interpret these images utilizing pattern recognition, computer simulation, and histologic correlation.

Methods Imaging sequences acquired with the OCT Ophthalmoscope were reviewed and correlated with clinical records. Individual images were examined looking at specific features and interpreted based upon general patterns of appearance. Eyes with similar scans were reviewed to establish shared sources of anatomic variation.

Results More than 1500 eyes of 800 patients with macular pathologies were studied. Specific artifacts and unique patterns were identified for a variety clinical entities. Computer and histologic models were helpful in training physicans to interpret scans and understand spatial distortion of anatomic relationships within the images.

Conclusion Muliplanar C-scan OCT imaging offers exciting new perspectives on a variety retinal pathologies. Clinical utility of this technology will depend upon recognition of identifiable patterns and artifacts to facilitate integration of image data into accepted classification schema.

■ 3126

Software assisted overlay of OCT C-scans and conventional angiography

DE SMET M (1), VERBRAAK FD (1), VAN VELTHOVEN MEJ (1), DE VOS K (2), POOL CW (2)
(1) Department of Ophthalmology, Academic Medical Center, University of Amsterdam, Amsterdam
(2) The Netherlands Institute for Brain Research, Amsterdam

Purpose Confocal images with a high transversal resolution (20µm) can be used to make a precise overly with angiographic images (FAG, ICG) using the vasculature of the retina as reference. Given the pixel-to-pixel correspondence of the confocal image with the OCT image on the OCT Ophthalmoscope, a direct correlation of the angiographic image with the transversal OCT is possible.

Methods Images from patients with a variety of pathologies on OCT in whom either FAG or ICG was performed were processed to produce overlays. Custom software was used to find a spatial transformation of the angiogram to the confocal image. Using the retinal vasculatrue, four to six pairs of reference points were manually chosen, and used to compute a least squares linear transformation.

Results In some patients with chronic CSR, the difference between window defects, staining and leakage on FAG was difficult to make. This was clearly visible on OCT. The site of leakage within a retinal angiomatous proliferation was also clearly visible.

Conclusion Overlay between OCT C-Scans and the angiograms improves the interpretation of both the angiogram as well as the OCT. The overlay technique is useful in interpreting complex central macular pathology.

EVER-2004-abstractbook.indd 179 8/19/04 12:27:12 PM

■ 3131

A cross-sectional survey of the medical indications for and performance of Scleral Contact Lens Wear in the Netherlands

VISSER ES (1), VISSER R (1), VAN LIER HJJ (2), OT'TEN HM (1)
(1) Visser Contactlenzen Praktijk, Nijmegen
(2) Universitair Medisch Centrum St. Radboud, Nijmegen

Purpose The main purpose of this study is to evaluate the indications for, and performance of scleral lenses in eyes of patients attending the clinics of Visser Contactlenzen Praktijk. A second aim is to compare the performance of the regular scleral lens and the toric designs.

Methods In this cross-sectional survey the first follow-up visit of the candidates during the 5 months study period was used to collect all data. Four scleral lens types were defined: regular, front toric, toric rear haptic surface and bi-toric. All scleral lenses were fitted following the preformed fitting technique developed at Visser Contactlenzen Praktijk. They were cut by Sub Micron Lathing out of a Boston Equalens II blank at Procornea.

Results Most of the 178 patients (284 eyes) were diagnosed with keratoconus (143 eyes, 50.4%) followed by PKP (56 eyes, 19.7%). The remaining diagnosis groups were irregular astigmatism, keratitis sicca, corneal dystrophy and multiple diagnoses. A grade of 3 or more (median 4, range 1-5) was scored by patient interview in 98.9% for comfort, in 97.9% for visual quality and in 98.9% for overall satisfaction with the present scleral lens. A significant increase from regular to toric scleral lenses was demonstrated for the three topics (Signed Rank test, all $p<0.001$, n= 99 eyes).The questionnaire revealed median ratings of 75 to 87.5 for eight topics on a one to 100 visual analogue scale.

Conclusion Scleral lenses can be used successfully in several forms of ocular pathology. This success is confirmed by results of the examination and reports by patients. Differences in the performance of the four types of scleral lenses were shown by patient interview in favor of the toric designs.

■ 3132

Therapeutic applications of contact lenses

JACKSON AJ
Contact Lens Clinic, Department of Ophthalmology, Royal Group of Hospitals, Belfast

Purpose To provide an overview of the indications for, and complications associated with, a range of therapeutic contact lenses used in the management of anterior segment disease.

Methods Using material gleaned from a comprehensive literature review on the subject, and from 20 years' experience of having fitted and monitored therapeutic contact lens performance, the presenter will highlight developments in this field. The presentation will illustrate how a range of corneal pathologies including recurrent erosion syndrome, bullous keratopathy and Thygesons Superficial Punctate Keratitis can be successfully treated using therapeutic lenses. The presentation will also illustrate how lenses can be used to alleviate pain, promote healing and to provide protection in cases involving both corneal and lid related pathology.

Results Using the results from a number of studies, into the effectiveness of therapeutic contact lens usage, the presenter will illustrate how decisions can be made as to which cases are most appropriate for treatment. Indications for fitting will be developed and guidance as to when to use various types of lenses given. An overview of potential complications will be presented and comments on the management of the management of these complications made. Participants will be encouraged to think beyond the "One Size Fits All" mentality and to embark on the process of therapeutic contact lens fitting with cautious optimism.

Conclusion Those present at the seminar should gain an insight as to when and how to fit therapeutic bandage contact lenses. Participants should also gain an understanding as to how best to manage contact lens related complications.

■ 3133

Visual rehabilitation after corneal grafting: what types of contact lenses are chosen?

GEERARDS AJM
The Rotterdam Eye Hospital, Rotterdam

Purpose To describe the problems encountered after corneal grafting concerning visual rehabilitation with contact lenses for the last ten years

Methods Retrospective series, with patients operated in the Rotterdam Eye Hospital in the Netherlands for a corneal graft with a comparisonbetween 257 patients operated for Fuchs and 190 patients operated for keratoconus. Main outcome measures are best corrected visual acuity, tolerance of the contact lens, type of contact lens, time of fitting after the operation, complications of the contact lenses regarding the graft.

Results Comparison is made between 257 patients, grafted for Fuchs, and 190 patients grafted for Keratoconus. Of the first group, 135 and of the second group 90 patients were fitted with contact lenses. (53 %, 47.4 %)Keratoconus and Fuchs patients started with lensen after 8.5 and 7.9 months, respectively. BCVA in the keratoconus group is 20/25, in the Fuchs group 20/32. Tolerance in hours wearing time was less in Fuchs patients compared to keratoconus patients and Fuchs patients stopped wearing lenses significantly more often. There was no difference in graft rejection rate between the two groups. There were more fits of semi scleral lenses in keratoconic patients compared to Fuchs patients.

Conclusion Visual rehabilitation with contact lensen in grafted patients is a worthwile effort as significant improvement in visual acuity can be reached. Careful fitting with regard to the status of the graft and regular follow up is needed tp prevent serious complications and to motivate the patient.

■ 3134

Contact lens related ulcerations in Belgium. Trends over a seven year period

KOPPEN C (1), VERHELST D (2)
(1) Dep. Ophthalmology, Antwerp
(2) Dep. Ophtalmology, Antwerp

Purpose Retrospective analysis of the files of patients hospitalised for contact lens related corneal ulceration in the 8 Belgian university hospitals from 1997 up to 2003 included.

Methods Case series study of 105 files of patients hospitalised for contact lens related ulceration; the files were retraced, using the ICD-9 codes (370.0 to 370.55) for corneal ulceration and were checked individually to sort out any ulcerations unrelated to contact lenses.

Results The number of cases has been increasing over the years :

1997	5 cases
1998	9
1999	12
2000	17
2001	22
2002	18
2003	22

Soft contact lenses were involved most frequently (90%), most often planned replacement lenses, the most popular mode of lens wear in Belgium. In 2000 there was 1 case of ulceration associated with daily disposable lenses, in 2003 two cases !The typical hospital case is that of a patient with a central, sight-threatening ulceration, caused by Pseudomonas or other Gram negative bacteria (82%). Acanthamoeba is responsible for 17 out of the 105 cases.Full results on the residual loss of visual acuity will be presented at the conference, but we already know for certain that at least 16 eyes underwent penetrating keratoplasty and 1 eye had to be eviscerated.

Conclusion One of the more striking results is the fact that the numbers of serious contact lens related ulcerations are going up in the course of the years. Recently a study by FADICON (Belgian association of contact lens distributors) has estimated that the number of contact lens wearers has increased from 3,5 % to 6,5%. Even then the fact remains, that despite advances in contact lens materials, modes of lens wear and new care systems, the problem of vision threatening corneal ulcerations has not been resolved.

EVER-2004-abstractbook.indd 180 8/19/04 12:27:12 PM

■ 3141

Melanopsin-Containing Retinal Ganglion Cells: Novel Photoreceptors Involved in Pupillary Light Reflex

HATTAR S (1), LUCAS RJ (2)
(1) Neuroscience, Baltimore
(2) Biological Sciences, Manchester

Purpose In the mammalian retina, a small subset of retinal ganglion cells (RGCs) are intrinsically photosensitive, express an opsin-like protein melanopsin, and project to the olivary pretectal nucleus in the brain which is important for pupillary light reflex (PLR) (Hattar et al., Science 295, 2002). These photoreceptors are unable to intrinsically respond to light in the absence of melanopsin. We investigated the role of these photoreceptors and the classical photoreceptors rods and cones in PLR.

Methods In mice with the melanopsin gene ablated, we determined the role of the melanopsin-containing RGCs in PLR by measuring the response to an adirectional light stimulus. Light was provided by a PT1 Xenon arc-lamp and transmitted via a liquid light-guide to a diffusing sphere. An adult mouse, dark adapted and unanesthetized, was positioned with the help of an infrared image-converter such that one eye was situated at the exit of the sphere and the other eye was in focus to a CCD camera fitted with a 10X macro lens. Illumination of the videoed eye was with infrared LEDs.

Results The melanopsin knockout animals showed a pupillary light reflex indistinguishable from that of wildtype at low light irradiances, but at high irradiances the reflex was attenuated. Rod and cone phototransduction disabled animals showed normal pupil responses at high irradiances but their sensitivity was highly compromised at low irradiances. Finally, animals that are lacking melanopsin coupled with disabled rod and cone phototransduction mechanisms essentially showed no pupillary light reflex.

Conclusion The rod, cone and melanopsin cells are the only independent photoreceptors responsible for driving the PLR and these photoreceptors are complementary in function.

■ 3142

The Hemifield Pupil Response in Patients with a Unilateral Optic Tract Lesion: Implications for the Tectal RAPD

KAWASAKI A (1), KARDON R (2, 3)
(1) Neuro-ophthalmology, Lausanne
(2) Ophthalmology, Iowa City
(3) Visual Sciences, Iowa City

Purpose The presence of a relative afferent pupillary defect (RAPD) without visual field loss in patients with a midbrain lesion is presumed to reflect injury to the afferent pupillomotor fibers distal to their separation from visual fibers near their synapse in the pretectal nuclei.The purpose of this study was to better understand the pupillometric features of these "tectal" RAPDs.

Methods The pupillomotor sensitivity of the full field, nasal, and temporal hemifield was studied using computerized pupillometry as a function of stimulus light intensity in patients with optic tract lesions with homonymous visual field loss and in patients with midbrain lesions without visual field loss who demonstrated a clinical RAPD. The pupillographic RAPD and the pupil contraction amplitude for the different stimulus conditions were recorded and ratio comparisons were made between nasal and temporal hemifields.

Results From the patients with an optic tract lesion, the estimated decussation of the temporal hemifield ranged from 57% to 61%. Individual differences in the properties of the stimulus-response curves (hemifield and full-field) of the pupil response were found among patients. The patients with tectal RAPDs showed nasal-temporal asymmetry of pupillomotor sensitivity, similar to the patients with optic tract lesions, but without visual field loss.

Conclusion The presence of an RAPD associated with optic tract and tectal lesions derives from an asymmetric distribution of the afferent pupillomotor fibers between the nasal and temporal hemifields but the magnitude of RAPD is due to the inherent stimulus-response properties of the hemifields of any given individual.

■ 3143

The fear-inhibited light reflex: The pupil as a test-system in Anxiety research

BITSIOS P
Psychiatry, Medical School, University of Crete, Heraklion

Purpose It has been shown that the amplitude of the pupillary light reflex is reduced when the light stimulus is presented in the presence of a cue (e.g. a tone) that has been previously associated with an electric shock. This phenomenon was termed "fear-inhibited light reflex" and the threat-induced decrease in light reflex response amplitude was proposed as a potential laboratory model for human anxiety. Studies with the fear-inhibited light reflex have uniformly employed a standardised light intensity, the association of the conditioning stimulus (CS) to threat of shock and have always assumed that the CS has no effect on its own. To test these assumptions, we have examined how the various parameters affect the mediation of the fear-inhibited light reflex.

Methods We measured the light reflexes of 16 healthy male participants across 4 light intensities, either in the presence of the CS alone, or when associated with the threat of either an electric shock or an acoustic sound blast. Pupil diameter was monitored with an infrared TV pupillometer.

Results The presence of the CS alone did not affect the amplitude of the light reflex response, while both types of threat inhibited the light reflex across all light intensities, the threat of shock being more potent than the threat of sound blast. The effect of either type of threat on light reflex amplitude was greater with increasing light intensity.

Conclusion It is concluded that the CS per se does not contaminate the results, the fear-stimulus modality is not important although the light reflex is sensitive to the variations in the threat inherently associated with different types of fear-inducing stimuli and that the manifest effect of fear on light reflex amplitude increases with increasing light intensity.

■ 3144

Learning from the pupil - fundamental studies and clinical applications

BARBUR JL, RODRIGUEZ - CARMONA M, HARLOW JA
Applied Vision Research Centre, The Henry Wellcome Laboratories for Vision Sciences, City University, London

Purpose Findings from a number of recent studies suggest that the processing of stimulus attributes such as colour and spatial structure can also cause the pupil to constrict transiently. These responses are thought to involve separate pathways and are spared selectively in patients with damage to the midbrain, even when the same patients exhibit no pupil light reflex response (Brain 125:2296-2307, 2002). The aim of this study was to learn more about pupil responses to colour, gratings and chromatic afterimages and to investigate the potential use of pupil response components in clinical studies.

Methods Pupil responses were elicited with either rapid luminance changes or the onset / offset of stimuli that were both photopically and scotopically isoluminant. In addition to investigating normal subjects, the various pupil studies were also carried out in a group of patients in severe optic neuritis, both during the acute and the recovery phases of the disease.

Results Pupil responses can be elicited both at the onset and the offset of isoluminant, chromatic stimuli, even when rod contrast signals are absent. The study reveals a greater loss of pupil response amplitude and significantly longer latencies to chromatic modulation in patients with optic neuritis.

Conclusion Significant pupil responses can be elicited by both the onset and offset of coloured stimuli that are both photopically and scotopically isoluminant. The results also show that various pupil response components can be affected differently in patients with optic neuritis. The new findings suggest that the pupil colour response, in particular, may provide a useful, objective estimator to judge the extent of damage and recovery in diseases of the optic nerve.

EVER-2004-abstractbook.indd 181 8/19/04 12:27:13 PM

■ 3151

Expression of matrix metalloproteinases (MMP'S) in the juxacalicuar tissues in poag ad exfoliation glaucoma (ExG)

UUSITALO H, RONKKO S, REKONEN P, KAARNIRANTA K, OKSALA E, PUUISTJARVI T, TERASVIRTA M
Department of Ophthalmology, University of Kuopio, Kuopio, Finland

Purpose Accumulation of extracellular matrix material in the trabecular meshwork and juxtacanalicular tissue is a known pathogenic factor in the development of increased IOP and glaucoma in general. However, there seem to be certain differences in composition of this material and pathogenic role of it in POAG and ExG. The main function of MMPs is related to remodelling of extracellular matrix (ECM). Thus they may regulate the outflow facility and thus IOP by controlling the composition of the ECM in the chamber angle. The present study is focused on the detection of MMP-1, -2, -3 and -9 expression in the juxtacanalicular tissue in POAG and ExG.

Methods Samples of juxtacanalicular tissue were collected from the eyes of the patients suffering from POAG or ExG during deep sclerectomies. Frozen sections, monoclonal antibodies against MMP-1, -2, -3 and -9 and a standard immunohistochemical procedure were used for the visualization and semiquantitative analysis of MMP's.

Results Juxtacanalicular tissue of the POAG eyes showed constant but individially variable expression of MMP-1, -2, -3, and -9. On the contrary, juxtacanalicular tissue of ExG eyes was virtually devoid of MMP expression. Instead of this there was an accumulation of variable amount of pigment in ExG eyes.

Conclusion Expression of MMP's in POAG eyes and the nearly complete absence of MMP's in the juxtacanalicular tissues of ExG eyes indicates clearly different histopathological characteristics of POAG and ExG. This may reflect the different ability of juxtacanalicular tissue to respond to the accummulation of extracellular material and the different capacity of the trabelular tissue to remodel ECM in POAG and ExG eyes.

■ 3152

Survey of glaucoma treatment in pregnancy

VAIDEANU D, FRASER SG
Ophthalmology, Sunderland

Purpose When glaucoma occurs in pregnancy, the treatment options can be very challenging.At present there are no guidelines for the treatment of glaucoma in pregnancy. The aim of our study was to survey the experience of ophthalmologists in managing glaucoma in pregnant women.

Methods Anonymous survey of 600 UK consultant ophthalmologists via a postal questionnaire with 4 questions mailed with a covering letter.

Results : Of the 600 questionnaires sent, 282 were returned. 26% of the respondants, had previously treated pregnant women with glaucoma. Of these (note: some ophthalmologists treated more than one patient) 34% observed the patient(s), 73% continued with medical treatment(s), 11% had used surgery whilst 3% could not recall what treatment they had used.When questioned about their current opinions of the management of glaucoma in pregnant women, 21% stated they would observe, 45% would use topical treatment, 10% would use ALT and 6% would chose surgery. 34% of the doctors were unsure of what treatment option they would choose. When a preference for the medical treatment was expressed, most preferred topical beta-blockers.

Conclusion This survey confirms variation in the management of glaucoma in pregnancy. We suggest that evidence based guidelines for the management of glaucoma in pregnant women are required.

■ 3153

Adjunctive use of Ginkgo Biloba in patients undergoing glaucoma

RUIZ-LAPUENTE CJ, PLAZAS A, BERENGUER-ANDREU J, GÓMEZ L
HH UU Virgen Del Rocio, Sevilla

Purpose Introduction: Glaucoma is a progressive optic neuropathy with an increase in the apoptotic pathway. Ginkgo Biloba is used in the treatment of cerebral circulatory insufficiency and peripheral vascular diseases by improvement of blood flow, inhibition of apoptotic ways, reduction of vasospasm, decrease of serum viscosity, platelet activating factor antagonism and antioxidant properties. Furthermore Ginkgo Biloba has proved efficacy in visual field stability in patients undergoing normal pressure glaucoma. Purpose: To evaluate the effect of Ginkgo Biloba Extract on visual field in patients undergoing open angle glaucoma.

Methods Methods: Fifty five caucasian patients undergoing primary open angle glaucoma, with intraocular pressure controlled with topicaltherapy, were randomly assigned to any of this group: Group "A": 27 patients (54 eyes) were added Ginkgo Biloba Extract (60-80 mg/12h) and Group "B" : 29 patients (58 eyes) were treated only with topical drops.After a training, visual field test were performed at first baseline and after two-four months. Differences in mean sensibility (MS, dB) were evaluated by means of Student´s t-test (paired data).

Results Results: After Ginkgo Biloba treatment, a statistically significant increase in mean sensibility (MS) was recorded (At baseline: SM= 22.71 ± 8.25 dB (SM ± SD); after study period: MS=24.09 ± 8.56 dB ($p<0.005$). In group "B" there was no statistical significant difference(MS was 22.76 ± 5.41 dB and decreased to 22.51 ± 5.08 dB (p =NS) after the study period.

Conclusion Conclusions: Ginkgo Biloba Extract administration appears to improve preexisting visual field damage in patients undergoing glaucoma.

■ 3154

A 10 Year Outcome Study following Bilateral YAG laser Peripheral Iridotomy

WRIDE NK, VAIDEANU D, FRASER SG
Sunderland Eye Infirmary, Sunderland

Purpose To study the outcome of patients following bilateral YAG laser peripheral iridotomy (PI) over a ten year period.

Methods A retrospective review of the casenotes of all patients who underwent bilateral YAG laser PI between 1992 and 1994 was undertaken. The indications for PI (acute angle closure/chronic angle closure/narrow angles on gonioscopy), the use of additional therapies or procedures and follow up pattern were documented.

Results 114 eyes of 58 patients were identified from records and reviewed from this period. They were composed of 18 males and 40 females with an average age of 66. 10 patients (17%) had incomplete records and lost to follow up. 22 patients (38%) had been discharged and 24 patients (41%) were still under regular review at the clinic. 3 patients died during follow up.25 patients had suffered an attack of acute angle closure glaucoma, 9 had chronic angle closure and 11 patients had narrow angles on gonioscopy. In the angle closure group only 4 patients did not require further treatment. The other 21 needed combinations of cataract extraction and filtration surgery and 13 were still under review. In the chronic angle closure group all 9 patients (18 eyes) were on topical treatment but 5 eyes underwent filtration surgery. In the narrow angle group 8 out of 22 eyes underwent cataract surgery.

Conclusion A high percentage of patients in all groups ended up requiring additional measures other than just PI alone. This is not surprising with the chronic angle closure glaucoma, but the finding in the angle closure group where 84% of eyes underwent some form of further treatment is striking. Over 50% of these patients are still attending review and this suggests that these patients require monitoring long after their PI.

EVER-2004-abstractbook.indd 182 8/19/04 12:27:13 PM

■ 3155

Standard Deep Sclerectomy with Collagen Implant Compared to a New Method of Very Deep Sclerectomy with Collagen implant: a Randomised Controlled Trial

MANSOURI K, VIET TRAN H, MERMOUD A
Hopital Ophtalmique Jules Gonin, Lausanne

Purpose To compare the intraocular pressure lowering effect and safety of an innovative method of deep sclerectomy, the very deep sclerectomy (VDSCI) with collagen implant to conventional deep sclerectomy (DSCI) with collagen implant.

Methods Fifety patients with medically uncontrolled primary and secondary open-angle glaucoma were included in the study. Randomly, 25 patients were assigned to undergo either DSCI or VDSCI procedure. The patients were examined before and after the operation at 1-D, D-1, 1, 2, 3 weeks and 1, 3, 6, 9, and- 12 months. UBM examination was done at 3 and 6 months after surgery.

Results Preliminary results at a mean follow-up of 8.1 months (SD 3.1, VDSCI) and 8.3 months (SD 4.2, DSCI) showed a mean post-operative IOP of 5.5 (SD 3.1, VDSCI) and 7.4 (SD 3.8, DSCI) at day one and 15.5 (SD 5.7, VDSCI) and 14.8 (SD 6.1, DSCI) at the last follow-up. The difference was not statistically significant. Two patients had perforations of the TDM and were excluded from the analysis. Complete Success rate using Kaplan-Meier Survival Analysis was 88.9 % (VDSCI) and 72.6% (DSCI). The complication rate was comparable in both groups.

Conclusion At 8 months of follow-up, there was no statistically significant difference between VDSCI and DSCI in terms of complete and qualified success rates. In VDSCI, UBM showed a statistically significant increase in the number of suprachoroidal effusion (uveoslceral outflow) associated with a statistically significant smaller size of the subconjunctival bleb compared to DSCI. VDSCI might be a good alternative to classical penetrating surgery.

■ 3156 / 356

Effects of latanoprost 0.005% and the fixed combination dorzolamide/timolol on IOP and retrobulbar hemodynamics in glaucoma patients

MARTÍNEZ-GARCÍA AMG (1), SANCHEZ-SALORIO MSS (2), GARCÍA-FEIJOO JGF (3)
(1) Instituto Galego de Oftalmoloxía, Santiago de Compostela
(2) Instituto Galego de Oftalmoloxia, Santiago de Compostela
(3) Hospital Clinico San Carlos, Madrid

Purpose In a prospective, crossover, randomized study the vascular and the IOP effects of latanoprost and the fixed combination of dorzolamide/timolol were evaluated in patients with open-angle glaucoma.

Methods 22 consecutive subjects with newly diagnosis of open-angle glaucoma were included in this study. IOP and Doppler examination were assessed in all patients at baseline, then patients were randomized in two groups: Group A (12 patients) recieved firstly treatment with latanoprost QD for 1 month; IOP and Doppler examination were measured and, after a 1-month washout period, they recieved treatment with a fixed combination of dorzolamide/timolol BID and, the same measurements were repeated. Group B recieved firstly treatment with the fixed combination during 1 month, IOP and Doppler measurements were assessed and, after 1 month of washout, the patients were treated with latanoprost QD and the same measurements were repeated.

Results IOP and Doppler measurements were similar at baseline. Latanoprost reduced the IOP from 25.83(3.74) to 19.00(1.81) mm Hg in group A, and from 26.90(3.76) to 19.00(2.49) in group B. The fixed combination reduced the IOP from 26.00(3.89) to 18.92(1.00) in group A, and from 27.30(3.80) to 19.30(2.21) in group B. Compared to baseline and washout measurements only the fixed combination dorzolamide/timolol induced a statistically significant decreased in the hemodynamic parameters in the Ophthalmic and Short posterior Ciliary Arteries.

Conclusion Both treatments decreased IOP, but only the fixed combination dorzolamide/timolol had a vascular effect on the retrobulbar vessels.

■ 3157 / 357

The rabbit´s IOP after instillation of the amino acid L-arginin. HCl and antiglaucomatics misture

OLAH Z (1), VESELOVSKY J (2), GRESSNEROVA S (2), VESELA A (2)
(1) Dept. of Ophthalmology,Comenius University, Bratislava
(2) Inst. of Animal Physiology and Ethology, Comenius University, Bratislava

Purpose To compare effectivity of the 3 mixtures: L-arginin.HCl with Timolol, Trusopt and Xalatan on the physiologic intraocular pressure (IOP) in rabbits.

Methods a/ The 10% L-arginin.HCl only; b/ mixture of the 10% L-arginin.HCl with 5.5% Timoptol, 10% L-arginin.HCl with 2% Trusopt and 10% L-arginin.HCl with 0.005% Xalatan was instilled into the left conjunctival sac of te 5 adult rabbit´s (female of the New Zealand Whithe species) and the rigth eye was used as control. The IOP and pupilar diameter were measured before and in 5th, 15th, 30th, 60th, 120th, 180th, 240th min. and 24 hours after the instillation.

Results The 10% L-arginin.HCl decreased the physiologic IOP by 16% (mean value). The mixture of the 10% L-arginin.HCl with 0.5% Timoptol, 2% Trusopt and 0.005% Xalatan decreased significantly the IOP value compared with the contol eye. This mixtures was twice as effective as any of the mentioned antiglaucomatics used separately. The pupilar diameter was not changed.

Conclusion We assume that the mentioned mixtures were able to decrease the physiologic IOP in rabbits through their better penetration to the receptors of the ciliary body followed by decrease of the amino acid secretion into the aqueous humor. We conclude that the increased effectivitiy of the mixtures compared with the separate components is related to the instillation of the by now ready "bioantiglaucomatic".

■ 3158 / 358

Clinical experience with the Ahmed Valve implant in a non-tertiary ophthalmic unit

KALHORO A (1), MATAFTSI A (1), ATTENBOROUGH M (1), MEARZA A (1), BIDGOOD P (2), MCNIECE R (2), GILLESPIE I (1)
(1) Royal Eye Unit, Kingston-Upon-Thames
(2) Kingston University, Kingston-Upon-Thames

Purpose To assess clinical outcomes of Ahmed valve implants in intractable glaucoma.

Methods Single-centre, retrospective case-note analysis. Success was defined as post-operative IOP of 6-21 mmHg in the absence of complications.

Results 23 eyes (21 patients) were treated with an Ahmed valve implant between 1996 and 2002. The mean ± SD (standard deviation) patient age was 72.9 ± 13.7 years (range 33-93). Mean follow-up was 38 ± 27 months (range 12-92).The underlying diagnosis was primary open angle glaucoma in 65% (n=15). In 13 cases (57%), patients had undergone ≥3 previous penetrating ocular surgeries. Intraocular pressure was reduced from a pre-operative mean of 28.4 ± 6.6 mmHg to 15 ± 7.9mmHg at last follow-up. Cumulative probabilities of success at 1 and 2 years were 73% and 53% respectively (Kaplan-Meier life table analysis). 7 implants (30%) remained successful beyond 24 months (range 24-92) with no additional complications. 7 implants (30%) failed by 12 months and 10 implants (43%) failed by 24 months. Major post-operative complications were persistent hyphaema in 2 cases (9%), gross tube or plate extrusion in 3 cases (13%), intra-cameral tube displacement in 2 cases (9%) and one case each of endophthalmitis, corneal graft decompensation and chronic hypotony. Tubes were removed in 4 cases (17%) and additional surgery (not including needling) was necessary in 10 cases (43%). 10 patients (43%) lost at least 2 lines of Snellen acuity.

Conclusion Results for success at 1 year are comparable with studies in tertiary units. Lower rates for success were obtained at 2 years. This may reflect both a significantly higher mean age and previous number of ocular surgeries in this cohort.

EVER-2004-abstractbook.indd 183 8/19/04 12:27:14 PM

3159 / 359

Evaluation of preoperative factors associated with success of mitomycin C needling revision for failed filtration blebs: a prospective study

GUTIERREZ CG, TEUS MT
Hospital de Alcala de Henares, Alcala de Henares

Purpose To study the effectiveness and the factors for success of Mitomycin C (MMC) needling revision for failed filtration blebs.

Methods Prospective, nonrandomized conparative (self-controlled) trial of34 consecutive patients that underwent MMC needling revision for failed filtering bleb.. Needling revision followed by 0.01ml (0.2 mg/ml) MMC injection. Preoperative factors were evaluated for an association with postoperative success using Kaplan-Meier survival analysis.

Results The mean (+/- standard deviation) IOP before the procedure was 25.58 (+/- 4.43) and decreased 11.11, 13.47, 15.82, 16.70, 14.96, 14.19, 113.95 and 13.07 on the first postoperative day, after 1, 3, 6, 9, 12 and 24 months respectively. At each interval, the mean IOP was significantly lower than the preoperative value (P=0.000 for each period). At the last visit overall succes was achieved in 29 eyes (85.2%); absolute in 15 (44.1%) and qualified in 14 (31.2%). The success rates were 90% and 75% at 1 and 2 years respectively (Kaplan-Meier survival analysis). Successful single-needling procedure was highly correlated with past glaucoma filtration surgery of less than 4 months (Kaplan-Meier survival analysis, log-rank test P=0,006).

Conclusion Mitomycin needling revision appears to have high succes rate. Past surgery of less than 4 months isre found to be significant factors for success. We recommend performing the procedure as soon as IOP starts to increase or bleb aplanation is detected.

EVER-2004-abstractbook.indd 184 8/19/04 12:27:14 PM

■ 3161

Endothelin-1 is a major regulator of ocular blood flow in humans

SCHMETTERER L (1, 2)
(1) Clinical Pharmacology, Vienna
(2) Medical Physics, Vienna

Purpose Endothelin-1 (ET-1) is a major contributor to blood flow regulation in many organs within the human body. In vitro and animal experiments indicate that ET-1 also plays a role in blood flow regulation in the eye. This presentation reviews a number of recent studies that we have done to elucidate the role of ET-1 in the ocular blood flow control in humans.

Methods A number of studies were designed to investigate the role of ET-1 in the regulation of retinal, choroidal and optic nerve head blood flow in healthy humans. Special emphasis was put on the role endothelin in autoregulation and in the retinal vasoconstrictor response to systemic hyperoxia.

Results ET-1 induces a dose-dependent reduction retinal, choroidal and optic nerve head blood flow. These results can be reversed by the ET(A) receptor antagonist BQ-123, whereas BQ-123 alone has no effect. In addition, BQ-123 alters the retinal and choroidal hemodynamic response to isometric exercise and blunts the response to systemic hyperoxia.

Conclusion ET-1 is a major regulator of ocular blood flow, but does not contribute substantially to basal vascular tone in the eye. Potent vasoconstrictor action of ET-1 in the posterior pole of the eye is mainly mediated via the ET(A) receptor. In addition, our data indicate a role for ET-1 in ocular autoregulation and in the retinal vasoconstrictor response to hyperoxia.

■ 3162

The Role of Endothelin 1: Elevation in retinal vascular abnormalities of diabetes

KING G
Joslin Diabetes Center, Havard Medical School, Boston, MA

Purpose Elevation of endothelin-1 expression has been reported by multiple groups in the retinal tissue of diabetic patients and animals. The infusion of endothelin-1 in vitreous can cause initial vascular dilation and then vascular constriction of retinal arteries and veins. The decrease in retinal blood flow observed in the diabetic state can be normalized by inhibitors of ETA receptors. Thus it is possible that the elevation of ET-1 with its induction of decreased blood flow in the retinal circulation may contribute to diabetic retinopathy. Recently we have reported that PKC activation, induced by diabetes and hyperglycemia can lead to increased expression of PDGF- B. PDGF-B, in turn, increased the expression of ET-1, which can lead to hemodynamic changes such as a decrease in retinal blood flow. Thus, we have postulated that elevation of PKC β isoform induced by diabetes and hyperglycemia will lead to early changes in cytokine expression such as PDGF-B and endothelin-1, causing hemodynamic abnormalities in the retina which can contribute to diabetic retinopathy.To test this hypothesis our laboratory has made two types of transgenic mice. In one strain of mice we have over-expressed PKC β2 isoform in the vasculature using pre proendothelin promoter. These mice have developed retinal arterial and venous lesions after six months of life without diabetes. These lesions include venous bleeding, sacular aneurysms and increasing permeability in the capillaries. Since many of the retinal vascular abnormalities mimic those found in diabetic patients, these data strongly suggest that activation of PKC β isoform induced by diabetes and hyperglycemia can contribute significantly to the development of diabetic retinopathy. The second strain of mice overexpressed ET-1, again using pre proendothelin promoter. In the homozygous version of the transgenic ET-1 mice, ET-1 is increased by two or three-fold in the retina. Circulation time of fluorescein, from artery to the vein, was prolonged indicating a decrease in retinal blood flow. In addition, a parallel decrease in vascular permeability was observed. The findings of decreased retinal blood flow and decreased permeability in the retina of ET-1 transgenic mice does not completely mirror the findings in diabetic animals which exhibit decreasing retinal blood flow but an increase in vascular permeability. The results in our study, using transgenic mice, suggest that PKC activation of the β isoform in the retinal blood vessels can lead to several biochemical and physiological parameters as observed in diabetes such as increased expression of PDGF-B, ET-1, decreased blood flow and increases in permeability. However, the overexpression of ET-1 in the blood vessels can only mimic a decrease in the retinal blood flow but cannot explain the increase in permeability observed in diabetes.

Conclusion Elevation of PKC β isoform appears to be quite important in the development of diabetic retinopathy. ET-1 elevation as observed in diabetic state in the retina can account for some of the hemodynamic abnormalities but not vascular permeability, and the other vascular lesions of diabetic retinopathy.

■ 3163

Endothelin system in human eye: overexpression of ET-1 in the anterior segment of patients with primary open-angle glaucoma

FERNANDEZ DURANGO R
Unidad de Investigación, Departamento Medicina Interna III, Hospital ClinicoUnidad de Investigación, Departamento Medicina Interna III, Hospital Clinico San Carlo, Madrid

Purpose The ocular blood flow and the intraocular pressure are under the influence of ET-1. In this presentation, I review the expression pattern of ET-1 and its receptors ETA and ETB in the human eye. We also investigate the expression of ET-1 in the anterior segment of eyes from primary open glaucoma (POAG).

Methods Immunohistochemistry was done in 4 um paraffin sections of 4% paraformaldehyde-fixed eyes using a rabbit anti-ET-1 polyclonal antibody. In situ hybridization for ET-1 was done in similar sections using sense and antisense digoxigenin labeled RNA probes. Quantitative real time RT-PCR was used to quantify the expression of ETA and ETB.

Results Our previous studies demonstrated the expression of ET-1 and its receptors ETA and ETB in the iris, nonpigmented epithelial ciliary cells and ciliary muscle as well as in the cornea, limbus, retina and anterior portion of optic nerve of human eye. We have observed an increase of immunostaining for ET-1 in different tissues of the anterior segment of eyes with POAG in comparison to that seen in normal and other types of glaucomatous eyes.

Conclusion ET-1 and its receptors ETA and ETB are constitutively expressed in human eye. These studies support the idea that ET-1 is important ocular factor acting by autocrine and paracrine pathways and suggest a role of ET-1 in the pathophysiology of POAG.

■ 3164

Endothelin-1 induced optic nerve damage

CHAUHAN BC
Department of Ophthalmology and Visual Sciences, Dalhousie University, Halifax

Purpose Chronic ischaemia of the optic nerve may be a potential risk factor for the development of glaucoma.

Methods We have developed a model of chronic endothelin-1 induced optic nerve modified from the technique first described by Orgul and Cioffi in rabbit and monkey. An osmotic minipump is used to deliver a fixed volume of perfusate containing ET-1 to the retrobulbar optic nerve.

Results ET-1 causes a time dependent loss of retinal ganglion cells (RGCs) with approximately 23%, 40% and 50% loss at 3, 6 and 12 weeks. There is characteristic microglial activation in both the optic nerve head and retina. At the doses used in this study (3 to 27 μM), ET-1 caused a dramatic decrease in optic nerve head blood flow. Unlike intraocular pressure induced optic neuropathy in rat, this model did not cause optic disc cupping.

Conclusion This presentation will review the data from this model and discuss the role of ET-1 on RGC axons and glia, and discuss the relevance of this model to human optic neuropathy.

EVER-2004-abstractbook.indd 185 8/19/04 12:27:15 PM

■ 3165

Endothelin and glaucoma

YORIO T (1), PRASANNA G (1), KRISHNAMOORTHY R (2)
(1) University of North Texas Health Science Center, Forth Worth
(2) University of North Teas Health Science Center, Forth Worth

Purpose This presentation will focus on the cellular and molecular aspects of endothelins (ET) and its receptors in the eye with an emphasis on its relationship to ocular function and role in the etiology of glaucoma.

Methods The Morrison elevated IOP rat model of glaucoma for both ETB-deficient and wild type animals was used wherein IOP was raised in one eye and maintained for up to three months. Aqueous ET-1 levels were measured by RIA. Expression of ETA and ETB receptors and markers for astrogliosis (e.g. glial fibrillary acidic protein; GFAP) were detected in the retina and ONH by immunohistochemistry and immunoblotting. TUNEL assay were performed as an index of apoptosis and radiolabel 35S Easy Tag methionine/cysteine protein labeling mix, was used for axonal transport.

Results Intravitreal ET-1 or ET-3 significantly decreased axonal transport at 4 and 21 days post-administration, with p's =0.001 and 0.010, respectively. Effects on Slow Component b were much greater than on SCa, indicating that ET-1's effects were either somewhat component-specific or partially reversible. Intravitreal ET–1 treatment also produced an increase in apoptotic cell death of retinal ganglion cells, compared to vehicle–injected control eyes, but not in ETB-deficient animals. Elevated IOP induced astrogliosis in wild-type animals but not in ETB-deficient animals. Increases in GFAP, ET-1 and ETB receptor was found in IOP elevated eyes of wild-type but not in ETB-deficent animals.

Conclusion The results suggest that ET and the ETB receptors are key mediators in astroglial activation, axonal transport changes and retinal ganglion cell loss. These findings strongly suggest that one of the key factors in optic nerve damage due to elevated IOP may be ET.

EVER-2004-abstractbook.indd 186 8/19/04 12:27:15 PM

■ 3211

Endothelin-1, trigger or active component in ocular diseases

SCHMETTERER L
Clinical Pharmacology, Vienna

Purpose Endothelins have major influence on the function and structure of the vasculature as they favor vasoconstriction and cell proliferation through activation of specific ET(A) and ET(B) receptors. The endothelin system is activated in a variety of disorders and disease states, such as systemic hypertension, pulmonary hypertension, atherosclerosis, acute coronary syndromes, and congestive heart failure.

Methods Evidence for the involvment of endothelins in vascular diseases of the eye from the literature is given. Special emphasis is put on the role of endothelins in glaucoma, diabetic retinopathy and HIV-related retinopathy.

Results There is increasing evidence that endothelins play a role in vascular diseases of the eye. In glaucoma, diabetic retinopathy and HIV retinopathy clinical features are well compatible with a role of endothelins in the pathogenetic process. This evidence arises from in vitro, animal and human studies.

Conclusion Elelvation of endothelins in ocular vascular disease does not appears to be a secondary process, but is likely involved in the processes that finally lead to vision loss. Accordingly, endothelin receptor antagonists do provide hope for the treatment of these diseases and clinical trials are warranted to prove the hypothesis that this class of drugs may be beneficial to patients with glaucoma or diabetic retinopathy.

■ 3212

Metabolism of endothelin-1 (ET-1), principles of measurement in the plasma and prevalence in ocular diseases

HAUFSCHILD T
University Eye Clinic, Basel

Purpose Endothelin (ET) is one of the most potent known vasoactive substances. Three isoforms have been described: ET-1, ET-2 and ET-3.The metabolism of ET will be demonstrated and measurment of ET-1, a 21-amino acid peptide, in the plasma will be explained. Furthermore the prevalence of ET-1 in other ocular diseases then glaucoma, pseudoexfoliation and central serous chorioretinopathy will be discussed.

Methods The biosynthesis of ET-1 is predominantely performed by vascular endothelial cells, but also organs like heart and brain or pulmonary epithelial cells and glomerular mesanglial cells synthesize ET. ET acts by binding to specific receptors which leads to various cellular actions e.g. efflux of cellular calcium, activation of phospholipase C and inhibition of Na/K-ATPase. Beside it's vasoactive function (directly or indirectly by increasing the sensitivity to other vasoconstictors) it also contributes to regulation of cardiac output, neurotransmitter action, blood volume and renal ion and water excretion. The measurment of ET-1 in the plasma is based on a radio immuno assay and a highly sensitive protocol will be explained.

Results Increased levels of ET-1 could - beside in glaucoma, pseudoexfoliation and central serous chorioretinopathy - also be demonstrated e.g. in optic neuritis and multiple sclerosis, giant cell arteriitis and retinal vascular occlusive diseases of younger patients.

Conclusion Therefore ET-1 seems to play a role in many ocular diseases, not only glaucoma and measurement is relatively simple.Some therapeutical options will be discussed.

■ 3213

Endothelin-1 and exfoliative glaucoma

HOLLÓ G
1st Department of Ophthalmology, Semmelweis University, Budapest

Purpose To investigate the role of endothelin-1 (ET-1) in the development of exfoliative syndrome and exfoliative glaucoma as well as in the associated systemic conditions.

Methods Patients with exfoliative syndrome and exfoliative glaucoma were enrolled in different clinical studies. Aqueous humour ET-1 concentration as well as plasma ET-1 level were measured using radioimmunoassay and ELISA techniques. The values were compared to those of normal controls, cataract patients with no glaucoma or exfoliation, and patients with primary open-angle glaucoma of similar age ranges. Potential connection between plasma ET-1 level and systemic vascular regulation was also investigated.

Results Aqueous humour ET-1 concentration (similarly to sevaral other component of the aqueous humour) was altered (elevated) in exfoliative syndrome compared to the control cataract patients. In contrast plasma ET-1 concentration showed no difference between exfoliative glaucoma, primary open-angle glaucoma and control subjects. In contrast to the lack of difference in plasma ET-1 level the cutaneous capillary perfusion and the reactions of cutaneous flow to cold and warmth were altered in the exfoliative glaucoma group compared to the other two groups (normal controls and open-angle glaucoma).

Conclusion The different results suggest that intraocular but not systemic plasma ET-1 levels may play a role in the development of exfoliation syndrome or glaucoma. The exact mechanism of this process remaines to be determined, however, it is clear that the role of ET-1 in these processes can not be separated from the other biochemical alterations of aqueous humour.

■ 3214

Endothelin-1 in progressive glaucoma

ORGUL S (1), EMRE M (1), HAUFSCHILD T (1), SHAW SG (2), FLAMMER J (1)
(1) University Eye Clinic, Basel
(2) Department of Clinical Research, Berne

Purpose To compare the plasma levels of endothelin-1 (ET-1) between patients with primary open angle glaucoma with visual field progression despite normal or normalized intraocular pressure and patients with stabile visual fields in a retrospective study.

Methods The progressive group consisted of sixteen primary open-angle glaucoma patients and the group with stable visual field consisted of 15 patients. After a 30-minute rest in a supine position, venous blood was obtained for ET-1 dosing. Difference in the plasma level of ET-1 between two groups was compared by means of analysis of covariance (ANCOVA), including age, sex and mean arterial blood pressure as covariates.

Results ET-1 plasma levels were found to be significantly increased in patients with deteriorating (3.47 +/- .75 pg/ml) glaucoma when compared to those with stable (2.59 +/- 0.54 pg/ml) visual fields (p=0.0007).

Conclusion Glaucoma patients with visual field progression in spite of normal or normalized intraocular pressure have been found to have increased plasma endothelin-1 levels. It remains to be determined if this is a secondary phenomenon or whether it may have a role in the progression of glaucomatous damage.

EVER-2004-abstractbook.indd 187 8/19/04 12:27:15 PM

■ 3215

Endothelin-1 plasma levels in patients with Central Serous Chorioretinopathy

PRUENTE Ch, HAUFSCHILD T, FLAMMER J
University Eye Clinic, Basel

Purpose The pathogenesis of Central Serous Chorioretinopathy (CSC) is still largely unknown. Recent angiographic studies suggest the possible involvement of choroidal vascular dysregulation in the pathogenesis of CSC. The aim of our studies were to investigate whether CSC-patients have pathologic ET-1 plasma levels which could explain some of the changes in the choroidal microcirculation in these patients.

Methods In 22 consecutive patients with acute CSC (mean age 42.0±1.9 yrs) and 22 age- and sexmatched normals (mean age 42.2±1.8 yrs) ET-1 plasma levels were determined by specific radioimmunoassay after a 30 minutes rest in lying position. All CSC-patients had acute visual disturbances, localized neurosensory detachment and typical angiographic changes at the time of ET-1 determination. Control examinations were performed after 3 month when all symptoms had disappeared and examinations revealed no activity of the lesion.

Results Plasma ET-1 levels were markedly and significantly ($p<0.001$) elevated in patients with CSC (2.76±0.17; min: 1.94, max: 4.37) compared to the normal group (1.50±0.10; min: 0.68, max: 2.13). After 3 month the values had significantly decreased.

Conclusion These findings show that plasma ET-1 levels are significantly increased in patients with CSC during the acute period of the disease. Since ET-1 is a potent vasoactive substance in the arterial and venous parts of the microcirculation these results could explain the changes in the choroidal lobular blood-flow demonstrated in CSC, providing a further hint for the possible involvement of microvascular dysregulation in the pathogenesis of CSC.

EVER-2004-abstractbook.indd 188 8/19/04 12:27:16 PM

3221
Prevalence of age related maculopathy and macular degeneration

AUGOOD C
London School of Hygiene and Tropical Medicine, London

Purpose To estimate the prevalence of age-related maculopathy in an older population from 7 European countries.

Methods Randomly sampled people aged 65 and over were invited to an eye examination and risk factor assessment in Norway, Estonia, UK, France, Italy, Greece and Spain. Two non-simultaneous 35 stereoscopic colour fundus images were taken for each eye and graded by the International ARM Epidemiological Study Group classification using grading in the worst eye. Overall, age and sex specific rates were calculated for stage of ARM with 95% confidence intervals (CIs) calculated for clustered data. Multinomial modelling was used to assess the associations (relative risk ratio, RRR) of gender with stage of ARM.

Results 4760 people (2128 men, 2632 women, 50% response rate) had gradeable fundus images. 1.2% of eyes could not be graded. Overall, nearly half of the population studied had no signs of early or late maculopathy, with slightly fewer women than men. Just over a third had evidence of ARM stage 1, 10% had ARM stage 2, 2.5% had ARM 3 and 3.3% had ARM 4(AMD).Of the 158 cases of AMD, 49 were Geographic atrophy and 109 were Neovascular AMD. Prevalence of ARM stage 0 decreased with increasing age in both men and women. Prevalence of stages 2-4 rose with age. Compared to men, age adjusted prevalence were lower for women for stage 2, RRR=0.77 (95%CI 0.67-0.90,p=0.006) and higher for AMD, RRR=1.37 (1.03-1.84, p=0.037). After adjustment for smoking, the RRRs for women for stage 2 were unchanged while for AMD the RRR increased to 1.89 (1.55-2.30,p=0.0001).

Conclusion The prevalence of age-related maculopathy in the EUREYE study is of similar magnitude to other population-based studies in western populations. We also found an excess of AMD in women observed in some, but not all studies.

3222
Antioxidants and risk of ARM

YOUNG IS
Queen's University Belfast, Belfast

Purpose To investigate the association of lutein, zeaxanthin and vitamin C with age-related maculopathy.

Methods 4760 randomly sampled people aged 65 and over participated in an eye examination and risk factor assessment in 7 centres. Two non-simulteanous stereoscopic colour fundus images were taken for each eye. All images were graded at a single centre using the International ARM Epidemiological Study Group classification and stratified into 5 exclusive stages based on the grading in the worst eye. Peripheral venous blood samples were collected from each participant and analysed in a central laboratory. Lutein and zeaxanthin were analysed by reverse phase HPLC and vitamin C by an enzyme-based assay in plasma stabilized with metaphosphoric acid. Multinomial modelling for clustered data, adjusted for potential confounders, was used to assess the associations (relative risk ratios RRR) of fifths of the antioxidants with stage of ARM and with the lowest decile of the distributions.

Results In either age and sex adjusted or fully adjusted analyses there were no significant trends for lutein, zeaxanthin or vitamin C with early ARM or with AMD. The lowest decile of vitamin C (<12.2 umol/L) was in the range associated with biochemical depletion and suggested a small adverse association with AMD (RRR=1.36, 95%CI 0.88 to 2.10). Similar effects were observed also for the lowest decile of zeaxanthin and a weaker association for lutein. People with the lowest levels of both vitamin C and zeaxanthin were at highest risk of AMD (RRR=2.67, 95%CI 1.17 to 6.06), p=0.003.

Conclusion We found no evidence to support an important association across the full distribution of lutein, zeaxanthin or vitamin C levels with stage of ARM. A high risk for AMD was observed for a small proportion of people with very low levels of these antioxidants.

3223
Solar radiation and age related macular degeneration

FLETCHER AE
Epidemiology & Population Health, London School of Hygiene & Tropical Medicine, London

Purpose To investigate the association between solar radiation (UVR) and its components (UVA, UVB and blue light) with age related macular degeneration in the seven country EUREYE study.

Methods 4760 randomly sampled people aged 65 and over participated in an eye examination and risk factor assessment.Two non-simultaneous stereoscopic colour fundus images were graded at the Rotterdam Centre using the International ARM Epidemiological Study Group classification. Data was collected on time spent out of doors daily throughout an individual's working life (from age 14), for different occupational time periods and in retirement and during weekend and holiday leisure time and on the use of protective eyewear. Information from questionnaires and geographical coordinates for residence were sent to the University of East Anglia for mapping onto meteorological data. The statistical analysis examined associations between quintiles of cumulative years of exposure for UVA, UVB, and blue light.

Results In analyses adjusted for age, sex and smoking, no significant associations were found by stage of ARM and any type of UVR exposure, whether all day or peak exposures. Different patterns were observed in analyses by type of AMD with suggestions of increased risks for the highest quintile of exposure for neovascular but not for geographic AMD. Significant interactions were found with plasma levels of ascorbate, lutein and zeaxanthein and high exposures to UVR for risk of neovascular AMD; those in the lowest quintile of antioxidant and highest UVR exposure having the highest risks (2.3 for vitamin C, p=0.009, 2.3 for zeaxanthein p=0.002. and 2.6 for lutein p=0.02)

Conclusion Our results suggest that adverse effects of high UVR exposures are associated with low levels of antioxidant exposures.

3224
Vision-related quality of life in the EUREYE study

CHAKRAVARTHY U
Queens University Belfast, Belfast

Purpose To examine vision-related quality of life in an older population from seven European countries.

Methods Randomly sampled people aged 65 and over were invited to an eye examination and risk factor and quality of life assessment in seven centres across Europe. Vision-related quality of life was assessed with the National Eye Institute Visual Function Questionnaire (NEI-VFQ), translated into the languages of the seven centres. We used 16 of the original 25 questions. This resulted in 10 rather than 12 sub-scales, with vision-specific role difficulties and dependency sub-scales being excluded. Each sub-scale is assigned a score from 0 to 100, where 0 is the worst and 100 represents no disability related to vision.

Results Vision-related quality of life scores were obtained from 4652 participants. There were low item-level missing data rates (missing replied ranged from 0.1% on the general health question to 4.0% for one of the driving questions). Mean scores were high (over 80) for the sub-scales ocular pain, near and distance activities, peripheral vision, social functioning, colour vision and driving, middle (69 and 79) for general vision and mental health and low (44) for general health. For all sub-scales, mean scores were lower in women than in men and decreased with age. There were no differences between ARM 0 and 1; there was a strong trend for poorer scores with increasing grade of ARM. People with AMD (stage 4) had substantially poorer scores eg 57 and 64 on near and distance activities compared with 91 and 94 respectively in stage 0. Scores reduced with decreasing visual acuity.

Conclusion The mean scores overall were high but those with visual impairment and AMD suffered aroubnd a 50% reduction in vision related quality of life for some subscales.

EVER-2004-abstractbook.indd 189 8/19/04 12:27:16 PM

3225
Smoking and risk of AMD

SOUBRANE G
Universite de Medecin Creteil-Paris, Creteil

Purpose To investigate the association of smoking and type of AMD.

Methods Randomly sampled people aged 65 and over were invited to an eye examination and risk factor assessment in seven centres across Europe (Norway, Estonia, UK, France, Italy, Greece and Spain). Two non-simultaneous 35 stereoscopic colour fundus images centred on the macula were taken for each eye and graded at a single reading centre by the International ARM Epidemiological Study Group classification using grading in the worst eye. Data on smoking were collected by interview. Multinomial modelling was used to assess the associations (relative risk ratio, RRR) of risk factors with type of AMD (Neovascular AMD or Geographic Atrophy) compared to ARM grade 0 (controls) taking account of potential confounders and the study design of seven centres.

Results Of 4760 people (55% women, mean age 73.2), 2261 (47.5%) were graded as Stage 0 and 158 (3.3%) as Stage 4 (AMD). 49 were Geographic Atrophy and 109 Neovascular AMD. In the control group the prevalence of current smoking was 20% in men and 9% in women. Over two thirds of women had never smoked compared to a quarter of men. Current smokers were associated with two fold risks of NVD and nearly five fold of GA; for ex-smokers the risks were nearly two fold for both types.

Conclusion Women have higher rates of both types of AMD compared to men, which is not explained by cardiovascular risk factors. The adverse effects of smoking are observed for both types of AMD.

3226
Cardiovascular risk factors and type of AMD

TOPOUSIS F
Aristotle University, Thessaloniki

Purpose To investigate the association with cardiovascular risk factors by type of AMD.

Methods Randomly sampled people aged 65 and over were invited to an eye examination and risk factor assessment in seven centres across Europe. Two non-simultaneous 35 stereoscopic colour fundus images centred on the macula were taken for each eye and graded at a single reading centre by the International ARM Epidemiological Study Group classification using grading in the worst eye. Data on smoking and cardiovascular (CVD) risk factors were collected by interview. Multinomial modelling was used to assess the associations (relative risk ratio, RRR) of risk factors with type of AMD, Neovascular (NVD) or Geographic Atrophy (GA) compared to ARM grade 0 (controls).

Results There were 109 cases of NVD, 49 of GA and 2261 Stage 0. In confounder adjusted analyses, current smokers were associated with NVD (RRR=2.5, 95%CI 1.3-4.8) or GA (RRR= 4.8, 95%CI 2.0-11.5) while for ex-smokers the RRRs were 1.8 for both types. Increased RRRs for NVD were found for diabetes (RRR= 1.9, 95% CI 1.0-3.5), CVD history (RRR= 2.0, 95% CI 0.9-4.3) and daily use of aspirin (RRR= 2.1, 95% CI 1.3-3.2). RRRs for GA for these factors were around 1 although the confidence limits were wide.

Conclusion The adverse effects of smoking are observed for both types of AMD. Other CVD risk factors are associated only with NVD although the small sample size for GA limits conclusions. The association with daily aspirin use may reflect residual confounding due to unreported CVD but an adverse effect of aspirin per se cannot be excluded.

3227
Prevalence of visual impairment in the EUREYE study

SELAND J
Haukeland Eye Hospital, Bergen

Purpose To examine the prevalence of visual impairment and its association with age-related maculopathy in an older European population.

Methods Randomly sampled people (N=4760) aged 65 and over participated in an eye examination and risk factor assessment in seven study centres across Europe (Norway, Estonia, UK, France, Italy, Greece and Spain). Two non-simultaneous 35 stereoscopic colour fundus images centred on the macula were taken for each eye and graded at a single reading centre using the International ARM Epidemiological Study Group classification based on grading of ARM in five mutually exclusive stages in the worst eye. We measured presenting visual acuity in each eye using ETDRS charts with best correction for those with visual acuity <=6/9.

Results The prevalence of best corrected presenting visual acuity <= 6/18 in the better eye was 6.6%, 5.9% for low vision (acuity less than 6/18 to 3/60) and 0.7% for blindness (acuity less than 3/60). Visual impairment prevalence was higher in women than men even after adjustment for age (OR= 2.04, 95% CI 1.77, 2.34) . Prevalence rose steeply with age in both sexes. This was particularly evident for blindness (2.98% in those aged 80+ compared with 0.31% in those aged 65-69). There was an increase in all types of visual impairment for ARM stages 1-4. In AMD the prevalence of visual acuity <6/12 to 6/18 was 13%, <6/18 to 3/60 was 30% and of blindness was 11%.

Conclusion We found a higher prevalence of visual impairment compared to those reported for some other large population based studies of older people. The higher prevalence of vision impairment in women has been consistently reported elsewhere and is of concern.

EVER-2004-abstractbook.indd 190 8/19/04 12:27:17 PM

■ 3231

Molecular mechanisms of lymphangiogenesis: the cornea as a model system

CURSIEFEN C (1, 2)
(1) Department of Ophthalmology, University of Erlangen, Erlangen
(2) Schepens Eye Research Institute, Harvard Medical School, Boston

Purpose The normal cornea is devoid of both blood and lymphatic vessels. Whereas invasion of blood vessels can easily be observed at the slit-lamp secondary to several inflammatory and traumactic disorders of the cornea, only recently it became possible to demonstrate the ingrowth of clinically invisible lymphatic vessels into the cornea in corneal inflammation.

Methods This observation became possible only after the recent advent of specific markers of lymphatic endothelium (VEGFR3, LYVE-1, PROX1). These pathologic corneal lymphatic vessels play an important role as afferent arm of immune responses in the cornea, especially after corneal transplantation. Since the normal cornea is devoid of lymphatic vessels, the cornea is an ideal model system to study the mechanisms of lymphangiogenesis.

Results We report two novel discoveries recently made in this model system: (i) the novel lymphangiogenic role of VEGF-A and (ii) the essential role of macrophage recruitment for induction of inflammatory hem- and lymphangiogenesis.

Conclusion Lymphangiogenesis research using the cornea as a model system will not only enhance understanding of the basic pathomechanisms of inflammatory lymphangiogenesis, but in the future will also improve corneal graft survival after transplantation.

■ 3232

Diabetic macular edema - molecular pathways

JOUSSEN J
Department of Vitreoretinal Surgery, Center for Ophthalmology, Köln

Purpose Diabetic maculopathy is the leading cause of visual loss in diabetic patients. Malfunction of the blood retinal barrier plays a central role in the disease and leads to retinal edema and secondary photoreceptor dysfunction. Diabetic vascular leakage and this diabetic macular edema is regulated by a distinct combination of direct paracellular transport, alterations in the cell-cell junctions of endothelial cells and cell death of these endothelial cells. With increasing duration of diabetes, the relative relevance of these three components varies, and that with increasing duration of diabetes, the cummulative endothelial cell death will become more relevant.

Methods Leukocyte adhesion in the retinal vasculature is one of the earliest manifestations of diabetic retinopathy. We have previously shown that leukocytes are causally related to capillary non-perfusion, endothelial cell death, and vascular permeability in diabetes. However, the role of inflammation in the pathogenesis of the long-term functional and anatomic pathologies of diabetic retinopathy remains unknown. A chronic, low-grade subclinical inflammation seems responsible for many of the signature vascular lesions of diabetic retinopathy.

Results When compared to age-matched wild type controls, mice deficient in the genes encoding for the leukocyte adhesion molecules (CD18-/- and ICAM-1-/-) demonstrate a marked and sustained suppression of retinal vascular leukocyte adhesion, endothelial cell injury, blood-retinal barrier breakdown, pericyte loss and acellular capillary formation.

Conclusion Taken together, these data indicate that diabetic retinopathy is an inflammatory disease, with CD18 and ICAM-1 representing specific therapeutic targets for the prevention of vision loss.

■ 3233

Ephrin/Ephs in proliferative retinopathy - lessons from a mouse model

AGOSTINI HT
Dep. of Ophthalmology, Freiburg

Purpose Ephrins and their Eph-receptors are involved in axonal guidance during the development of the central nervous system. Receptor and ligand are both membrane bound and allow bidirectional signalling after cell to cell contact. Different elements of the Ephrin-Eph signal transduction pathway are involved in cell morphology, cell motility and cell-cell interaction. Ephrin/Ephs also influence the development of blood vessels. For example, Ephrin-B2 and Eph-B4 are asymmetrically expressed on veins and arteries and ephrin-B2 can be upregulated on endothelial cells during angiogenesis.

Methods Proliferation of retinal vessels can be induced in young mice by keeping them at 75% oxygen from postnatal day 7 to 12. When they return to room air, relative hypoxia leads to angioproliferation. Expression of angiomodulatory factors in the retina was determined by RT-PCR and quantitative PCR. Manipulation of the system is possible by intravitreal injection. Proliferative changes were evaluated by retinal wholemounts.

Results The murine retina under physiological conditions expresses both Ephrin-B2 and Eph-B4. There is a tendency towards increased Ephrin-B2 expression following oxygen exposure whereas Eph-B4 levels remain unchanged. Intravitreal injection of dimeric Ephrin-B2 or Eph-B4 leads to increased retinal angioproliferation.

Conclusion Ephrin/Ephs do not have a direct mitogenic effect on endothelial cells. However, injection of dimeric ligand or receptor can enhance retinal angioproliferation. An increase of Ephrin-B2 expression before the onset of proliferation additionally indicates an involvement of this receptor/ligand-system in retinal angiogenesis. Preliminary reports from patients with proliferative diabetic retinopathy confirm this assumption.

■ 3234

VEGF/VEGFR interactions in ocular development, physiology and disease

SCHLINGEMANN RO, WITMER AN
Ocular Angiogenesis Group, Dept of Ophthalmology, Academic Medical Center, Amsterdam

Purpose Extensive evidence implicates the VEGF family of growth factors and its three receptors in vascula functions in ocular development, physiology and disease. Different VEGFs have different functions, partly through differential affinity for the different receptors, and through the differential signaling pathways stimulated via these receptors. The functional significance of VEGFs in the eye therefore depends not only on their local production in ocular tissues but as much on cell-specific expression and signaling of their receptors. Ocular VEGF receptor expression is not limited to vascular cells, indicating additional roles of VEGFs in the eye such as in neuronal survival or other functions.

EVER-2004-abstractbook.indd 191 8/19/04 12:27:17 PM

■ 3235

Regulation of angiogenesis and vascular homeostasis through the Angiopoietin/Tie system

AUGUSTIN HG
Dept. of Vascular Biology and Angiogenesis Research, Tumor Biology Center, Freiburg

Purpose The angiopoietin/Tie system mediates remodelling and maturation of the blood vascular system. It has also been identified as a critical regulator of retinal neovascularization and retinal vessel remodeling. Angiopoietin-1 is the paracrine acting agonist of Tie2 which results in endothelial cell survival and blood vessel stabilization. Angiopoietin-2 acts as natural antagonist of Ang-1 that induces vessel regression in the absence of VEGF or remodelling in the presence of VEGF. Ang-2 is expressed by endothelial cells (EC) and, thus, acts as an autocrine regulator of EC functions. We have identified Ang-2 as an endothelial Weibel-Palade body stored molecule that can be made rapidly available upon stimulation. Analysis of Ang-2 autocrine EC functions demonstrated that Ang-2 is capable to destabilize contacts of EC and SMC in an autocrine or a paracrine manner. Based on these findings, we hypothesized that Ang-2-mediated EC destabilization controls the responsiveness of EC to exogenous cytokines. Combination experiments with Ang-2 and TNFalpha showed that Ang-2 is capable to sensitize endothelial cells towards TNFalpha-induced monocyte adhesion to EC. Correspondingly, we examined the role of Ang-2 in controlling acute inflammatory responses. Intraperitoneal thioglycollate injection results in a massive neutrophil influx in wildtype mice within 4 h. In contrast, Ang-2-deficient mice have an impaired ability to elicit an inflammatory response. The Ang-2 loss-of-function phenotype can be rescued by injection of recombinant Ang-2. Collectively, the data identify Ang-2 as an autocrine regulator of rapid endothelial cell responses thereby controlling vascular homeostasis including the response to inflammatory stimuli.

EVER-2004-abstractbook.indd 192 8/19/04 12:27:18 PM

■ 3242

Ophthalmodynamometry: From Bailliart to the contact lens dynamometer

STODTMEISTER R

Purpose Dynamometry is literally the measurement of force. Ophthalmodynamometry is the measurement of blood pressure by looking at the pulsation phenomena of the retinal vessels during the application of force to the ocular surface. In case the pulsations are registrated the method is called ophthalmodynamography. The first method of quantitative pressure enhancement was the indentation method by spring load and the second method used suction cups for this purpose. These two methods were difficult to apply and may be painful. With the advent of Doppler sonography these methods were widely abandoned because the new method promised to give more information combined with less discomfort to the patient. With a new dynamometer - consisting of a Goldmann three mirror contact lens and force sensors - ophtalmodynamometry is much easier and more comfortable. The results obtained by this method may put some Doppler results in question. Therefore, it seems to be promising to use the new method in the daily ophthalmological practice. By giving a short history of ophthalmodynamometry the basics and especially the pitfalls of this method are shown.

■ 3243

Intracranial pressure measured by venous dynamometry of the central retinal vein

MEYER-SCHWICKERATH RMS
Praxisklinik Bocholt, Bocholt

Purpose The possibility of measuring venous pressure of the central retinal vein is rarely recognized.

Methods A technical model to analyze the conditions of the venous collapse and first experience with clinical dynamometry are presented. A definition of venous collapse types is necessary.

Results With the technical model we could demonstrate that there were identical results for venous outflow pressure measured by venous dynamometry and by a intravasal pressure detector.Venous dynamometry in vivo means that we use the onset of the venous collapse phenomenon to register the pressure in the central retinal vein at the point at which it leaves the eye. The elevation of intraocular pressure for dynamometry is performed by suction cup, finger-impression- and Goldmann-contactlens – dynamometer. Any kind of retroocular obstruction of the venous outflow may be assessed. As the central retinal vein leaves the eye through the optic nerve, which is enclosed in cerebrospinal fluid, intracranial pressure can be analyzed as well.

Conclusion The venous collapse phenomenon enables us to determine the venous outflow pressure. Clinical results are promissing.

■ 3244

Clinical experience with modified ophthalmodynamometry

JONAS JB
Department of Ophthalmology, Faculty for Clinical Medicine Mannheim, Ruprecht-Karls-University, Heidelberg

Purpose Examination of the collapse pressure of the central retinal artery and central retinal vein can have importance for the diagnosis of diseases involving the lamina cribrosa, the retrobulbar part of the optic nerve, the cerebrospinal fluid space, the orbit, and the brain. Reason is that both vessels pass through the lamina cribrosa, and originate from, or drain into, structures which are located in the orbit or inside of the cranium.

Methods Using a new ophthalmodynamometric technique consisting of a Goldmann contact lens with a pressure sensor oncorporate into the holding grip was applied.

Results Recent studies have suggested that the new ophthalmodynamometric technique may be helpful to detect ischemic ophthalmopathy and to measure the cerebrospinal fluid pressure; that the assessment of the central retinal vein collapse pressure may be useful to estimate the tissue pressure in the orbit; that the central retinal vein collapse pressure may be higher in eyes with central retinal vein occlusion than in eyes with branch retinal vein occlusion or eyes with retinal venous stasis;; that the new ophthalmodynamometric technique may be useful for detecting intracranial arterio-venous fistulation; and that the central retinal vein collapse pressure may be higher in eyes with chronic open-angle glaucoma than in normal subjects. The coefficient of variation for the re-determination of the central retinal vein and artery, respectively, collapse pressure was 15.9 ± 11.9% and 9.1 ± 4.2%, resp.. Central retinal artery collapse pressure was significantly correlated with the brachial diastolic arterial pressure.

Conclusion A modified ophthalmodynamometry may be give few and additional information during a non-invasive ophthalmoscopic exmaination.

■ 3245

Quantitative evaluation of Ophthalmodynamometry in a rabbit model

REITSAMER HA (1, 2, 3)
(1) Dept Ophthalmology and Optometry, Salzburg
(2) Dept Physiology, Vienna
(3) Dept Clinical Pharmacology, Vienna

Purpose The goal of this study was to investigate the relationship between ophthalmodynamometric force measurements and blood pressure, intraocular pressure and orbital venous pressure using a modified ophthalmodynamometer in anesthetized New Zealand white rabbits.

Methods The rabbits were instrumented with hydraulic occluders around the inferior caval vein and the descending aorta. Activation of the aortic occluder redirects the heart output towards the head causing an increase of blood pressure at the eye level whereas activation of the caval occluder reduces venous return to the heart, thereby decreasing blood pressure in the entire body. Mean arterial pressure was measured with an arterial catheter in the right ear artery which was advanced to the level of the right eye. Intraocular pressure and orbital venous pressure were measured invasively by cannulation of the orbital venous sinus and the vitreous cavity respectively.

Results During subsequent caval and aortic occlusions mean arterial pressure was manipulated between 17 and 95 mmHg. Ophthalmodynamometric measurements were performed at different blood pressure levels and correlations between the measured variables were calculated.Our data show that the relationship between intraocular pressure and force measurements using the ophthalmodynamometer is linear for a certain range of forces applied to the eye.

Conclusion Since little changes in force cause substantial changes in IOP, it is conceivable that individual differences in active and passive counteracting forces from the orbicular muscle or the eye lids influences the measurements. Especially the estimation of small pressures like the pressure in the central retinal vein should be performed and interpreted with caution.

EVER-2004-abstractbook.indd 193 8/19/04 12:27:18 PM

■ 3251

The role of colour vision testing in the diagnosis and management of acquired degenerative eye diseases

ARDEN GB (1), WOLF JE (1), BERNINGER T (2)
(1) Applied vision research centre City University, London
(2) Eye Hospital Matthildenstrasse, Munich

Purpose To assess value of colour contrast measurement in patients with retinal degenerations

Methods Colour contrast thresholds were measured with "ChromaTest" (briefly flashed isoluminant coloured optotypes) and are compared to clinical examination, fundus photography and electrophysiology.

Results In persons with diabetes and no visible fundus disturbance, tritan colour contrast thresholds are elevated. The degree of elevation increases with disease duration. Persons with mild background DR have thresholds elevated above those with grade 0. When sight-threatening change in the fundus develop, tritan thresholds increase further and protan losses also occur. In elderly patients with only a few soft drusen, and minimal pigment disturbance, tritan thresholds are elevated. In persons with unioculer loss of vision caused by Age Related Macular Degeneration, the fellow eyes all have abnormal colour vision, with tritan thresholds rising as much as 8 SDs above the age matched normal thresholds before immediately sight-threatening fundal changes can be seen. There is a correlation between threshold and severity of fundus change and electro-oculographic abnormality. In patients with drug intoxications, (e.g. chloroquine) elevation of tritan threshold increases before visible fundus changes.

Conclusion Colour vision screening with computer generated flashed images may be effective because small scotomata to blue prevent character recognition. The test is quick and simple and could potentially be useful in screening populations at risk of sight thresatening disease.

■ 3252

The use of central and peripheral colour contrast threshold in ophthalmological practice

SPILEERS W
Dept of Ophthalmology University Hospitals Leuven, Leuven

Purpose To describe the use of measuring central and peripheral colour contrast thresholds in various ophthalmological conditions.

Methods Coloured stimuli, isoluminant with the background, are generated along a chosen colour axis. Central and peripheral stimuli can be used. Colour contrast thresholds are measured psychophysically.

Results Central colour contrast thresholds are used for detection and follow-up of optic neuritis, incipient maculopathy, early diabetic retinopathy, ...Peripheral colour contrast thresholds are measured in four quadrants of the visual field for the detection of early functional loss in chronic open angle glaucoma.

Conclusion Central and peripheral colour contrast thresholds are used successfully in the detection and follow-up of functional loss due to a variety of ophthalmological diseases.

■ 3253

Colour vision and cone driven signals: insights from multifocal ERG and VEP

JAEGLE H
University Eye Hopsital, Tuebingen

Methods The multifocal m-sequence technique developed by Sutter in 1992 has considerable potential for assessing retinal and cortical function. In recordings of the electroretinogram, (ERG) and visual evoked potentials (VEP), the derivation of binary kernels by means of a cross-correlation technique allows local response functions to be calculated, making it a powerful tool for assessing localized retinal pathologies. Moreover, the technique is versatile. By altering the temporal and spatial properties of the stimulus one can selectively study specific retinal cells or layers. Examination of the oscillatory potentials (Wu & Sutter, 1995, Kurtenbach & Weiss, 2002), of ON- and OFF-retinal responses (Kondo et al., 1998) and of ganglion-cell contributions to the responses (Sutter & Bearse, 1999) have provided some insight into retinal function. The topography of the cortical response to isolated M and P pathway stimulation has been examined in recordings of multifocal VEPs (Baseler & Sutter, 1997). Further, the combination of the m-sequence technique with the silent substitution technique (Estévez & Spekreuse, 1974) provides access to single cone-class driven response topographies at various stages of visual processing (Albrecht et al., 2002, Kurtenbach et al., 2004, Hood et al., 2002).

■ 3254

Methods for detection of significant changes in chromatic sensitivity

BARBUR JL
Applied Vision Research Centre, City University, London

Purpose Colour matching and the measurement of chromatic discrimination thresholds are the two most commonly used, quantitative methods for assessing colour deficiency and loss of chromatic sensitivity. The purpose of this study was to examine the correlation between the two measures.

Methods The CAD (Colour Assessment & Diagnosis) test was used to measure red-green and blue-yellow thresholds in 125 "normal" trichromats and 120 colour-deficient observers. The distribution of thresholds in normal trichromats was used to define the "normal CAD observer". This approach provides a simple way of detecting and classifying "abnormal" responses. The subjects investigated also made Rayleigh colour matches (e.g., a "yellow" match made on the Nagel anomaloscope).

Results The results confirm the large inter-subject variability in the distribution of red/green mixtures, even within "normal" trichromats. The mean red/green mixture ratio and the range of acceptable matches measured in colour deficient observers show poor correlation with CAD colour discrimination thresholds. In order to account for these findings and some unusual Rayleigh matches, a model was developed to examine how cone photoreceptor density changes, pre-receptoral absorption differences, shifts in peak photoreceptor spectral responsivity, post-receptoral amplification of cone signals and the spectral width and composition of the red-green mixture and the yellow reference field can affect the outcome of the yellow match.

Conclusion Examination of model parameters reveals the limitations of anomaloscope matches and explains, at least in part, the poor correlation between colour discrimination thresholds and the severity of colour deficiency as reflected in the parameters of the yellow match.

EVER-2004-abstractbook.indd 194 8/19/04 12:27:19 PM

■ 3255

Evaluating color vision at the earliest of ages

KNOBLAUCH K
Inserm U 371, Cerveau et Vision, Bron

Purpose Using behavioral or electrophysiological methods, its is possible to isolate and thereby demonstrate the functioning of spectral coding mechanisms in human infants within the first three post-natal months. We demonstrate that these measures can be used, exceptionally, to detect congenital and acquired deficits.

Methods Visual evoked potentials were measured from infants at 4 and 8 weeks in response to a 7.5 Hz flickering 6 deg field, with one field containing a monochromatic light of 570 nm and the other a mixture of 540 and 610 nm. The lights were adjusted so that the quantum fluctuations were equated for either rods and L or rods and M cones, thereby isolating the response of the third mechanism. In separate experiments, a forced-choice preferential looking procedure was used to estimate chromatic thresholds in the presence of random luminance noise.

Results The electrophysiological tests reveal functioning M and L cones as early as 4 weeks but with reduced VEP responses. The cone-isolating responses from some infants were attenuated for one of the conditions, suggesting a color deficiency. The behavioral paradigm also revealed some infants who could not detect chromatic modulations near protan or deutan lines. Interestingly, an infant who had experienced retinal hemorrhages failed to detect modulations along a tritan (S-cone isolating) axis.

Conclusion The integrity of infant color vision can be evaluated within the first year of life with specialized methods. These tests can be useful for assessing visual function secondary to ocular disease or pathology.

■ 3256

Long-term renormalization of chromatic mechanisms associated with aging, disease and following cataract surgery

WERNER J, DELAHUNT PB, HARDY JL
University of California, Sacramento, CA

Purpose The human visual system undergoes continuous anatomical and functional change throughout the normal life span, with additional changes in the case of age-related retinal disease. There is also continuous change in the spectral distribution and intensity of light reaching the retina from infancy through senescence, primarily due to changes in the absorption of short-wave light by the lens. We examined the consequences for color appearance.

Methods A series of studies was carried out with individuals, free of ocular and retinal disease, ranging from about 16 to 90 years of age. Using several different methods, we measured the achromatic point, unique hues, saturation and color naming. Additional tests were also carried out with individuals having diabetes and with individuals tested before and after removal of a cataractous lens.

Results Color appearance was found to be relatively stable during aging as in our more limited tests with diabetic individuals. In the latter cases, unique blue was similar to that of normals despite predicted shifts of 47 nm due to losses in sensitivity of an S-cone pathway. Measures of ocular media density for younger and older observers demonstrate that color appearance is independent of lens absorption. The achromatic point was found to shift following cataract surgery (removal of a brunescent lens) toward yellow in color space, but over the course of months, it drifted back in the direction of the pre-surgery achromatic point.

Conclusion The results of these different studies are consistent with a long-term renormalization process that compensates for age-related and perhaps disease-related change in the retinal stimulus and retinal signals.

EVER-2004-abstractbook.indd 195 8/19/04 12:27:19 PM

■ 3261

Ultrasonographic studies of ciliary muscle related to accommodation in the human eye

GUTHOFF R, STACHS O, MARTIN H
University of Rostock, Rostock

Purpose To be able to restore human accommodation many hurdles have to be taken. One of them is to show that the ciliary muscle in older eyes remains active. The aim of the study is the analysis of the muscle activity in pseudophakic eyes in comparison to that of phakic eyes.

Methods Using a special designed 3D ultrasound biomicroscope in combination with contour approximation procedures the accommodative shape changes of the ciliary muscle in human pseudophakic (mean age 66) and phakic (mean age 59) volunteers are determined. The shape changes of the pseudophakic eyes were analysed 6 month after IOL implantation. Accommodative studies have been carried out using pharmacologically induced accommodarion.

Results The 3D ultrasound biomicroscopy in combination with the developed approximation algorithm allow a qualitative description of accommodative ciliary muscle changes. During accommodation in the investigated pseudophakic eyes a shift in the ciliary muscle center of gravity of median 0.12 mm towards the lens equator in comparison to that of phakic eyes with median of 0.11 mm was observed.

Conclusion The ciliary muscle remains active in old pseudophakic eyes and is comparable to old phakic eyes. It seems that the remaining ciliary muscle activity in old eyes is no hurdle towards accommodation restoration.

■ 3262

Experimental studies of accommodation in monkeys

GLASSER A
College of Optometry, Houston, TX

Purpose Much remains to be learned about the physiological optics of accommodation and presbyopia. Rhesus monkeys have high accommodative amplitudes and develop presbyopia with the same relative age-course as humans. Studies in rhesus monkeys can provide new insights into how the adolescent primate eye undergoes accommodative changes and how these accommodative changes are altered by aging.

Methods These studies have been undertaken on six rhesus monkeys aged 6-13 years. Eyes were surgically iridectomized. Accommodation was stimulated in anesthetized monkeys via an electrode surgically implanted in the Edinger-Westphal (EW) nucleus of the brain. Accommodative optical changes were recorded dynamically with infrared photorefraction. Accommodative biometric changes were measured dynamically with continuous ultrasound biometry. Accommodative changes in ocular aberrations were measured with a Shack-Hartmann wavefront aberrometer.

Results Repeated accommodative responses are sustained with repeated EW stimulation for periods longer than 15 minutes. Peak velocity of EW stimulated accommodation increase linearly with amplitude and disaccommodation occurs faster than accommodation. As lens thickness increases during accommodation, the anterior lens surface moves anteriorly and the posterior lens surface moves posteriorly. Accommodative optical and biometric changes are highly correlated. During accommodation, the eye undergoes an increase in optical power near the axis with little or no change in optical power near the periphery.

Conclusion These studies provide insights into the physiological optics of accommodation in adolescent rhesus monkeys. The results challenge generally accepted notions that the posterior lens surface is stationary and the that lens become more uniformly spherical with accommodation.

■ 3263

In vivo studies of the human lens using corrected Scheimpflug imaging

DUBBELMAN M
VU medical centre, Amsterdam

Purpose To measure the change in shape of the aging human crystalline eye lens in vivo with age and accommodation using Scheimpflug imaging.

Methods Scheimpflug images were made of 102 subjects between 16 and 65 years of age. The images were corrected for distortion due to the geometry of the camera and the refraction of the cornea and anterior lens surface, which is necessary to determine the real shape of the lens. To ensure accurate correction for the refraction of the anterior lens surface, the refractive index of the crystalline lens must be determined. Therefore, axial length was also measured, which made it possible to calculate the equivalent refractive index of the lens.

Results The lens becomes thicker and more convex with age.With accommodation, there is a highly significant decrease in both the anterior and posterior radius of the lens. Using these results, it possible to calculate the shape of the in vivo maximally accommodated lens. This calculation shows that the shape of the maximally accommodated lens does not differ significantly from its shape measured in vitro, which supports the accommodation theory of Helmholtz.

Conclusion The increase in the power of the lens due to its more convex shape with age is compensated by a decrease in the equivalent refractive index, which explains the so-called lens paradox (Brown, 1974: emmetropia is maintained despite steepening of lens curvature in old age). The change in shape of the lens with age is much larger than the change during accommodation.The posterior lens surface does not play a negligible role during accommodation, since the accommodative power changes due to the more convex shape of the lens are caused for approximately 64% by the anterior lens surface and for 36% by the posterior lens surface.

■ 3264

To investigate the changes in position of the lens surfaces during accommodation

VAN DER HEIJDE RGL
Physics and Medical Technology, Amsterdam

Purpose To investigate the changes in position of the lens surfaces during accommodation.

Methods Several methods ara available to measure the thickness of the lens. However, only continuous ultrasound biometry (CUB) seems to be able to registrate the tiny movements of the crystalline lens or an IOL during accommodation. Because the ultrasonographic transducer is attached to the eye, CUB is able to measure changes with precision of less than 2 micrometer.Real time measurements of sound velocity of (parts of) the lens are possible.

Results The velocity of sound appeared to be independent of age. The measurements were analysed using a biomechanical model to compare the far-to-near and near-to-far accommodation dynamics.

Conclusion The fact that the velocity of sound in the human lens does not change with age, combined with the results of the analysis of the biomechanical model, support a lenticular cause of presbyopia.

EVER-2004-abstractbook.indd 196 8/19/04 12:27:20 PM

■ 3265

We were not born to read

WEALE R
King's College, London

Purpose A re-examination of the literature suggests that efforts devoted to the production of accommodative lens implants may be premature. Not only is there conflicting information about the functional performance of the aged ciliary muscle which may determine their performance, but doubts exist on the performance of the ageing lenticular capsule in connection with some types of implant. It would seem important to address these matters, and also to ensure that any change in the optical power of the eye that is successfully achieved is large enough for reading glasses to become unnecessary. However, not all these strictures apply to the development of accommodative lens implants for children who may have lost their natural lenses following operations e.g. for congenital cataracts.

■ 3266

Lenticular accommodation in relation to ametropia: the chick model

CHOH V (1), SIVAK JG (2)
(1) School of Optometry, Berkeley, CA
(2) School of Optometry, Waterloo, Ontario

Purpose To determine whether experimentally-induced ametropias have an effect on lenticular accommodation and spherical aberration.

Methods Form-deprivation myopia and hyperopia were induced in one eye of hatchling chicks by the application of a translucent goggle and +15 D lens, respectively. After 7 days, eyes were enucleated and lenses were optically scanned prior to accommodation, during accommodation and after accommodation. Accommodation was induced by electrical stimulation of the ciliary nerve.

Results Lenticular focal lengths for form-deprived eyes were significantly shorter than for their controls and accommodation-associated changes in focal length were significantly smaller in myopic eyes compared to their controls. For eyes imposed with +15 D blur, focal lengths were longer than those for their controls and accommodative changes were greater. Spherical aberration of the lens increased with accommodation in both form-deprived and lens-treated birds, but induction of ametropia had no effect on lenticular spherical aberration in general. Lenticular optical quality was degraded during accommodation but effects of refractive error on optical quality were equivocal.

Conclusion The crystalline lens contributes to refractive error changes of the eye both in the case of myopia and hyperopia. These changes are likely attributable to global changes in the size and shape of the eye.

EVER-2004-abstractbook.indd 197 8/19/04 12:27:20 PM

■ 3311

Supplementation of zinc may benefit glaucoma patients

OSBORNE NN
Nuffield Laboratory of Ophthalmology, Oxford University, Oxford

Purpose Primary open angle glaucoma (POAG) is an optic neuropathy characterised by morphological changes in the optic disc and retinal ganglion cell loss. It is a neurodegenerative disease because ganglion cell loss is gradual that can take place over 30 years or more. The factor(s) that initiate the disease and determine the rate of ganglion cell loss remain(s) unknown. Neuroprotection is a concept that has been applied for the treatment of neurodegeneration where it is envisaged that pharmacological agents can be used to attenuate the death rate of the neurones rather than to prevent the initiation of the insult. For any substance to potentially attenuate ganglion cell death in glaucoma it is necessary for it to reach the retina in sufficient amounts to elicit a positive response. Moreover, since most patients with POAG lead a fairly normal life any pharmacological agent used to treat the disease must have minimum side effects. One such potential substance is zinc, which can be taken orally with no obvious side effects.The actual cause of ganglion cell apoptosis in POAG remains a matter of debate. However, a body of evidence exists to support the opinion that excessive depolarisation caused by overactivation of glutamate NMDA receptors and the generation of reactive oxygen species (ROS) is the cause of ganglion cell death. It is also known from laboratory studies that free zinc concentrations work in concert with glutamate to determine the activity of the NMDA receptor. In addition, zinc levels relate to the activity of important antioxidant enzymes, such as the metallothioneins and catalase. Thus, it might be predicted that a deficiency in free zinc concentrations will make a ganglion cell more susceptible to glutamate toxicity while an elevation of circulating zinc would have the opposite effect. Laboratory studies generally support this proposition and these will be briefly summarised. It is therefore proposed that zinc supplementation (possible in combination with other antioxidants) may benefit glaucoma patients as has been demonstrated in a subset of people with age-related macular degeneration.

■ 3312

Neuroprotection of Cones in Retinitis pigmentosa

SAHEL JA (1, 2, 3), LEVEILLARD T (4)
(1) University Paris VI and Institute of Ophthalmology UCL, Paris
(2) Inserm U592, Paris
(3) CHNO des XV-XX and Rothschild Ophta Foundation, Paris
(4) Inserm U 592, Paris

Purpose Neuroprotection of photoreceptor cells in rod-cone degenerations is primarily targeted at preventing the loss of function. Strategies for protecting rod cells should therefore aim not only at structural preservation but also must be assessed using functional parameters (e.g. ERG). Given the number of mutations leading to an impaired visual response of rods, the preservation of cones is a realistic approach since 1) numerous mutations do not affect proteins expressed by cones; 2) the secondary degeneration of cones is the main event leading to profound visual impairment; 3) even a small proportion of functional cones is sufficient for major visual functions.

Methods We applied an expression cloning protocol to the identification of factors involved in protecting cone photoreceptors in vitro and in vivo (Leveilllard et al, Nature Genetics, July 2004, 754-758

Results Our group has 1) established and confirmed the existence of non cell autonomous mechanisms promoting cone cell viability; 2) shown that rod cell protection or replacement provides a mean to extend the survival of cones; 3) demonstrated that rod-cone trophic interactions are mediated by diffusible proteins; 3) identified by expression cloning a protein mediating such interactions: RdCVF (Rod derived Cone Viability Factor).

Conclusion These studies provide a rationale for protecting non functional rods and clues for broad neuroprotective therapies of rod-cone dystrophies.

■ 3313

Retinal ischemia alters axonal transport in retinal ganglion cells: neuroprotective effects of brimonidine.

VIDAL-SANZ M (1), MAYOR S (1), LAFUENTE MP (1), GARCIA A (1), BERNAL JM (2), VILLEGAS-PEREZ MP (2)
(1) Oftalmología. Universidad de Murcia, Murcia
(2) Oftalmolgía. Universidad de Murcia, Murcia

Purpose To study the effects of brimonidine (BMD) on axonal transport alterations in retinal ganglion cells (RGC) induced by ischemia.

Methods In adult SD rats the left ophthalmic vessels were ligated for 90 min. Rats received in their left eyes 1 h before ischemia, two 5 µl drops of saline or 0.5% BMD. Retrograde transport was investigated by comparing 1 or 2 weeks after ischemia (a.i.) the densities of RGCs retrogradely labeled with fluorogold applied to both superior colliculi (SCi) either 1 w before, or 1 h or 1 week a. i. Orthograde transport was investigated by comparing 2 months a. i. afferents to the SCi labelled with Cholera Toxin B subunit (CTB) injected into the ischemic eyes. Five days after CTB intraocular injections, their midbrains were sectioned on the cryostat and processed for CTB-immunohistochemistry.

Results In animals treated with saline approximately 15% of the RGCs that survived ischemia had their retrograde transport impaired. In the BMD-treated animals, RGC densities amounted to 90% of the RGC population 7 or 14 days a. i. The densities of CTB-labeled profiles in the contralateral SC of the vehicle-treated rats represented less than 1/2 the area occupied by CTB-labeled profiles in control rats, whereas in BMD-treated rats CTB-immunoreactivity occupied 86% of the area in the unlesioned group.

Conclusion Retinal ischemia induces RGC loss, alters axonal transport in surviving RGCs and results in degeneration of retino-tectal afferents. BMD prevents ischemia-induced RGC death, preserves retrograde axonal transport in surviving RGCs and protects against ischemia-induced degeneration of the retinotectal projection. Gran Support: BFI-2002-03742, Allergan unrestricted.

■ 3314

Evidence for neuroprotection in experimental ocular hypertension

WHEELER LA, WOLDEMUSSIE E, HARE WA
Biological Sciences, Allergan, Irvine, CA

Purpose A chronic progressive loss of retinal ganglion cells(RGCs) is responsible for vision loss in glaucoma. A growing understanding of mechanisms associated with injury and death of neuronal cells provides new targets for drug discovery and therapy. Animal models of experimental ocular hypertension lead to selective loss of RGCs. Possible mechanisms to explain the progressive loss of RGCs in human glaucoma and experimental models are: glutamate excitoticity; loss of trophic factors; nitric oxide, reactive oxygen species, etc. All of these mechanisms can drive apoptotic death of RGCs. Apoptosis is a genetically controlled process involving genes that induce cell death pathways or increase survival pathways. Drugs that influence apoptotic pathways or mechanisms of neuronal injury have been tested in chronic ocular hypertensive (COHT) models.

Methods Experimental ocular hypertension induced by laser in rats (WoldeMussie, IOVS, 2001)and primates (Hare, IOVS, 2002)causes RGC loss. Drugs that upregulate intrinsic survival pathways or block death signals were tested in the above models of hypertension.

Results Increases in GFAP, BAX, Caspase 3 etc. with increased IOP have been observed. Pharmacological approaches such as upregulation of survival factors with alpha-2 agonists and compounds that block the NMDA-ion channel are efficacious in the rat COHT model. Non-invasive methods for quantification of structural and functional effects of RGC injury and survival were used to test neuroprotective compounds in the laser induced COHT primate.

Conclusion Drugs targeting the pathways of stress, injury and death of RGCs can protect them from chronic ocular hypertensive injury. Neurprotection in glaucoma provides a direct means of protecting RGCs in addition to lowering IOP.

EVER-2004-abstractbook.indd 198 8/19/04 12:27:20 PM

■ 3315

Neuroprotection in randomized clinical glaucoma trials

GANDOLFI S
University Eye Clinic, Parma

Purpose Neuroprotection is extremely difficult to be proven in humans , in general, and in glaucoma patients in particular. Properly randomized and controlled clinical trials are mandatory. The success of a trial is greatly dependent on several issues:(a) definition of the outcome(b) selection of the patients(c) length of the study(d) estimate of attrition(e) statistical power(f) clinical relevance of the resultsThis presentation will focus on possible scenarios a scientist must be prepared to face when planning a clinical trial on neuroprotection in glaucoma. In particular, the rationale and the procedures adopted in a recently completed trial on brimonidine in progressing human glaucomatous eyes will be discussed.

EVER-2004-abstractbook.indd 199 8/19/04 12:27:21 PM

■ 3321

Choroidal blood flow regulation in the healthy human eye. A review

RIVA CE (1, 2)
(1) Faculty of Medicine, University of Lausanne, Lausanne
(2) Institut de Recherche en Ophtalmologie, Sion

Purpose In recent years, new non-invasive techniques have been developed to obtain quantitative information on choroidal blood flow (ChBF) and its regulation. Our aim was to review data pertaining to the response of this flow to a variety of physiological stimuli in the healthy human eye.

Methods Changes in various hemodynamical parameters of the choroidal circulation were obtained in response to a number of physiological perturbations using different techniques, including indocyanine green angiography-based techniques, pulsatile ocular blood flow (POBF), laser interferometry for pulsatile ChBF, laser speckle and subfoveal ChBF by laser Doppler flowmetry. Physiological stimuli included changes in the concentration of various gases in the arterial blood (O2, CO2, carbogen), changes in ocular perfusion pressure by modification of the intraocular pressure (IOP) or the systemic blood pressure, the latter by dynamic and static exercise, and light dark transitions.

Results Determination of the magnitude and time course of the responses to the different stimuli show that ChBF does not respond to hyperoxia, increases in hypercapnia and during carbogen breathing. ChBF varies little when the arterial blood pressure is increased moderately during isometric and dynamic (biking) exercises. A decrease of the ocular perfusion pressure induced by an acute increase in IOP results in a moderate autoregulatory response. The transition from light to darkness induces a slow decrease of ChBF.

Conclusion These results show that ChBF in the human eye is mainly controlled by autonomic innervation. However, some local control may also be operative. Further investigations are needed to fully elucidate the mechanisms underlying the regulation of ChBF.

■ 3322 / 254

Sub-foveal Choroidal Blood Flow in Healthy Individuals Before and After Timolol Maleate Administration

FALSINI B (1), GEISER M (2), GALAN ME (1), RIVA CE (3)
(1) Ophthalmology, Universita' Cattolica, Rome
(2) Institut de Recherche en Ophthalmologie, Sion
(3) Institut de Recherche en Ophtalmologie, Sion

Purpose To evaluate changes in sub-foveal choroidal blood flow of healthy individuals before and after Timolol Maleate administration.

Methods Fourteen normal subjects were enrolled in a double-blind, placebo-controlled study. One eye received a drop of Timolol Maleate 0.50%, while the fellow eye had placebo. Choroidal blood flow was measured by confocal laser Doppler flowmetry before and 30, 60 and 120 min after drug or placebo administration. Blood velocity, volume and flow were the main outcome variables.

Results Change detection sensitivities from baseline values were estimated to be 7, 16 and 13% for velocity, volume and flow, respectively. Timolol administration did not induce significant changes in any of these flow parameters compared to placebo. Mean flow parameter changes did not exceed 15% from baseline in either placebo or Timolol group.

Conclusion Locally administered Timolol Maleate does not induce detectable changes in choroidal blood flow in healthy volunteers. The present data may have potential implications for better understanding the therapeutic response to beta-blockers in glaucomatous eyes.

■ 3323

Choroidal blood flow in AMD

GRUNWALD JE, METELITSINA T, DUPONT J
Ophthalmology, Philadelphia

Purpose To investigate the potential role of choroidal blood flow abnormalities in AMD, we studied the relationship between choroidal blood flow changes and fundus features associated with increased risk for choroidal neovascularization (CNV).

Methods This study included 23 control eyes of 15 normal subjects and 148 eyes with early AMD characteristics of 96 AMD patients. AMD eyes were divided into 3 groups according to increasing risk for the development of CNV : 1) drusen ≥63μ in study eye and no CNV in the fellow eye, 2) drusen ≥63μ and RPE hypertrophy in study eye and no CNV in fellow eye, and 3) eyes with CNV in the fellow eye. Visual acuity was 20/40 or better in the study eye. Following pupillary dilatation, laser Doppler flowmetry (Oculix) was used to assess relative choroidal blood velocity (ChB Vel), volume (ChB Vol) and flow (ChB Flow) in the center of the fovea of the study eyes. Differences in the mean circulatory parameters between groups of eyes were assessed using analysis of variance (ANOVA) and a test of linear trend, with adjustment for the correlation between eyes.

Results Mean ChB Vel, ChB Vol and ChB Flow decreased with increased risk for CNV (linear trend, $p = 0.01$, $p = 0.02$, and $p = 0.002$, respectively). ChB Vel and ChB Flow were still significant ($p = 0.007$, and $p = 0.02$, respectively) after adjusting for covariates that had a significant effect on the measured parameter. The lowest circulatory values were observed in group 3 that included the eyes with the highest risk for CNV development.

Conclusion There is a systematic decrease in choroidal circulatory parameters with an increase in the severity of AMD features associated with risk for the development of CNV, suggesting a role for ischemia in the development of CNV.

■ 3324

Limitations and possibilities in assessing choroidal perfusion in AMD patients with currently available technology

SCHMETTERER L (1, 2)
(1) Clinical Pharmacology, Vienna
(2) Medical Physics, Vienna

Purpose There is increasing evidence that choroidal perfusion abnormalities are involved in the pathogenesis of age-related macular degeneration (AMD). Despite improvements in measurement of choroidal perfusion in humans all currently available techniques have significant limitations.

Methods A number of studies in patients with AMD and healthy controls is summarized. Special emphasis is placed on the effect of photodynamic therapy (PDT) on choroidal blood flow and on the limitations of the techniques in assessing this effect.

Results Our results indicate reduced choroidal blood flow in patients with AMD confirming previous studies. In addition, choroidal blood flow data as assessed with laser Doppler flowmetry after PDT are difficult to interpret, because of the pronounced morphological changes induced by this intervention. Results with laser interferomtric measurement of fundus pulsation amplitude indicate slightly reduced pulsatile choroidal blood flow after PDT.

Conclusion It appears that no single method is capable of assessing all aspects of choroidal perfusion abnormalities in AMD. Accordingly, clinical trials in patients with AMD should employ as many techniques as possible.

EVER-2004-abstractbook.indd 200 8/19/04 12:27:21 PM

■ 3325

Choroidal circulatory failure in AMD

POURNARAS CJ (1), RIVA CE (2), LOGEAN E (2)
(1) Department of Ophthalmology, University Hospital of Geneva, Geneva
(2) Institute for Research in Ophthalmology, Sion

Purpose To evaluate changes of sub-foveal choroidal blood flow and its regulation in AMD patients as ICG angiographic analysis of the choroidal circulation and Color Doppler imaging findings indicated a reduction of flow in the posterior ciliary arteries circulation in those patients.

Methods Laser Doppler flowmetry (LDF) was used to determine changes of subfoveal choroidal blood velocity (ChBvel), choroidal blood volume (ChBvol) and choroidal blood flow (ChBf) during isometric excercise. Measurements performed at baseline and at the end of exercise in 24 eyes of healthy volunteers (mean age 68 ± 4 years) were compared to those obtained in 23 eyes of age-matched patients presenting a subfoveal neovascular AMD (mean age 70 ± 5 years).

Results There was no significant difference in sex, age, blood pressure or intraocular pressure between both groups. The mean elevation of the perfusion pressure (PPm) during isometrics was similar in all groups (respectively 20 ± 4% and 23 ± 4%) (paired t-test $P < 0.05$). During isometric exercise, no significant changes occurred in the LDF parameters in the healthy volunteers ($P > 0.05$). In contrast, the increases in all LDF parameters (7+7 % for ChBvel, 7+7 % for ChBvol and 12 + 5 % for ChBf) in the eyes with neovascular subretinal tissue were significant.

Conclusion Acute and moderate elevation of the arterial blood pressure induced by isometric exercise did not affect subfoveal choroidal blood flow in elderly normal subjects. In contrast, patients with AMD demonstrated a significant increase of this flow within the neovascular tissue. This effect was attributed to a lack of regulation in response to the increase in blood pressure

■ 3326

Choroidal circulatory changes in central serous chorioretinopathy

PETROPOULOS IK (1), RIVA CE (2), STANGOS AAN (1), PETRIG BL (2), POURNARAS CJ (1)
(1) Department of Ophthalmology, Geneva University Hospitals, Geneva
(2) Institut de Recherche en Ophtalmologie, Sion

Purpose To investigate the regulation of subfoveal choroidal blood flow (ChBF) in response to an increase of the perfusion pressure (PPm) in patients with central serous chorioretinopathy presenting a subfoveal choroidal hyperfluorescent plaque in ICG-angiography.

Methods Measurements were performed in 10 eyes of 10 patients with central serous chorioretinopathy presenting a subfoveal choroidal hyperfluorescent plaque in ICG-angiography. Laser Doppler flowmetry (LDF) was applied to calculate relative ChBF in response to increases in PPm. PPm was raised through an increase in systemic blood pressure induced by isometric exercise. Three parameters were measured: the mean velocity (Vel), the number (Vol), and the flux (F) of erythrocytes at the subfoveal area. The patients used no medication that could affect ChBF, either locally or systemically.

Results Mean ophthalmic arterial blood pressure increased during isometric exercise from 67 to 91 mmHg (39% mean increase), resulting in a 49% mean increase of the PPm. This change induced a statistically significant increase in mean Vel (16.9%, $p<0.01$) and in mean F (18.7%, $p<0.05$), whereas the increase in mean Vol was not significant (2.2%, $p>0.5$).

Conclusion The LDF parameters, measured at the subfoveal area, indicated an abnormal ChBF regulation in response to an increase of the PPm in patients with central serous chorioretinopathy. Local vascular resistance did not increase and failed to maintain a constant blood flow. This suggests some alteration of the vessel tone regulatory mechanisms in the ICG-hyperfluorescent plaque observed at the subfoveal area in central serous chorioretinopathy patients.

■ 3327

Choroidal blood flow regulation in patients with CSC

WEIGERT G (1), MAAR N (2), TITTL M (2), LUKSCH A (1, 2), STUR M (2), SCHMETTERER L (1, 3)
(1) Clinical Pharmacology, Vienna
(2) Ophthalmology, Vienna
(3) Biomedical Engineering and Physics, Vienna

Purpose Central serous chorioretinopathy (CSC) is an exudative macular disease that predominantly affects young to middle-aged men. Angiographic images of the fundus indicate choroidal perfusion abnormalities in CSC. Little information is, however, available regarding quantitative data on choroidal blood flow in CSC.

Methods In the present study 15 patients with CSC and 15 healthy age-matched control subjects were studied. Continuous laser Doppler flowmetry was done during a 6 minutes squatting period to assess choroidal blood flow regulation during an increase in ocular perfusion pressure. Systemic blood pressure was measured in 1 minute intervalls and intraocular pressure was measured at baseline and at the end of the squatting period. This allows for calculation of ocular perfusion pressure.

Results In healthy subjects squatting induced a pronounced increase in ocular perfusion pressure paralleled by an increase in choroidal blood flow. This increase was, however, less pronounced than the increase in perfusion pressure indicating for a regulatory vasoconstrictor response of the choroid. In patients with CSC the increase in choroidal blood flow was more pronounced than in healthy subjects despite a comparable increase in ocular perfusion pressure ($p < 0.001$).

Conclusion The present study indicates that patients with CSC show an inadequate choroidal vasoconstrictor response to squatting. The reason for this choroidal dysregulation remains to be established.

EVER-2004-abstractbook.indd 201 8/19/04 12:27:22 PM

■ 3331

Corneal Hemangiogenesis And Lymphangiogenesis Immediately Following Penetrating Keratoplasty Are Triggered By Surgery And Wound Healing Rather Than Alloimmunity

MARUYAMA K (1), CURSIEFEN C (2), JACKSON DG (3), DANA R (1), STREILEIN JS (1), STREILEIN JW (1)
(1) Harvard Medical School, Schepens Eye Research Institute, Boston
(2) Department of Ophthalmology Univ Erlangen, Erlangen
(3) Molecular Immunology Group, Institute of Molecular Medicine, University of Oxford, Oxford

Purpose The development of new blood and lymph vessels in the graft bed following penetrating keratoplasty (PK) is known to be a risk factor for graft failure. We wished to determine the extent to which neoangiogenesis in this setting arises from the recipient alloimmune response, as opposed to the impact of surgery and wound healing.

Methods Orthotopic corneal transplants were performed with C57BL/6 donors, and BALB/c and CB17 SCID recipients. At three and 7 days post transplantation, flat mounts were prepared from graft-containing corneas and analyzed morphometrically for the presence of blood and lymph vessels using double immunofluorescence with CD31 as a panendothelial-marker and LYVE-1 as a lymphatic vascular endothelial cell-specific marker.

Results Blood and lymph vessels emerged simultaneously from limbal vessels at 3 days post-transplantation in graft-bearing corneas of BALB/c, immune-deficient recipient and completely allo-immunized mice. Moreover, blood and lymph vessels types penetrated the graft-host interface by 7 days in both recipient types and immunized mice.

Conclusion Since neoangiogenesis and lymphangiogenesis that arise in graft beds during the first week post-PK are equally robust in normal and immune-deficient recipients, surgical trauma and wound healing responses, rather than alloimmunity, are the primary source of this risk factor for graft failure.

■ 3332

Inhibition of Hem- and Lymphangiogenesis after Normal-Risk Corneal Transplantation Improves Graft Survival

CURSIEFEN C (1, 2), DANA MR (2), WIEGAND S (3), KRUSE FE (1), STREILEIN JW (2)
(1) Dept. of Ophthalmology, University of Erlangen-Nürnberg, Erlangen
(2) Schepens Eye Research Institute, Harvard Medical School, Boston
(3) Regeneron Pharmaceuticals Inc., Tarrytown, NY

Purpose To evaluate the feasibility of the new concept of improving corneal graft survival by modulating hem- and lymphangiogenesis after keratoplasty. Occurrence and time course of hem- and lymphangiogenesis after normal-risk corneal transplantation in the mouse model were analyzed.

Methods Normal-risk allogeneic (C57BL/6 to BALB/c) and syngeneic (BALB/c to BALB/c) corneal transplantations were performed and hem- and lymphangiogenesis after keratoplasty observed using double immunofluorescence of corneal flatmounts (CD31 as panendothelial and LYVE-1 as lymphatic vascular endothelial specific marker). A molecular trap designed to eliminate VEGF-A (VEGF TrapR1R2; 12.5 mg/kg) was tested for its ability to inhibit both processes after keratoplasty and to promote long-term graft survival.

Results No blood or lymph vessels were detectable immediately after normal-risk transplantation in either donor or host cornea, but hem- and lymphangiogenesis were clearly visible at day 3 after transplantation. Both vessel types reached donor tissue at one week after allo- and similarly after syngeneic grafting. Early postoperative trapping of VEGF-A significantly reduced both hem- and lymphangiogenesis and significantly improved long-term graft survival (78% versus 40%; $p<0.05$).

Conclusion There is concurrent, hem- and lymphangiogenesis after normal-risk keratoplasty within the preoperatively avascular recipient bed. Inhibition of hem- and lymphangiogenesis (afferent and efferent arm of an immune response) after normal-risk corneal transplantation improves long-term graft survival, establishing early postoperative hem- and lymphangiogenesis as novel risk factors for graft rejection even in low-risk eyes.

■ 3333

Effect of different immunosuppressive treatment strategies on natural killer cell involvement in corneal allograft rejection

CLAERHOUT I (1), KESTELYN Ph (1), BEELE H (2), LECLERCQ G (3)
(1) Department of Ophthalmology, Ghent University Hospital, Ghent
(2) Tissuebank, Ghent University Hospital, Ghent
(3) Department of Immunology, Ghent University Hospital, Ghent

Purpose To examine the effect of different immunosuppressive regimens on corneal graft survival and to analyze the effect of these drugs on natural killer (NK) cell involvement in the rejection.

Methods A postoperative versus a combined pre- and postoperative treatment regimen of cyclosporine A (CsA) and mycophenolate mofetil (MMF) was compared. The effect of CsA and MMF treatment on poly I:C mediated NK cytotoxicity was evaluated.

Results Both CsA and MMF induced a significant prolongation of graft survival. However, none of these two treatment regimens offer a beneficial effect when administerd both pre- and postoperative instead of postoperative only. There was a gradual increase of CD4+, CD8+ and CD25+ graft infiltrating cells in the control group. The influx of these cells was significantly reduced in all treatment groups. The most striking finding was the presence of CD161+ NK cells in the control group, which was significantly decreased in all treatment groups. The effect of CsA and MMF treatment on NK cell involvement in corneal allograft rejection seems to be indirect, since none of the treatment regimens was able to impair poly I:C-mediated stimulation of NK cytotoxicity.

Conclusion Preoperative administration of CsA or MMF does not additionally improve corneal graft survival. The presence of NK cells is significantly reduced by CsA and MMF treatment, although this effect is probably indirect.

■ 3334

Gene transfer of AdCTLA4-Ig prolongs experimental corneal allograft survival

PLEYER UP (1, 2, 3), YANG J (4), GONG N. (4), VOGT K (2), HEMPEL M (2), ANEGON L (3), RITTER T (2)
(1) Charité University Medicine, Dept. of Ophthalmology, Berlin
(2) Institute of Medical Immunology, Berlin
(3) Institut National de la Santé et de la Recherche medicale U 437, Nantes
(4) Charité – University Medicine, Berlin

Purpose To investigate the effect and mechanisms of blocking co-stimulatory signals on experimental corneal transplant survival by systemic CTLA4-Ig gene therapy.

Methods A total of 18 female Lewis rats received 3.5 mm corneal grafts of MHC class I/II disparate DA donors. Recipients were randomly assigned to receive either (1) no therapy, (2) a single i.p. injection (1x109 pfu/animal) of AdCTL4-Ig or (3) a single Adß-Gal (control) i.p. injection one day before transplantation. The immunoregulatory effect of this treatment was examined by intracorneal cytokine expression using quantitative RT-PCR (day 12 post transplant).

Results Treatment with i.p. injection of AdCTL4-Ig was effective ($p<0.05$) in prolonging the mean survival time of corneal grafts (26.3+/-6.7 days) compared to Adß-Gal application (13.6+/-1.1 days). Quantitative RT-PCR analysis of cornea explants (day 12 post transplant) revealed diminished expression of proinflammatory cytokines (IL-2, TNF-alpha) in the AdCTLA4-Ig group compared to Adß-Gal treated animals.

Conclusion Gene-based administration of CTLA4-Ig prolongs allograft survival by systemic application before grafting and is sufficient to down-regulate the systemic allo-specific immune response as well as the intra-corneal pro-inflammatory cytokine expression.Supported by: DFG PL150/14-1 and Charité-Research Grant

EVER-2004-abstractbook.indd 202 8/19/04 12:27:22 PM

■ 3335

Descemet's membrane retained during penetrating keratoplasty

JASTANEIAH SJ
KKESH, Riyadh

Purpose To describe the complication of Descemet's membrane (DM) inadvertently retained during repearted penetrating keratoplasty (PKP)

Methods Case report and litreture review: A 70-year-old man who had failed corneal graft after aphakic bolous keratopathy was admitted to repeat the PKP. During the procedure, an inadertently retained DM was noticed while suturing the corneal graft. It was managed intraoperatively by excising the membrane and suturing a new corneal graft.

Results Clear corneal graft with deep anterior chamber. No residual DM or pseudochamber was seen postoperatively. Histopathology confirmed daignosis.

Conclusion Descemet's membrane retained inadvertently after PKP is a known but rare complication. Early intraoperative recognition and management is important to avoid complications and save the patient from another procedure.

■ 3336

Artificial Cornea- Rapport of Human Corneal Cells and Animal Tests

GAN L (1), FAGERHOLM P (1), LIU Y (2), CARLSSON D (3), GRIFFITH M (2)
(1) Ophthalmology, Linköping University, Linköping
(2) University of Ottawa Eye Institute, Ottawa
(3) ICPET, National Research Council Canada, Ottawa, Canada, Ottawa

Purpose Our aim was to evaluate the response of rabbit corneas and human cornea cells to the tissue-engineered bio-synthetic corneal substitutes.

Methods Two groups of the tissue engineered (TE) corneas (10 mm in diameter and 350 µm in thickness) with different compositions were tested (total 20 rabbits). The first group of the implants were sutured to the human corneal rims and organ cultured for three different time points prior to processing for evaluation. The second group implants were transplanted to the rabbit's corneas by deep lamellar keratoplasty (DLKP) and penetrating keratoplasty (PK). The animals were evaluated clinically for 4 months, after which the corneas containing implants as well as untreated controls were processed for histopathological examination.

Results The TE corneas showed very good engraftment within the hosts and the epithelial cells covered the implant surface within the first week. At later time points, the host keratocytes migrated into the implants and in the cases of PK endothelial cells also will be reported. Wound healing of these implants were smooth. Most of the transplants were transparent after 4 months, and no immune rejection observed. Histology showed good biocompatibility and host integration.

Conclusion TE corneas were successfully transplanted into rabbits with no adverse reaction. The smooth wound healing process and in-growth of the host cells into the implants show that TE corneal constructs that allow regeneration are possible in the future.

■ 3337 / 353

Topical hydrosoluble prodrug of cyclosporin A to prevent corneal graft rejection

BOURGES JL (1), VALAMANESH F (2), AGLA EK (1), LALLEMAND F (3), GURNY R (4), JEAN-MAURICE D (5), BESSEGHIR K (5), BEHAR-COHEN FF (6, 2)
(1) ophthalmology, Hotel-Dieu Hospital, Paris
(2) INSERM U598, Paris
(3) Biopharmaceutics, University of Geneva, Lausanne
(4) Biopharmaceutics, University of Geneva, Geneva
(5) DeBiopharm, Lausanne
(6) Ophthalmology, Rothschild Foundation, Paris

Purpose UNIL-088 is a hydrosoluble prodrug, enzymatically converted into cyclosporin A (CsA), within minutes after contact with tears. The aim of the study was to evaluate the effect of topically applied UNIL-088 on acute corneal graft rejection in rat eyes and to compare its effect to CsA systemic administration.

Methods Fifty-two Lewis rats with technically successful corneal allografts from Brown Norway donors were included. UNIL-088 (Debiopharm,Switzerland), dissolved at 0.2% in phosphate buffer saline was instilled 5 times/day. Rats were divided in 3 groups: Group I received PBS, 5 times/day (n=18); Group II received UNIL-0880.2% drops in PBS 5 times a day (n=18); and Group III received systemic CsA 10mg/Kg/day (n=16). Treatments were administered for 2 weeks. The rejection evaluation was based on graft opacity, edema and neovascularization. Blood levels of CsA were measured 2 and 13 days after surgery.

Results On day 13, group II and III had significantly less graft rejection in all parameters tested versus group I (p= 0.026 for group II vs. I, and p= 0.013 for group III vs. I, chi2 test). On day 13, CsA blood levels were above 1,000 ng/ml in group III, but below 40 ng/ml in group II.

Conclusion Topical instillation of 0.2% UNIL-088 efficiently reduce corneal graft rejection as well as systemic CsA after conversion of the prodrug to active CsA and local release, while preventing CsA systemic adverse effects. Blood CsA levels after UNIL-088 administration were below the detection limits.

■ 3338 / 354

The role of T Helper 1 (Th1) and Th2 cytokines in corneal graft rejection

HOLAN V (1), VITOVA A (1), PINDJAKOVA J (1), KRULOVA M (1), ZAJICOVA A (1), FILIPEC M (2)
(1) Institute of Molecular Genetics, Prague
(2) Dept. Ophthalmol., 1st Medical Faculty, Prague

Purpose To investigate expression of genes for cytokines and other immunologically relevant molecules in rejected corneal allografts and xenografts.

Methods Corneal grafts from syngeneic (BALB/c mouse), allogeneic (B10 mouse) or xenogeneic (Lewis rat) donors were grafted orthotopically in mouse BALB/c recipients. The recipients were untreated or treated with monoclonal antibody (mAb) anti-CD4 or anti-CD8. Expression of genes for Th1 cytokines interleukin (IL)-2 and interferon (IFN)-g and Th2 cytokines IL-4 and IL-10 and for inducible nitric oxide synthase (iNOS) in the grafts was detected by RT-PCR.

Results Rejection of corneal allografts was associated with a strong expression of genes for Th1 cytokines IL-2 and IFN-g and a low expression of Th2 cytokines IL-4 and IL-10. On the contrary, a strong upregulation of genes for IL-4 and IL-10, in addition to the expression of Th1 cytokines, was found in rejected corneal xenografts. Treatment of graft recipients with mAb anti-CD4, but not with mAb anti-CD8, resulted in suppression of all upregulated genes and in a significant prolongation of survival of both corneal allografts and xenografts. Rejection of the grafts was always associated with expression of genes for IFN-g and iNOS and occured even in the absence of detectable IL-2, IL-4 or IL-10. There was not detectable expression of genes for cytokines in syngeneic grafts.

Conclusion Corneal allotransplantation induces typical Th1 cytokine response, while rejection of corneal xenografts is associated with a high production of both Th1 and Th2 cytokines. However Th2 cytokines are not needed for xenograft rejection. Rather, rejection of both allografts and xenografts correlates with the expression of genes for IFN-g and iNOS.

EVER-2004-abstractbook.indd 203 8/19/04 12:27:23 PM

■ 3339 / 355

Roles of Thrombospondin-1 and -2 in Maintaining Corneal Angiogenic Privilege

CURSIEFEN C (1, 2), DANA MR (2), LAWLER J (3), STREILEIN JW (2)
(1) Dept. of Ophthalmology, University of Erlangen-Nürnberg, Erlangen
(2) Schepens Eye Research Institute, Harvard Medical School, Boston
(3) Dept. of Pathology, Beth Israel Deaconess Hospital, Harvard Medical School, Boston

Purpose Thrombospondin (TSP)-1 and -2 are important antiangiogenic factors thought to be involved in maintaining corneal avascularity (angiogenic privilege). This study was undertaken to investigate whether deficiencies of these factors altered developmental and inflammation-induced angiogenesis in the cornea of mice.

Methods Expression of TSP-1 and -2 mRNA and protein was assayed in cornea by RT-PCR and Western blot. Corneas of TSP-1(-/-), TSP-2(-/-), and TSP-1,2(-/-) mice aged 2, 3, and 6 months, and wild-type control mice, were analyzed for spontaneous angiogenesis biomicroscopically, histologically, and with CD31 immunohistochemistry. The mouse model of suture-induced, inflammatory corneal neovascularization was used to evaluate the lack of TSP-1,2 and both TSPs on induced-corneal angiogenesis.

Results Corneas from normal mouse eyes constitutively expressed TSP-1 and -2 mRNAs and proteins. Corneas of TSP-1(-/-), -2(-/-), and -1,2(-/-) mice displayed no evidence of spontaneous developmental-postnatal angiogenesis. One week after suturing, corneas of all TSP(-/-) mice had significantly greater corneal angiogenesis than those of control mice ($P < 0.05$). TSP-1(-/-) had a significantly greater effect on induced corneal neovascularization than did TSP-2(-/-), with the opposite being the case in developmental iris angiogenesis ($P < 0.01$).

Conclusion Corneal avascularity during development is redundantly regulated, shown by the fact that lack of the antiangiogenic factors TSP-1 and/or -2 resulted in no spontaneous corneal angiogenesis. By contrast, TSP-1, more than TSP-2, helps to suppress inflammation-induced corneal angiogenesis postnatally, implying that angiogenic privilege in the cornea is actively maintained.

EVER-2004-abstractbook.indd 204 8/19/04 12:27:23 PM

■ 3342

Ocular morphology and visual function in children born preterm and in children born small for gestational age

HELLSTROM A
Dept of Ophthalmology, Institute of Clinical Neuroscience, The Sahlgrenska Academy at Göteborg University, Göteborg

Purpose Preterm birth has been shown to be associated with subnormal optic disc and rim area as well as tortuous retinal vessels in the central fundus. The long-term clinical prognosis of these findings has yet to be determined. Retinopathy of prematurity (ROP) is still a cause of infantile severe visual impairment and blindness. It has recently been shown that persistent low serum concentrations of insulin like growth factor 1 (IGF-I) after premature birth have been associated with development of ROP and other complications of prematurity. IGF-I is at least as strong a determinant of risk for ROP as postmenstrual age at birth and birth weight. Preterm children have a higher incidence of subnormal visual acuity, refractive errors and strabismus than children born at term. In addition, a majority of preterm children with subnormal visual acuity and/or strabismus have visual perceptual-cognitive problems.Intrauterine growth retardation (IUGR) has been shown to be associated with a lower number of vascular branching points and decreased neuroretinal rim area. The reduced number of branching points and decrease in neuroretinal rim area were associated with increasing negative birth-weight deviation. A decrease in neuroretinal rim area reflects either a reduction in axonal growth or a decrease in the number of axons in the optic nerve. It is yet unclear if this finding represents neuronal changes within other cerebral regions in subjects with IUGR.

Conclusion Preterm birth and /or low birth weight exposes the immature visual system to neonatal strain with effects on morphology and visual function. Timing of brain lesion, gestational age and size at birth as well as perinatal morbidity may influence the fundus appearance and the pattern of visual dysfunction.

■ 3343

Optic disc appearance and visual function in preterm children with periventricular white matter damage

JACOBSON L
Dept of neuro-pediatrics, Karolinska University Hospital, Stockholm

Purpose Background: End-stage periventricular white matter damage affecting the optic radiation has become the principal cause of visual impairment and dysfunction in children born prematurely.Children with periventricular white matter damage may present to the ophthalmologist within a clinical spectrum from severe cerebral visual impairment in combination with cerebral palsy and mental retardation to early-onset esotropia only.

Methods Fundus photographs were analised as were MRI of the brain. Visual function, eye motility and intellectual level were tested.

Results Optic disc abnormalities such as small discs or large cupping of normal-sizes discs are most likely a result of transsynaptic degeneration of optic nerve axons caused by the primary bilateral lesion in the optic radiation.Periventricular white matter damage may result in low visual system neural capacity expressed as low visual acuity and/or inferior visual field restriction. The visual dysfunction is complicated by difficulties processing visual information resulting in problems with simultaneous perception, depth perception, recognition of familiar faces and orientation. Abnormal eye motility often aggravates the visual problems.

Conclusion Periventricular white matter damage in prematurely born children causes visual dysfunction and eye motility problems. Optic disc appearance may give information about at what time the posterior visual pathways were injured.

■ 3344

Computerized perimetry in children

MARTIN L
Clinical Neuro Science, Stockholm

Purpose To describe the results from different methods for measuring visual fields in children

Methods In order to evaluate the feasibility of different perimetry techniques in examining children, Goldmann perimetry, High-pass resolution perimetry, Frequency doubling technology and Rarebit perimetry were used in selceted cohorts of children and young adults.

Results The different techniques will be discussed and results from studies regarding prematurity, paediatric glaucoma, periventricular white matter damage, and very low birth weight will be presented.

Conclusion Children can very well perform all types of computerized perimetry from about 7 years of age. The Rarebit perimetry was preferred among the children and gave most information about their visual function.

■ 3345

Visual impairment in children with motor handicaps

HYVARINEN L (1, 2)
(1) University of Helsinki, Helsinki
(2) Dortmund University, Dortmund

Purpose Visual pathway damages caused by asphyxia or abnormal development of brain are the most common causes of visual impairment in children with motor handicaps. In some children there is also damage to the anterior part of the visual system, retinopathy of prematurity or lesions in the eyes and optic nerves caused by traffic accidents or nonaccidental damage.Assessment of visual impairments needs to cover both the anterior lesions and the posterior lesions, i.e. the structure of the incoming information, changes in the cognitive vision and oculomotor functions and, especially in children with severe multi-impairment, also the possibility of changes in the inhibitory functions.Communication is affected by loss of face recognition, difficulties in perception of facial expressions or body language, loss of accommodation, especially in infants, and poor or eccentric fixation that lead to deviations from normal visual communication. Perception of forms, colours, figure-ground, depth, orientation and length of lines can be lost singly or as a part of a larger damage. Functions of the parietal lobe, like spatial orientation and eye-hand coordination are sometimes difficult to assess because of the motor problems. Therefore the transdisciplinary assessment is recommended.

EVER-2004-abstractbook.indd 205 8/19/04 12:27:24 PM

3351

Mouse models for retinal dysfunction

DALKE C (1), FAVOR J (2), PRETSCH W (2), SOEWARTO D (3), FUCHS H. (3), HRABÉ DE ANGELIS M (3), GRAW J (1)
(1) GSF-National Research Center for Environment and Health, Institute of Developmental Genetics, Neuherberg
(2) GSF-National Research Center for Environment and Health, Institute of Human Genetics, Neuherberg
(3) GSF-National Research Center for Environment and Health, Institute of Experimental Genetics, Neuherberg

Purpose Mouse models are an important tool to investigate functional disorders and gene mutations of retinal degeneration.

Methods To screen mice for retinal degeneration a high throughput electroretinography (ERG) method was employed. Histological examinations of the eyes were performed according to standard procedures. To locate the disease gene a genome-wide mapping was started in one line.

Results The mouse mutant Aey20 showing retinal degeneration was found among the CD-1 breeding colony, and a corresponding line could be established. It is characterised by a variable ERG and a stronger phenotype in older animals, suggesting a quantitative trait locus. In histological sections thinner INL and ONL than in wild types were found. First mapping results of the Aey20 were obtained. Because of the outbred background of the CD-1 strain the location of Aey20 was preliminary assigned to chromosomes 6, 7 and 19. Further detailed mapping of this line at a higher degree of inbreeding confirmed linkage to chromosome 7; however, chromosome 19 was excluded.In a dominant screen more than 1000 offspring of ENU-treated C57BL/6J males were screened for retinal degeneration, but no mutation could be confirmed. In view of this result and the mainly recessive mode of inheritance in human retinal degenerations we changed to a recessive screen, where up to now 235 offspring of the backcross generation were screened. Among these offspring 6 putative mutants were detected. Confirmation crosses are in progress.

Conclusion The mutation of a new mouse line with retinal degeneration was mapped to chromosome 7. Six putative mutants obtained from a recessive ENU screen are further analysed.Supported by the German National Genome Research Network (01GR0103)

3352

Association between sunlight exposure and pterygium prevalence in indigenous populations of the Brazilian Amazonian rain forest

PAULA JS (1), THORN F (2), CRUZ AAV (1)
(1) School of Medicine of Ribeirão Preto, USP, Ribeirão Preto, São Paulo
(2) New England College of Optometry, Boston, MA

Purpose To compare the prevalence of pterygium and cataract in three indigenous populations of the Brazilian Amazonian rain forest with different degrees of sunlight exposure (Arawak, Tukano and Yanomami).

Methods A pterygium and cataract survey was performed by slit-lamp biomicroscopy on 581 adults subjects belonging to 3 ethnic groups of Indians with high (Arawak and Tukano) and low (Yanomami) rates of sun exposure. All subjects were classified as 1 or 0 according to the presence or not of pterygia and cataracts. Sex and age were also recorded.

Results Chi-square tests revealed that the prevalence of pterygium and cataract did not differ between Arawaks and Tukanos (pterygia: 36,2% and 37,1%, and cataracts: 26,9% and 20,1%, respectively). Yanomami Indians showed lower prevalence of pterygia (5,4%) than Arawaks (p<0,0001) and Tukanos (p<0,0001). The prevalence of cataract for the Yanomami (13,9%) was significantly lower than for the Arawaks (p<0,0001), but not for the Tukanos (p=0,053). Gender was associated with pterygium (higher in females, p=0,026) but not with cataract. As expected, elderly subjects showed a significant higher prevalence of cataract (p <0.0001). The prevalence of pterygia did not increase in the elderly group.

Conclusion River people (Arawak and Tukano) who have high rates of sunlight exposure have higher prevalence of pterygia than forest dwelling people (Yanomami). This fact emphasizes that exposure to sunlight is a major determinant agent for pterygium but not for cataract.

3353

Vision impairment and its causes in Northern India

JOHN N (1, 2), MURTHY GVS (3), GUPTA SJ (2), PRICE GM (1), CHAKRAVARTHY U (4), MARAINI G (5), CAMPARINI M (5), FLETCHER AE (1)
(1) Epidemiology & Population Health, London School of Hygiene & Tropical Medicine, London
(2) Dr RP Centre for Ophthalmic Sciences, All India Institute of Medical Sciences, New Delhi
(3) Dr RP Centre for Ophthalmic Sciences, All India Institute of Medical Sciences, New Delhi
(4) Vision Sciences & Ophthalmology, Queen's University, Belfast
(5) Department of Ophthalmology,University of Parma, Parma

Purpose To obtain estimates of the prevalence and causes of vision impairment in the north Indian setting.

Methods 1443 people (median age 60 years), 52% women, were identified from enumeration of the 50+ age group age in 11 randomly sampled villages from a peri-urban district of Haryana, North India. 87 % attended an eye examination which included visual acuity using ETDRS charts and lens and fundus image capture. Lens images were graded using LOCS II and fundus images by the Rotterdam Grading system.

Results 37% were visually impaired (VA < 6/18 in best eye) and similar in men (33.7%) and women (39.8%). Visual impairment rose steeply with age, 16.1% at ages 50-59, 39.6% ages 60-69 and 68.9% at 70+. 9.3% were bilaterally blind (VA<3/60); 24.5% in those aged 70+. Correction for refractive error reduced vision impairment by around a half. Late stage AMD was present in 1.4 % overall and in 4.6% of these aged 70+ and significant lens opacities (LOCS Grade 2 or more for nuclear or cortical and > 1 for posterior subcapsular in worst eye) in 74.9%. Nearly 20% of those with significant opacities and 53% of those with AMD were visually impaired due to these conditions

Conclusion Refractive error and cataracts are a major cause of vision impairment in the older Indian population.

3354

Disposable camera viewfinders as visual field expanders for tunnel vision

VARGAS-MARTÍN F
Departamento de Física (área Óptica), Universidad de Murcia, Murcia

Purpose To study the use of a free-cost viewfinder as a visual aid for tunnel vision.

Methods Viewfinders extracted by making very minor modifications to cheap disposable photographic cameras has been evaluated objectively with a high resolution webcam, and compared to a commercially available reversed telescope (magnification ×0.5). Perimetry measurements in tunnel vision subjects using these viewfinders have been performed.

Results Magnification of about ×0.5 is easily achieved with these viewfinders with effective fields up to 20 deg.Expansion of the visual field in subjects is demonstrated by perimetry.

Conclusion Since creating low cost devices is one of the major goals in low vision aid design (especially in underdeveloped countries), the proposed viewfinders could be a cheaper (virtually for free) and more practical solution for preliminary adaptations to patients.

EVER-2004-abstractbook.indd 206 8/19/04 12:27:24 PM

■ 3355 / 314

Degradation of GLUT1 by the ubiquitin proteasome pathway (UPP) on retinal endothelial cells

FERNANDES R (1), CARVALHO AL (2), MURTA J (3), FERNANDES A (3), FARO C (2), PEREIRA P (3)
(1) Center of Opthalmology, Coimbra
(2) Center for Neurosciences, Coimbra
(3) Center of Ophthalmology, Coimbra

Purpose GLUT1 is the main transporter responsible for the glucose uptake in retinal endothelial cells. The purpose of this study is to determine if the UPP participates in regulation of levels of GLUT1 in response to oxidative stress.

Methods Retinal endothelial cells were exposed to 40 or 100 µM of hydrogen peroxide. Endogenous ubiquitin conjugates and GLUT1 were detected by Western Blotting and immunofluorescence confocal microscopy. The levels of GLUT1 in cell membranes were determined following biotinylation of membrane proteins. The involvement of the UPP on constitutive GLUT1 degradation was further assessed by transfection of HEK cells with pCAGGS-GLUT1.

Results Proteasome inhibition leads to an accumulation of total GLUT1 content and to a specific stabilization in membrane of endothelial cells. The same was observed for HEK 293 T cells transfected. These results suggest the involvement of the UPP on constitutive GLUT1 degradation. Moreover, oxidative stress further enhances degradation of GLUT1. Inhibition of proteasome following oxidative stress results in a dramatic increase in the amount of GLUT1. Significantly, recovery from oxidative stress leads to increased degradation of GLUT1 by a proteasome dependent mechanism.

Conclusion The data suggests that the oxidative stress is a potencial mechanism that may induce increased degradation of GLUT1 by the UPP presumably contributing to alter glucose homeostasis in diabetes.

■ 3356 / 315

Detection of basic fibroblast growth factor after scleral implantation of orbital adipose tissue in a pig's eye

PINNA A (1), CARTA A (2), MANUNTA L (3), CAREDDU GM (3), MADEDDU P (4, 5), CARTA F (1)
(1) Institute of Ophthalmology, University of Sassari, Sassari, Italy
(2) Institute of Ophthalmology, University of Parma, Parma, Italy
(3) Institute of Veterinary Surgery, University of Sassari, Sassari, Italy
(4) Institute of Internal Medicine, University of Sassari, Sassari, Italy
(5) National Laboratory of the National Institute of Biostructures and Biosystems, Osilo, Italy

Purpose Evidence indicates that the basic fibroblast growth factor (bFGF) has a protective effect on the retina. Previous studies have shown that adipocytes can produce bFGF. The present experiment was undertaken to investigate the effect of the scleral implantation of orbital adipose tissue on bFGF production in the eye of a pig.

Methods A 2-month-old pig underwent the surgical procedure performed in Cuba for the treatment of retinitis pigmentosa under general anesthesia. A conjunctival incision was made in the right eye and a pedicle flap of retrobulbar fat with blood vessels was implanted in a scleral pocket in the posterior part of the globe. The left eye served as the control. The animal was suppressed 8 months after surgery and the eyes were enucleated. A specific ELISA was used to detect bFGF levels in the choroid and in the retina along with the proximal portion (3 mm) of the optic nerve.

Results ELISA showed that bFGF levels were as follows: 4122 pg/ml (right choroid), 40,297 pg/ml (right retina + optic nerve), 5362 pg/ml (left choroid), 19,631 pg/ml (left retina + optic nerve).

Conclusion Results suggest the surgical procedure used in Cuba might increase bFGF levels in the nerve tissue of the eye. Further "in vitro" and "in vivo" studies are necessary to confirm these preliminary data.

■ 3357 / 317

Cumulative incidence of visual impairment and competing risks in childhood-onset type 1 diabetes

VIRTAMO T (1), KIVELÄ T (1), YKI-JÄRVINEN H (2), STENMAN UH (3), HARJUTSALO V (4), TUOMILEHTO J (4), LAATIKAINEN L (1), SUMMANEN P (1)
(1) Ophthalmology, University Hospital, Helsinki
(2) Medicine, University Hospital, Helsinki
(3) Chemistry, University Hospital, Helsinki
(4) Epidemiology and Health Promotion, National Public Health Institute, Helsinki

Purpose To study the cumulative incidence of visual impairment in relation to lifetime glycaemic control, systolic (SBP) and diastolic blood pressure (DBP) in childhood-onset diabetic patients in Finland.

Methods 5166 Finnish patients under the age of 18 were diagnosed with Type 1 diabetes between 1965-1979. In a population-based sample of 1032 patients clinical data on retinal examinations, visual acuity (VA) and medical risk factors were analysed since the onset of diabetes. Mean annual HbA1c, SBP and DBP were calculated. The vitality data were obtained from Statistic Finland. Cumulative incidence of permanent loss of VA 0.5, 0.3 and 0.05 in the better eye is reported using death without visual loss as a competing risk. Cox regression analysis of loss of VA 0.5 with HbA1c, SBP and DBP as a time-varying covariates is reported.

Results Cumulative incidence of loosing VA 0.5, 0.3 and 0.05 by 20 of diabetes was 4.1%, 2.7% and 1.6% and by 30 years 6.6%, 5.4% and 2.0%, respectively. Cumulative incidence of death without loosing VA 0.5, 0.3 and 0.05 by 30 years was 9.6%, 10.3% and 11.2%, respectively. Loosing VA 0.5 in the better eye was significantly related to HbA1c (HR 1.42 for every 2% unit increase p = 0.000), SBP (HR 1.47 for every 10 mmHg increase; p = 0.000), and DBP (HR 1.49 for every 5 mmHg increase; p = 0.000), not to gender, age and year at the onset of diabetes.

Conclusion Hyperglycaemia and hypertension were significantly related to visual loss. Cumulative incidence of dying was 5 times higher than blindness by 30 years of diabetes.

EVER-2004-abstractbook.indd 207 8/19/04 12:27:25 PM

3361
Restoring accommodation in pseudophakic eyes

TASSIGNON MJ
Ophthalmology, Antwerp

Purpose Under "restoring" one could ironously understand that accommodation is fully understood. This is currently not the case. Furthermore, the capsular bag and more precisely its healing process after cataract surgery, is still not fully understood making it difficult for the surgeon to predict the final position of the intraocular lens (IOL) in the anterior chamber of the operated eye.

Methods An overview of all parameters influencing accommodation will help to better understand the importance of the complexity of the accommodation function. Specifically for the pseudophakic eye, the healing process of the capsular bag plays a crucial role in the final position of the IOL within the eye. Within that healing process, the LECs play the most important role and are the cells that should be controlled.

Results Intraocular lenses (IOLs) that have their accommodation effect based on the so-called anterior movement of the vitreous gel will loose all benefit in case the position of the intraocular lens is not well aligned according to the visual axis.

Conclusion The final place of the intraocular lens in the eye is crucial. For this purpose we developed a new way of fixation called the bag-in-the-lens implantation. This lens has the advantage that it will not rotate and not defocus. It is therefore possible to develop a customized IOL depending on the corneal aberrations: "corneal optical coupling IOL."

3362
Hydrogels as potential lens replacement material

RAVI N
Departments of Ophthalmology & Chemical Engineering, St. Louis, Missouri

Purpose To develop an injectable accommodating intra-ocular lens for the preservation of accommodation after cataract surgery

Methods As proof of concept, acrylamide derivaties were copolymerized with disulphide containg crosslinkers. The hydrogel was extensively washed with water to remove unreacted monomers and other excipients. The swollen copolymer was liquified to yeild copolyacrylamide containing thiol functional groups. Various concentrations of these copolymers were introduced into pre-evacuated porcine lens capsular bags. The hydrogel formed spontaneously in the presence of oxygen at physiological pH. The mechanical properties were determined using a dynamic mechanical analyzer, and a custom-designed multi arm radial stretcher. Biocompatibility tests were performed on porcine lens epithelial cells in tissue culture medium.

Results The aqueous copolyacrylamide solujtion gelled spontaneously under physiological conditions to form a clear and stable hydrogel. The modulus of the gels ranged from 0.47 -1.1 KPascals, the refractive index varied from 1.35-1.42, and the relaxation time constant from 50-100 milliseconds. The copolymers showed minimum contact toxicity in the thiol form but no toxicity was observed in the disulfide form.

Conclusion We have successfuly developed a hydrophillic phaco-ersatz material that appears to have the right range of optical, mechanical and biocompatible properties. Animal studies are being planned.

3363
Model of IOL with changeable optical power

SERGIENKO N

Purpose A biometry measuring enables objective assessment of IOL forward movement as a result of the pilocarpine-induced contraction. This fact serves an indirect evidence of the vitreous pressure over the posterior lens capsule during accommodative function.Purpose. To develop an IOL model stimulating by vitreous pressure for increasing an optical power of the implant.

Methods A model of the accommodative IOL (A-IOL) is designed with following characteristics: length-10.5 mm, width- 6.5 mm, optical part diameter- 4.75 mm.A developed model of eyeball imitates a capsular bag after performing the circular capsulorhexis. The model is hermitic and allows to control pressure on capsular bag from behind. After placing the A-IOL model in-the-bag of the eyeball it is possibility to observe increasing of the optical power of the implant.

Results Design of the A-IOL allows securing quality of the optical system and degree of the altering of optical power. Demonstration of work of the A-IOL model is presented on video.

Conclusion A possibility of increasing of optical power of IOL following vitreous pressure over the posterior lens capsule is proved. The next step may be developing the IOL model for clinical trial.

3364
Optical and Mechanical Design for Human Implantation of the Sarfarazi Elliptical Accommodating Intraocular Lens (EAIOL)

SARFARAZI FM
Harvard Medical School, Carlsbad, CA

Purpose The purpose was to improve the design of the three dimensional accommodating IOL designs used for implantation in a human eye.

Methods The Sarfarazi EAIOL is an accommodating IOL composed of two optics and three haptics. The anterior optic is a biconvex plus lens, and the posterior optic is a concave convex minus lens. It is designed to achieve a true accommodation through the natural contraction and relaxation of the capsule by the ciliary muscle. This one-piece foldable lens was molded from a silicone material and implanted in a monkey eye. The mold has been re-designed, optically and mechanically re-calculated and adjusted for the human eye.

Results This newly design EAIOL will be implanted in the human eye through a small incision and the result will be reported. As previously demonstrated, the Sarfarazi EAIOL was implanted in the three monkey eyes. The lens was easily inserted in the eye with a lens folder using relatively small incision surgery. The UBM images confirmed that the Sarfarazi EAIOL fit the entire capsule. Long-term follow-up shows that the EAIOL is very stable and is providing accommodation. No decentration or misalignment has been observed. Implantation in the live monkeys indicated that the lens achieved 7-8 diapers of accommodation in repeated tests utilizing various testing techniques. Surgical technique and slit lamp examinations after implantation were very similar to those of traditional IOLs.

Conclusion Initial tests indicate that the Sarfarazi twin-optic Elliptical Accommodating IOL can emulate the performance of the natural lens and can achieve a significant degree of accommodation. Implantation in the monkeys has demonstrated that the lens is safe enough to be implanted in the human eye.

EVER-2004-abstractbook.indd 208 8/19/04 12:27:25 PM

■ 3365

What is there to be learned about accommodation and presbyopia from in vitro mechanical stretching studies?

GLASSER A
College of Optometry, University of Houston, Houston, TX

Purpose Due to the relative inaccessibility of the accommodative structures of the eye there are still many unanswered questions about accommodation and presbyopia. In vitro studies using mechanical stretching of the lens with radially directed forces have provided important insights. The history of these studies since their inception from Fisher's (1977) pioneering study to testing of new accommodative intraocular lenses and the insights and limitations of this approach, will be detailed.

Methods Fisher (1977), Pierscionek (1993; 1995), Glasser & Campbell (1998) and Glasser (1999); Roorda & Glasser (2004) have used mechanical stretching devices to study the accommodative changes in the natural crystalline lens. These studies and the results obtained have provided the groundwork for new studies in this area such as those by Koopmans, et al (2003), testing of new accommodative IOLs, and towards the development of a new generation of these devices such as those by Parel, Ravi and Barraquer and colleagues.

Results Mechanical stretching studies support the capsular basis of accommodation, have allowed estimations of the force of contraction of the ciliary muscle, have led to observations that aged human lenses fail to undergo accommodative changes, provided descriptions of the accommodative optical changes that the lens undergoes and provided insight into the lenticular basis of presbyopia. These devices also allow a cost effective method for testing the performance of new accommodative intraocular lenses.

Conclusion While mechanical stretching does not duplicate the accommodative mechanism of the living eye, and suffers from inherent limitations, the results from this line of experimental work has validated mechanical stretching as a reliable and useful approach to investigate some aspects of accommodation, presbyopia and accommodative IOLs.

EVER-2004-abstractbook.indd 209 8/19/04 12:27:26 PM

■ 3411

Detection of Glaucomatous eyes using Automated perimetry, Scanning laser ophthalmoscopy of the optic disk or scanning laser polarimetry of the RNFL

MILANO G (1, 2), MACERI C (1, 2), TISO C (1, 2), SCATASSI I (1, 2), ROSSI GCM (1)
(1) University Eye Clinic, Pavia
(2) IRCCS Policlinico San Matteo, Pavia

Purpose To evaluate the clinical ability of visual field testing, of scanning laser polarimetry (GDx-VCC) and scanning laser ophthalmoscope (HRT-II) to differentiate between normal and glaucomatous eyes.

Methods Among those referring to the Glaucoma service of the University Eye Clinic of Pavia, Italy, 157 eyes were selected on the basis of a complete ophthalmic examination. They were submitted to an automated visual field testing (VF) using 24-2 pattern and SITA-Standard strategy. The diagnostic criteria for the assessment of glucomatous visual field loss proposed by the European Glaucoma Society were applied. All subjects were then classified as normal, glaucomatous or glaucomatous suspect on the basis of the VF outcomes and IOP values. They were also submitted to scanning laser polarimetry (GDx-VCC) and scanning laser ophthalmoscope (HRT). The VF global indices MD, PSD and the parameters TSNIT average, TSNIT standard deviation, NFI for GDx and Cup Shape Measure, Cup/Disk Ratio, Cup Area, Rim Area for HRT-II were considered.

Results The correlation between VF indices and clinical diagnosis seems to be efficient as expected. The morphometric parameters seem to discriminate between normal and glaucomatous eyes but they seem to be less efficient in differentiate glaucoma suspect from normal eyes. A correlation was also found between NFI and VF global indices.

Conclusion The morphometric analysis of the RNFL and of the optic disk differentiate between normal and glaucomatous eyes. The ability of these methods to differentiate between normals and glaucoma suspects is less efficient. The best correlation between functional and morphologic outcomes comes from the use of GDx.

■ 3412

Optic disc edema leads to non-reliable OCT retinal nerve fiber layer thickness measurements

MENKE MN (1, 2), FEKE GT (1), TREMPE CL (1)
(1) Schepens Retina Associates Foundation, Boston, MA
(2) Dept. of Surgery, Beth Israel Deaconess Medical Center, Harvard Medical School, Boston, MA

Purpose OCT is known to provide reliable retinal nerve fiber layer (RNFL) thickness measurements in healthy subjects and glaucoma patients. However, diseases such as optic neuritis and central or branch retinal vein occlusion can be associated with disc edema (DE). Due to the proximity of the OCT scan to the disc, tissue swelling might influence the correct RNFL thickness measurement. This study was designed to test this hypothesis.

Methods Thirteen patients with previously diagnosed DE and 13 healthy age matched subjects were included in the study. Standard 3.46 mm diameter OCT-RNFL circle scans were performed centered on the disc. The scans were analyzed using the newly established normative database for RNFL thickness (Stratus OCT 3000, Software version 3.0).

Results OCT measured significantly greater RNFL thickness in the DE group compared to the control group ($p<0.001$). The superior, inferior, temporal and nasal quadrant RNFL thickness values were separately compared with those in the control group. In each quadrant the DE group showed significantly greater RNFL thickness values ($p<0.001$ to $p<0.03$). In the DE group, RNFL thickness exceeded the normative database values in 22 of the 52 quadrants tested. The superior quadrant was the most frequent area of "supernormal" RNFL thickness.

Conclusion Our study indicates that OCT RNFL thickness measurements in patients with DE are not reliable, yielding an overestimation when using the standard 3.46 mm circle scan centered on the optic disc. The superior quadrant was most affected by DE in our patient group.

■ 3413

Early morphological changes in an ocular hypertensive monkey model of claucoma as evidenced with ultrahigh-resolution Optical Coherence Tomography, Scanning Laser Polarimetry and Scanning Laser Tomography

DOELEMEYER A (1), POLSKA E (2), SCHMETTERER L (3, 4), DREXLER W (3, 4), LAMBROU GN (1)
(1) Novartis Institutes for Biomedical Research, Neuroscience and Ophthalmology, Basel
(2) Department of Clinical Pharmacology, Medical University, Vienna
(3) Dept. of Clinical Pharmacology, Medical University, Vienna
(4) Dept. of Medical Physics, Medical University, Vienna

Purpose To assess and compare early morphological changes measured using ultra-high-resolution optical coherence tomography (uhrOCT), scanning laser polarimetry (SLP) and scanning laser tomography (SLT) in ocular hypertensive (OHT) eyes of cynomolgous monkeys.

Methods OHT was induced unilaterally in 6 monkeys by photocoagulation of the trabeculum. 3 baseline experiments were performed. After surgery, study days were scheduled every 2-3 weeks over 3-6 months. Cross-sectional images of the macula and optic nerve head (ONH) and circular scans along the peripapillary area were obtained with uhrOCT. Thickness of the nerve fiber layer (NFL) and intraretinal layers were calculated. NFL thickness maps were acquired with a GDX VCC system (Laser Diagnostic Technology). Confocal SLT (Heidelberg Engineering) was used to acquire focal image sequences of the ONH.

Results Baseline experiments showed a good reproducibility for all systems. After induction, IOP developed differently in different monkeys. Two animals displayed a stable increase in IOP of 20-35 mmHg. These monkeys showed marked changes in ONH topography already at day 20 post surgery. The GDx detected a reduction of NFL thickness also at day 20 and progressing subsequently. Three animals showed only sporadic and/or a mild increase in IOP of 10-15 mmHg. Morphological changes could also be evidenced with the employed techniques in these animals, but to a lesser extend.

Conclusion Changes in retinal morphology occur rapidly after induction of ocular hypertension in the monkey model of glaucoma and can be detected at early stages consistently with all 3 techniques.

■ 3414

Relationship between OCT nerve fiber layer thickness and visual field sensitivity level in corresponding areas

LINGARO N, TARDINI MG, GANDOLFI S
Ophthalmology, Parma

Purpose Determine the relationship between retinal nerve fiber layer thickness in specific sectors, as measured with OCT3, and visual field sensitivity level in corresponding areas.

Methods 31 eyes of 31 patients with glaucomatous optic neuropathy were included in the study. All subjects had BCVA of 20/32 or better, refractive error between ±5 D sph and ±1.5 D cyl, IOP <20 mmHg, full threshold 24/2 Humphrey perimetry, and OCT3 RNFL thickness measurements, both acquired within 6 months. To prevent bias due to diffuse RNFL loss, VF with a MD worse than –12 dB were excludedVF sensitivity levels were recorded as decibels and as 1/Lambart. Three OCT 360° RNFL scans were taken by the same technician, results were exported into Excel and averaged; this 512 values were than divided into 6 zones of the optic nerve head, based on Garway-Heath work, in order to exactly match thickness of a determinated RNFL sector with the corresponding sector of the ONH. The VF sensitivity was as well divided into 6 zones, topographically related to the optic disc.

Results Correlation was significant for sectors 1, 2, 5 and 6 (R= 0.486, 0.524, 0.565 and 0.652 respectively); for all this sectors correlation values were the same with dB and 1/Lambart. On a graph, with VF in dB, points arranged into an hyperbolic curve; with 1/Lambart, points arranged in a much more linear way.

Conclusion In this subgroup of patients with glaucomatous optic neuropathy and well defined VF deficits, RNFL thickness, as measured with OCT, showed a good relationship with VF sensitivity in four out of six sectors. Correlation was better for superior sectors of the VF; the relation had a curvilinear shape when expressed in dB and a linear when expressed in 1/Lambart.

EVER-2004-abstractbook.indd 210 8/19/04 12:27:26 PM

■ 3415

Relationship of Intraocular Pressure and Perfusion Pressure on Progression of Glaucoma

WIEDERHOLT M (1), ERB C (2)
(1) Inst Klin Physiolgie, Charite,Universitätsmedizin, Berlin
(2) Ophthalmology, Medizinische Hochschule, Hannover

Purpose To evaluate the probability of progression in patients with primary open angle glaucoma (POAG), and to perform a quality monitoring of risk factors accociatetd with progression.

Methods 5,519 eyes were studied. 336 ophthalmologists participated ind the study. A computerized documentation was performed, and the data were transmitted for central data analysis. The following data were recorded: stages of optic disc and visual field, cup to disc ratio, IOP, IOP differences (24 hours), vascular risk factors, progression of glaucoma and blood pressure.

Results The analysis of the data after one year revealed the following: Mean IOP was lowered from 19.9 to 17.2 mmHg with administration of antiglaucoma drugs. In 23% of the patients the differences in IOP were greater than 4 mmHg. The stage of the optic disc correlated with the cup to disc ratio, stage of visual filed, and IOP. In at least 48% of all glaucoma patients a systemic hypertension could be detected, in 17% of patients the nocturnal dip of blood pressure was greater than 10%. Ocular perfusion pressure was calculated. The analysis of these data showed a V-shaped dependence of the progression of the stage of the optic disc and visual field as well as cup to disc ratio on ocular perfusion pressure. This means that the considerable increase of perfusion pressure can just as well lead to a progression of glaucoma alike the decrease of perfusion pressure.

Conclusion In order to reach the optimum range of perfusion pressure for glaucoma patients, IOP and possibly blood pressure have to be normalized. Already the continuous observation of standardized recorded data over one year shows that the presented concept for quality assurance of therapy can be an essential contribution.

■ 3416

Dynamic contour tonometry (DCT): A comparison with Goldman applanatory tonometry with respect to central corneal thickness

KAMPPETER BA, DEGENRING RF, JONAS JB
Department of Ophthalmology, Faculty for Clinical Medicine Mannheim, Ruprecht-Karls-University, Heidelberg

Purpose Dynamic contour tonometry (DCT) offers the possibility of direct intraocular pressure measurement independently of corneal thickness. It was the purpose of this study to compare results to Goldman tonometry with respect to central corneal thickness.

Methods 99 eyes from 74 patients were examined using a standard Goldman applanatory tonometer and dynamic contour tonometer "Pascal" (Ziemer Ophthalmics, Switzerland). In addition, corneal thickness was determined by ultrasound pachymetry.

Results Central corneal thickness was in the mean 560,31±70,1µm (Range: 436-894µm). DCT yielded significantly higher results (18.15±5.4 to 16.94±6.03mmHg, $p<0.01$). Coefficient of correlation was 0.91 ($p<0.01$). Goldman tonometry showed a significant correlation with central corneal thickness (Pearson´s coefficient of correlation: 0,215, $p<0,05$). No correlation was found by dynamic contour tonometry and central corneal thickness (Pearson´s coefficient of correlation: 0,175; $p=0,108$).

Conclusion DCT and Goldman applanatory tonometers were highly and significantly correlated. Only Goldman applanatory measurements were significantly correlated with central corneal thickness. Dynamic contour tonometry may provide a new method of intraocular pressure measurement, which is less dependent on corneal thickness.

■ 3417 / 360

Comparison of anterior and posterior corneal curvatures (Orbscan II) in normal and glaucoma patients

HERNANDEZ VJL (1, 2), TEUS MA (1, 3), MARINA C (1), GIL R (4, 2), SáNCHEZ JM (1)
(1) VISSUM Hospital Oftalmológico, Madrid
(2) Universidad Complutense, Madrid
(3) Universidad de Alcalá, Madrid
(4) VISSUM Hospital Oftalmólogico, Madrid

Purpose To evaluate differences in corneal anterior and posterior curvatures between patients with and without glaucoma.

Methods This is a masked prospective study done in a group of glaucoma patients and healthy people (used as control group). Ultrasound central pachimetry (three measurements), refractive error, gonioscopy, Goldman tonometry (prior to hypotensive treatment) in the glaucoma group (three measurements), and elevation topography Orbscan II (three measurements) were done in all patients. Subjects with corneal disease, previous ocular surgery and patients under treatment with inhibitor of carbonic anhidrase were excluded. The statistical analysis was done with the two tail paired t – Student test.

Results We compared 69 glaucomatous eyes with 69 normal healthy eyes, matched pachimetry. The mean age was 51.15 + 16.67 (range 22 to 78 years) and the astigmatism was lower than -3.00 D. The mean keratometric values were 43.77+ 1.68 D. We found significant higher difference in posterior surface elevation ($p=0.001$) and a significant difference between the highest and lowest elevation points in the anterior surface ($p=0.005$) in the glaucomatous group when compared to the control group.

Conclusion Our results suggest that elevation of the posterior surface, parameter that is traditionally related to ectasia, is higher in glaucomatous patients than in normal healthy subjects when they are pachimetry and corneal astigmatism matched.

■ 3418 / 361

Central corneal thickness correlated with glaucoma damage and rate of progression

JONAS JB, STROUX A, VELTEN I, JUENEMANN A, MARTUS P, BUDDE WM
Department of Ophthalmology, Faculty for Clinical Medicine Mannheim, Ruprecht-Karls-University, Heidelberg

Purpose To evaluate whether the amount of glaucomatous optic nerve damage at presentation of the patient and the rate of progression of glaucoma during follow-up are related to central corneal thickness.

Methods The prospective observational clinical study included 861 eyes of 454 Caucasian subjects (239 normal eyes of 121 subjects, 250 ocular hypertensive eyes of 118 patients, 372 eyes of 215 patients withchronic open-angle glaucoma). For 567 eyes (304 patients) with ocular hypertension or chronic open-angle glaucoma, follow-up examinations were performed with a mean follow-up time of 62.7 ± 33.2 months (median 60.8 months; range 6.2 to 124.9 months). All patients underwent qualitative andmorphometric evaluation of color stereo optic disc photographs and white-on-white visual field examination. Central corneal thickness was measured by corneal pachymetry.

Results Central corneal thickness was significantly ($p<0.001$) and positively correlated with the area of the neuroretinal rim and negatively correlated with the loss of visual field. Development or progression ofglaucomatous visual field defects detected in 119 (21.0%) eyes was statistically independent of central corneal thickness, in a univariate ($p=0.99$) as well as in a multivariate Cox regression analysis ($p=0.19$).

Conclusion At the time of patient referral, the amount of glaucomatous optic nerve damage was significantly correlated with a thin central cornea. Progression of glaucomatous optic nerve neuropathy was independent of central corneal thickness suggesting that central corneal thickness may not play a major role in the pathogenesis of progressive glaucomatous optic nerve damage.

EVER-2004-abstractbook.indd 211 8/19/04 12:27:27 PM

■ 3419 / 362

Chronic ocular hypertension alters retrograde axoplasmic transport in adult rats

MAYOR - TORROGLOSA S (1), VILLEGAS-PÉREZ MP (1), SALAZAR JJ (2), RAMÍREZ JM (2), TRIVIÑO A (2), RAMÍREZ AI (2), COLL L (1), VIDAL-SANZ M (1)
(1) Departamento de Oftalmología, Universidad de Murcia, Murcia
(2) Instituto de Investigaciones Oculares Ramón Castroviejo, Universidad Complutense de Madrid, Madrid

Purpose To study the effects of chronic ocular hypertension on retrograde axonal transport in adult rat retinal ganglion cells (RGC)

Methods In adult Sprague-Dawley rats, the intraocular pressure of the left eye was chronically elevated by laser photocoagulation (532nm wavelength, 500mW power, 0,25 second duration, 100 µm diameter spot size) of the limbus and most of the episcleral veins following previously described methods (WoldeMussie et al., 2001). Intraocular pressure in both eyes was measured with a Tono-Pen prior to and 1 and 2 weeks after lasering. Retrograde axonal transport was investigated by examining RGCs labeled with fluorogold applied to both superior colliculi 1 week before sacrifice. The nerve fiber layer was examined with neurofilament antibodies (RT97)

Results Laser treatment induced an increase in mean intraocular pressure of approximately 30% over baseline that was maintained throughout the period of study. After three weeks of elevated IOP, there were wedge sectors of the retina lacking RGCs retrogradely labelled with FG. The neurofilament staining in these sectors revealed the presence of RGC axons that showed typical features of axonal degeneration. There was certain variability among different animals in the size of these sectors that often extended to one quadrant of the retina and were more frequent in the superior retina

Conclusion Chronic elevation of the intraocular pressure results 3 weeks later in RGC loss and altered retrograde axonal in pie shaped sectors of the retina Research Support: FIS CO3/13

■ 341a / 363

Chronic ocular hypertension induced degeneration of retinotectal afferents: long term neuroprotection with topical brimonidine

MAYOR - TORROGLOSA S (1), WOLDEMUSSIE E (2), GARCÍA A (1), RUIZ G (2), BERNAL JM (1), WHEELER LA (2), VIDAL-SANZ M (1)
(1) Dpto Oftalmología, Murcia
(2) Allergan Inc., Irvine, California

Purpose To study chronic ocular hypertension (COHT)-induced alterations of retinotectal innervation and the neuroprotective effects of topically applied hipotensive drugs.

Methods COHT was induced in the right eye of adult male Wistar rats by laser photocoagulation of episcleral veins (WoldeMussie et al., 2001). Right eyes were treated twice daily with 5 µl of Alphagan-P, Timoptic or 0,9% NaCl. Intraocular pressure was measured with a Tono-Pen prior to, 1, 2, 5 and 9 weeks after lasering in experimental and in a group of naïve rats. The effects of these drugs were investigated by examining at 9 weeks retinal afferents to the superior colliculus anterogradely labeled with Cholera Toxin B subunit injected into COHT eyes.

Results At 9 weeks the volume of the retino-tectal projection was 4.09±0.31 (n=16), 3.13±0.74 (n=13), 3.78±0.8 (n=15), or 3.19±0.63 (n=15), for the unlesioned, vehicle-, Alphagan-P-, or Timolol-treated groups of rats, respectively. There were significant reductions in the volume of the retino-tectal projection in timolol or vehicle-treated groups when compared to naïve or BMD-treated groups.

Conclusion COHT results nine weeks later in the loss of approximately 13% of the retino-tectal terminals, Timoptic treatment did not prevent retino-tectal degeneration, and Alphagan-P-treatement resulted in loss of 7%, providing a statistically significant protection against COHT-induced degeneration of the retinotectal projection. These results are consistent with previous studies (WoldeMussie et al., 2001; IOVS 42:2849) showing similar degree of protection. Research support: F.Séneca PI82/00540/FS/01, BFI2002-03742 and Allergan Inc.

EVER-2004-abstractbook.indd 212 8/19/04 12:27:27 PM

■ 3421

Health Economics for the European Vision Research Community

SMITH AF
Health Economics Unit, Alcon Laboratories & Nuffield Laboratory of Ophthalmology, University of Oxford, Oxford

Purpose To present some of the rationale and key health economics techniques used in evaluating existing and new health care interventions within the context of eye disease.

Methods The following key topics will be covered: Budget impact analysis, cost-analysis, cost-minimisation, cost-effectiveness, cost-utility and cost-benefit analyses will all be explored in a lecture format with examples drawn from studies in the field of eye disease which have already been conducted.

Results The hope is that participants will ask questions and that the session will be interactive with questions from the floor.

Conclusion An attempt will be made to form a working group on ocular health economic matters to promote research in this area throughout Europe.

EVER-2004-abstractbook.indd 213 8/19/04 12:27:27 PM

■ 3431

Anatomical and geometric model for biomechanical corneal flattening in Lasik: The flap and stromal ablation in myopia surgery

VELARDE JI (1), LLORCA F (2), FERNANDEZ DEL COTERO JN (3)
(1) Research and Development. Instituto Cántabro de Oftalmología, Santander
(2) Preventive Medicine and Public Health - University of Cantabria, Santander
(3) Instituto Cántabro de Oftalmología, Santander

Purpose To propose a model of corneal flattening in Lasik treatment of myopia that takes into account the microanatomy of the human cornea.

Methods A theoretic geometric model of the cornea was designed. The thickness of the epithelium was considered to be 45µ, and the distribution of stromal lamellae was considered constant and uniform across the central stroma. The relationship between the theoretic flap thickness (160µ) of a Moria 2 microkeratome, the stromal ablation depth and the proportion of corneal thickness was worked out.

Results Even though the thickness of the epithelium and the distribution of stromal lamellae was considered constant across the central stroma, the theoretic flap of thin corneas account for a bigger proportion of corneal thickness. The same proportion was obtained when evaluating stromal ablation depth. This effect is only evaluated in the central area of the flap and at the centre of the stromal ablation.

Conclusion In spite of the uniformity of the model, there is a difference between thin and thick corneas when evaluating the percentage that represents central area in myopia surgery. Variability of three-dimensional stromal architecture and corneal fibrils can modify this proportion.

■ 3432

LASIK induced Keratectasia

JASTANEIAH SJ (1), RAJHI AR (2)
(1) Khaled Eye Specialist Hospital (KKESH), Riyadh
(2) KKESH, Riyadh

Purpose To evaluate different proposed risk factors for the development of ectasia after laser in situ keratomileusis (LASIK)

Methods A retrospective study including 23 eyes of 14 patients who developed ectasia after LASIK. Evaluated criteria included pre and postoperative cycloplegic refraction, uncorrected and best-corrected visual acuity, pachymetry, corneal curvature, topographic maps and operative data findings

Results The interval between surgery and the diagnosis of ectasia ranged from a 1 to 33.7 months. Nine of the23 eyes(39%) had significant history indicating possible corneal pathology. Form fruste keratoconus was diagnosed in 9(39%) eyes.Thirty four% of eyes had over ablation leaving the cornea with< 250 um of residual corneal bed (RCB). The average pachymetry was 504 um;10 eyes had preoperative pachymetry of < 500 um.The correlation between preoperative corneal thickness of < 500 um and < 540 um, and 250 um of RCB was significant (P = 0.004, P = 0.04 respectively). There was also a significant correlative between BCVA of < 20/20 & a cylinder of >2 D (P = 0.008). Eighteen of 20(90%) eyes had > 10% of ablation ratio per total corneal thickness (P = 0.005)

Conclusion It is important to identify factors such as family history of keratoconus including ectasia after LASIK or a history of changing refraction when interviewing a patient for LASIK. Suspicious corneal topography, preoperative corneal thickness of <500 um and astigmatism of > 2 D are predisposing factors for the development of ectasia after LASIK. High respect should be given to keep a RCB of 250 um or even 300 um. It may now be timely to consider setting new, safe criteria for LASIK given the availabiity of alternative refractive procedures

■ 3433

Effect of lasik to correct high compound myopic astigmatism on visual acuity

GIL R (1, 2), ARRANZ E (1), SáNCHEZ JM (1), HERNANDEZ VERDEJO JL (3, 2), TEUS MA (1, 4)
(1) VISSUM Hospital Oftalmológico, Madrid
(2) Universidad Complutense, Madrid
(3) VISSUM Hospital Oftalmólogico, Madrid
(4) Universidad de Alcalá, Madrid

Purpose To evaluate the effect of lasik to correct high compound myopic astigmatism on Snellen visual acuity.

Methods This is a prospective study in which we evaluated 37 eyes of 37 patients with compound myopic astigmatism higher than 3 D, with best Snellen visual acuity lower than 0.9. Lasik was performed by the same surgeon, using the Tecnolas 217 laser and the Moria M2 microkeratome. The principal variable was the postoperative best corrected visual acuity. The statistical analysis of the results was done with the two tail paired t–Student test.

Results The preoperative spherical refractive error was –5.1 ± 0.2 D and –4.04 ± 0.6 D of cylinder. The preoperative BCVA was in all cases lower than 0.9 (0.74 ± 0.16). The postoperative spherical refractive error was -0,3 ± 0.5 D and -0.4 ± 0.5 D for cylinder with postoperative BCVA of 0.79 ± 0.16 (p = 0.002). 38.8% of the eyes improved their vision up to one line, 21.6% improved between one and two lines and 13.5% improved more than two lines.

Conclusion Our results suggest an increase of postop BCVA in patients who undergo lasik to correct high compound myopic astigmatism with abnormal BCVA. This might indicate that the presumed ambyopia associated to high astigmatism is, in some cases, due to optical phenomena that might be corrected with lasik surgery.

■ 3434

Contrast sensitivity function and low contrast visual acuity in low to moderate myopic patients after LASIK

GIL R (1, 2), TEUS MA (1, 3), HERNANDEZ VERDEJO JL (1, 2), ÁLVAREZ MT (4), MARINA C (1)
(1) VISSUM Hospital Oftalmológico, Madrid
(2) Universidad Complutense, Madrid
(3) Universidad de Alcalá, Madrid
(4) VISSUM Hospital Oftalmólogico, Madrid

Purpose To study the change in low contrast visual acuity and contrast sensitivity function in low to moderate myopic patients after LASIK.

Methods This is a prospective, single masked, interventional case series study were the inclusion criteria were myopia lower than 7.00D and astigmatism lower than 3.00D, and best corrected visual acuity 20/20 or better.Low contrast visual acuity and contrast sensitivity were measured by a single masked examiner under mesopic conditions using ETDRS 2,5 % contrast and CSV 1000, respectively. Measures were analyzed before LASIK, at 1 week, at 1 month and 3 months after surgery always with the residual refractive errorLASIK was performed using the Technolas laser, the Hansatome microkeratome, the same nomogram settings and surgeon in all cases.The ANOVA and paired two tails Student´s t tests analyses were performed.

Results We analyzed 43 eyes of 43 consecutive patients who underwent LASIK for low to moderate myopia. The mean spherical was –3.25 +/- 1.35 D (range –0.25 to –6.75D) and astigmatism lower than 3.00D.We found a reduction in low contrast visual acuity in every follow-up after LASIK, but it was only significant at 1 week after (p:0.01). On the other hand, contrast sensitivity function was not statistically reduced in any follow-up after the procedure.

Conclusion Our results suggest that the 2.5% ETDRS is a more sensible test to detect changes in visual function than the CSV 1000 in low to moderate myopic patients after LASIK procedure.

EVER-2004-abstractbook.indd 214 8/19/04 12:27:28 PM

3435
What can we learn from failures in refractive surgery?

MÜLLER LJ (1), NIEUWENDAAL CP (2)
(1) Netherlands Ophthalmic Research Institute, Ocular Signal Transduction, Amsterdam
(2) Academical Medical Centre AMC, Amsterdam

Purpose Refractive surgery is a well accepted technique to correct for refractive errors. As it interferes with the normal physiology of the cornea and thus also with corneal nerves essential to sense pain it is necessary to analyse buttons from failures in order to understand the process of wound healing.

Methods A LASIK patient treated abroad in 2001 visited the AMC in 2003. Due to insertion of an INTAC (ectasia) and flap displacement, vision was 1/60. After replacement of the cornea by transplantation, the 9 mm button was immediately fixed in the operating theatre and completely analysed in cross and serial frontal sections for light and electron microscopy.

Results Stromal nerves in the human cornea are known to be located in the anterior third and to give rise to an extremely high density of nerve fibers and nerve terminals in the epithelium. The interface of the LASIK flap characterized by amorphous extracellular matrix (a-ECM) appeared to be located in the mid stroma (approximately 250 µm) and not as expected in the anterior third (160-180 µm). Stroma and epithelium in the flap were hardly innervated whereas in the mid periphery of the posterior stroma beautiful ones were found. Some had a normal oval shaped morphology and few larger nerve bundles showed fiber free spaces filled with a-ECM. In addition, a-ECM and cells others than keratocytes were present at the borderline between INTAC and stroma.

Conclusion A remaining stromal bed of about 250 µm may lead to ectasia. Any cut or insertion in the stoma induces the formation of a-ECM and such a discontinuity forces the nerves to take another pathway. The cells along the INTAC seem to be from bone marrow origin.

3436 / 340
Risk Factors for Laser In Situ Keratomileusis (LASIK)

BEHNDIG AB, JONSSON M
Department of Clinical Science/Ophthalmology, Ummeå University, Umeå

Purpose To see if deviations in the localization of the cornea's thinnest point, or the magnitude and localization of a posterior corneal ectasia, is associated with deviations in the spherical equivalent, the astigmatism or the magnitude of an anterior corneal ectasia. To see if "risk corneas" for iatrogenic keratectasia can be identified without a pachymetry map of the cornea.

Methods 308 eyes of 156 healthy volunteers with various refractive errors were examined with Orbscan II and autorefractometer-keratometer. The corneal thickness was registered at the fixation point, at the geometrical center and at the thinnest point of the cornea. Keratometry and refraction were determined for all subjects.

Results The thinnest point of the cornea was predominantly located in the inferotemporal quadrant, and was significantly thinner than the fixation point (539.6 ± 35.8µm and 548.0 ± 35.4µm, respectively, $P < 0.001$). Interestingly, the larger this difference was, the longer the distance between these points. No relationship was found between the refractive or "external surface" measurements and the "internal surface" measurements.

Conclusion The absence of a clear relationship between the shape of the anterior corneal surface or the refractive error, and the shape of the posterior corneal surface, necessitates a thorough pachymetric evaluation of the cornea before every LASIK procedure, with special attention to the inferotemporal area.

3437 / 385
Therapeutic Applications of Contact Lenses in Myopia Control

MAHOMED A (1, 2), PUNYAMOONWONGSA P (1, 2), TIGHE B (1, 3)
(1) Biomaterials Research Unit, CEAC
(2) Aston University, Birmingham UK
(3) Aston Univeristy, Birmingham UK

Purpose Pirenzepine has attracted recent interest in the control of myopia. This poster examines the potential of using micellar phosholipid-based nanostructures ("Astosomes") to incorporate pirenzepine in order to improve the bioavailability and the therapeutic efficacy of the drug when delivered from a contact lens and to determine whether pirenzepine can be incorporated without disrupting the phospholipid assembly.

Methods Monolayers of Astosome-pirenzepine complexes were studied using a Langmuir-Blodgett Trough. The complexes were incorporated into a range of hydrogel compositions.

Results The incorporation of 0.5% pirenzepine into astosome nanoparticles does not cause a remarkable change in the shape of surface pressure-area (λ-A) isotherm but increasing of the percent of drug to 1.0% does cause the isotherm to shift to larger areas, indicating that the pirenzepine incorporated inside astosome nanoparticles increases the size of this nanostructure formulation. The cross-sectional molecular area of monolayer of astosome loaded with 1.0% pirenzepine was found to be 20% greater than that of 0.5% pirenzepine. The information was used in the design ofhydrogel release systems.

Conclusion The incorporation of pirenzepine into Astosome formulations produces nanostructures of sub-liposomal dimensions and it is logical to use this approach to improve the bioavailability and the therapeutic efficacy of pirenzepine and other ophthalmic drugs using contact lenses as a delivery device.

3438 / 386
Comparison of early and middle-term microscopic morphological corneal response after PRK, LASEK and alcohol-free LASEK

NUBILE M, LANZINI M, COSTANTINO O, MASTROPASQUA L
Ophthalmic Clinic, University "G.d'Annunzio" Chieti-Pescara, Chieti, Italy

Purpose To compare the early wound-healing and inflammatory response after PRK, standard LASEK, and alcohol-free LASEK by means of confocal microscopy.

Methods 90 eyes of 90 patients were randomly assigned to 3 myopic treatment groups. 30 eyes were treated with PRK, 30 eyes underwent standard LASEK, and 30 eyes underwent alcohol-free LASEK. Confocal microscopy examination was performed by using Confoscan 3 at the baseline, 30', 24 hours, 3,7,15 days, and 1 months postoperatively.

Results At 30' after ablation a superficial acellular layer was visible in all patients without differences in reflectivity and thickness within groups. PRK group showed activated keratocytes as main cell type responsible for repopulation. In LASEK and alcohol-free LASEK groups, both activated keratocytes and inflammatory cells repopulated the acellular layer in the first week. The mean value of inflammatory cell density at day 1 and 3 however showed significant differences ($p<0,01$) between standard and alcohol-free technique (310 ± 66 cell/mm2 and 68 ± 25 cell/mm2, respectively). Epithelial flap was visible in the early postoperative period up to 3 days in both LASEK groups, appearing less damaged in the alcohol-free LASEK group. 15 and 30 days examinations showed in all groups a clear anterior stroma with tendency of keratocyte repopulation with no haze. Keratocyte density and reflectivity of the anterior stroma did not show difference between groups.

Conclusion Epithelial damaging of the LASEK flap due to alcohol exposure could explain the greater inflammatory induction within the anterior stroma. In the middle-term postoperative period no differences in transparency and cellularity among the groups were observed.

EVER-2004-abstractbook.indd 215 8/19/04 12:27:28 PM

■ 3441

Improved retinal imaging by combining a series of OCT scans

SANDER B (1), MARTINI JøRGENSEN T (2)
(1) Department of Ophthalmology, Herlev Hospital, University of Copenhagen, Copenhagen
(2) Optics and Plasma Research Department, Risø National Laboratory, Roskilde

Purpose We present a method for enhancing the signal-to-noise ratios of optical coherence tomography images as obtained with commercial systems like the Humphrey-Zeiss OCT1-2 and Stratus-OCT systems.

Methods The method is based on recording a series of conventional B-scans, which are then adequately aligned in order to produce an average B-scan.

Results We outline the steps in combining the individual scans and demonstrate the impact of the improved imaging for the heatlhy eye and a number of clinical cases. In the healthy eye, the visualisation of the layered structure of the retinal layers is substantially improved. The outer photoreceptor segments, as well as a multi-layered structure of the outer hyperreflective band which has been loosely attributed to the retinal pigment epithelium (RPE)/choriocapillaris is outlined clearly. As demonstrated in a case of central serous detachment the middle, hyperreflective layer in the multilayer structure can be identified as the interdigitizing outer photoreceptor segments/junction. The improved visualisation also allows a detailed examination of post-edematous structural disorganization as well as post ichemic attenuation of the inner retina superior to standard OCT images

Conclusion Averaging of multiple OCT scans raises the quality of retinal imaging sufficiently to reveal new details of retinal structure and pathophysiology with a resolution comparable to ultrahigh-resolution optical coherence tomography.

■ 3442

Avenues opened by en-face OCT in imaging the eye

PODOLEANU A (1), ROSA CC (1), DOBRE GM (1), CUCU R (1), JACKSON DA (1), ROSEN RB (2), ROGERS JA (3)
(1) Applied Optics Groups, University of Kent, Canterbury
(2) New York Eye and Ear Infirmary, New York
(3) Ophthalmic Technologies Inc., Toronto

Purpose To report different imaging possibilities opened by the en-face flying spot OCT concept.

Methods We researched, designed, assembled and tested imaging instruments for the eye which have at least two channels. These are OCT/confocal or OCT/OCT. These channels can work simultaneously or sequentially. All the versions mentioned are versatile in respect to their regime of operation, as they can perform A-scanning, B-scanning and C-scanning, such possibility being allowed by using T-scans (transverse profiles of reflectivity) to construct the images.

Results We present: (i) images from the fundus and from the cornea using simultaneous imaging in an OCT and confocal channel;(ii) images from the fundus using simultaneous imaging in an OCT and confocal channel tuned on the fluorescence of ICG;(iii) images from the fundus using simultaneous imaging in two OCT channels with different depth resolution, where the channel of coarser depth resolution offers an image similar to that of the confocal channel in the OCT/confocal instrument;(iv) images of the retina using an instrument which can sequentially be switched between OCT and confocal regime of operation;(v) images of the lamina cribrosa and cornea using two OCT polarisation channels sensitive to polarisation along rectangular directions.

Conclusion En-face OCT imaging opens new ways for high resolution imaging of the eye.

■ 3443

Recent developments in Ultrahigh resolution OCT

DREXLER W
Christian Doppler Laboratory, Institute of Medical Physics, Vienna

Purpose In the past two decades Optical Coherence Tomography (OCT) has been established as an adjunct diagnostic technique for non-invasive, high resolution cross-sectional imaging in ophthalmology.The development of ultrabroad bandwidth light sources has recently enabled a significant improvement in OCT imaging, demonstrating the potential of OCT to accomplish its original goal of performing noninvasive optical biopsies.

Methods Ex vivo ultrahigh resolution OCT images are compared with histological results. In vivo ultrahigh-resolution OCT and preliminary spectroscopic OCT results are presented.

Conclusion Ultrahigh resolution OCT results in Ophthalmology will be presented and impact on future clinical and research applications will be discussed.

■ 3444

Ultra-high resolution video rate in vivo retinal imaging and Doppler velocimetry with Spectral Domain Optical Coherence Tomography

DE BOER JF
Harvard Medical School and Wellman laboratories of Photomedicine, Boston

Purpose We have realized a 150 fold improvement of the sensitivity over current state of the art OCT technology allowing video rate in vivo retinal imaging without compromising image quality. An ultra-high speed video rate (29 frames/sec) spectral domain OCT (SD-OCT) system will bepresented that continuously obtained in vivo images of a human retina at 29,300 A-lines/s. A 3-D volume of the retina was constructed from the data acquired. Using Doppler signal processing bi-directional flow was measured in retinal artery-vein pairs. The ultra-high-speed SD-ODT system allows visualization of the pulsatile nature of retinal blood flow, detects blood flow within the choroid and retinal capillaries, and provides information on the cardiac cycle. Using a new broadband superluminescent source, we present a verified in vivo axial resolution of 3.5 micron by analyzing the specular reflection form the foveal umbo.Video rate ultra high resolution movies of the fovea are presented.

Conclusion Ultra-high-resolution video rate SD-OCT offers many advantages inretinal imaging, maintaining high signal to noise while operating at asafe ocular exposure level. The unprecedented speed eliminates motionartifacts and the need to re-align A-lines, enabling accurate 3-Dmapping of the retinal topography, and provides a shift fromtwo-dimensional imaging to three-dimensional screening of large retinalvolumes.

EVER-2004-abstractbook.indd 216 8/19/04 12:27:29 PM

■ 3445

Miniaturized Fundus Cameras

NIEDERER P
Institute of Biomedical Engineering, Zurich

Purpose Retinopathy of prematurity (ROP) is a pathological development of the retina in prematurely born children. In order to enable timely diagnosis and treatment miniaturized fundus cameras intended for acquisition of wide angle digital fundus pictures have been designed. Prototypes of these cameras and images acquired with these prototypes will be exposed.

■ 3446

Selective Retina Therapy (SRT): Technics, Methods and First Clinical Results

BRINKMANN R (1), THEISEN-KUNDE D (2), ELSNER H (3), PÖRKSEN E (3), HAMILTON P (4), ROIDER J (5), BIRNGRUBER R (2)
(1) Medical Laser CenterUniversity Eye Clinic, Lübeck
(2) Medical Laser Center, Lübeck
(3) University Eye Clinic, Lübeck
(4) St. Thomas Hospital, London
(5) University Eye Clinic, Kiel, Germany

Purpose The selective retina therapy (SRT) is a new laser procedure targeting on retinal diseases, which are thought to be associated with a degradation of the retinal pigment epithelium (RPE). Aim of the irradiation is to selectively damage the RPE without affecting the neural retina and the photoreceptors. Goal of the treatment is to stimulate RPE cell migration and proliferation into the irradiated area in order to improve the metabolism of the diseased retina. In a pilot study more than 150 patients with soft drusen, retinopathia centralis serosa (RCS) and macular oedema were treated. The first 3-center international trial targets on diabetic macular oedema and branch vein occlusion. In SRT a train of 30 green µs-laser pulses from a Nd:YLF-Laser (527 nm) is applied to the fundus with a repetition rate of 100 Hz. The mechanisms behind selective RPE-effects will be discussed reviewing in vitro results and temperature calculations. Exceeding radiant exposures of 650 mJ/cm2 per pulse, RPE-defects in patients were shown by leakage using Fl- or ICG-angiography. Neither bleeding nor scotoma, proved by microperimery, were observed, thus demonstrating no adverse effects to the chorioidea or the photoreceptors, respectively. The clinical results after an observation period of 12-18 months are reported.Since the laser effects are limited to the RPE, the irradiated sides are ophthalmoscopically invisible, thus a dosimetry control is demanded. We report on a non-invasive optoacoustic on-line technique to point out successful RPE-irradiation and compare the data to those achieved with standard angiography one hour post treatment.

EVER-2004-abstractbook.indd 217 8/19/04 12:27:29 PM

■ 3461

Manual lens stretching apparatuses for optical properties analysis of natural lens, iols and refilled lens capsule (phaco-ersatz)

ACOSTA AC (1, 2), LAMAR PD (1, 3), LEE W (1), DENHAM DB (1), ABRI A (1, 4), NOSE I (1), ZIEBARTH N (1), BORJA D (1, 5), OROZCO M (1, 5), MANNS F (1, 5), HO A (6), PAREL JM (1, 5, 4)

(1) Ophthalmic Biophysics Center, Bascom Palmer Eye Institute, University of Miami, Miami, FL
(2) Hospital Oftalmológico Dr P. Lagleyze, Buenos Aires, Argentina
(3) Rudolf Foundation Hospital Department of Ophthalmology and Ludwig Boltzmann Institute for Retinology and Biomicroscopic Laser Surgery, Vienna, Austria
(4) Rudolf Foundation Hospital Department of Ophthalmology and Ludwig Boltzmann Institute for Retinology and Biomicroscopic Laser Surgery, Vienna
(5) Department of Biomedical Engineering, University of Miami, College of Engineering, Miami, FL
(6) Vision CRC, University of New South Wales, Sydney

Purpose To design a compact portable instrument to measure and compare the accommodative optical properties of crystalline, implanted IOLs and refilled lens (Phaco-Ersatz).

Methods MLSA are hand-held devices to stretch the sclera-ciliary body-zonular apparatus–lens section. MLSA I has 8 independent spring activated segments whereas MLSA II is equipped with a cam system that activates all 8 segments simultaneously by rotating a lever. The devices straddle the globe at the level of the lens. Different segments were built to accommodate different globe diameters. After conjunctival, muscle and fat tissues removal, the globe is glued to the 8 segments using cyanoacrylate adhesive. The posterior pole is sectioned, manual vitrectomy performed and the tissue section flipped over for cornea removal. Dissection of the sclera between the 8 segments is made using thin scissors and the iris is removed. Optical power (+/-0.5D) and zonules/lens diameter (+/-25um) measurements can be obtained using a Scheiner system and a 45o slit-lamp mounted on an operating microscope equipped with CCD and digital camera. The MLSA are also used with the BPEI-Miyake-Apple morphology system and a non-contact optical lens capsule thickness measuring system. Once measurements have been completed, the lens is removed for shadowphotogrammetric assessment and/or the tissue is fixed for histopatology.

Results MLSA was used in human and monkey eyes. An analysis on the effect of tissue preservation and showed a ~5% lens diameter change due to stretch over 3 days when tissues where immersed in BSS at 3oC, whereas no measurable changes occurred after 24 hrs with 0.3% formalin. In an ongoing study, MLSA showed >8% changes occurring in a refilled lens capsule (Phaco Ersatz) but no changes in 4 eyes implanted with conventional IOLs.

Conclusion MLSA is a useful tool for accommodation studies.CR: NONE. Support: NIH EY14225; Florida Lions Eye Bank; Vision CRC, Sydney Australia; Fight for Sight; Research to Prevent Blindness, NY, NY; Henri and Flore Lesieur Foundation, Palm Beach, FL.

■ 3462

In vivo experiments of polymer refilling of the capsular bag for presbyopia

KOOPMANS SA (1), TERWEE T (2), KOOIJMAN AC (1), GLASSER A (3), WENDT M (3)

(1) Department of Ophthalmology, Groningen
(2) Pfizer, Groningen
(3) College of Optometry, Houston, TX

Purpose Demonstration of accommodation in refilled primate eyes.

Methods Polymer refilling of the capsular bag is carried out after removal of the lens nucleus and cortex in iridectomised eyes of rhesus macaques. Accommodation is stimulated with pilocarpine or carbachol iontophoresis and the result is measured with a Hartinger coincidence refractometer and A-scan ultrasound.

Results Accommodative changes are recordable as changes in refraction and changes in lens thickness.

Conclusion Objective measurements of refractive- and lens thickness changes are required to demonstrate accommodation in rhesus macaques.

■ 3463

Phaco-Ersatz 2004 update: Ex-vivo pre-post lens capsule refilling optomechanical accommodative evaluation.

PAREL JM (1, 2, 3), LAMAR PD (4, 1), ACOSTA AC (1, 5), BILLOTTE C (6, 1), FERNANDEZ V (1), ABRI A (4, 1), DENHAM DB (1), LEE W (1), ZIEBARTH N (1, 2), BORJA D (1, 2), OROZCO M (1, 2), MANNS F (1, 2), HO A (7), WATLING T (8), HUGHES T (8), MANOR B (7), SWEENEY D (7), AUGUSTEYN R (7), HOLDEN B (7)

(1) OBC/Bascom Palmer Eye Institute University of Miami School of Medicine, Miami
(2) Dept of Biomedical Engineering, Univ of Miami College of Engineering, Coral Gables
(3) University of Liege Department of Ophthalmology CHU Sart-Tillman, Liege
(4) Dept of Ophthalmology, Rudolf Foundation Hospital and Ludwig Boltzmann Institute for Retinology and Biomicroscopic Laser Surgery, Vienna
(5) Hospital Oftalmológico Dr P. Lagleyze, Buenos Aires
(6) Centre Hospitalier Universitaire de Caen, Caen
(7) Vision Cooperative Research Centre, University of New South Wales, Sydney
(8) CSIRO, Melbourne

Purpose Evaluate the potential of Phaco-Ersatz at restoring accommodation.

Methods Phaco-Ersatz is a lens capsule refilling technique designed to restore accommodation after presbyopia and cataract surgery via a 2mm self-sealing clear corneal incision. Procedure safety, anti-LEC proliferative treatment and polymer biocompatibility were tested in rabbits while effectiveness was assessed using lens stretching apparatus EVAS to measure radial stretching forces, changes in lens diameter, thickness, and optical power. Simulated accommodation in human, rhesus, cynomolgus, baboon and pig cadaver eyes were studied.

Results The effect of radially stretching the circular ciliary muscle by 2 mm only affected the results by less than 10%, accommodation forces ranged from 3 to 13 g and accommodation amplitude from 0 to 1.5D in 40 to 90 year old presbyopic human eyes (avg 0.3D, n=10), to 2.8D in a 5month old pig, to over 20D in young primates eyes (avg 14D, n=44). Up to 13D of accommodation was restored by Phaco-Ersatz in primates (avg 10D, n=10).

Conclusion Lens refilling can restore accommodation

EVER-2004-abstractbook.indd 218 8/19/04 12:27:30 PM

■ 3464

Computer controlled lens stretching device

BARRAQUER R, MICHAEL R, CARRETIE R
"Joaquin Barraquer" Chair of Eye Research, Barraquer University Institute, Autonomous University of Barcelona, Barcelona

Purpose To design an instrument to measure the mechanical and dynamic optical properties of human donor lenses and refilled lenses during simulated accommodation ex-vivo.

Methods Based on previous designs by Fisher, Glasser, Campbell and Parel the Computer Controlled Lens Stretching Device (CCLSD) consists of a rigid bench for holding and stretching coronal eye sections including the ciliary-lens zone, while allowing front and back axial, as well as oblique observation and measuring. Circumferential stretching is created by a stepper motor coupled to a digital outside micrometer for linear displacement and distance measurement, and a digital balance for load measuring. This is attached to the specimen through 8 Prolene sutures and plastic plates glued to the sectioned sclera. One web cam is placed above the crystalline lens to monitor the coronary diameter changes and another web cam will be rebuilt to take low resolution Scheimpflug images to monitor sagittal diameter changes during stretching.

Results The CCLSD is a compact, portable lens stretching device with direct measurement of displacement with a precision of 1.25 µm (one step movement of the stepper motor), and of load with precision of 0.1 mN (0.01g). All operating and measuring parts have data output and are computer controlled through LabView routines with a single program, also integrating image acquisition. The apparatus can be used in horizontal or vertical position, for measurements with either laboratory or clinical-design (topography, aberrometry, ray tracing) instruments.

Conclusion The CCLSD offers precision, integrated control and measurement, and portability for lens accommodation studies.

EVER-2004-abstractbook.indd 219 8/19/04 12:27:30 PM

'The book gives a very good overview of the embryology of the eye and its adnexae and may serve as a useful compendium for students of neonatal and paediatric ophthalmology.' Ophthalmologica
(Review of the first edition)

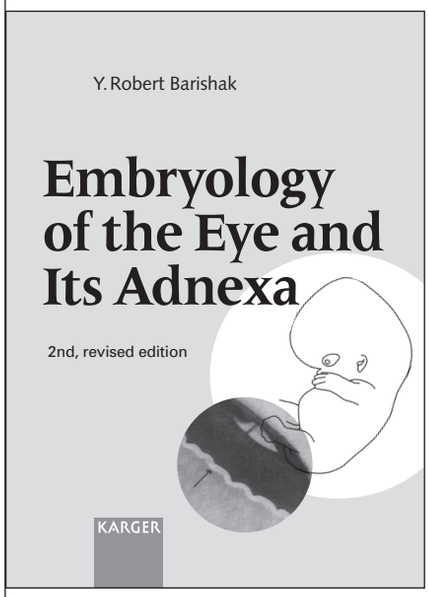

Y. Robert Barishak

Embryology of the Eye and Its Adnexa

2nd, revised edition

Ophthalmology; Embryology; Histology, Perinatal Medicine, Teratology

Contents

Introduction

Embryogenesis

Organogenesis
- Fourth Week
- Fifth Week
- Sixth Week
- Seventh Week
- Eighth Week

Differentiation
- Third Month
- Fourth Month
- Fifth Month
- Sixth Month
- Seventh Month
- Eighth Month
- Ninth Month

Birth and after Birth

References
Subject Index

This monograph, unlike most previously published books on the subject, approaches the embryology of the eye and its adnexae from the perspective of gestational age, providing a unique overall view of the various structures of the eye at different stages of prenatal development. Embryogenesis, organogenesis and differentiation are three main periods that can be distinguished in the prenatal development of the human eye. The chapters in this book describe in detail the series of sequential events that occur during these periods from the fertilization of the ovum to, and after, birth.
Superbly illustrated and clearly written, this text contains a wealth of information for residents in ophthalmology, neonatal and pediatric ophthalmologists, as well as for all ophthalmologists and physicians interested in developmental anomalies.

KI 01402

www.karger.com/ophthalmology

Barishak, Y.R. (Ramat Gan)
Embryology of the Eye and Its Adnexa
2nd, revised edition
VIII + 132 p., 80 fig., 1 tab., hard cover, 2001
CHF 97.50 / EUR 69.50 / USD 85.00
Prices subject to change
EUR price for Germany, USD price for USA only
ISBN 3–8055–7179–8

Order Form

Please send: ____ copy/ies

Postage and handling free with prepayment

Payment:
☐ Check enclosed ☐ Please bill me

Please charge to my credit card
☐ American Express ☐ Diners ☐ Eurocard
☐ MasterCard ☐ Visa

Card No.: _____

Exp. date: _____

Fax: +41 61 306 12 34
S. Karger AG, P.O. Box, CH–4009 Basel (Switzerland)
E-Mail karger@karger.ch, **www.karger.com**

Name/Address: _____

Date: _____

Signature: _____

KARGER

Orders may be placed with any bookshop, subscription agency, directly with the publisher or through a Karger distributor.

ALL AUTHORS INDEX

EVER 2004

September 24-27, 2004
Vilamoura, Portugal

EVER-2004-abstractbook.indd 221 8/19/04 12:27:33 PM

All authors of abstracts are listed alphabetically.

Three digit numbers refer to posters, reproduced on pages 17-84.
Four digit numbers refer to oral presentations, printed on pages 85-221.
The digit numbers marked in bold indicates a first author abstract.

ABAD LOZANO JL: 2321
ABAD M: **156**, **1261**, **1265**
ABBOUD EB: 126, 1356
ABDALLAH A: 179, 1114, 1115
ABECIA E: **146**
ABREU R: 1431
ABRI A: 3461, 3463
ABU EL ASRAR A: **105**, **1157**, **1213**, **1216**
ACOSTA AC: 1461, **3461**, 3463
ACQUART S: **349**, **350**, 344, 345, 348, 351, 352
AGLA EK: 353, 3337
AGOPSOWICZ KA: 137
AGOSTINI HT: **3233**
AGUSTIN GONZALO AGUSTIN M: **263**
AHAD M: **179**, 1114, 1115
AHMAD I: **2434**
AIHARA T: 151
AKHTAR S: **320**, **1442**
AKKOYUN I: 140, 1256, 1451
AKOVA Y: 140, 1256, 1451
AL-HAMAD A: 329
AL-HARTHI E: 126, 1356
AL-HUSAINI S: 139
AL-JADAAN IA: 105, 1157
AL-JISHI Z: 329
AL-OBEIDAN SA: 1213
ALACALI N: 1252
ALBON J: 157, 1266, 1443
ALESSANDRINI C: 181
ALFANO G: 2353
ALFONSO E: 1461
ALIÓ JL: 156, 211, 1261, 1265, 2321
ALJAMAL RT: **234d**
ALL-ERICSSON C: **214**
ALLAN B: 1368, 1466
ALLEN RJ: **313**, 191, 274
ALLGOEWER I: 1432
ALMALKI W: 239, 2329
ALMARAZ A: 208
ALMEIDA JB: 227, 269, 271, 306, 333, 337
AL ROBAIE M: 126, 1356
ALVAREZ MT: 1253, 3434
ALYAHYA GA: **234c**
AMANO K: 262, 266, 2425
AMBRÓSIO AF: 124, 236, 2326
AMOAKO MENSAH T: 1123
ANASTASSIOU E: 182, 322
ANASTASSIOU G: **2144**
ANDERSON OA: **115**, **256**, **2428**
ANEGON L: 3334
ANGENIEUX B: 2435
ANTÓN A: 375
ANTON LOPEZ AAL: **234**, **1128**
ARAIZ J: 364, 378
ARDEN GB: **3251**
AREND O: **2412**
ARMITAGE WJ: 157, 1266
ARMOUR R H: **153**
ARRANZ-MARQUEZ E: 1253, 3433
ARSENIJEVIC Y: **2435**
ARTHUR LEVINE-BEREBICHEZ: 101
ASHERY-PADAN R: 2354
ASHWIN P: 203, 2148
ASSELAIN B: 1224, 2242
ASSMANN W: 171
ÅSTRÖM E: **160**, **1446**, 2252
ATKINSON SD: 1467
ATTENBOROUGH M: 358, 3158
AUER C: 1315
AUGOOD C: **3221**
AUGUSTEYN R: 3463
AUGUSTIN HG: **3235**
AURICCHIO A: 2353
AUW-HAEDRICH C: 2142
AVELEIRA C: **124**, 236, 2326
AYALA-FLORES M: 379
AYALA M: 183, 194, 195, 1232, 1235, 2453
AYNACI B: 1451
AZIZ O: 274
BACKHOUSE O: 1133
BAHIA R: 318, 2316
BAKONDI E: 246
BALAYRE SB: **1262**, **1263**, 1445
BALOGH K: 1131
BANFI S: **2353**
BANSAL A: 241
BANTAN I: 126, 1356
BANTSEEV V: 2454
BAPTISTA AMG: **152**
BAPTISTA P: **2466**
BARATHI A: 1241
BARBUR JL: **3144**, **3254**
BARILE S: 1255
BARLET T: 231
BARRANDON Y: 2432
BARRAQUER J: **1362**, **1365, 1464**
BARRAQUER R: **3464**, 1431
BARRETT RP: 332
BASSIME L: **231**
BATHEN TF: 324
BATISTI C: 2141
BAUER SM: 3116
BAUMGARTNER C: 230
BAZAN NG: 116
BECERRA E: 234a
BECKERS J: 2355
BECKINGSALE AA: 188
BEELE H: 3333
BEHAR-COHEN FF: 353, 3337
BEHNDIG A: **340**, 160, **2252**, **3436**, 1446
BENSKIN S: 203, 2148
BENSON S E: **2462**
BERENDSCHOT TTJM: **119**, **120**, 117
BERENGUER-ANDREU J: 3153
BERGLIN L: 214
BERGMAN B: 110
BERGUA A: **225**
BERISHA F: 235, 1129
BERNABINI B: 383
BERNAL DESCOUR F: 202, 2147
BERNAL FB: 221
BERNAL JM: 363, 3313, 341a
BERNARDES R: 130, **2362**, **2463**, 2464, 2465, 2466, 3122
BERNINGER T: 3251
BESCH D: 147
BESSEGHIR K: 353, 3337
BESSOU PB: 221
BETIS F: **1452**
BETTI M: 196
BEUERMAN R: **1241**
BHAT M: 1337
BHOLA RM: 328
BIALEK-SZYMANSKA ABS: 137
BIALEK M: 216, 2126
BIANCIOTTO C: **2341**, **234b**
BICHO MM: 134, 1152
BIDGOOD P: 358, 3158
BILLOTTE C: 3463
BILOTTO L: 2422
BIRCH MK: 1135
BIRKENKAMP-DEMTRÖDER KBD: 321
BIRNGRUBER R: 3446
BITSIOS P: **3143**
BJORCK E: 1161
BLACK GCM: 1443
BLANCO G: 208, 2341, 2347, 2348, 2349, 234a, 234b
BLAZQUEZ ARAUZO FBA: 234, 1128
BLERO D: 1113
BLESSING K: 2455
BODAGHI B: **1214**
BOGDANICI C: **2346**
BOIARDI L: 2121
BONFRER JGM: 2245
BONNEL S: 175
BORJA D: 3461, 3463
BORNFELD N: 2144, 2167
BOUHAIMED M: 126, 1356
BOULTON M: 157, 1266, 1443
BOURGES JL: **353**, 107, **3337**
BOZULIC LD: 1331
BRANDÃO E: 1132

EVER-2004-abstractbook.indd 222 8/19/04 12:27:33 PM

BRANKA F: 1121
BRAVO-LLATA C: 1454
BRECKER S: 229
BREMNER F: 2221
BRETON P: 242
BRICHARD V: 2246
BRINKMANN R: **3446**
BRITTAIN P: 1364
BRON A: 161, 319, 320, **1341**, **2112**, 1442, 1447, 2312, 2317
BRUENECH JR: **1343**
BRUN G: 349
BRUYNS C: 1113
BRUZZICHESSI D: 213, 223, 334
BUCHWALD C: 201, 2146
BUDDE WM: 361, 3418
BUNCE CV: 1434
BUNIATYAN IY: **381**, **382**
BURNIER MN: 208
BYSTRÖM B: **1444**
CABAY L: 1113
CACCIOPPOLI C: 2353
CACHO I: **270**
CAI J: 1443
CAISSIE AL: 208
CALIPEL A: 205, 2247
CAMPARINI M: 3353
CAMPBELL D: 165
CAMPBELL I: 2244
CAMPOS-GUYOTAT L: 343, 347, 348, 349, 351, 1264
CAMPOS EC: 383
CAMPOS L: 323, 345
CAMUS D: 180
CAPÃO-FILIPE J: 148, 190
CAPOROSSI ALDO: 212
CAPPUCCINI L: 2121
CARAMICO T: 2353
CARBOTTI P: 181
CAREDDU GM: 315, 3356
CARLSSON D: 1468, 3336
CARLSSON E: 173
CARLSSON L: 173
CARNEIRO A: 136
CARNOVALE-SCALZO G: **223**, 213, 334
CARRETIE R: 3464
CARTA A: 315, 3356
CARTA F: 315, 3356
CARUNTU I: 2346
CARVALHO AL: 314, 3355
CARVALHO M: **112**
CASANOVA C: **2422**, 2423
CASILLO FC: 247
CASPERS L: 1113
CASTANHEIRA DINIS ACD: 1352, 1353
CASTELO-BRANCO M: 273, 2224, 2421
CASTILHO A: **236**, 124, **2326**
CASTILLO A: 367
CATARINO S: 198, **1333**, 1234, 2254
CEDDAH AC: 107
CEJKOVA J: 324, 1233
CELLINI: **383**
CERMAKOVA I: 325
CHAKRAVARTHY U: **3224**, 3353
CHAN J: 121, 1154
CHARTERIS DG: 2462
CHAUHAN BC: **3164**
CHAUVAUD DC: 107
CHAUVEL P: 2144
CHENTSOVA EV: 1146
CHIDLOW G: **238**, **2328**, 2132, 2233
CHINNERY PF: 1135
CHOH V: **3266**
CHONG NV: 121, 145, 1154
CHONG V: 109, 111
CHUA W H: 1246
CHUNG A: **128**, 326
CHUNG SH: 158, 1267
CHYLACK LT: **2451**
CIMINO L: **2121**
CLAERHOUT I: **3333**
CLARK H: 161, 1447
COCKER KD: 103, 1156
COENTRÃO L: 190
COLLIN JRO: 1364
COLLINS CE: **1133**
COLLINS M: 2454
COLL L: 362, 3419
COLONNA G: 312
CONNOR S: 218, 2128
COOPS A: **366**
CORCOSTEGUI B: **2166**
CORREIA-PINTO J: 2325
COSCAS F.: 1354
COSCAS G: 135, **1254**, **1354**
COSTAGLIOLA CC: 247
COSTANTE G: 223
COSTANTINO O: 386, 3438
COTTER MA: 2322
COUTINHO NETO J: 151
COWDREY G: 248
COZMA L: 2346
CRICELLI R: 312
CROSS SH: 2151
CRUZ AAV: 3352
CUCU R: 3442
CUENCA N: 132
CUNHA-VAZ J: 130, 2463, 2464, 2465, 2466, 3122
CURSIEFEN C: **355**, **2116**, **3231**, **3332**, **3339**, 3331
CZECH T: 230
CZOP DC: 216, 2126
DABBAGH A: 187
DALKE C: **2153**, **3351**
DAMATO B: **1222**, **2244**
DANA MR: 355, 3332, 3339
DANA R: **2333**, 3331
DANNOWSKI H: 341
DARMON J: 1354, 1452
DART JKG: 1368
DAVIES NP: 115, 256, 2428
DE ALMEIDA VMN: **2426**
DEAN WL: 1331
DEB-JOARDAR N: 133
DEB N: **149**, **323**, 344
DE BOER JF: **3444**
DE FRANCESCO S: 212, 2141
DEFREYN A: 352
DE FRUTOS-BARAJA JM: 215
DEGENRING RF: 141, 1251, 3416
DE GRAEF C: 1113
DE HOZ R: **172**, 143, 144, 1143
DE KEIZER RJW: 206, 2248
DEL-MORAL I: 265
DELAHUNT PB: 3256
DELAMERE N.A.: **1331**
DELBOSC B: 2142
DELLBY A: 1161, 1162
DEL MONTE MA: 241
DEL MORAL MARTÍNEZ MI: **264**
DE LUCA M: 2431
DENDALE R: 1224, 2242
DENHAM DB: 3461, 3463
DENIS P: **2414**
DESCAMPS FJ: 1213
DESJARDINS L: **1224**, **2242**, 2246
DE SMET M: **1311**, **1312**, **2164**, **3126**, 1151, 3121, 3124
DE SOUZA RAMALHO P: **134**, **1152**
DEUTMAN A F: **2162**
DE VOS K: 3126
DEWIT D: **191**, 267, 313, 326
DE WIT DW: **311**, 274
DEWITTE J-M: 180
DE WOLFF-ROUENDAAL D: 206, 2248
DHIBI H: 126, 1356
DIAS J: 2466
DIAS JMD: **1353**, 1352
DIAZ-REY A: 333
DÍAZ J: 272
DICK A: **1313**, **2334**
DICKINSON C M: 270
DIEDEREN R: 131
DIEUDONNE SC: **131**
DIGHIERO PLD: 174, 1163, 1262, 1263, 1445
DI IORIO V: 2431
DIMITRAKOPOULOS G: 322
DINET E: 133
DJATIKUSUMO A: 114
DOAN S: **1416**
DOBRE GM: 3442
DOELEMEYER A: **3413**
DOHLMAN C: **1462**, 1463
DONADI EA: 1111
DONAGHY M: 320
DONG X: 183, 194, 195, **1232**, 1235, 2453
DORVAL T: 2242, 2246
DOWLER JF: 1435
DOWNES CS: 1467
DRALANDS L: 105, 1157
DREXLER W: **3443**, 3413
DRIESSENS G: 1113
DROBYSHEV AL: 2355
DUA HS: **2211**, **2433**
DUARTE L: **130**

EVER-2004-abstractbook.indd 223 8/19/04 12:27:34 PM

DUBBELMAN M: **3263**
DUCHESNE B: 1461
DUCREY N: 2142
DULKU S: 1113
DUMBRAVA D: 2422
DUPONT J: 3323
DURAND ML: 1463
DURÁN J: 364, 378
DUTOIT E: 180
DWARIKA D: **328**
DYKA FM: 2133
DZIAMBOR AP: 108
EASTY D: **2113**
EGELHOFFER H: 344
EHLERS NE: 321
EHRICH D: 1334
EK S: 1162
EL-AMIR AN: **1455**
ELENA TIRADO ELENA MJ: 263
ELFVING Å: 194, 195
ELGOHARY MA: **188**, **1435**
EL SHEHA H: **222**, **2124**
ELSNER H: 3446
EL TOKHY E: 222
EMARA E: 2124
EMRE M: 3214
ENZ R: **2133**
EPERON S: 242
ERB C: 3415
ERDELYI B: **2313**
ESKELIN S: 2241
ESPINOZA-NAVARRO J: **101**, 379
ESTEBAN R: 2341
ESTOUR B: 149
EVERY S: 319, 2317
EXARCHOU A: 322
EZRA E: 2461
FABER D: 3124
FAGERHOLM P: 331, **1161**, **1162**, 3336
FALCÃO-REIS F: 136, 148, 190, 1132, 2223, 2325
FALSINI B: **254**, **3322**, 2232
FARIA P: **2224**
FARKAS A: **147**, 257, 305, 2467
FARO C: 314, 3355
FARQUHARSON M: 2243
FAVOR J: 1136, 2155, 3351
FEKE GT: 3412
FELT-BAEYENS O: 242
FELTGEN NF: **2266**
FENERTY C: 366
FERNANDES A: 314, **2323**, 1234, 2254, 3355
FERNANDES P: 227, 269, 271, 306
FERNANDES R: **314**, **3355**, 1234, 2254, 2323
FERNANDEZ-CRUZ A: 1454
FERNANDEZ-DURANGO R: 1454
FERNANDEZ CANILLAS J: 2321
FERNANDEZ DEL COTERO JN: 3431
FERNANDEZ DURANGO R: **3163**
FERNANDEZ N: 2341, 2347, 2349
FERNANDEZ V: **1461**, 3463
FERNANDO A: **125**, **189**
FERNANDO FI: 115, 256, 2428
FERRERAS A: **367**, **368**, 369, 370, 371, 372, 373, 374, 375, 376
FERRER RODRIGUEZ C: **211**, **2321**
FESSER N: 1432
FEUCHT M: 2167
FIADEIRO PT: 2426
FIELDER AR: **103**, **1156**
FIGUEIRA J: 130
FIGUEIREDO JFC: 1111
FILIPEC M: 342, 354, 3338
FINK A: 244
FIRTH G: 248
FIRTH M: 248
FITZKE F: 121, **2361**, 1154
FLAMANT P: 201, 2146
FLAMMER J: 251, 1121, 3214, 3215
FLANAGAN J: 330
FLETCHER AE: **3223**, 3353
FLUOCINOLINE ACETONIDE UVEITIS STUDY GROUP: 1312
FONTES G: 134, 1152
FORMISANO E: 2421
FORRESTER J: **2332**, 2322
FOR THE OPHTHALMIC ONCOLOGY TASK FORCE: 1223
FOSTER DH: 152, 262, 266, 2425
FRANCO S: **337**
FRANKLIN V: 1469
FRANKLIN VJ: **169**, **330**
FRASER S: 307, 1134, 1434, 3152, 3154
FRAZER DG: 1467
FREIRE A: 2224
FREITAS S: 190
FRIS M: **1336**, 1233
FROMBERG I: 1432
FROMOW - GUERRA M: 101, **379**
FRUSCHELLI M: **181**
FRUTOS BARAJA J: 2341
FUCHS H: 1136, 3351
FUCHSJÄGER-MAYRL G: **1123**
FURST D: 1142
FUTTER C: 1466
GABRIEL MM: 332
GAIN P: **344**, **345**, 133, 149, 323, 343, 346, 347, 348, 349, 350, 351, 352, 1264
GALAND A: **1436**
GALAN ME: 254, 3322
GANDOLFI S: **2413**, **3315**, 3414
GAN L: **3336**, 1468
GARCÍA-FEIJOO JGF: 356, 3156
GARCÍA A: 363, 341a, 3313
GARCÍA M: 364, 378
GARCIA-FEIJOO J: 368
GARCIA P M: 3125
GARCIDUENAS-MEJIA M: 379
GARCIN A: 149
GARDIM DEMARCO AL: 1111
GARHOFER G: **1125**
GARON M-L: 2423
GARRAUD O: 344, 345, 348, 349, 350, 351, 352, 1264
GARTAGANIS S: 322
GASTAUD P: 1452
GAUBA V: **267**, **326**, 128, 191, 274
GAVET Y: **133**, **346**, 149, 343, 344, 345, 348, 349, 350
GAVIOLI IG: **247**
GEBOES K: 105, 1157, 1213
GEDIK S: 140, 1256, 1451
GEE H: 330
GEERARDS AJM: **3133**
GEHL Z: **246**
GEHRING W: 2435
GEISER M: 254, 3322
GEKELER F: 2153
GEORGAKOPOULOS C: **322**
GEORGOPOULOS M: 1123
GERMAIN N: 149
GHANCHI FD: 128
GICQUEL JJG: 174, 255, **1163**, **1445**, 1262, 1263, 2427
GILBERT BG: 1163
GILBERT I: 171
GILLESPIE I: 358, 3158
GIL R: 360, **3433**, **3434**, 3417
GIRAO H: **198**, 1234, 1333, 2254
GIRAUD JMG: **150**
GLACET-BERNARD A: 135
GLANC MG: 255, 2427
GLASSER A: **3262**, **3365**, 3462
GLAVINI A: **1443**
GLOTIN AL: 205, 2247
GOEBEL R: 2421
GOGI D: 186
GOLDSCHMEDING R: 1151
GOMBOSS K: **185**
GOMES AOS: 220, 2226
GOMES J: **2212**
GÓMEZ L: 3153
GÓMEZ-RAMÍREZ AM: 127, 138
GONG N: **341**, 3334
GONZAGA S: 2325
GONZALEZ-MEIJOME JM: **333**
GONZALVEZ BG: **118**
GORCZYCA WG: 137
GRAHAM JE: 1467
GRAHAM M: 238, 2328
GRASSI F: **196**
GRASSO G: 181
GRAW J: **1136**, **2155**, 2153, 2355, 3351
GREAVES BG: 2221
GREENWOOD J: 122
GREGORY PTS: 155, 1167
GREGOR Z: 2461
GRESSNEROVA S: 357, 3157
GRESTA P: 323
GRIFFITH M: **1468**, 3336
GRIFFITHS PG: 1135
GRIFFO E: 312
GRUNWALD JE: **3323**
GRUSS P: 2354
GUERREIRO M: 273
GUEX-CROSIER Y: 242, **1414**
GUOMUNDSDÓTTIR GJ: 308

EVER-2004-abstractbook.indd 224 8/19/04 12:27:34 PM

GUO W: 197, 2253
GUPTA SJ: 3353
GURNY R: 242, 353, 3337
GURSHUMOV N: 258
GUTHOFF R: **3261**
GUTIERREZ CG: **359**, **384**, **3159**
GUYOTAT D: 351
GWIAZDA J: **1245**
HABIB MS: **1434**
HADJISTILIANOU T: **212**, **2141**
HAEFLIGER I.O.: 251, 380
HAGEMAN G: **2161**
HAMAR P: 246
HAMEDANI M: **1412**
HAMILTON P: 3446
HAMMAR B: 1161, 1162
HANSEN LH: **2264**, 2266
HAOUCHINE B: **3123**
HARA K: 1112
HARDING JJ: **2251**
HARDY JL: 3256
HARE WA: 3314
HARJUTSALO V: 317, 3357
HARLOW JA: 3144
HARPER RA: 270, 366
HART A: **2151**
HARTSTEIN I: 170
HASZCZ D: 216, 2126
HATA I: 159, 1268
HATTAR S: **3141**
HATTENBACH LO: **2262**
HAUFSCHILD T: **3212**, 3214, 3215
HAUGEN G: 217, 2127
HAWKSWORTH NR: 1442
HAYAKAWA K: 1212
HAZLETT LD: 332
HEEGAARD S: **204**, 116, 201, **2149**, 2142, 2143, 2146, 234c
HEGDE KR: **2452**
HEGDE V: 139
HEIJL A: **2411**
HEIKKONEN J: 2342
HELLSTROM A: **3342**
HEMPEL M: 3334
HENDRIKSE F: 131
HENLEY C: 330
HENNING G: 244
HENRICH PB: **1453**
HENSON DB: 366
HERA R: **129**
HERBA E: **260**, 108, **2123**, 2122
HERBORT CP: **1215**, **1315**
HERNANDEZ E: 1461
HERNANDEZ VERDEJO JL: 3433, 3434
HERNANDEZ VJL: **338**, **360**, **3417**
HERNÁNDEZ E: 364
HERNÁNDEZ M: 364, 378
HERNING M: 204, 2149
HEROLD J: 1363, 1364, 1366, 1367
HERO M: 113, 139
HERRAG S: **347**, **348**, 323, 344
HERRERAS JM: 2348
HERRMANN JH: 2266
HICKS CR: **1465**
HIRST M: 2454
HJERPE A: 322
HO A: 3461, 3463
HOANG-XUAN T: 2432
HOFMANN-RUMMELT CR: 1432
HOLAN V: **354**, 342, **3338**
HOLBACH L: 225, 1432
HOLDEN B: 3463
HOLLÓ G: 365, **3213**
HOLLICK EJ: 1368
HOLMES J. M.: **228**
HONG YJ: 245
HONORÉ BH: 321
HONRUBIA FM: 367, 368, 369, 370, 371, 372, 373, 374, 375, 376
HORNIG R: 2167
HORSCH M: 2355
HOWARD P: 2244
HOYNG C B: 2162
HRABÉ DE ANGELIS M: 1136, 3351
HUA MT: 1436
HUANG LC: 2311
HUGHES EH: 145
HUGHES T: 3463
HUNYADY L: 1131
HYKIN P: 122, 2461
HYVARINEN L: **3345**
IDREES F: 1134
INOUE J: 2455
IOMDINA EN: **250**, **3115**
IONIDES A: 184
ISLAM N: **187**
ISPOLOVA EA: **3117**
ITHO N: 1212
JACKSON AJ: **3132**
JACKSON DA: 3442
JACKSON DG: 3331
JACKSON IJ: 2151
JACKSON TL: 1455
JACOBSON L: **3343**
JAEGLE H: **3253**
JAGER MJ: 2245
JAHN CE: **193**, **1433**, 1432
JAHN CH: 1432
JAHN SE: 193
JAKUBOVICS E: 185
JANOCHA A: 309
JANUARIO C: 2224
JANUARIO G: 2224
JASTANEIAH SJ: **3335**, **3432**
JAUMAIN-SPRIMONT A-S: 180
JÓHANNESSON G: 308
JEAN-MAURICE D: 353, 3337
JEDRZEJEWSKI W: 108
JENKINS JN: 233, 1127
JENKINS SA: 121, 1154
JOHN N: **3353**
JOHNSTON M: 126, 1356
JONAS JB: **141**, **361**, 339, 1251, **3244**, **3418**, 3416
JONSSON M: 340, 3436
JORGE J: **269**, **306**, 227, 271
JOUSSEN J: **3232**
JUENEMANN A: 361, 3418
JUHL BR: 2142
JUROWSKA-LIPUT JJL: 137
KAARNIRANTA K: **1145**, 3151
KABACK M: 377, 2227
KACHAN OV: 250
KADOR P: **2455**
KAHTANI E: 126, 1356
KAIMBO WA KAIMBO D: **316**
KAKAR M: **195**, 194, 1232, 2453
KALHORO A: **229**, **358**, **3158**
KAMAYA S: 1112
KAMEYA S: 1212
KAMIMURA Y: 159, 1268
KAMINSKI S: 1461
KAMPPETER B: **1432**, 1251, 3416
KANDEL GL: **377**, **2227**
KANTELIP B: 2142
KARACORLU M: **1252**, **2265**, 2267
KARACORLU S: 1252
KARAMANOS N: 322
KARDON R: 3142
KARIM A: 248
KARLSSON J-O: 199, 243, **1332**
KASHANI S: 145
KASMIYA M: 203, 2148
KASSNER C: **244**
KATSANOS A: 365
KAWA P: **216**, **2126**
KAWASAKI A: **3142**
KÖKÉNY G: 246
KEATING D: 106
KEERS S: 1135
KEIJSER S: **2145**
KEIZER DE RJW: 2145
KEMENY JL: 2142
KERR J: 330
KERTY E: 217, 2127
KESSELS A: 131
KESTELYN Ph: 3333
KEUNEN JEE: 2245
KHAN AJ: **145**
KHAN I: 1443
KIJLSTRA A: 131
KIM CY: 245
KIM EK: 158, 1267
KING G: **3162**
KINNUNEN K: **301**
KIRCHER K: **230**
KISELEVA OA: 250
KIVELA T: 317, **1221**, 2142, 2241, 2342, 234d, 3357
KJELLEVOLD HAUGEN IB: 1343
KJELLGREN D: **1142**, 1141
KLAEßEN D: 1453
KLOPFER M: 1453
KNEZY K: **259**
KNIGHT B: 1455

EVER-2004-abstractbook.indd 225 8/19/04 12:27:34 PM

KNOBLAUCH K: **3255**
KNOP E: 161, **1441**, **2331**, 1447
KOCH P: 231
KOCKI T: 1335
KOJIMA M: **159**, **1268**
KOLKO M: **116**
KOLODJASCHNA J: **235**, **1129**, 1122
KONO-KONO JO: 1453
KOOIJMAN AC: 3462
KOOPMANS SA: **3462**
KOPPEN C: **3134**
KOSHITZ IN: **3118**, 3111, 3113, 3117
KOSTAKIS VT: 310
KOTHARY PC: **241**
KOTHY P: **365**
KOTLIAR K: **232**, 171, 249, **1126**, **3111**, 1124, 3116, 3118
KOULIKOVSKA M: **331**
KOZAK LR: **2421**
KREISSIG I: 141, **1251**
KRISHNAMOORTHY R: 3165
KRUKOWSKI J: 216, 2126
KRULOVA M: 342, 354, 3338
KRUSE FE: 3332
KUHLI C: 2262
KUIPER EJ: 1151
KUJALA E: **2241**, 1221, 234d
KUO N-W: 179, 1114, 1115
KUROPATWA MK: 137
KUSNYERIK A: 185
KVANTA A: 214
KWARTZ AJ: 366
KYHN M: 204, 2149
LAAN LA: 206, 2248
LAATIKAINEN L: 317, 3357
LABALETTE PL: **180**
LABONIA AF: 223
LACHAPELLE P: **2423**, 2422
LACOMBE E: 1461
LAFUENTE MP: 3313
LAGERSTEDT K: 1161
LA HEIJ EC: 131
LALLEMAND F: 353, 3337
LAMAR PD: 1461, 3461, 3463
LAMBROU GN: 3413
LANGA-MORAGA A: 264
LANGA A: 265
LANGA MORAGA LANGA A: 263
LANGENBUCHER A: **335**
LANTZ O: 2246
LANZINI M: 386, 1165, 3438
LANZL I: **249**, 171, 232, **1124**, **3116**, 1126, 3111
LARROSA JM: **372**, **373**, 367, 368, 369, 370, 371, 374, 375, 376
LARSSON L: 1142
LAUBE T: 2167
LAUDE A: **114**
LAUTENSCHLÄGER C: 1334
LAWLER J: 355, 3339
LAWRENSON JG: **1344**
LEAL EC: 124, 236, 2326
LECLERCQ G: 3333
LEE E: **1367**, 1366
LEE ES: 245
LEE HK: **158**, 245, **1267**
LEE JH: 158, 1267
LEE JJ: 114
LEE W: 3461, 3463
LEFEVRE G: 205, 2247
LEFOURNIER VL: 221
LE GARGASSON JFL: 255, 2427
LEGUAY JM: 1452
LEITE-MOREIRA AF: 2223, 2325
LEONARDI A: **2114**
LEON CR: **1464**
LEONETTI P: 383
LESCH B: **257**
LESKE D. A.: 228
LE TIEN V: 135
LEVEILLARD T: 3312
LEVY C: 1224, 2242
LEYS A: **2163**
LIBONDI T: **312**
LIEM A: 131
LI F: 1468
LIGHTMAN S: 179, 1114, 1115, 1435
LIM TH: 114
LINDBOHM N: 2315
LINDEBERG H: 201, 2146
LINDEGAARD J: **2143**
LINDEN C: **308**
LIND H: 1161
LINHARES JMM: **266**
LIRA M: **162**, **163**
LIU BF: 1337
LIU C: **1361**, 1363, 1364, 1366, 1367, 1467, 1469
LIU Y: 1468, 3336
LLORCA F: 3431
LLOYD AW: **1469**
LOBO C: 130, 2463, 2465
LÖFGREN S: 194, 195, 1232, 2453
LOGEAN E: 2232, 3325
LOHMANN CP: 1468
LOPEZ LARA F: 2341
LÓPEZ-LARA-MARTÍN F: 215
LOPEZ MJ: 369, 372
LOPEZ R: 208
LÖSTER J: 1136, 2155
LOU MF: 2251
LU B: 132, 304
LUCAS RJ: 3141
LUIJK VAN CM: 2145
LUKSCH A: **102**, **1155**, 3327
LUMBROSO I: 1224, 2242
LUNDBERG B: 195
LUND RD: 132, 302, 303, 304
LUNG S: 1122
LÜTJEN DRECOLL E: **2134**
LUTHERT P: 2142
LYMPANY P: 179, 1114, 1115
MAAR N: 102, 1155, 3327
MACEDO AF: **220**, **2226**
MACERI C: 3411
MADEDDU P: 315, 3356
MADILL SA: **218**, **2128**
MAGNANI M: 3121
MAHOMED A: **167**, **385**, **3437**
MAIER M: 3116
MAJO F: **2432**
MÄKIMATTILA S: 1153
MAKOWIECKA-OBIDZINSKA K: 108, 260, 2123
MA KT: 158, 1267
MALASSAGNE F: 345
MANGANELLI C: **2314**
MANISSOLLE C: **351**, **352**, 323, 343, 344, 347, 350, 1264
MANIVANNAN A: 2322
MANKOWSKA A: 216, 2126
MANN AM: **165**, **168**
MANNS F: 3461, 3463
MANOLI P: 149
MANOR B: 3463
MANSOURI K: **3155**
MÄNTYSAARI M: 1153
MANUNTA L: 315, 3356
MANZOURI B: 2335
MARAINI G: 196, 3353
MARCONCINI S: 2141
MARDIN C: 225
MAREY MV: 1146
MARIANI P: 2242
MARINA C: 360, 3417, 3434
MARKIEWICZ A: 2343
MARKLUND SL: 160, 1446
MARQUES C: **197**, 2253
MÁRQUEZ A: 196
MARSCHALEK J: 230
MARSHALL J: 1455
MARTÍN B: 338
MARTÍNEZ-GARCÍA AMG: **356**, **3156**
MARTÍNEZ-JARRETA B: 146
MARTÍNEZ-MORALES JA: 138
MARTÍNEZ A: 374, 376
MARTÍNEZ DE LA CASA JM: 373
MARTHIN JK: 2143
MARTIN B: 1253
MARTINEZ-MONTERO JC: 1454
MARTINEZ DE MIGUEL MARTINEZ M: 263
MARTIN H: 3261
MARTINHO R: 136
MARTINI JøRGENSEN T: 3441
MARTIN L: 268, **3344**
MARTIN MARTIN BMM: 234, 1128
MARTINS ALMEIDA MELO P: **253**
MARTIN W: 239, 2329
MARTONE G: 212, 2141
MARTUS P: 361, 3418
MARUYAMA K: **3331**
MASCARELLI F: 205, 2247
MASCIOPINTO F: 211
MASSAI L: 181
MASSANO J: 2224
MASTROPASQUA L: 386, 1165, 3438

EVER-2004-abstractbook.indd 226 8/19/04 12:27:35 PM

MATAFTSI A: 229, 358, 3158
MATSUNO K: 142
MAURIN JFM: 150
MAVRIKAKIS I: **1364**
MAY CA: **2131**, **2231**, 2133, 2134
MAYOR - TORROGLOSA S: **362**, **363**, **3419**, **341a**
MAYORAL C: **369**, **376**, 367, 368, 370, 371, 372, 373, 374, 375
MAYOR S: 3313
MCCLUSKEY P: 1435
MCDERMOTT AM: **2311**
MCDONALD B: 161, 1447
MCKAY I: 2243
MCKIE L: 2151
MCLEOD D: 366
MCNIECE R: 358, 3158
MEARZA A: 229, 358, 3158
MEDIERO A: 1454
MEEK KM: 1442
MEENAN BJ: 1467
MEHTA JS: **1466**
MEIGEN T: **2424**
MELLER D: 2144
MENCARELLI M: 181
MENDEZ MC: **2347**, **2348**, 2341, 2349, 234a, 234b
MENEZO V: 179, 1114, 1115
MENICACCI F: 2141
MENKE MN: **3412**
MERCIE MM: 1263
MERMOUD A: 1315, 3155
MESNIL MM: 1445
METELITSINA T: 3323
MEULENDIJKS C F M: 2162
MEULLE A: 344
MEYER-SCHWICKERATH RMS: **3243**
MEYER B: 1136
MEYER L: 194, 195, 1232, 2453
MEYER P: 2142
MICHAEL R: **1431**, 3464
MICHAUD JE: 2164
MICHAULT L: 2435
MICHOUD NM: 107
MIDELFART A: 324, **1233**, 1336
MIETTINEN R: 1145
MILANO G: **3411**
MILINCHEVITCH SM: 1445
MILLOT L: 149
MIOT F: 1113
MIRALLES DE IMPERIAL J: 127, 138
MISIUK-HOJLO M: **137**, 178
MISSOTTEN GS: **206**, **2245**, **2248**, 2145
MISSOTTEN L: 105, 316, 1157, 3357
MISSOTTEN T: 179, **1114**, **1115**
MITCHELL S: 115, 189
MOCHIZUKI M: **1211**
MODOS K: 257
MODY JR VC: 195
MODY V: **194**, 1232, 2453
MOISEEVA IM: **3112**
MOLNAR FE: 259
MONTERO J: 1255
MONTINI G: 325
MOORE CBT: 1467
MOORE JE: **1467**
MORA P: **242**, **1415**
MORGADO AM: 154, 1164, 1166
MORGAN J: 2151
MORILLA A: **208**, **215**
MORRIS C: 1469
MOSCHOS MM: **1411**
MOSELEY MJ: 219, 2222, 2225
MOSS R: 248
MOTA S: 272
MOTTERLE L: 2114
MOUILLON M: 118, 129, 202, 221, 2147
MOURIAUX F: **205**, **2247**
MUÑOZ A: 1351
MUECKE B: 1124
MUENSTER D: **2355**
MUGHAL S: **113**, **139**
MUHTASEB M: 176
MUIÑOS Y: 2341, 2348, 2349, 234a
MUKHAMEDJAROW F: 3115
MULET ME: 156, 1265
MÜLLER LJ: 154, **3435**, 1164, 1166
MULS V: 231
MUNIER FL: 2435
MUNOZ MORALES AM: **123**, **2125**
MUQIT MMK: **106**
MURDOCH JR: 106
MURTA J: 154, 314, 1164, 1166, 3355
MURTHY GVS: 3353
NADAL J: 1365
NAGARAJ RH: **1337**, **2456**
NAGAR M: 184
NAGEL E: 232, 244, 1126
NAGY ZZ: **336**, 1131
NAH GKM: 114
NARAYANAN S: 2311
NASCIMENTO JCN: **1352**, 1353
NASCIMENTO SMC: 152, 220, 262, 266, **2425**, 2226, 2426
N ASSO M: 166
NEMETH J: 259, 2313
NEOH C: 209, 310
NIEDERER P: **3445**
NIELSEN KN: **321**
NIEUWENDAAL CP: 3435
NILSSON M: **268**
NIRANKARI VS: **2213**
NI Y: **251**, 380
NORDENSKJOLD M: 1161
NORRILD B: 201, 2146
NOSE I: 3461
NOURI M: **1463**
NOVAK K: 230
NOWILATY SR: **126**, **329**, **1356**
NOWOMIEJSKA K: 216, 2126
NUBILE M: **386**, **1165**, **3438**
NUNES S: 130, **2465**
NÜRNBERG P: 1136
O'BRIEN T: **2115**
OBIKPO R: 1435
OBROSOVA IG: **2324**
OCKRIM ZK: **122**, **2461**
OHBAYASHI M: 2335
OHRLOFF C: 2262
OKANO T: **142**
OKHRAVI N: 1435
OKSALA E: 3151
OLAH Z: **357**, **3157**
OLIVER N: 1151
ONG GL: 267
ONO S: **2335**
OPDENAKKER G: 1213
ORDOÑEZ JL: 208
ORGUL S: **3214**, 1121
ORLOWSKA-HEITZMAN J: 2345
ORNTOFT TFO: 321
OROZCO M: 1461, 3461, 3463
ORTH G: 201, 2146
OSBORNE NN: 237, 238, 252, **2132**, **2233**, **3311**, 2327, 2328
OTTEN HM: 3131
OTTONELLO S: 196
OUBAAZ AO: 150
OWEN RI: 209
OWENS H: **2312**
OYA-ITO T: 1337
OZDEMIR H: 1252
PACHER P: 2324
PAJARÍN AB: 371
PAJARIN AB: 367, 368, 370
PAK NV: 1146
PANDIT R: 177
PANTELEEVA OG: **210**, **224**
PAOLA A: 223
PAPATHEODOROU G: 192, 240
PAQUES M: **2263**
PARAFITA M: 227, 269, 271, 306, 333, 337
PAREL JM: **3463**, 1461, 3461
PARKS S: 106
PARMEGGIANI FP: 247
PATARAIA E: 230
PATEL N: 145
PATIL R: **2234**
PAULA JS: **3352**, 1111
PAUL B: **1363**, 1366, 1367
PÅLSSON AZ: **199**, 243
PÉREZ-CALATAYUD J: 215
PÉREZ-PÉREZ JM: 264, 265
PÖRKSEN E: 3446
PEDROSA-DOMELLÖF F: **173**, **1141**, 1142, 1444
PEIRÓ F: 146
PELÁEZ-COCA MD: 272
PELLEGRINI G: **2431**
PENAS S: **136**, **148**
PEOC'H M: 323
PEREIRA DA SILVA A: 134, 1152
PEREIRA FIGUEIRA J: **3122**
PEREIRA P: 197, 198, 314, **1234**, **2254**, 1333, 2323, 3355
PEREZ-CARRASCO MJ: 264

EVER-2004-abstractbook.indd 227 8/19/04 12:27:35 PM

PEREZ CARRASCO PEREZ MJ: 263
PEREZ MJ: 265
PER FAGERHOLM PF: 321
PESCE G: 213
PETERSEN A: **243**, 199, 1332
PETRIASHVILI GG: 1146
PETRIG BL: 3326
PETROPOULOS I: 182
PETROPOULOS IK: **3326**
PETTA V: 192
PEYRAGROSSE T: 352
PEYROCHE C: 133
PFEILER T: 1453
PFLUGFELDER S: **2214**
PHARMAKAKIS N: **182**, **192**, 240
PHILLIPS JR: 2312
PICCIRILLO V: **213**, 334
PICHLER A: **171**
PIERRE-KAHN VPK: **107**
PIGAZO JM: 2348, 234a, 234b
PILCH HA: 1337
PINAZO DURAN MD: 253
PINDJAKOVA J: 342, 354, 3338
PINELLO L: **325**
PINILLA I: **132**, **302**, 303, 304
PINNA A: **315**, **3356**
PINOLI JC: 346
PINTO PD: **262**
PIPERNO-NEUMANN S: 2242, **2246**
PLANCHER C: 1224, 2242
PLAZAS A: **104**, **1357**, 1351, 3153
PLECH AR: 108, 260
PLEYER U: 341, **1314**, **3334**
PODOLEANU A: **3442**, 3125
PODSKOCHY A: 331
POJDA-WILCZEK D: **108**, 260, **2122**, 2123
POJDA SM: 108, 260, 2122, 2123
POLO V: **374**, **375**, 367, 368, 369, 370, 371, 372, 373, 376
POLSKA E: 235, **1122**, 1129, 3413
POLTAVTSEVA RA: 1146
PONTORIERO GF: 2354
POOL CW: 3126
POPOVIC Z: 110
POPPER M: 154, **1164**, 1166
POUILLART P: 2246
POURNARAS CJ: **2261**, **2267**, **3325**, 3326
PRABHAKARAN E: 319, 2317
PRASANNA G: 3165
PRAUSE A: 335
PRAUSE JU: 116, 201, 204, 2142, 2143, 2146, 2149, 234c
PRETSCH W: 1136, 3351
PRICE GM: 3353
PRICKETT C: 2454
PROENÇA R: 112
PROOST P: 1213
PRUEFER R: 2424
PRUENTE Ch: **3215**
PRZYDRYGA J: **170**, 233, 1127
PTITO M: 2422
PUELL C: 265
PUELL MARIN PUELL C: 263
PUELL MC: 264
PUEYO V: **370**, **371**, 367, 368, 369, 372, 373, 374, 375, 376
PUNYAMOONWONGSA P: 385, 3437
PURI P: 115, 125, 189
PUUSAARI I: **2342**
PUUSTJARVI T: 3151
QUADRADO MJ: **154**, **1166**, 1164
QUEIRÓS A: **227**, **271**, 269, 306, 333
QUINTON JQ: 1163
QURESHI K: 176
RACHAPALLI S: 313
RACHDAN D: 186, 2251
RACINE G: 349
RAINER G: 1123
RAJHI AR: 3432
RALFKIAER E: 2142
RAMALHO J: 2323
RAMÍREZ AI: 143, **144,** 172, 362, 3419
RAMÍREZ JM: 143, 144, 172, 362, 1143, 3419
RAVI N: **3362**
REAL OLIVEIRA E: 162, 163
REEVES B C: 270
REGATEIRO F: 2224
REIME S: 2424
REINHARD G: 1121
REITNER A: 230
REITSAMER H: **2152, 3245**
REJDAK R: 1335
REKONEN P: 3151
RENARD GR: 107
RENARD JPR: 150
RENATA GARCIA-FRANCO: 101
RESÚA C: 163
RESCH H: 102, 1125, 1155
RESSINIOTIS T: **310**, 177, 209, **1135**
RESUA C: 162
RICHARD G: **2167**
RIGAL-SASTOURNÉ JCRS: 150
RISA Ø: 1233
RISSANEN T: 301
RITTER T: 341, 3334
RIVA CE: 254, **2232**, **3321**, 3322, 3325, 3326
ROBBIE S J: **176**
ROBERTS F: 2243
ROCHA-SOUSA A: 148, 190, 1132
ROCHA DE SOUSA A: **2223**, **2325**
ROCHAT A: 2432
RODRIGUES LG: **252**
RODRIGUEZ - CARMONA M: 3144
RODRIGUEZ-PRATS JL: 1261
RODRIGUEZ AE: 2321
ROGERS JA: 3442
ROIDER J: 3446
ROJAS B: 143, 144, 172, **1143**
ROLDAN-PALLARES M: **1454**
ROLLÍN R: 1454
ROMANET JP: 129, 202, 221, 2147
ROMAN JM: 338
ROMANOWSKA DIXON B: **2343**, **2345**
ROMÃO E: 1111
ROMERO-CASTILLO L: 379
RONKKO S: 3151
ROSA CC: 3442
ROS E: 272
ROSE GE: 311
ROSEN R: **3125**, 3442
ROSE S: 1469
ROSSI GCM: 3411
ROTONDO E: 334
ROULAND J-F: 180
RUFIANGE M: 2423
RUIZ-LAPUENTE C: 104, **1351**, **3153**, 1357
RUIZ G: 363, 341a
RUIZ J: 364, 378
RUIZ LAPUENTE CR: 2125
RUIZ MORENO JM: **1255**
RUSIECKA J: 178
RUSSO AR: 247
RYHÄNEN T: 1145
SÆTHER Ø: 1233, 1336
SAGODIRA S: 242
SAHEL J: 175, **2364**, **3312**
SALACZ G: 147, 185, 257, 305
SALAMA BS: **174**, **255**, **2427**, 1163, 1445
SALAZAR JJ: **143**, 144, 172, 362, 1143, 3419
SALEH G: 267, 326
SALEH GM: **274**, 191, 313
SALLO FB: 175
SALMINEN A: 1145
SALMON R: 2242, 2246
SALOMON E: **309**
SALVARANI C: 2121
SALVI SM: 1442
SAMARASINGHE S: 319, 2317
SANCHEZ-RAMOS C: 264, 265
SANCHEZ RAMOS SANCHEZ C: 263
SANCHEZ-SALORIO MSS: 356, 3156
SANCHEZ A: 156, 1265
SÁNCHEZ JM: 338, 360, 3417, 3433
SANCHEZ R: 377, 2227
SANDER B: **3441**
SANDHU R: **109**, **111**
SANDINHA MT: **2243**
SAÑUDO F: 333
SAORNIL-ALVAREZ MA: 208, 215, **2349**, **234a**, 2341, 2347, 234b
SARAIVA J: 2223, 2325
SARASA JL: 2347, 2349
SARFARAZI FM: **3364**
SARMENTO AS: 118
SAROLI TL: 233, 1127
SARROT-REYNAUD F F: 202, 2147
SASAKI K: 159, 1268
SASTRE X: 2242
SAUERWEIN W: 2144
SAUNTE JP: 234c
SAUVÉ Y: **303**, **304**, 132, 302
SAW SM: **1243**
SCATASSI I: 3411
SCHAARAWY T: 380

EVER-2004-abstractbook.indd 228 8/19/04 12:27:35 PM

SCHLENZKA A: 1153
SCHLINGEMANN R O: **1151**, **3234**, 2162, 3121
SCHLOTTMAN P: 2462
SCHMETTERER L: 102, 235, **3161**, **3211**, **3324**, 1122, 1123, 1125, 1129, 1155, 3327, 3413
SCHMIDT N: 341
SCHOLL HPN: 2363
SCHORDERET DF: 2435
SCHUBERT M: 171
SCHUELER AO: 2144
SCORCIA G: 213, 223, 334
SCORCIA V: **334**, 213, 223
SCORSETTI D: 156, 1261, 1265
SCULLICA L: 2314
SEBASTIANI AS: 247
SEITZ B: 335
SELAND J: **3227**
SELBY P: 1136
SEO KR: 158, 1267
SEONG GJ: **245**, 158, 1267
SEREGARD S: 214, **1225**, 1162
SERES A: **1355**
SERGIENKO N: **3363**
SERRA A: 124, 236, 2326
SETHU MADHAVAN A: **307**
SHANG F: 197, **2253**
SHAW SG: 3214
SHELDRICK J: 313
SHIEW M: **184**, **248**
SHUKHAEV SV: 3114
SIDEROUDI TI: **240**
SIEGEL LI: **233**, **1127**
SILVA M: **273**, 2224
SILVA R: 2362
SIMADER C: 1122, 1125
SINGH R: 1435
SIVAGNANAVEL V: **121**, **1154**
SIVAK JG: 3266
SJÖ LD: **2142**
SJÖ NC: 2142
SJÖSTRAND J: 243
SJÖSTRAND JB: **110**
SJO NC: **201**, **2146**
SKINNER KC: **155**, **1167**
SKJODT K: 234c
SMALL D: 1467
SMITH AF: **327**, **3421**
SMITH RT: 121, 1154
SMOLNIKOV BA: 3111, 3113, 3117
SOBRADO-CALVO P: **127**, 138
SÖDERBERG P: 183, 194, 195, **2453**, 1232, 1233, 1235
SOEWARTO D: 1136, 3351
SOLTANINIA J: **157**, **1266**
SOMFAI GM: 2467
SOUBRANE G: 135, **2165**, **3225**, 1254, 1354
SOUIED E: 1254
SOURJIKOV AV: 3114
SOUZA NV: 1111
SOWDEN J: 1134
SPENCER AF: 366
SPILEERS W: 207, **3252**, 2344
SPOERL E: 3115
SRINIVAS HV: 155, 1167
STACHS O: 3261
STANESCU D: **175**
STANFORD M: 1455
STANGOS AAN: 3326
STARZYCKA M: 2343
STÅL P: 1142
STENEVI U: 1162
STENMAN UH: 317, 3357
STEUHL P: 2144
STEVENS MJ: 2324
STEWART WC: 233, 1127
STIP E: 2422
STODTMEISTER R: **3242**
STOIBER J: 1461
STOLARZ W: 108
STREILEIN JS: 355, 3331, 3331, 3332, 3339
STRID H: 183, 1235
STRONG NP: 209
STROTMANN H: 193
STROUX A: 361, 3418
STRUCK HG: **1334**
STRUYF S: 1213
STUR M: 3327
SUAREZ N: 1113
SUGITA J: 2312
SUKHIKH GT: 1146
SUMMANEN P: 317, **1153**, 3357
SUNDARAM V: **161**, **319**, **1447**, **2317**
SÜVEGES I: 336
SVETLOVA OV: **3114**, 3113, 3117, 3118
SWEENEY D: 3463
SZABÓ V: 336, **1131**
SZABO C: 2324
SZLITER EA: **332**
TAHHAN M: **186**, **203**, **2148**
TAKAHASHI N: 159, 1268
TAKI M: 159, 1268
TAKIYAMA T: 1212
TAKSERMAN A: 217, 2127
TAKTAK A: 1222
TALBOT JF: 125
TALBOT K: 320
TAMIYA S: 1331
TANCK MW: 1151
TAN D: **1246**
TANDON R: **1366**, 1363, 1367
TAN HS: 1151
TARDINI MG: 3414
TASSIGNON MJ: **3361**
TAVARES MA: 252, 253
TAYLOR A: 197, 2253
TÖPFNER VON SCHÜTZ K: 193
TEIXEIRA C: **190**, **1132**
TERASVIRTA M: 3151
TERVO TMT: 2315
TERWEE T: 3462
TESSEM MB: **324**, 1233, 1336
TEUS MA: 338, 360, **1253**, 3417, 3433, 3434
TEUS MT: 359, 384, 3159
THAUNG C: 2151
THEISEN-KUNDE D: 3446
THEOCHARIS A: 322
THIRAN C: 134, 1152
THOMPSON GM: 248
THOMPSON S: 186
THORNELL LE: 173
THORN F: 3352
THORP S: 1363, 1367
THURET G: **343**, 133, 149, 323, 344, 345, 346, 347, 348, 349, 350, 351, 352, **1264**
TIFFANY J: **164**, 2312
TIGHE B: **166**, **318**, 165, 167, 169, 330, 385, **2316**, 3437
TIGHE BJ: 168, 1469
TISO C: 3411
TITTL M: 3327
TKACHOV SI: 1334
TONINI M: **202**, 129, **2147**
TOPOUSIS F: **3226**
TOTO L: 1165
TOWLER H: 1435
TREMPE CL: 3412
TRESSERRA F: 1431
TREVITHICK JR: **2454**
TRIVIÑO A: 362, 1143, 3419
TRIVIñO A: 143, 144, 172
TSAPENKO IV: 1146
TSE DT: 222
TUFT S: 1442
TUISKU ISJ: **2315**
TUOMAALA S: 2241
TUOMILEHTO J: 317, 3357
TURCO S: 2314
TUROWSKI P: 122
TURSKI WA: 1335
UNGARO N: **3414**
URBAN E: **178**, 309
URCOLA JH: 364, **378**
UUSITALO H: 301, **3151**, 1145
VAMOS R: 147, 257, **305**
VABRES PV: 174
VAIDEANU D: 307, **1134**, **3152**, 3154
VALAMANESH F: 353, 3337
VALVERDE J: 136
VAN BEST J: 154, 1164, 1166
VAN DAMME J: 1213
VAN DE KRAATS J: 117
VAN DER HEIJDE RGL: **3264**
VAN DER LINDEN MH: 3124
VAN DER WERF F: **1345**
VAN GINDERDEUREN R: **207**, **2344**
VAN HEYNINGEN V: **2351**
VAN LIER HJJ: 3131
VAN LIMBERGEN E: 207, 2344
VAN MEURS JC: 1151
VAN NIEUWENHOVEN FA: 1151
VAN NORREN D: **117**, 119, 120
VANTZOU C: 182
VAN VELTHOVEN MEJ: **3124**, 3121, 3126
VARANDAS J: **2464**, 2463
VARGAS-MARTÍN F: **272**, 127, **3354**

EVER-2004-abstractbook.indd 229 8/19/04 12:27:36 PM

VARMA SD: 2452
VARSANYI B: **2467**
VASDEV ASHOK: 221
VASS C: 1123
VATHESATOGIT C: 319, 2317
VAUDAUX J: **1413**
VÁZQUEZ C: 1351
VECINO E: **364**, 378
VELARDE JI: **3431**
VELIKAY-PAREL M: 2167
VELTEN I: 361, 3418
VELU T: 1113
VERBRAAK FD: **3121**, 2164, 3124, 3126
VERHELST D: 3134
VERONESE RODRIGUES ML: **1111**
VESELA A: 357, 3157
VESELIC-CHARVAT M: 2145
VESELOVSKY J: 357, 3157
VIDAL-SANZ M: 362, 363, **3313**, 3419, 341a
VIDAL LÓPEZ J: **226**, **261**
VIEIRA DE SOUZA E: 151
VIEIRA DE SOUZA N: **151**
VIET TRAN H: 3155
VIGANDER K: **217**, **2127**
VILA J: **265**
VILLEGAS-PÉREZ MP: 127, 138, 362, 3313, 3419
VILSER W: 232, 244, 249, 1124, 1126
VINH VV: **221**
VIRAG L: 246
VIRTAMO T: **317**, **3357**
VIRTANEN I: 1141
VISSER ES: **3131**
VISSER R: 3131
VITIELLO C: 2353
VITOVA A: **342**, 354, 3338
VOGT K: 341, 3334
VOIGT M: **135**
VOLK HD: 341
VOROS GM: **177**, **209**, 310, 1135
VORUM HV: 321
VOSSMERBAEUMER U: **339**, **1144**
VOTE B: 1455
VOYIATZIS GA: 240
VRENSEN GFJM: **1342**
WADDELL JM: **2322**
WAKE K: 159, 1268
WAKILI NS: 1432
WALLACE BJ: 164
WALLY B: 1123
WALTER P: 2167
WANG S: 132, 304
WATANABE S: 159, 1268
WATLING T: 3463
WATSON S: **1368**
WEALE R: **3265**
WEBSTER AR: 121, 1154
WEGENER A: **1231**, **2154**
WEHBEH ML: 186
WEIGERT G: 102, **3327**, 1122, 1125, 1155
WEIR RE: **2221**, 2222
WEITZ R: 3125
WENDT M: 3462
WEON SR: 1241
WERNER J: **3256**
WEST-MAYS J: **2354**
WHEELER LA: 363, **3314**, 341a
WIEDERHOLT M: **3415**
WIEGAND S: 3332
WIETEN L: 1151
WILLERMAIN F: 231, **1113**
WILLIAMS T: 2354
WILSON C: **2111**
WILSON WS: **239**, **2329**
WITKOWSKA DW: 137
WITMER AN: 3234
WITTBRODT J: **2352**
WOLDEMUSSIE E: 363, 3314, 341a
WOLF E: 1136
WOLFF-ROUENDAAL DE D: 2145
WOLF JE: 3251
WOLLENSAK G: 3115
WONG TY: **1244**
WOOD JPM: **237**, 238, **2327**, 2132, 2233, 2328
WRIDE NK: **3154**
WUESTEMEYER H: 2144
WU RY: 251
XU W: **380**
YAMAKI K: **1112**, **1212**
YAMANAKA Y: 159, 1268
YANG J: 341, 3334
YANNOPOULOS S: 192
YAP E: **1242**
YEBRA-PIMENTEL VILAR E: 162, 163
YILMAZ G: **140**, **1256**, **1451**
YINON U: **258**
YKI-JARVINEN H: 317, 1153, 3357
YLA-HERTTUALA S: 301
YOKOI N: 2312
YORIO T: **3165**
YOUNG IS: **3222**
ZACCHELLO G: 325
ZAGÓRSKI Z: 216, 1335, 2126
ZAIDI FH: **219**, **2222**, **2225**, 2221
ZAJICOVA A: 342, 354, 3338
ZARNOWSKI T: **1335**
ZASEEVA MV: **3113**, 3114
ZATORSKA B: 108
ZAWINKA C: **1121**
ZETTERBERG M: 243
ZHAO M: 350
ZHUKOV CR: 250
ZIEBARTH N: 3461, 3463
ZIELINSKA-RZECKA E: 1335
ZIERENBERG A: 241
ZOGRAFOS L: **1223**
ZOLOTAS V: 182
ZOURDANI A: 135, 1354
ZRENNER E: **2363**, 2153

EVER-2004-abstractbook.indd 230 8/19/04 12:27:37 PM

The easiest way to order: copy this page and fax to

S. Karger AG
CH–4009 Basel (Switzerland)
+41 61 306 12 34

David E. Matthews
Vernon T. Farewell

Using and Understanding Medical Statistics

3rd, revised edition

Contents

- Basic Concepts
- Tests of Significance
- Fisher's Test for 2×2 Contingency Tables
- Approximate Significance Tests for Contingency Tables
- Some Warnings Concerning 2×2 Tables
- Kaplan-Meier or 'Actuarial' Survival Curves
- The Log-Rank or Mantel-Haenszel Test for the Comparison of Survival Curves
- An Introduction to the Normal Distribution
- Analyzing Normally Distributed Data
- Linear Regression Models for Medical Data
- Binary Logistic Regression
- Proportional Hazards Regression
- The Analysis of Longitudinal Data
- Data Analysis
- The Question of Sample Size
- The Design of Clinical Trials
- Further Comments Regarding Clinical Trials
- Epidemiological Applications

Fields of Interest: General Medicine, Social Medicine; Communication, Medical Statistics, Epidemiology

Since the last edition of this book was published, major developments in computer technology have affected both the practice of medicine and the methods of analyzing medical data. These advances make the focus of this revised edition – understanding many of the statistical methods that are used in modern medical studies – all the more important. Two new chapters have been added by the authors. One provides readers with an introduction to the analysis of longitudinal data. The other augments previous material concerning the design of clinical trials, exploring topics such as the use of surrogate markers, multiple outcomes, equivalence trials, and the planning of efficacy-toxicity studies. In addition to providing new information and fine-tuning the rest of the book, the authors have reorganized the final six chapters so that the topics build, naturally, on each other. This latest edition is highly recommended both as an excellent introduction to medical statistics and as a valuable tool in explaining the more complex statistical methods and techniques used today.

'... a very useful text to which to refer and expand knowledge in certain areas ...'
International Journal of Epidemiology

'... conveys all appropriate information with exceptional clarity and simplicity.'

'I strongly recommend this book, also as a journal editor. The extraordinary developments in computing technology have enabled almost any clinical investigator to perform sophisticated statistical analysis. This book is an excellent guide to understand them.'
G.A. Fava (Editor)
Psychotherapy and Psychosomatics

Order Form

Please send:

__ copy/ies

Matthews, D.E. (Waterloo, Ont.); Farewell, V.T. (London)
Using and Understanding Medical Statistics
3rd, revised edition
XIV + 246 p., 31 fig., 86 tab., hard cover, 1996
CHF 40.– / EUR 28.50 / USD 35.00
Prices subject to change
EUR price for Germany, USD price for USA only
ISBN 3–8055–6276–4

S. Karger AG
P.O. Box, CH–4009 Basel
(Switzerland)
Fax +41 61 306 12 34
E-Mail karger@karger.ch
www.karger.com

S. Karger Publishers, Inc.
26 West Avon Road
P.O. Box 529
Farmington, CT 06085 (USA)
Fax (860) 675–7302
Toll free: 1–800–828–5479

KARGER

Payment:

☐ Check enclosed
☐ Credit card
☐ American Express ☐ Visa ☐ Diners
☐ MasterCard ☐ Eurocard

Postage and handling free with prepayment

☐ Please bill me

Card No.: Exp. date:

Name/Address:

Date/Signature:

KI 03414

A comprehensive survey of the state of the art in molecular analysis, epidemiology and the management of hereditary ocular disorders



Genetics in Ophthalmology

Editors
B. Wissinger
S. Kohl
U. Langenbeck

Ophthalmology; Genetics; Epidemiology, Human Genetics, Molecular Biology, Neurobiology

The objective of this publication is to enhance mutual understanding and communication between ophthalmologists, molecular geneticists, genetic counselors and biomedical researchers.

In the introductory chapter, current genetic paradigms and experimental genetic approaches relevant to the nature of hereditary disorders are discussed. The following contribution on the epidemiology of hereditary ocular disorders provides an excellent reference to geneticists as well as clinicians. Myopia is presented as an example of a complex clinical phenotype where genes and environment interact. Further molecular ophthalmogenetic topics, such as corneal dystrophies, cataract, glaucoma, opticus neuropathy, non-syndromic and syndromic pigmentary retinopathies, defects of vitamin A metabolism and macular dystrophies including age-related macular degeneration, are investigated in depth. The volume concludes with a survey of color vision deficiencies, a discussion of animal models and gene therapy, and a useful description of technical devices supporting patients who are losing sight.

Contents

A Glimpse into Genomeland: ***Langenbeck, U.***

Epidemiology of Hereditary Ocular Disorders: ***Rosenberg, T.***

Interactions of Genes and Environment in Myopia: ***Feldkämper, M.; Schaeffel, F.***

A Molecular Perspective on Corneal Dystrophies: ***Vincent, A.L.; Rootman, D.; Munier, F.L.; Héon, E.***

Molecular Genetics of Cataract: ***Hejtmancik, J.F.; Smaoui, N.***

Progress in the Genetics of Glaucoma: ***Weisschuh, N.; Schiefer U.***

LHON and Other Optic Nerve Atrophies: The Mitochondrial Connection: ***Howell, N.***

Retinitis pigmentosa: Genes, Proteins and Prospects: ***Hims, M.M.; Diager, S.P.; Inglehearn, C.F.***

Bardet-Biedl Syndrome and Usher Syndrome: ***Koenig, R.***

Genetic Defects in Vitamin A Metabolism of the Retinal Pigment Epithelium: ***Thompson, D.A.; Gal, A.***

KI 03433

www.karger.com/deoph

Developments in Ophthalmology, Vol. 37
Series Editor: Behrens-Baumann, W. (Magdeburg)
ISSN 0250–3751

Genetics in Ophthalmology
Editors: Wissinger, B.; Kohl, S. (Tübingen); Langenbeck, U. (Frankfurt a.M.)
VI + 224 p., 20 fig., 6 in color, 12 tab., hard cover, 2003
CHF 224.– / EUR 160.– / USD 195.00
Prices subject to change
EUR price for Germany, USD price for USA only
ISBN 3–8055–7578–5

Order Form

Please send: ____ copy/ies

Postage and handling free with prepayment

Payment:
☐ Check enclosed ☐ Please bill me

Please charge to my credit card
☐ American Express ☐ Diners ☐ Eurocard
☐ MasterCard ☐ Visa

Card No.: _____

Exp. date: _____

Fax: +41 61 306 12 34
S. Karger AG, P.O. Box, CH–4009 Basel (Switzerland)
E-Mail orders@karger.ch, **www.karger.com**

Name/Address: _____

Date: _____

Signature: _____

KARGER

Orders may be placed with any bookshop, subscription agency, directly with the publisher or through a Karger distributor.